COLUMBIA LIBRARIES OFFSITE
HEALTH SCIENCES STANDARD
HX00043869

RK301 B892
1915
Columbia University
in the City of New York
College of Physicians and Surgeons
Library

Gift of
Dr. C. F. MacDonald

A TEXT-BOOK

OF

DENTAL PATHOLOGY

AND

THERAPEUTICS

FOR STUDENTS AND PRACTITIONERS

BASED UPON THE ORIGINAL OF

HENRY H. BURCHARD, M.D., D.D.S.

LATE SPECIAL LECTURER ON DENTAL PATHOLOGY AND THERAPEUTICS IN THE PHILADELPHIA DENTAL COLLEGE

REWRITTEN BY

OTTO E. INGLIS, D.D.S.

PROFESSOR OF DENTAL PATHOLOGY AND THERAPEUTICS IN THE PHILADELPHIA DENTAL COLLEGE

FIFTH EDITION, THOROUGHLY REVISED

ILLUSTRATED WITH 708 ENGRAVINGS AND A COLORED PLATE



LEA & FEBIGER

PHILADELPHIA AND NEW YORK

1915

C. Franklin MacDonald D. M. D.

H 301
B59 2
1915

Entered according to the Act of Congress, in the year 1915, by
LEA & FEBIGER,
in the Office of the Librarian of Congress. All rights reserved.

THIS

VOLUME

IS RESPECTFULLY DEDICATED

TO

RUSSELL H. CONWELL, D.D., LL.D.

IN RECOGNITION OF HIS UNSELFISH

EFFORTS IN THE

OPENING OF OPPORTUNITIES

FOR EDUCATION.

Digitized by the Internet Archive
in 2010 with funding from
Open Knowledge Commons

http://www.archive.org/details/textbookofdental1915burc

PREFACE TO FIFTH EDITION.

This volume was originally designed as a text-book of the principles and practice of dental medicine for the use of students, and as a reference work on applied special pathology and therapeutics for the use of dentists. Accepting the dictum of the advanced teachers of the day, it was considered that an entirely rational system of dental medicine could have but one basis—namely, the same principles which underlie general medical and surgical practice. The book represents, therefore, an attempt at formulating, from data obtained from every available source, a system of dental pathology and therapeutics of which the several parts shall be in harmony with one another and also with the several collateral sciences involved. The impulse prompting the work was no desire to multiply books, but arose from a conviction expressed by many teachers, that such a volume was needed by students, practitioners, and teachers.

In revising the work for this new edition, the Editor has endeavored to maintain the original idea of a text-book furnishing a description of each dental disease and its treatment in such manner that teachers may find it a useful adjunct in the presentation of dental pathology and therapeutics to their students. The development in this branch of dental science during the last few years has necessitated many changes in the text to reflect the present advanced position of the entire subject. Many new illustrations have been added to increase its value for didactic purposes.

In place of the original section on Pharmacology, which was necessarily limited in scope, the various remedies and drugs mentioned are fully indexed in order that their various uses as applied to the therapy of the pathological conditions discussed may be studied.

The thanks of the Editor are due to those who have kindly loaned valuable illustrations. In no instance has a request been denied.

The Editor also takes this opportunity to express his warm appreciation of the continued favor bestowed on this work by professors and teachers of the subject throughout this Continent and in Europe.

O. E. Inglis.

1524 Chestnut Street,
Philadelphia, 1915.

CONTENTS.

SECTION I.

GENERAL PATHOLOGY.

CHAPTER I.

General Principles 17

CHAPTER II.

Causes of Disease, General and Local 28

CHAPTER III.

Microörganisms as Exciting Causes of Disease 36

CHAPTER IV.

Disturbances of Nutrition 66

CHAPTER V.

Disturbances of the Vascular System 113

SECTION II.

EMBRYOLOGY, ANATOMY, AND HISTOLOGY.

CHAPTER VI.

The Development, Anatomy and Histology of the Jaws and Teeth . 153

CHAPTER VII.

Dentition: Its Progress, Variations, and Attendant Disorders . 194

CHAPTER VIII.

Malformations and Malpositions of the Teeth 239

SECTION III.

AFFECTIONS OF THE ENAMEL AND DENTIN.

CHAPTER IX.

Abrasion, Erosion, and Mechanical Injury 299

CHAPTER X.

Stains of the Enamel and Dentin 329

CHAPTER XI.

Dental Caries: History; Exciting and Predisposing Causes . . 337

CHAPTER XII.

Dental Caries: Pathology, Morbid Anatomy, and Clinical History 362

CHAPTER XIII.

Dental Caries: Diagnosis, Symptoms, and Prognosis 390

CHAPTER XIV.

Dental Caries: Therapeutics and Prophylaxis 416

SECTION IV.

DISEASES OF THE DENTAL PULP.

CHAPTER XV.

Constructive Diseases 447

CHAPTER XVI.

Destructive Diseases of the Dental Pulp 468

CHAPTER XVII.

Methods of Removal of the Dental Pulp and Root-canal Filling 515

CHAPTER XVIII.

Gangrene of the Pulp 562

SECTION V.

DISEASES OF THE PERICEMENTUM.

CHAPTER XIX.

Septic Apical Pericementitis (Acute) 585

CHAPTER XX.

Chronic Septic, Purulent, Apical Pericementitis (Chronic Apical Abscess) 609

CHAPTER XXI.

Non-septic Pericementitis 644

SECTION VI.

PERICEMENTAL DISEASES BEGINNING AT THE GUM MARGIN.

CHAPTER XXII.

Gingivitis 673

CHAPTER XXIII.

Salivary and Serumal Calculus 692

CHAPTER XXIV.

Pyorrhea Alveolaris 713

CHAPTER XXV.

Pericemental Abscess 745

CHAPTER XXVI.

Reflex Neuroses 752

CHAPTER XXVII.

Infections of and from the Mouth, and Sterilization 766

DENTAL PATHOLOGY AND THERAPEUTICS.

SECTION I.

GENERAL PATHOLOGY.

CHAPTER I.

GENERAL PRINCIPLES.

General pathology (*pathos*, disease, and *logos*, a discourse) is that branch of science which treats of the modifications in function and changes in structure occurring in disease. It embraces all pathological processes occurring in the human body, and as many of these occur in and about the teeth, modified only by the peculiar anatomy of the parts, Dental Pathology may be said to be that branch of dental science which treats of modifications in function and changes in structure occurring in the diseases of the teeth and associate parts.

This being true, it follows that the study of dental pathology must be preceded by a study of the general disease processes which affect the tissues of the body, and such of these as are applicable to the study are known as the General Principles.

The word Therapeutics is derived from the Greek *therapeuin*, to take care of, meaning the measures adopted to remedy or remove the changes induced by pathological processes.

The study of the pathology of a part begins with a study of its anatomy and histology, then naturally follows a study of its physiology and embryology. These form the basis from which degrees of abnormal function and altered structure may be judged by comparison with similar processes occurring in other parts of the body.

The body is composed of cells held together by intercellular substance. These cells are the essential functionating parts of the organism; each cell is composed of a small mass of protoplasm containing in nearly all cases a nucleus, and has a form adapted to

its environment and function. The exact chemical composition of protoplasm is unknown and efforts at analysis destroy its peculiar property as a substance exhibiting a sequence of phenomena called life. It is a viscid substance composed physically of a network, the spongioplasm, containing a slightly more fluid substance, the hyaloplasm.[1] Chemically it is 70 per cent. water containing a collection of proteids, and differs as to these in the different classes of cells. Proteids are but imperfectly understood, but are known to consist essentially of carbon, hydrogen, oxygen, and nitrogen, combined with sulphur and other varying elements in enormous molecules approximately represented by the formula $C_{400}H_{310}O_{120}N_{50}S$.[2] This formula represents merely the quantities of these elements, which are probably combined into various chemical compounds in the cell, including in some proteids one or more carbohydrate radicals, and each having its peculiar chemical affinity for food materials, and even irritating or poisonous materials, capacity for energy or function, and reduction to waste or useless cell material. The study of the properties of cell protoplasm may be made by observing *in situ* the action of living cells under normal conditions, and when subjected to artificial stimuli, and by observing the action of free single cells, such as an ameba, under like conditions.

FIG. 1

Changes of form in an ameba: *PP*, pseudopodia; *V*, vesicle; *N*, nucleus.

If a drop of water be taken from the sides or bottom of an aquarium, placed on a slide and covered with a cover-glass, and then placed under a microscope with, first, a $\frac{1}{4}''$ objective, there will be noted at some portion of the fluid a small transparent mass having the appearance of a colorless fragment of jelly; this is an ameba. The outline of the mass may have almost any form. At some portion there will be a defined and easily distinguished spot, the nucleus; at another point a vesicle is seen; the body of the ameba appears to contain numbers of fine granules. The nucleus appears more markedly granular than the body of the ameba. If kept under observation, the ameba will be seen to change its outlines; at one or more and it may be in several places, projections like blunt arms or feet are seen to be extending from the ameba (Fig. 1). On account of their appearance they are called by the physiologist pseudopodia, from *pseudo*, false, and *pous*, a foot—false feet. These changes of

[1] Kirke's Physiology.

[2] Schofield, Elementary Physiology.

form are much varied (Fig. 2). The cell has, therefore, the property of altering its form—*i. e.*, it has mobility and contractility; as by means of these motions it changes its location, it has the property of locomotion.

FIG. 2

Ameboid movement of a white blood corpuscle of man; various phases of movement. (Klein.)

When certain solid substances contained in the water come in contact with the ameba, the latter is seen to flow around and engulf them; as is shown in Figs. 3 and 4, where the analogue of an ameba, a leukocyte, has taken in bacteria (phagocytosis). After a time the ingested body is found to have disappeared; it has been digested. Evidently the cell must produce a substance capable of dissolving some foreign substances—*i. e.*, it has the function of secretion. This is due to a digestive enzyme analogous to trypsin, which has been experimentally isolated from the ameba.[1] More than this, the

FIG. 3

Leukocyte of a frog from the neighborhood of a piece of the lung of a mouse infected with anthrax, about forty-two hours after the piece of lung had been placed under the skin of the frog's back. The leukocyte is in the act of eating up an anthrax bacillus. (Brunton, after Metchnikoff.)

FIG. 4

The same leukocyte a few minutes later, after it has completely enveloped the bacillus. (Brunton, after Metchnikoff.)

ameba does not take in substances indiscriminately; some it rejects. All cells change the chemical nature of the media in which they grow, both by exhausting the nutritive supply and ejecting their excreta.

If the temperature of the slide be raised the movements of the cell become more rapid, and if raised to a temperature of 55° C. the cell contracts in a round lump; it responds to stimuli, and has therefore the property of irritability.

If the stage be cooled, the movements of the protoplasm are

[1] Hiss and Zinsser, Text-book of Bacteriology.

lessened, and when foreign substances come in contact with the cell it fails to encompass them—its irritability and contractility are lessened.

It is noted that some simple cells are attracted and stimulated by light; others are repelled by it.

If a mild induction (interrupted) current be passed through the water in which the ameba is, the movements of the cells are checked; if a strong current be passed, the cell contracts sharply. If a galvanic (constant) current be passed, movement at first ceases, but pseudopodia are extruded toward the cathode and the cell crawls toward that pole.[1]

FIG. 5

Forms assumed by a nucleus in dividing: *a*, resting nucleus; *b*, skein-form, open stage; *c*, wreath-form; *d*, aster, or star-form; *e*, equatorial stage of division; *f*, separation more advanced; *g* and *h*, star and wreath forms of daughter nuclei. (Reduced from Flemming's drawings in the Arch. f. Mik. Anat.)

The cell responds to mechanical stimuli, such as violent shaking, by contraction.[2]

If substances such as ether or chloroform are added to the fluid, the irritability of the cell is so lessened that it does not respond to stimuli. It is either chilled by evaporation or actually anesthetized.

If the supply of oxygen be cut off, or if carbon dioxid be admitted to the fluid, movement ceases and the cell remains contracted.

If the observations are continued, it will be noticed that changes occur in the nucleus of the cell. A series of alterations in its figure are noted, as shown in Fig. 5. Two nuclei are formed, and soon the body of the cell divides and two cells appear—the ameba has reproduced itself.

These observations serve to show that protoplasm as shown by the behavior of cells containing it has the properties of irritability, contractility, motion, selection, secretion, and excretion (*i. e.*, met-

[1] O. Hertwig, The Cell. [2] Ibid.

abolism or cell digestion) and reproduction, and that it responds to stimuli of physical and chemical nature, and that its functions may be altered by substances which are brought in contact with it. Upon these facts depends the practice of therapeutics, in which stimulation, sedation or alteration of nutritive function of the cells by means of the various drugs or remedies available is the aim of the therapeutist.

A living organism, it will be seen, has a certain degree of action and function. The general average of its action and functions is spoken of as a condition of health. When from any cause the functions are raised or lowered or in any way chemically altered from the general average, a condition of disease exists.

Stimulation.—Certain agencies applied to the cell increase its activity; this is called stimulation. The movements of the cell become more rapid, food particles are taken in more rapidly and disappear more quickly; irritability, contractility, and secretion are increased. The cell subdivides, or reproduces more quickly. Increase the stimulation, and the vital activity becomes fretful; in some cases cell division is incomplete—the nucleus divides, but not the cell body. Increase the stimulation beyond this degree, and the wearied cell ceases its movements—refuses to respond; is paralyzed in the body by overwork. It has also been shown that the cell loses its essential substance in overwork and that sometimes the products of its activity are held about it, causing cessation of function. This may be restored, if not carried too far, by rest and nutrition or by rest and the removal of the waste product.

Sedation.—If the conditions be reversed; if, instead of applying a stimulus to the cell, an opposite influence be introduced, the phenomena are reversed.

If the temperature be reduced, the movements of the cell become sluggish; the body changes its form more slowly and less extensively —*i. e.*, contractility is lessened; particles taken into the cell remain apparently unchanged; irritability, secretion, and excretion are lessened; and, furthermore, reproduction does not occur nearly so rapidly—that is, the cell in contact with sedative influences has all of its activities lessened. This leads to paralysis and death of the cell—it is starved to death.

Alteration.—It is to be understood that the cell is a microscopic laboratory conducting complex chemical processes which may be altered by an infinite number of influences of subtle nature. This modification may possibly occur in a manner not referable to simple stimulation or sedation, as, for example, by retention of waste, or depositon of matter extraneous to the cell. Such changes may

fittingly be spoken of as alterations, especially in view of the behavior of cells when subjected to the influence of that class of drugs known as alteratives or such influences as sunlight or the psychological remedies. While such alterations also probably occur as the result of stimulation and sedation, the fact that the beneficial action of certain classes of therapy is not understood warrants this third classification even if for explanatory reasons only. The term malnutrition is synonymous with alteration as here described.

Every cell has a range of resistance to these influences which tend to destroy it, which is fitly termed the resistance of vitality. Disease itself is some alteration in the cell chemistry controlling any one or more of these several cell properties, of irritability, contractility, growth, secretion, maintenance, or reproduction. If any one of these properties is not exhibited, it is said that the cell is diseased.

The cell lives its cycle and reproduces, and the parent is no more, the life being continued in the offspring.

The life and properties of this small mass of protoplasm represent in miniature the primitive functions and life of the highest animals.

The contractility is represented in the motive apparatus of the higher animals.

The reception, engulfing, and dissolving, or casting out, of bodies with which the ameba is brought in contact correspond in the higher animals to the digestive apparatus and process and the excretory function.

The highly evolved irritability is represented in the nervous system of the higher animals.

The movements occurring in and about the vacuole are the progenitors of the circulatory apparatus and all of its adjunct organs.

If the irritability of a simple cell be increased or diminished, it corresponds to a disease of the nervous system, and so with the other functions.

In the human body certain collections of cells are found in which one function is active, the others in abeyance; thus, large colonies of cells exist in which contractility is the dominant property noted; these are muscle cells. Others have but the property of irritability; these are nerve cells. Still others develop peculiar chemical functions, and become glandular or secretory cells. Such collections of cells are known as tissues. These special cell colonies or tissues are built together into defined masses for the performance of their specialized functions. In the development of these masses, means of holding and maintaining the cells in definite mass forms and provisions for their food supply and waste-removing apparatus are provided in what are called the connective tissues, binding the

cells in definite forms and transmitting their vascular supply (food- and waste-carrier). When thus bound together the tissues are said to form organs.

While all tissues are capable of analysis into cells and intercellular substance, a more practical view may resolve the tissues into (1) functional cells; (2) a supporting intercellular substance; (3) intercellular spaces in which flows the lymph derived from the blood; (4) the channels of circulation and conductors of nervous impulses—*i. e.*, arteries, capillaries, veins, lymphatics, and nerves. The arteries bring to the tissues the blood freighted with oxygen and nutrient material. As it passes through the capillaries a portion of the blood plasma, under arterial pressure and osmotic force, passes into the intercellular spaces into contact with the cells. This exuded fluid is now called lymph.

Stated in general terms, the food materials contained in arterial blood and furnished to the tissues by way of the lymph are water, some proteid, and the constituent to make proteid, amino-acids and polypeptids,[1] glucose and fats or their elements, inorganic salts, and oxygen. From this store the cells take what they require, and within themselves they elaborate chemically substances essential to their growth and maintenance as masses of functionating protoplasm (anabolism). As the protoplasm is of more complex composition than the majority of food elements, they are said to form from simple compounds substances of a higher degree of complexity. Having performed its functions, or in the act of such performance, this protoplasm is chemically altered into waste products of less complex chemical composition (catabolism) and such "products of catabolism" are thrown out from the cell into the lymph in the intercellular (lymph) spaces. This process may be spoken of as cell elimination and the substances themselves as cell ejecta. The total process is termed metabolism.

While the exact nature of the chemical change occurring in cells is not known, the present thought is that much of the process of cell metabolism is conducted within the cell through the action of one or more enzymes which have the power of catalytically effecting prompt and smooth chemical changes at low temperature, which can at times be produced in the laboratory only by complicated experiments not at all comparable with the action of cells.

Various organs of the body evidently prepare the food material absorbed by the intestines for the use of the cells—for example, glycogen is formed from the absorbed glucose by the ferment of liver

[1] Howell, Text-book of Physiology, 1911, p. 877.

cells, and when needed again is transformed into glucose. As a proteid example the fibrinogen of the blood is supposed to be produced in the liver.[1] The proteid as built into complete form in the body juice and tissues is very complex and may contain all or a portion of fourteen or more monoamino-acids or four or more diamino-basic bodies, which shows the tremendous problem of the chemical study of metabolism, which is as yet imperfect.[2]

Ehrlich's side-chain theory for immunity (which see) presupposes the presence of atom groups of protoplasm surrounding a complex group of atom groups, the nucleus, each atom group having affinity for a particular form of substance presented to it. These he terms receptors, and each is supposed to possess a combining or prehending group of atoms called an haptophorous group and a ferment group capable of altering the chemistry of the food element to suit its needs or that of the cell as a whole; this latter group is termed a zymophorous group. This obviously is merely stating in a scientific manner that the cell receives and digests food materials. The carbohydrates and fats are in the main the producers of energy, and are, lastly, resolved into glucose and fat or their elements for the consumption of the cells, and by them appropriated into their protoplasm, whence, by catabolic changes, they are started upon their retrogressive course to the final products CO_2 and water. The proteids are mainly useful for the building of the cell protoplasm and its maintenance, and when catabolized end in products which in other organs are transformed into urea and uric acid.

There is evidence that changes occur in the cell waste either in the blood or in various organs of the body. While, then, the bodily ejecta contain substances fairly constant in composition, they are held to represent elaborations of cell waste rather than actual cell ejecta. For example, urea is pretty certainly derived from muscular tissue, yet is nearly absent in muscle and is supposed to be due to the dehydration of ammonium carbonate in the liver.[3] Lactic acid and ammonium carbonate have been experimentally shown to be probably combined into uric acid in the liver. The cell waste is carried by the lymph into the lymphatics connecting with the intercellular spaces. Thence it is delivered by way of the venous system to the circulation, for further elaboration and elimination from the body. Any interference with such elaboration or elimination must of necessity result in a retention of waste products within the system, probably leading to irritation and disturbance of metabolism in all cells.

Cell metabolism is a chemical change and is therefore accompanied

[1] Howell, Text-book of Physiology, 1911, p. 444.
[2] Ibid., p. 986.
[3] Kirke's Physiology.

by heat production. Energy is stored up in the cell as latent force existing in actual cell substance and is capable of liberation under stimulus, which force is expressed in various forms of functional activity—*i. e.*, contractility in muscular tissue, irritability and mentality in nervous tissue, secretion in the various secretory glands, eliminative selection in the various excretory organs, etc. Experimental evidence has shown that after energy has been liberated to the point of fatigue, there is an actual loss of substance by the cells, in consequence of which they become smaller and of different histological appearance. It is evident, therefore, that any condition which will produce an expenditure of energy without a compensating restoration of cell material must result in a malnutritional process. Cells after a period of activity undergo degenerative processes, and are removed or are reproduced by the process of mitosis (Fig. 5).

The life conditions of cells are necessarily those under which they best perform these functions without exhaustion, and are the following: (1) a proper food supply, including water and oxygen; (2) a proper removal of waste products; (3) proper physical conditions, including a proper temperature; (4) possibly a proper innervation.[1] Any interference with these conditions, which may be termed the normal physiological conditions, results in a morbid process of physiology or *pathology* in its limited sense. With such interference *disease* may be said to begin. The definition of disease as an *alteration of nutrition* is therefore appropriate. For this reason the proximate exciting causes of disease are classed as (1) abnormal food supply; (2) abnormal waste removal; (3) abnormal physical conditions; (4) abnormal nerve supply.

The morbid physiology results in morbid products or in retained normal products and an altered cell function. When pronounced this is spoken of as Functional Disease, although it may be said to be in existence even if discomfort be not produced. Sooner or later an abnormal change in the histological characteristics of the cells or intercellular substance may occur, which has been referred to as Morbid Histology or Pathological Histology. As definite microscopic and often macroscopic appearances are associated with certain diseased conditions, these are referred to as the Morbid Anatomy of a disease or Pathological Anatomy. The phemonena associated with a disease are called its Semeiology (*semeion*, a mark or sign) or Symp-

[1] While this conception is practical, experiments at the Rockefeller Institute have shown that, kept in a proper aseptic nutritive fluid at a low temperature various organs and tissues may be preserved for a considerable time and even shipped, thus being available for surgery. This shows that cells possess a life only dependent upon the body as a whole for their source of nutritive supply.

tomatology, and are either described by the patient as sensations or pains of varied character or situation (Subjective Symptoms), or may be noted by normal or aided vision, by physical examination, chemical analysis or positive reactions to certain biological tests (as in the Wassermann reaction for syphilis) (Objective Symptoms). That which excites a disease or promotes the action of the excitation is called a Disease Cause. The study of disease causes is Etiology (*aetios*, a cause, and *logos*). It is noted that diseases having a fairly defined pathology and morbid anatomy have from their beginning to ending tolerably constant phenomena; they have each a natural history; this is called the Clinical History of a disease.

The study of the origin and development of a disease together is known as its Pathogenesis (*pathos*, disease; *gennao*, I produce). Through the study of the characteristic symptoms of diseases, as well as those common to several diseases, a particular disease may be distinguished. This is called Diagnosis (*dia*, through; *gignosko*, I know)—Direct Diagnosis when there is no question as to the symptoms, Differential Diagnosis when several diseases are possible and the characteristics of one are considered as more pronounced. Under certain circumstances a disease may be inferred to be present by excluding all other possible conditions (Diagnosis by Exclusion). A fourth method of diagnosis is by the therapeutic test (see below). In the course of a disease experience has shown that certain signs and symptoms are apt to be followed by good or ill results, as the case may be. By these signs and symptoms it may be foretold with some degree of assurance what will be the probable outcome of the disease. The inference based upon these symptoms is known as the Prognosis (*pro*, before, and *gignosko*, I know). The care of or treatment of a disease is its Therapeutics. This involves a knowledge of remedies applicable, known as the Materia Medica. When applied upon the basis of a scientific study of the pathogenesis, clinical history, and prognosis of disease and a parallel knowledge of the physiological action of drugs and of other remedies, the treatment is known as Rational Therapeutics. When the treatment is based upon the known good effects of a remedy in a certain disease, and not upon its physiological action, it is known as Empirical Therapeutics. Diagnosis may not always be clear, but upon a basis of previous experience of association of symptoms a given therapeutics may be applied with more or less rationality. Whether good results follow or not the method is known as "the therapeutic test."

The pathogenesis of a disease being known, intelligent efforts may be exerted for its prevention. The causes may be removed or neutralized before they have an opportunity to act; this is Prophylaxis.

The science of prevention of disease upon the broad basis of a knowledge of disease causes and observance of laws of health is Hygiene.

It will be seen that a knowledge of special pathology can only be obtained from (1) a knowledge of pathology in general or at least of those principles of general pathology which underlie all disease processes; (2) a knowledge of the local anatomy and histology; (3) a knowledge of local embryology and physiology; (4) a study of local pathology and morbid anatomy. To this must be added a study of materia medica and special therapeutics.

CHAPTER II.

CAUSES OF DISEASE, GENERAL AND LOCAL.

A DISEASE cause may be defined as any influence of whatsoever nature which is capable of disturbing the nutritive balance of any portion of the body. The branch of study which deals with the causes of disease is called Etiology.

The causes of disease are classed as Exciting (or Determining) and Predisposing. These are each divisible into Extrinsic, originating from without, and Intrinsic, originating within the body.

EXCITING CAUSES OF DISEASE.

These are influences, either extrinsic or intrinsic, which are competent to suddenly or gradually interfere with the nutrition of the cells of a part or with the general nutrition of cells. These influences are very numerous, but may be grouped according to their action under a few convenient headings: (1) Abnormal Food Supply. (2) Abnormal Waste Removal. (3) Abnormal Physical Conditions. (4) Abnormal Nerve Supply.

These are termed the Proximate Exciting Causes, as their effects are immediately exerted upon the cells. Other causes may be back of these and are spoken of as Primary (or Contributory) Causes—*e. g.*, tuberculosis of the lung (primary) may cause insufficient oxygenation of the blood which constitutes an abnormal food supply (proximate).

Abnormal Food Supply.—By abnormal food supply is meant an altered quantity or quality of nutritive elements delivered to the cells either of a part or of the entire body. The primary causes of this may exist as disturbances or faults in any of the food-elaborating organs, the lungs, the eliminating organs, or the oxygen carriers of the blood may exist in lessened numbers. In the first case the quality or quantity of nutritive material is impaired, in the second and fourth cases oxygenation is insufficient, and in the third case materials injurious to cells are retained in the body and are again presented as food to the cells, acting as poisons. Poisonous or even non-poisonous drugs, and the products of bacterial action, whether absorbed from the intestines or from foci of infection, have all more or less delete-

rious action upon cell protoplasm, violent if entering the blood in large quantity, chronic if entering continuously in small quantities.

Faults in the circulatory apparatus, interfering with the circulation generally, cause an interference with general nutrition, while local disturbances of the circulation from any cause disturb the relations of the blood supply to the nutrition of a part. Thus the fresh blood supply (food supply) to a particular location may be excessive, as in arterial hyperemia, or deficient, as in venous hyperemia and inflammation.

Abnormal Waste Removal.—Abnormal waste removal is ordinarily included under the heading of abnormal food supply, and it is evident that retention of waste in the blood causes the presentation to cells of an abnormal food or poison. In local conditions, such as venous hyperemia and inflammation, the stasis causing waste retention prevents the access of a fresh food supply as well. In kidney disease the substances ordinarily physiologically eliminated by the kidneys are retained in the blood and act as poisons to cell protoplasm generally. Insufficient circulation of lymph about cells means a relative retention of waste products about the cells with its effects upon them.

Abnormal Physical Conditions.—This class of disease causes includes all injuries due to any of the physical or chemical forces: Traumatic injuries, such as cuts, bruises, surgical openings, etc. Mechanical causes, such as compressions, obstructions to ducts or the natural outlets of the body, faults in the circulatory mechanism, stoppages in the arteries or veins. Chemical causes, such as the action of abnormal temperatures, burns, freezing, or irritations of various sorts, such as those due to mustard, arsenic, acids, or caustics, and the local effects of microörganisms may all be classified under this heading. The disturbance is due to either a direct destruction of the life of the cells or an interference with the circulation in a part.

Abnormal Nerve Supply.—It is known that division of, injury to, or disease of certain nerves causes trophic or nutritional changes in the part to which they are supplied. Whether the nutrition of the parts is controlled by special trophic nerve fibers has not been demonstrated. Halliburton,[1] in support of the trophic influence of nerves, instances that when the fifth nerve (sensory) is divided beyond the Gasserian ganglion, ulceration of the cornea results; while if the seventh nerve (motor) be divided or paralyzed, the eyeball is equally exposed to irritants, yet does not ulcerate. He also instances that division of the vagi produces fatty degeneration of the heart.

[1] Kirk's Physiology.

While admitting the lack of anatomical proof, he regards the trophic influence of nerves upon parts to be unexplainable upon the ground taken by others, that all apparently trophic changes are due to disturbances of the vasomotor nerves controlling the caliber of vessels. According to these other observers degrees of dilatation are produced which modify the amount of blood delivered to a part and thus modify its nutrition.

Effects are produced upon nutrition by causes which can act only through the nervous system—*e. g.*, the effect of anxiety upon appetite and digestion. The interdependence of these classes of causes is almost self-evident; for example, constant suppuration at a focus of infection (abnormal physical condition) may induce a toxemia (abnormal food supply) which may be responsible for kidney or other disease (abnormal physical condition), resulting in the retention of waste products in the blood (abnormal waste removal or food supply), which has a vicious result upon all metabolism, including that of the nervous system, inducing in turn an abnormal nerve supply and lessening resistance even in the tissues about the original focus of infection. Such a train of events is known as the establishment of a vicious cycle and is interesting as related to the lessened resistance produced in the gingival tissues in pyorrhea alveolaris.

PREDISPOSING CAUSES OF DISEASE.

A predisposing cause of disease is one which influences the cells or juices of the body or part in such a manner as to lessen the resistance to the action of the exciting causes of disease.

It must be considered that a predisposition or lessened resistance is in itself a condition of disease, not recognizable, perhaps, yet a departure from the standard of the best health of an individual or part. For the most part predisposition is regarded in its relation to the extrinsic causes of disease, such as bacterial influences. In such a condition the individual is said to be susceptible. (*Susceptibility.*) Predisposition is either general or local.

General Predisposition.—This is either (1) a natural or inherent lack of resistance to infectious or non-infectious diseases, or (2) an acquired lack of resistance to infectious or non-infectious diseases. The human race in general is naturally predisposed to many infectious diseases, such as tuberculosis, cholera, malaria, measles, smallpox, typhoid fever, scarlet fever, and syphilis.[1] When a person is exposed to the disease and contracts it, he is said to be predisposed

[1] Ziegler, General Pathology.

or susceptible to it. If he does not contract it, his system is immune either temporarily or permanently. (See Immunity.) There being several forms of immunity, the lack of any natural form may be considered as a predisposition. This immunity is ordinarily operative when the individual is in the best state of health, and when a departure from this standard is brought about by any cause, exciting infective causes may then act. This is acquired predisposition. Some individuals have a natural or congenital lessened resistance to external influences of a non-infectious character, such as heat or cold, mental effort, or nervous irritations of a degree ordinarily borne by the great majority of individuals. This may also be acquired, as, for example, by extreme subjection to the above or other enervating causes. An inherited predisposition to such diseases as insanity, cancer, or gout may exist.

Some persons cannot bear certain kinds of food without illness, or react strongly to small doses of drugs, or are not affected by large doses. This is called an idiosyncrasy, and may be either congenital or acquired.

The predisposing causes capable of producing a lessened resistance may be grouped under a few headings.

Sex as an Intrinsic Predisposing Cause.—In this connection the influence of sex upon predisposition to disease must be considered. While the general resistive power of the bodies of both sexes may be regarded as practically equal under similar conditions, yet the anatomical structures and physiology of each sex have an influence upon predisposition to certain diseases. Aside from the diseases peculiar to sex, on account of their peculiar organs, each sex exhibits predispositions to diseases which the other sex escapes; for many of these the habits of life furnish an explanation, for others an explanation is not available. For example, males are much more subject to hemophilia than females.

Age.—During the first two years after birth the nervous system and the appendages of the alimentary canal are developing, and improper feeding, difficult teething, or other influences readily act as exciting causes of alimentary or nervous disturbances.

Later, children are subject to acute infectious diseases, especially tuberculosis, diphtheria, and the eruptive fevers. At adolescence other predispositions occur, notably chlorosis in young girls. Later come the diseases of early maturity, such as typhoid fever, pulmonary tuberculosis, and to a degree dental caries.

In old age or middle life occur arterial and other degenerations and diseases consequent upon them or upon overstimulation of organs or tissues.

Temperament.—Temperament is the peculiar congenital constitution of an individual imparting certain physical characteristics and certain natural tendencies. There are four basal temperaments:

The sanguine is that in which individuals are decidedly inclined to the blonde type, with evidence of an abundance of the nutritive fluid, the blood—*i. e.*, the vascular system is said to dominate the other functions of the body. Such are predisposed to acute pulmonary and cardiac diseases and inflammatory disturbances of serious import. The mental characteristics of this temperament are hopefulness, cheerfulness, and solidity but floridity of mental endowments. The recuperative power is good.

The bilious temperament is characterized by a decided inclination to the brunette type, with evidence of a domination of other functions by the liver. There is a tendency to hepatic and digestive derangements and despondency; at the same time there is possessed great physical and mental strength, together with a reliable recuperative power.

The nervous temperament is indicated by the smallness and delicacy of frame and the quickness of motion and perception, evidencing a domination by the nervous system, to diseases of which such temperament predisposes. In such individuals disease is usually of rapid course, and recuperation is rather more rapid than reliable.

The lymphatic temperament is indicated by bulk, pallor, and flaccidity of tissue, a colorlessness of temperament, indicating an inherent feebleness. There is a tendency to serious chronic conditions. This temperament is accompanied by poor recuperative force.

There are no individuals of pure basal temperament, so that the nearest approach is a dual or binary temperament, such as the biliosanguine, in which the characteristics of the sanguine predominate, strongly modified by those of the bilious temperament. In like manner the sanguonervous, nervolymphatic, and other classes, twelve in number, are recognized as having typical representatives in each community. A third or ternary classification is possible—*e. g.*, sanguonervobilious. It will be seen that temperament has a distinct relation to the vital resistance normally implanted in an individual, and therefore may to a certain extent be counted upon in a prognosis. Temperament is a predisposing cause probably only in so far as it introduces a natural general lack of resistance to disease, or irresistibly drives an individual into certain habits of life which may become the cause of a lessened resistance. The writer is aware that question has been raised as to even the existence of such a thing as temperament. It is true that the Chinese, Negro, Arab, etc.,

have not been included in the above classifications. As applied to the Caucasian race, however, what is said above is intended to convey the meaning that there is a combination of mental and physical characteristics which, apart from education or environment, influence the tendencies of individuals.

Heredity.—Certain diseases exhibit a predisposition to descend from parent to child direct, or from grandparent through the unaffected son or daughter to a grandchild (in the latter case it is called atavistic hereditary transmission, also remote heredity).

The mode of transmission is in all probability the inheritance of a type of tissue, a tissue anatomy and physiology which permit the more ready action of the exciting causes of the disease. This tendency is called a diathesis—*e. g.*, hemorrhagic diathesis (hemophilia), gouty diathesis, or tuberculous diathesis. Diathesis may also be acquired. The influence of race may also be considered as coming under this heading. (See Immunity.)

Existing Disease.—The presence of one disease may weaken the resistance of a part or the organism so that another disease may the more readily become implanted—*e. g.*, measles followed by pneumonia; diabetes accompanied by pyorrhea alveolaris. In diabetes the opsonic index may be reduced one-half. McFarland states that when glucose is present in excess in the blood (glycosuria as in diabetes), susceptibility to infection is increased.

Previous Disease.—At a period subsequent to disease the same disease may recur or another disease may be implanted—*e. g.*, pneumonia predisposes a lung to a recurrence of pneumonia, or tuberculosis may readily follow. Previous disease may confer immunity to the same disease, as, for example, in smallpox or measles.

Extrinsic Predisposing Causes of Disease.—Under this head are included all those conditions of external origin which lessen the resistance of an individual to the action of exciting causes. Excessive heat is weakening; cold and dampness, by chilling the surface of the body, cause hyperemia of internal parts and thus predispose to such diseases as pneumonia, rheumatism, etc. Fatigue, unhealthy, cramping, or sedentary occupations, continued loss of sleep from any cause, evil habits, continued hunger, etc., are other examples of debilitating influences which may be partly intrinsic.

Local Predisposition.—Alterations in the normal physiology of a part are apt to occur through certain actions upon it, thus bringing it into a condition of lessened resistance, permitting the action of entirely different exciting causes. Apart from this fact, a part may be predisposed, by nature apparently, to permit the growth of

bacteria which do not grow well in other tissues. Local depression of tissue vitality predisposes to the growth of organisms in the tissues. Thus slight injury producing either arterial or venous hyperemia or ischemia may permit bacteria to produce even grave consequences. More severe injury also may predispose, but the contrary effect has also been observed—*i. e.*, that severe injury excites a phagocytic reaction and copious exudation of lymph (a later stage of inflammation) which antagonizes the bacteria. (See Inflammation.)

The structure of a part has also been shown to have an effect upon the life of microörganisms gaining access to its tissues. The tissues about the mouth are normally notoriously resistant to infections, but at times are exceedingly susceptible, as in pyorrhea alveolaris. Ordinarily surgical operations about the mouth were successful in pre-aseptic times, while abdominal or gynecological operations were attended by an enormous percentage of death from infection. General depression of vitality also necessarily affects the resistive force of all local tissues. Thus extensive suppuration is more liable to occur in those rendered feeble and anemic by any cause.

IMMUNITY.

Immunity is the opposite of predisposition, and, like it, can be either natural or acquired. It signifies an insusceptibility to a disease. Natural immunity to a particular infectious disease can only be determined by repeated exposures, and may then fail at last owing to some systemic change.[1] Immunity may be exhibited toward only one disease. In some persons disease appears to be influenced by sex, as, for example, males have a general immunity from goitre, females from Addison's disease. Immunity is influenced by age in certain diseases; for example, the diseases of childhood are rare in the elderly; they do occur, however. The degenerative diseases of old age are almost unknown in childhood. Race has its influence; the negro is almost immune to malaria and yellow fever, but particularly susceptible to smallpox and tuberculosis. Some have explained this on the ground that in localities in which malaria and yellow fever are endemic the disease has been acquired in early life and that an apparent natural immunity is really an acquired immunity. Inheritance of amboceptors from immune ancestors has been offered as an explanation. The natural immunity may be more apparent than real, owing to failure of the bacteria to find a local condition favorable to development and to enter the blood. If special care

[1] Green, Pathology and Morbid Anatomy.

in experiment be taken to introduce the bacteria, and failure of inoculation result, the natural immunity is absolute. Example: Rats to diphtheria, or negroes to yellow fever.

A striking example of lost immunity occurred in the case of a friend, who, in early and middle life, could handle poison ivy with impunity. On approaching seventy years of age, and while in a condition of general debility, he was affected from head to foot with the peculiar dermatitis as the result of pulling up a plant.

The further discussion of immunity as related to bacterial infection should properly be discussed after the consideration of bacterial causes, and will be found at the end of Chapter III.

CHAPTER III.

MICROÖRGANISMS AS EXCITING CAUSES OF DISEASE.

The infectious and contagious diseases have for the most part been shown to be caused by low forms of vegetable organisms known collectively as fungi, while in a few diseases minute animal organisms (protozoa) are the causes.

The following table shows the position of the vegetable organisms in the scale of vegetable life and gives the lowest forms of animal life:

Vegetable kingdom	Phanerogams: plants reproducing by flowers and seeds.				
	Cryptogams, reproducing by spore formation or division.	Leafy cryptogams.			
		Thallophytes, having no distinction between the leaf and stem.	Lichens.		
			Algæ.		
			Fungi.	Basidiomycetes.	Favus fungi.
				Mycomycetes.	Common molds.
				Phycomycetes.	Mucor molds.
				Saccharomycetes.	Yeasts or blastomycetes.
				Schizomycetes.	Bacteria.
Animal kingdom	Lowest forms	Protozoa: single cells without circulatory or nervous systems.	Sarcodinea.		
			Flagellata.		
			Sporozoa.		
			Infusoria.		
		Mycetozoa, fungi not certainly defined as animal or vegetable forms.[1]			
	Higher forms.	Certain insect and worm forms are pathogenic.			

Fig. 6

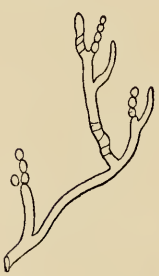

Trichophyton tonsurans ("barbers' itch"). (Mycomycetes.) Diagrammatic. (Lehmann.)

Of the protozoa four classes are known, though but few species are pathogenic; these classes are (1) the sarcodinea (ameboid), which includes the Ameba coli of dysentery (Fig. 10); (2) the flagellata, non-ameboid but motile by means of flagella; (3) the sporozoa living within the bodies of other animals, a class which includes the hemosporidia, ameboid motile parasites living in the blood, and of which the malarial germs, Plasmodium malariæ (quartan fever, seventy-two-hour cycle), the Plasmodium præcox (estivo-autumnal fever, twenty-

[1] The terms mycetozoa and protozoa seem to be practically synonymous to pathologists, who use the term protozoa in the sense of mycetozoa as above defined.

four or forty-eight-hour cycle, Fig. 11), the Cytorrhyctes variolæ seu vaccinæ (the probable cause for smallpox and chickenpox) are examples; (4) the infusoria.

Fig. 7

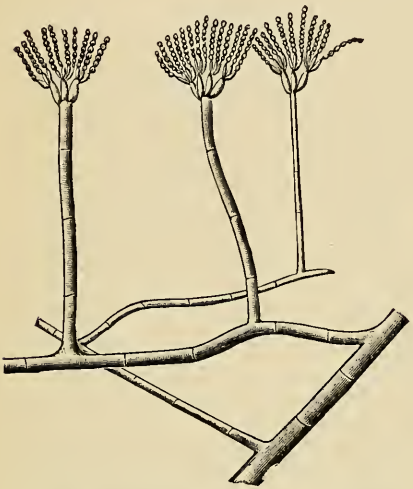

Penicillium with spores. (Mycomycetes, non-pathogenic.) (Lehmann.)

Fig. 8

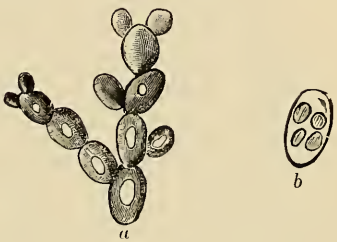

a, saccharomyces; *b*, cell with four spores. (Lehmann.)

Fig. 9

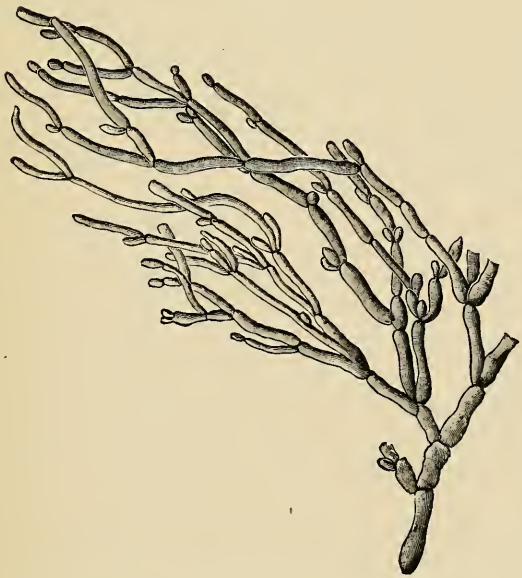

Saccharomyces (oïdium) albicans. (After Grawitz, in Lehmann.)

Fig. 10

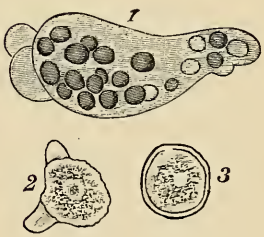

1, ameba from dysenteric stool, with vacuoles and inclosed red cells; 2, ameba from straw infusion; 3, the same encysted. × 600. (Künster.)

Some of the protozoa act by entrance to the intestinal tract as Ameba coli of dysentery; some by direct contact of the healthy

FIG. 11

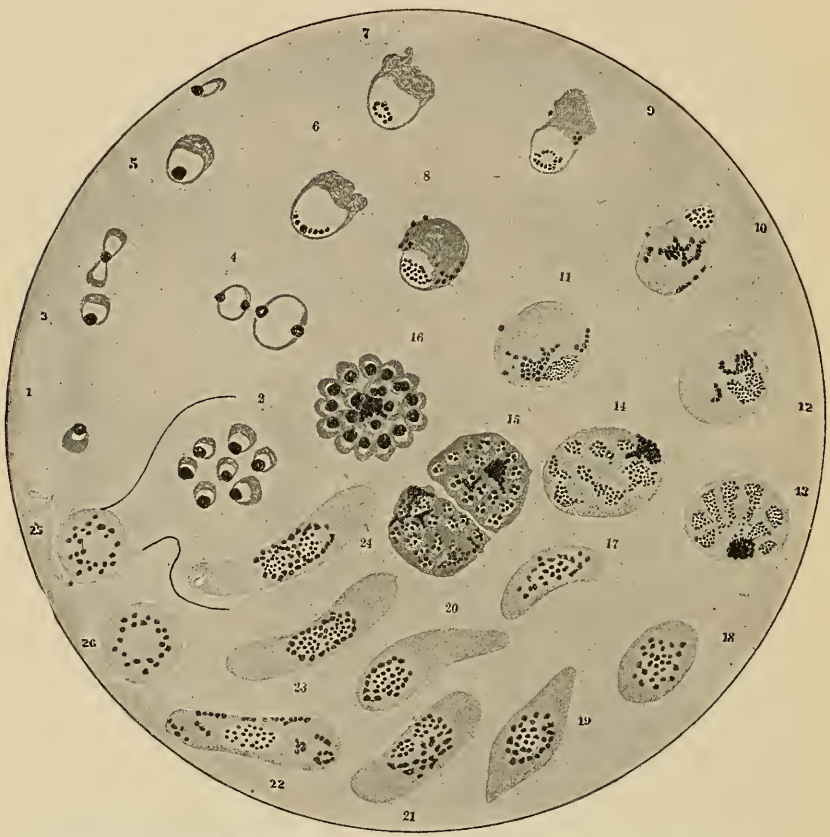

Plasmodium præcox (forty-eight hours). Cycles of estivo-autumnal parasite 1, very young form; 2, infection of one cell with seven young parasites (drawn from a marrow smear); 3, triple infection, two parasites joined by single chromatin mass; 4, double infection, peculiar rings with two chromatin grains at opposite poles; 5, double infection, small ring adherent to cell; 6, 7, signet ring forms, subdivision of chromatin; 8, 9, later ring forms, with subdivided chromatin and few pigment grains; 10 to 12, full-grown forms, with finely subdivided chromatin and gradual concentration of pigment; 13, 14, stages of presegmenting forms, with concentrated eccentric pigment; 15, double infection, with separate presegmenting bodies; 16, estivo-autumnal rosette; 17, 18, young crescent and ovoid; 19, "pulsating" crescent; 20 to 22, various forms of crescents; 23, two bows about single crescent; 24, fully developed crescent, two masses of chromatin, achromatic substance, double wreaths of pigment; 25, diagrammatic flagellating body; 26, extracellular sterile body. (Schmaus and Ewing.)

with the diseased surface or the infected object, as Treponema pallidum of syphilis (not yet positively classed with the protozoa) or Trepanosoma equiperdum of equine syphilis (Dourine). Some

act only through an intermediary host as in the case of the plasmodia of malaria through the anopheles mosquito. For a more extensive description of the action of protozoa, see works on general pathology.

FIG. 12

a *b* *c*

a, spiral forms with a flagellum at only one end; *b*, bacillus of typhoid fever with flagella given off from all sides; *c*, large spirals from stagnant water with wisps of flagella at their ends (Spirillum undula). (Abbott.)

The vegetable fungi are divided into (1) Basidiomycetes, which form spores borne upon basidia. The Achorion schönleinii, cause of tinea favosa or favus, a disease of the hair, usually of the head, is an example. (2) Mycomycetes (common molds) many-celled, characterized by mycelium. Form sporangia, conidia, and asci. Example: Oïdium albicans, cause of thrush and aphthous ulcer, frequently in the mouth. Trichophyton tonsurans, cause of barbers' itch. (3) Phycomycetes (mucor molds). Resemble algæ, but destitute of chlorophyl; occasionally pathogenic in man. (4) Sacharomycetes (Blastomycetes), yeasts. Useful in vinous and bread fermentation; occasionally causes a vegetative dermatitis called cutaneous blastomycosis.[1] (5) Schizomycetes, or bacteria. Being without chlorophyl (the green coloring matter of plants which synthesizes CO_2 and water into starch), the fungi are unable to utilize the simple compounds, such as carbon dioxid and ammonia, as foods, and are therefore compelled to break down the complex organic compounds, for which purpose they are competent by reason of their enzymes. All classes of fungi have representatives which produce disease in the human body, but the schizomycetes furnish by far the greater number of infectious disease causes.

Chemically, bacteria are about 85 per cent. water, together with albumin, called mycoprotein, ferments, soluble extractives, salts, sometimes nuclein bases, coloring matters, organic acids, sulphur, starch, and cellulose.

The schizomycetes (Greek *schizo*, to split, and *mukes*, a fungus) are minute single-celled plants without nuclei, but possessed of a

[1] See Hyde and Montgomery, Diseases of the Skin.

cell wall and cell protoplasm (mycoprotein). They have a size of about 1 micron ($1\mu = \frac{1}{25000}$ inch) or less in their smallest diameter. Some of them possess flagella, hair-like processes, often very numerous, arising from the protoplasm rather than the wall, with which

Fig. 13

Typhoid bacilli stained by Van Ermengem's method to show flagella.

they lash the fluid surrounding them, and by which means they effect locomotion (Fig. 12). Other bacteria again are non-motile. Entering the organic compounds, carbohydrates, hydrocarbons, and nitrogenus (albuminous) substances, they ferment or decompose them, forming new products, and extract from them substances

Fig. 14

a, staphylococci; *b*, streptococci; *c*, diplococci; *d*, tetrads; *e*, sarcinæ. (Abbott.)

necessary to their growth and subsequent reproduction. The substance in which they thus grow is called the medium or soil. The conditions under which this is accomplished are: (1) The fungi must have a proper vitality. (2) Their food-supply or soil must be suited

to their growth and must be moist. When dried they may retain their vitality without development for months. In general terms they require water, CNO, and salts. (3) The temperature must be suitable; they grow more actively at about 102° F.; at 160° F. maintained they usually die, but in some cases, as with the typhoid bacilli, they may live in the spore form at even 212° F. or over unless maintained for some time. Some that develop best at high temperature are called thermophilic. Low temperature, as 32° F. or far below that, inhibits their growth, but does not necessarily kill them. (4) Their waste products must be removed or they die in them. This is said to be due to the reaction, whether acid or alkaline, and not to any of the other by-products—*e. g.*, in lactic fermentation 2 per cent. of lactic acid is about the greatest amount endured by them. They are also sensitive to and inhibited by agitation, daylight, electric light, and electric currents. Morphologically the schizomycetes are grouped into several families according to form, methods of reproduction, and motion. The following is Migula's classification modified by McFarland:[1]

FIG. 15

Zoöglea of bacilli. (Abbott.)

I. **Family Coccaceæ.**—Cells globular, becoming slightly elongate before division, which takes place in one, two, or three directions of space. Formation of endospores very rare.

1. *Streptococcus.*—Division in one direction of space only, producing chains of organisms like strings of beads. No flagella.

2. *Micrococcus.*—Division in two directions of space, so that fours or tetrads are often formed. No flagella.

3. *Sarcina.*—Division in all three directions of space. Leading to the formation of bale-like packages of cocci. No flagella.

4. *Planococcus.*—Division in two directions of space, like micrococcus. Flagellated.

5. *Planosarcina.*—Division in three directions of space, and like sarcina, but provided with flagella.

II. **Family Bacteriaceæ.**—Cells more or less elongate, cylindric, and straight. Never form spiral windings. Division in one direction of space only, transverse to the long axis.

1. *Bacterium.*—Without flagella. Occasional endospores.

2. *Bacillus.*—Flagella arising from all parts of the surface. Endosporulation usual.

3. *Pseudomonas.*—Flagella attached only at the ends of the cells. Endosporulation rare.

[1] Text-book of Pathology.

III. **Family Spirillaceæ.**—Cells spirally twisted like a corkscrew, or short and curved and representing segments of the spiral. Division transverse to the long diameter.

1. *Spirosoma.*—Rigid. Without flagella.

2. *Microspira.*—Rigid. One, two, or three undulating flagella attached to the ends.

3. *Spirillum.*—Rigid. From five to twenty semicircular or undulating flagella attached to the ends.

4. *Spirocheta.*—Serpentine and flexile. Flagella not observed. Movement probably accomplished by means of an undulating membrane.

IV. **Family Mycobacteriaceæ.**—Cells forming more or less elongate, cylindric filaments, often clavate-cuneate or irregular in form. No endospores, but formation of gonidia-like bodies due to segmentation of the cells. No flagella. Division transverse to the long diameter. Not surrounded by a sheath as in chamydobacteriaceæ.

1. *Mycobacterium.*—Cells in their usual form, short cylindric rods, often bent and irregularly cuneate. At times Y-shaped forms or longer filaments with true branchings. Sometimes produce short coccoid elements, perhaps gonidia. (This genus includes the corynebacterium of Lehmann-Neumann.)

2. *Actinomyces.*—Cells in their ordinary form occur as long branched filaments. Produce gonidia-like bodies. Cultures usually have a moldy appearance, due to the development of aërial hyphæ.

V. **Family Chamydobacteriaceæ.**—Vary in different stages of their development. Characterized by a surrounding sheath about both branched and unbranched threads. Division transverse to the length of the filaments.

1. *Cladothrix.*—Characterized by *pseudo*-dichotomous branchings. Division only transverse. Multiplication by the liberation of whole branches. Transplantation by means of flagellated swarm spores which are actively motile.

2. *Crenothrix.*—Cells united in unbranched threads, which in the beginning divide transversely only. Later the cells divide in all three directions of space. The products of final division become spherical and serve as reproductive elements.

3. *Pharagmidiothrix.*—Cells at first united into unbranched threads. Division in all three directions of space. Late in development, by the growth of certain cells through the delicate, closely approximated sheath, branched forms are produced.

4. *Thiothrix.*—Unbranched cells inclosed in a delicate sheath. Non-motile. Division in one direction of space. Cells contain sulphur grains.

VI. **Family Beggiatoaceæ.**—Cells united to form threads, which are not surrounded by an inclosing sheath. The septa are scarcely visible. Division transversely only. Motility accomplished through an undulating membrane.

Beggiatoa.—Cells contain sulphur grains.

Fig. 16

a *b* *c* *d*

a, Bacillus subtilis with spores; *b*, Bacillus anthracis with spores; *c*, clostridium with spores; *d*, bacillus of tetanus with end spores.

If in division the micrococci agglomerate like a bunch of grapes, without a definite arrangement in pairs, etc., they are called often staphylococci (*staphle,* a grape). During reproduction bacteria may excrete a material which unites them into a gelatinous mass called zoöglea. Some, as the pneumococcus, form a gelatinous capsule about themselves, the office of which is not known.

Fig. 17



a *b*

a, spirillum of Asiatic cholera (comma bacillus); *b*, involution forms of this organism as seen in old cultures. (Abbott.)

The bacilli in the course of reproduction may form long threads, showing, as a rule, the traces of segmentation. Under certain unfavorable conditions of development a bacillus forms a glistening oval body within itself (endospore) which resists stains. The body of the bacillus may attenuate into a capsule for the spore. When the spore germinates this bursts open and the new bacillus escapes. These spores are very resistant to devitalizing agents. The bacilli-forming spores are said to be in the resting stage. These spores under favorable conditions again form bacilli like their progenitors, but do not form other spores without this return to the bacillus form. A single cell forms, as a rule, but one spore.

If the entire bacterium is changed into the spore form they are called arthrospores; when cocci take on the appearance of spores

they are also called arthrospores. Under unfavorable conditions bacteria may undergo degeneration and take on abnormal or involution forms, and when the conditions are again favorable to development they may resume their typical forms.[1] While these form changes occur, bacteria are never permanently changed from one form to another.[2] Those bacteria which have several forms in their life cycle are termed pleomorphic. Those having but one form are monomorphic. Ptomains are products of decomposition of the medium and some are poisonous if taken in as food. Those bacteria which exist on living tissue are known as parasitic. They enter the body by way of open wounds or surfaces deprived of epithelium, or may lodge at certain points of the mucous surface of the lungs, skin openings, or the alimentary canal. If not killed out they multiply in the natural juices of the part on which they locate and produce an infective inflammation. Poisonous substances may be generated, which are absorbed into the system and may act as poisons, producing toxemia. When the toxin is soluble, diffuses from the bacteria and floats in the blood it is called extracellular toxin or exotoxin; when confined to the bacteria and liberated upon dissolution of the bacteria, it is called endotoxin; when the free toxin gives the reaction for albumin it is called a toxalbumin.

The character of both the inflammation and the poisoning depends upon the particular bacterium or bacteria present. The bacteria may in certain cases be taken into the blood, and, coming to rest at certain spots, the above-described process is repeated.

The Bacillus anthracis divides in the blood stream,[3] and other organisms, such as the Bacterium pneumoniæ and Bacillus influenzæ and the pyogenic organisms may exist in it. They may thus localize in a spot and produce effects. This has some significance in the production of blind apical abscesses and pericemental abscess (dental) and in the reverse general infection from dental sources. Many forms of organisms exhibit a preference for certain spots at which they find the conditions best suited to development—*e. g.*, the typhoid bacillus in the glands of the ileum, Peyer's patches; the anthrax bacillus in the lungs of animals; the diphtheria bacillus in the mucous surfaces of the pharynx and contiguous parts. Bacteria may enter the blood via the mucosa of the alimentary canal, but this is ordinarily highly resistant. Those parasitic bacteria which produce disease are called pathogenic, others are non-pathogenic.

[1] Abbott, Principles of Bacteriology.

[2] The subject of transmutation when certain bacteria (as Streptococcus viridans) are gradually changed from anaërobic to aërobic conditions is now under study.

[3] Green, Pathology and Morbid Anatomy.

The mouth offers a suitable habitat for many bacteria.

The bacteria which live on dead organic matter are called saprophytic (*sapros*, rotten, and *phuton*, a plant). They break up the dead animal and vegetable matter into simple compounds like carbon dioxid, ammonia, etc., which are utilized by the higher chlorophyllous plants. The nitrogen of the air is also utilized by some plant bacteria, and can be introduced to aid crops. As animals are dependent upon plants for existence, their vast importance in the economy of nature is evident. Bacteria may often pass from a parasitic existence to a saprophytic one—a fact which is utilized in their study by bacteriologists, who prepare artificial media in which to cultivate them. These are called cultures, which by transference from one culture plate to another of like kind are said to be passed through generations. When by careful segregation one form of bacterium is separated from others present in a mixed culture and thereafter cultivated alone, it is called a pure culture; when the bacteria are thinly spread on a gelatin or agar culture and then isolated, the grouped bacteria developing at each point are called a colony. Bacteria may pass from a saprophytic to the parasitic form of existence. Bacteria which have this power of adaptation to a new form of medium are called facultative. When without this power, they are obligate bacteria.

According to Pasteur, those which develop in the presence of free oxygen as in the air are called aërobic. Those which cannot live in its presence are anaërobic. These derive the necessary oxygen from the medium. Those which live either way are facultative. Those compelled to either mode of existence are obligate.

When bacteria produce pigment either within themselves or their medium, they are termed chromogenic; when they produce light or phosphorescence, they are termed photogenic. If they have the ability to produce fermentation, they are termed zymogenic; when they produce gas they are called aërogenic.

FERMENTATION.

Fermentation in the broadest acceptation of the term has been defined as the decomposition of substances possessing complex molecules under the influence of organized (living) or unorganized ferments (enzymes). The decompositions occur when organic substances are exposed to the action of fungi or their enzymes, or are subjected to the action of certain ferments such as are found in the digestive fluids secreted into the elimentary canal, which are really enzymes also derived from living cells.

According to Woodhead,[1] the molecules of the fermented compound are separated from one another for a brief period and then allowed to combine and form simpler and more stable compounds. The process is accompanied by heat due to chemical changes.

Ferments, then, are of two kinds: (1) organized or formed ferments or living fungi which multiply at the expense of the substance which they are fermenting; (2) unorganized or unformed ferments or enzymes, nitrogenous bodies produced by living cells which have the power of producing chemical changes in organic substances. They thus affect many times their own weight of the particular organic substance being fermented without being themselves much affected, though eventually exhausted (catalysis). Typical examples are the pepsin of the gastric juice, which changes albumin to peptone, and the ferment of the yeast plant, proved capable of changing sugar into alcohol and carbon dioxid, even when the cells themselves are crushed and filtered out.

The unorganized ferments usually act by oxidizing, deoxidizing, or hydrating the substance modified. They act best when their products are removed from the neighborhood.

Many bacteria have been shown to possess such unorganized ferments. It is probable that they produce their effects on organic substances by the aid of these ferments, which serve them as pepsin serves man (extracellular ferments). It is thought that in other cases the germs take up organic food, digest it, and excrete waste products in somewhat the same manner that the body cells nourish themselves by intracellular ferments (p. 23). As a rule, more than one species of bacterium infects a fermentable substance. The more active varieties predominate in the fermentation, but mixed fermentations may proceed. In some cases the bacterial multiplication is favored by the activity of other bacteria (symbiosis), in some cases the development is retarded. Some may die out, finding an unfavorable soil. After a time the predominating bacteria may die in the waste products accumulated about them, leaving the field clear for a second or third variety. In this way progressive decompositions may occur—*e. g.*, the alcoholic fermentation may be succeeded by the acetic, in which the alcohol is changed to acetic acid, as in cider-vinegar formation. The nature of the chemical changes produced in a fermentable substance depends upon the chemical nature of the medium and upon the nature of the fungus causing the fermentation.

Thus, in an infusion of vegetable juices containing sugar a yeast

[1] Bacteria and their Products.

fungus (one of the blastomycetes) will produce carbon dioxid gas and alcohol if the oxygen of the air be freely admitted (aërobiosis), while if to a fresh portion of the same solution scrapings from carious dentin be added, lactic acid will be formed, and, as a rule, no gas. Moreover, the reaction will occur if oxygen be excluded (anaërobiosis). In albuminous compounds an alkaline reaction and entirely different substances will be formed upon the addition of carious dentin. Probably upon this fact depend the different effects of bacterial plaques upon the teeth. (See Caries and Pyorrhea.)

The ferments or enzymes produced by bacteria are quite numerous.

Proteolytic ferments dissolve albuminous substances; proceed under an alkaline reaction and sometimes under an acid reaction.

Diastatic ferments change starch into sugar. (See Dental Caries.)

Inverting enzymes convert saccharose into dextrose or non-fermentable forms of sugar to fermentable ones. (See Dental Caries.)

Coagulating ferments coagulate milk. Coagulation is also produced in the tissues and exudate in inflammation by the ferments of pyogenic micrococci.

Sugar-splitting ferments change sugar into other products, as alcohol, carbon dioxid, and lactic acid.

Fat-splitting ferments split fats into glycerin and fatty acids.

Hydrolytic ferments cause a combination with the elements of water in substances they decompose.

Emulsifying, oxidizing, and nitrifying ferments also occur.

Toxins are also classed with the ferments, and are capable of producing new substances when distributed in the blood. (See Immunity.)

Putrefaction.—The progressive decomposition of albuminous matter into simple compounds is effected by many bacteria through processes of oxidation, deoxidation, and hydration.

Peptones[1] are first formed, next alkaloid-like bodies called ptomains (putrefactive alkaloids); succeeding this such nitrogenous bases as leucin, tyrosin, and the amins (methyl, ethyl, and propylamin) are formed; next fatty acids and such acids as butyric, lactic, and succinic acid appear; next aromatic products such as indol, phenol, and cresol are formed, and the final decomposition is represented in the end products—carbon dioxid, CO_2; hydrogen sulphid, H_2S; ammonia, NH_3; and water, H_2O. When bacteria produce decomposition of living animal tissue they effect this putrefaction as distinctly noted in certain cases of abscess.

[1] Ziegler, General Pathology.

Such products of bacterial action, either produced in a living or a saprophytic medium, as are capable of acting as poisons in the animal organism are called toxins. Some animal parasites also produce them. It is understood that they differ according to the fungus and the medium. If the toxin be proteid in nature, it is termed a toxalbumin.

Some of the ptomains are toxic; the greater number are not. The poisoning due to the eating of putrefactive meats, fish, etc., containing them is known as "ptomain poisoning."[1]

Fig. 18



Staphylococcus pyogenes aureus (micrococcus). From a culture. × 1000. (Green.)

Fig. 19

Streptococcus pyogenes. From pus found in a pyemic abscess. × 1000. (Green.)

When the toxins alone are absorbed from a focus of infection the subject is poisoned—a condition called toxemia, whether due to a toxic ptomain, as in the case of Asiatic cholera, or to a toxalbumin, as in the case of diphtheria. Such toxemia is commonly accompanied by more or less fever, according to the amount taken up. When the organisms enter the circulation and multiply in the blood, or at least move about and live in it, to be carried to capillaries in which they can rest and multiply, the condition is termed a septicemia.[2] In toxemia and septicemia the symptoms depend upon the nature of the organisms and their products. (See page 148.) Bacteria are found everywhere and exist upon the surface of the body, in its external cavities, and in the alimentary canal. Here under conditions of health there seem to be conditions favoring certain forms, which, when implanted, occupy the field and exclude, except temporarily, other

[1] For a table of origins, formulæ, and toxicity of ptomains, see Gould's Medical Dictionary.

[2] Abbott, Principles of Bacteriology.

forms to which the soil is not so well suited. These are known as the "normal flora." It has been shown, however, that the growth of some bacteria is favored by the presence of certain others (symbiosis). This is said to be characteristic of Vincent's angina, in which the fusiform bacillus is symbiotic with a spirochetal form.

After certain changes occur in the medium, other forms may become implanted. Pathogenic bacteria may exist in the healthy cavities and produce no ill results. Again, the soil may favor and disease begins. Certain bacteria have been found constantly present in relation with certain diseases—*e. g.*, the spirillum of Asiatic cholera with that disease, the Treponema pallidum with syphilis; these are specific bacteria. Taken from individuals with the disease, they produce it in susceptible animals inoculated with them if circumstances favor their growth.

FIG. 20

Mouse's lung; vessels plugged with Bacilli anthracis: *a*, alveolus; *v*, vein full of bacilli: *c*, capillaries also full; *br*, bronchus. × 400. (Horsley.)

Bacteria spread in the tissues along the lines of least resistance. They may follow the cellular tissue or enter the lymphatics, or pass at once into the veins and be carried into the circulation. They may be strictly localized at the point of infection.

Thus there may be a localized inflammation—*e. g.*, in simple abscess due to the Staphylococcus pyogenes aureus; a diffuse inflammation, as in case of infection by the Streptococcus pyogenes; a gland infection or a septicemia, as in anthrax or in a general infection by Streptococcus pyogenes or Bacterium pneumoniæ; or a metastatic inflammation, as in pyemia, in which the germs (usually Streptococcus pyogenes) gain access to the blood from a local focus of infec-

tion and are carried to distant parts, in which they cause abscesses while the products produce toxemia. To produce effect, germs in the blood must come to rest at some point, which may occur in the capillaries owing to their injury, in thrombi or emboli, or, in case of entrance of bacteria into a leukocyte, they may migrate into the connective tissue (Fig. 20).

It has been shown that pyogenic germs may exist in the blood without local effects, while again a local injury may cause the arrest of the germs and a secondary local inflammation or abscess be set up. This is due to simple arrest or to extravasation of blood, which permits the germs to pass from the vessels into the connective tissue.

General or local depression of tissue vitality acts as a predisponent to local infection.

The infections themselves are classified as primary, secondary, and mixed.

The primary is the original infection, say, *e. g.*, Bacillus tuberculosis. The secondary is that implanted when the original disease is well under way—*e. g.*, Streptococcus pyogenes aureus upon tuberculosis; a third or tertiary infection is possible.[1]

The original infection may be by mixed germs, more than one of which may multiply. Thus, the Streptococcus pyogenes aureus and Bacterium pneumoniæ may both be found in an abscess. This is a mixed infection.

BACTERIA OF THE MOUTH.

In even the best-cared-for mouths bacteria are numerous and find the conditions suited to their growth. In unclean mouths containing food debris, dead epithelium, etc., their life conditions are much more favorable.

According to Miller[2] there are a number of bacteria which invariably occur in every mouth. These are:

1. Leptothrix innominata.
2. Bacillus buccalis maximus.
3. Leptothrix buccalis maxima.
4. Jodococcus vaginatus.
5. Spirillum sputigenum.
6. Spirochete dentium (denticola).

To this list Goadby[3] has added:

Leptothrix racemosa of Vicentini, further described by Williams.[4]

[1] Park, Surgery by American Authors.
[2] Microörganisms of the Human Mouth.
[3] Mycology of the Mouth, 1903.
[4] Dental Cosmos, 1899. See Dental Caries.

Streptothrix buccalis.

Streptococcus brevis of Lingelsheim and Cladothrix buccalis (provisionally added.)

With the exception of Streptococcus brevis and perhaps Cladothrix and Bacillus buccalis maximus, these have been until recently uncultivable on laboratory media, and are strictly obligate parasites. Of the last-named organism, Goadby obtained biological characteristics of the pure culture, but he did not establish its disease-producing power, if it possesses any. Noguchi,[1] working in the Rockefeller laboratories, has cultivated several forms of oral treponemata (so-called spirocheta) by the use of ascitic fluid and fresh sterile tissue in the medium. (See Pyorrhea Alveolaris).

FIG. 21

Diplococci pneumoniæ entangled in the meshes of the fibrinous exudation. From a section of lung in the "red hepatization" stage of acute pneumonia. In the upper part of the field is a cell containing several cocci—possibly a phagocyte. × 1000. (Green.)

Certain pathogenic organisms have been shown to be present in the mouths of healthy persons, such as bacteriological investigators; those nursing infectious diseases, such as diphtheria, scarlet fever, etc., and even in the mouths of healthy individuals apparently not exposed to any infection. In about 10 per cent. of all individuals examined at random, Netter found Staphylococcus pyogenes aureus (golden pus). Staphylococcus pyogenes albus was also found. The Pneumococcus, or Bacterium pneumoniæ, was found in the mouths of about 15 per cent. of healthy individuals. This organism has been found by Kirk to be apparently causative of pericemental abscess, and has been reported by Schreier[2] as found in 75 per cent. of cases of apical abscess examined. It has also been related with cases of osteomyelitis and Ludwig's angina. The Bacillus diphtheriæ of Löffler has been found in about 10 per cent. of mouths examined at random, and 33 per cent. of 600 children in a school examined during an epidemic of diphtheria were found to have the bacillus present in the mouth, while but about 2 per cent. developed the disease.[3] This latter fact shows the absolute necessity for at least a local predisposition as well as an exciting cause.

[1] Journal of Experimental Medicine, vol. xv.

[2] Dental Cosmos, 1893.

[3] Goadby.

The Bacillus tuberculosis exists in the mouths of many suffering from pulmonary tuberculosis, and exists also at times in the mouths of the healthy. The Saccharomyces albicans may be present and at times produce thrush (Fig. 9).

FIG. 22

Bacillus diphtheriæ: *A*, its morphology on glycerin-agar-agar; *B*, its morphology on Löffler's blood serum; *C*, its morphology on acid blood-serum mixture. (Abbott.)

The Bacillus typhosus (typhoid) has been found in the healthy mouth, and at times has oral pathogenicity. Many other organisms have been isolated from the human mouth. Some of these have a specific character, of others little is known. The mouths of professional nurses have been shown to contain bacteria, which increased the danger of infection of their patients, and that the sanitation of their mouths reduced the danger. Some of the bacteria of the mouth possess the power, under certain conditions, of felting themselves in plaques upon the surfaces of the teeth. Here, if properly supplied with carbohydrate food, some of them produce lactic acid and decalcify the teeth. Some bacteria have a later putrefactive action upon the organic matrix of the dentin. Some of the masses may develop an alkaline reaction due to putrefaction. Goadby[1] gives an interesting classification of bacteria found in dental caries (which see). Some bacteria not yet isolated are the probable causes of pyorrhea alveolaris. (See chapter on Pyorrhea Alveolaris). M. T.

[1] Mycology of the Mouth.

Barrett[1] has discovered an ameba constantly associated with pyorrhea alveolaris. (See Pyorrhea Alveolaris.)

The bacteria in the mouth probably are taken into the food and swallowed in great numbers. Many are doubtless killed by the gastric juice, which is a weak germicide; notwithstanding, some pyogenic cocci and some of the blastomycetes may develop in the stomach and produce disease. Many also may enter the intestines and either excite disease of specific character or produce abnormal intestinal fermentations, the toxins of which may be absorbed, and produce malnutritional conditions. They may remain localized in the mouth and produce oral disease, dental caries, or pericemental diseases, etc.; abscesses, pyorrheas, etc., are unquestionably the causes in many instances of fever, septic infection, intestinal disturbances, endocarditis, pulmonary tuberculosis, glandular enlargements, joint inflammations of rheumatic character, skin eruptions, etc. The relation of an unclean mouth to effects upon the mouth, alimentary canal and air passages and blood and lymph channels, is, therefore, a direct one of an importance that renders exact studies in this direction of extreme value. The saliva, while not germicidal (Miller), may or may not contain substances acting as pabulum for the growth of bacteria, but probably does in many cases apart from extraneous food materials introduced. It has been considered by Hugenschmidt that the saliva is positively chemotactic, attracting many leukocytes to the oral mucous membrane; also the great vascularity of the part probably aids in reducing effective inoculation.

FIG. 23

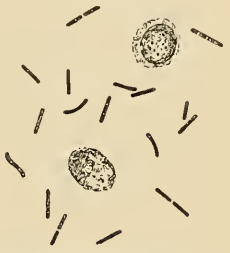

Bacillus tuberculosis. × 1000. (Green.)

THE RESISTANCE OF THE TISSUES TO INFECTION.

The resistance of the tissues to bacteria is to be considered from two main standpoints: (1) The prevention of the entrance of bacteria into the tissues. (2) The destruction of the bacteria after entrance into the tissues.

1. The prevention of entrance. It has been shown that pathogenic bacteria may enter the mouth, alimentary canal, lungs, etc., but few develop.

The skin acts as a mechanical barrier, though its openings may at times harbor bacteria.

The mucous membrane secretes mucus, which envelops bacteria

[1] Paper read before the Pennsylvania State Dental Society and the National Dental Association, 1914. (See Dental Cosmos, August, 1913.)

and with it they are carried away. The healthy mucus also has apparently a devitalizing power for some bacteria, not for others.

FIG. 24



1, a spore which has penetrated the intestinal wall and entered the abdomina cavity, where four leukocytes have surrounded its end: *m*, the muscular layer of the intestine; *e*, epithelial layer; *s*, the serous layer. 2, a spore surrounded by leukocytes from the abdominal cavity of a Daphne. (Metchnikoff.)

The acid gastric juice kills many, but some may pass through, two or three hours after a meal, at times when the gastric juice is not active. Probably the intestinal juices also inhibit, in large degree, the action of such as have entered the alimentary canal. In all cases the agitation of the fluids of a part seems to act mechanically to prevent localization of bacteria.

FIG. 25

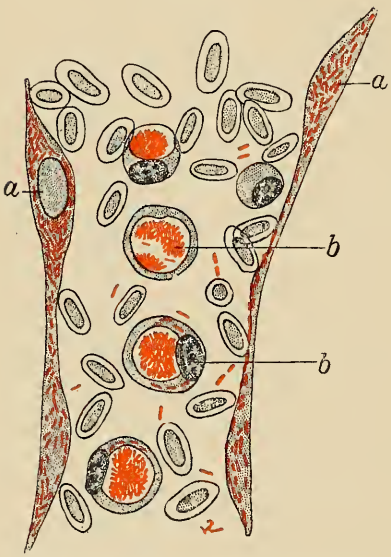

Active phagocytosis. Endothelial cells enclosing the bacilli of swine septicemia, from an hepatic vein of a pigeon: *a*, *a*, indothelial cells; *b*, *b*, leukocytes. (Metchnikoff.)

2. The prevention of development in the tissues. Within the healthy tissues bacteria find several elements opposing their development.

It seems the consensus of opinion among pathologists that the blood serum normally contains germicidal substances probably of the nature of a nuclein and called by Buchner "alexins."

This belief is mainly based upon the demonstration of Nuttall that filtered blood serum possesses the power of producing the degeneration of bacteria. Buchner found that heating to 55° C. destroyed this property, a fact pointing to the albuminous nature of the alexins. After reviewing all the evidence, Vaughan and Novy[1] conclude:

[1] Cellular Toxins.

"(1) the exact nature of the germicidal constituents of the blood or alexins is not known; (2) the alexins have their origin in the white blood corpuscles; (3) disintegration of the white blood corpuscles liberates alexins; (4) it is probably true that alexins are also secreted by living leukocytes." Authorities disagree, some claiming multiplicity of alexins, others that only one alexin exists in a given serum (Metchnikoff).

Metchnikoff, in 1884, demonstrated that the leukocytes take up bacteria within themselves and claimed that they thus destroy them. This process he termed phagocytosis (*phago*, I eat; *cytos*, a bud). The polymorphonuclear leukocytes, called microphages by Metchnikoff, and the large mononuclear leukocytes, which he called macrophages, have this power. The macrophages take up dead leukocytes. It is now considered that this property, which is also possessed by the endothelial cells of the bloodvessels and serous cavities, is but evidence of the nutritive function of simple cells occurring after the bacteria have been partially degenerated by the serum (Fig. 25). This is borne out by experiments: Mixed pyogenic cocci and leukocytes free from blood serum exhibiting no phagocytic activity, whereas when the bacteria are first exposed to blood serum and then to phagocytes, there is marked phagocytosis. (See Opsonins.) In some cases bacterial disintegration may liberate the intracellular toxins and thus permit the toxic effects upon the host. This is said to be true in case of administration of typhoid vaccines during the course of the actual disease.

Researches of Leber, Buchner, and others have shown that leukocytes may be attracted by certain bacterial products even in high dilution, and by other chemical substances such as mercury and copper salts. This is called positive chemotaxis. The opposite is negative chemotaxis. It has been shown that the negative may be followed by marked positive chemotaxis.

Toxins are negatively chemotactic, and when bacteria produce much toxin phagocytosis and suppuration are lessened,[1] *e. g.*, in streptococcus infection. Many other bacterial products and bacterial proteins are positively chemotactic, and when they are produced in place of much toxin phagocytosis is increased, and the bacteria, if few, are coincidently destroyed by the alexins and taken up by the phagocytes with resolution, or, if the bacteria be numerous, suppuration is increased and the bacteria expelled as a protection to the body. It has been shown, however, that the taking up of living bacteria may occur and may spread an infection. Also it has

[1] Stengel, A Text-book of Pathology.

been shown that the microphages take up some bacteria and the macrophages take up others.

If the combined local forces be incompetent to kill out the infecting organisms, the local infection spreads until limited or the patient dies; or a metastasis may occur, in which case the process is practically repeated in another locality.

IMMUNITY.

Immunity is the opposite of predisposition, or susceptibility, and may be defined as that condition of the local fluids, the blood, or the body cells, in which inoculation with bacteria or bacterial products has no injurious effects.

There is also some relative immunity to non-infectious diseases, *e. g.*, females to hemorrhagic diathesis. (See Predisposition p. 30.) Immunity to infective agencies may be natural or acquired.

Natural Immunity.—This is due to a healthy action of the phagocyte of the body or to some peculiar substance in the blood; the antibody of the particular bacterium, or fungus or toxin which it is thought may be inherited from ancestors.

Typical examples of this kind of immunity are those of the rat to dphtheria; man to rinderpest; lower animals to syphilis; the negro to yellow fever (though he is susceptible to smallpox); the hog to snake venom, etc.

Natural immunity may change to susceptibility through some change in the systemic condition. Thus, two students attending a scarlet-fever ward for months became susceptible through the effects of a long walk and hunger; both took the fever, one dying.[1]

Rats, run in a wheel until exhausted, were successfully inoculated with anthrax bacilli, to which they are normally insusceptible. These states of tissue fatigue are noted in the overstrain of athletes, who often suffer from furuncle. According to Gildersleeve[2] examination shows that the opsonic index is greatly lowered by the overstrain. Metchnikoff considers immunity due to an enzyme derived from the leukocytes called microcytase, which either acts within the leukocytes or outside of them to produce deterioration of the bacteria (cytolysis), and that it may require other factors to act with it as amboceptor or complement.

Natural immunity may therefore fail upon severe test, and survival of the test is the only certain assurance. This natural immunity may be of two kinds:

[1] Green, Pathology and Morbid Anatomy. [2] Lecture.

1. Natural toxin immunity, *e. g.*, hog to snake venom.
2. Natural bacterial immunity, *e. g.*, negro to yellow fever.

Acquired Immunity.—This is of two kinds:

1. Acquired toxin immunity.
2. Acquired bacterial immunity.

Acquired Toxin Immunity.—Toxin immunity may be acquired in two ways:

1. By the injection of small doses of toxins at intervals until no reaction results. The horse is so immunized in diphtheria antitoxin production. The antitoxin is produced by the cells of the horse.

2. By the injection into man or animals of serum containing antitoxin produced by method No. 1. The former is an active immunity; the latter passive.

Acquired Bacterial Immunity.—Immunity to bacterial inoculation may be acquired in several ways:

1. Naturally, through having had an attack of the particular specific disease; thus, as a rule, measles, smallpox, syphilis, yellow fever, and many other infectious diseases cause the body cells to produce substances antagonistic to the bacteria known as antibodies which are said to be in part the cause of immunity. Phagocytosis is increased against subsequent infections which remain in the blood and render the individual immune to a second attack, though in some cases this immunity is lost.

2. Artificially, through the injection into the body of attenuated bacteria, cultivated through several generations under unfavorable conditions; for example, at increased temperatures or in the presence of weak antiseptics or by passing them through other animals, whereby their virulence is lost; a mild immunizing attack ensues. Thus in rabies, or, rather, for prevention of rabies, after the bite of an animal suffering from it, accurately graduated doses of emulsions of the spinal cord of infected rabbits, dried for varying periods to produce accurately degenerated rabies germs, are injected into man, preventing the development of the germs introduced by the bite. The emulsion of older cords are injected first, then those of younger cords (dried for a shorter time). The use of cowpox vaccine against smallpox is of this nature.

3. Artificially, by the injection of dead bacteria from a pure culture of the specific bacterium from which immunity is sought. (Wright's vaccine.) What is known as the opsonic index is raised, and the person becomes more resistant to that particular infection; that is to say, phagocytosis is increased. (See Opsonins.)

4. Artificially, by the injection of graduated doses of toxins, produced in a saprophytic medium by the specific bacterium, all bacteria

being filtered out. This is most readily done when the toxins produced lie in the medium external to the bacteria (extracellular toxins). The horse is so treated in the production of diphtheria antitoxin for use in the diphtheria of man.

5. Artificially, by the injection of the serum of animals immunized by method No. 4, which serum contains a substance antagonistic to the specific toxin and known as an antitoxin. Thus the injection of horse serum containing antitoxin of diphtheria produced by method No. 4 into a diphtheric patient aborts the disease by antagonizing its toxin while the phagocytes kill out the bacteria. Injection into the attending nurse produces immunity to the disease, but antitoxin does not act upon the bacteria but upon the toxin. The immunity then is probably due to phagocytosis and an amboceptor which aids it.

FIG. 26

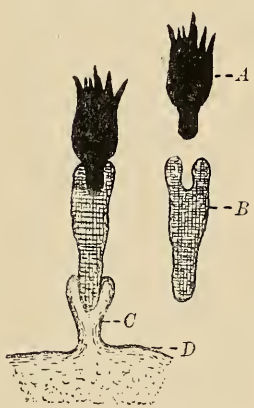

A, complement; *B*, amboceptor; *C*, receptor; *D*, part of cell. Showing how complement destroys bacteria through the agency of amboceptors.

FIG. 27

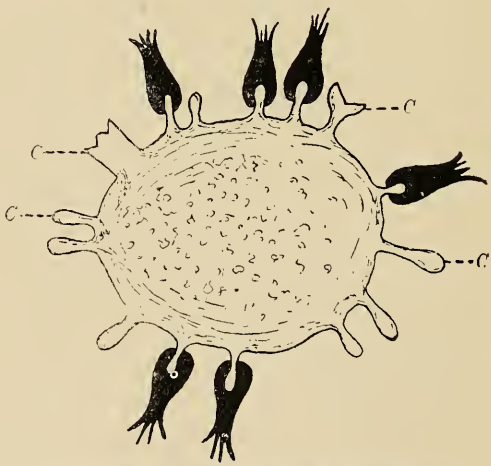

Cell with different kinds of receptors: *C*, receptors. The dark objects represent food molecules, toxins, etc.

The methods 1, 2, 3, and 4 produce a much more lasting immunity, as the antagonizing substance is the result of cell reaction on the part of the individual, and is called active immunity; that produced by method No. 5 is passive immunity, because not produced by cell reaction, but directly introduced into the blood, and is much less lasting. It is not effective for all bacteria.

The various forms of acquired immunity are explainable by the now generally accepted theory of Ehrlich known as the side-chain theory.

Ehrlich's Side-chain Theory.—This theory is based upon certain demonstrated facts and upon the supposition that each cell is composed of aggregations or groups of atoms and surrounded by side groups of atoms (molecules), which compose the cell protoplasm. Each atom group is supposed to have its own chemical affinity for food elements, poisons, etc., as shown by the selective affinity of drugs.

These chemical atom groups, therefore, have a receptive function and are called *receptors on the cell.* Other groups have a fermentative action and chemically change the substances presented; these are called *zymophorous* atom groups.

Each toxin molecule has an affinity for some cell receptors, otherwise no effect is produced by it. (Snake venom has no effect upon the hog.)

The receptor is considered to possess a group of atoms suited to a prehending action, whereby it combines with the toxin molecule (or food molecule in nutrition), which possesses a similar combining group of atoms. In each these are termed the *haptophorous* group. The toxin molecule is capable of inflicting injury upon or stimulating cell action, as shown in the case of tetanus, in which tonic muscular contractions are excited. The group of atoms in the toxin molecule which accomplishes this is termed the *toxophorous* group (Fig. 27).

That the body cells neutralize the toxin if not in overwhelming quantity is shown by the experiment of Wassermann and Takaki, in which a mixture of brain emulsion and tetanus toxin was inert when injected into a susceptible animal. Therefore, a zymophorous group of atoms is said to exist in the cell or its receptor.

The Theory of Toxin Immunity.—The toxin produced during an infective disease, such as diphtheria, and floating in the blood, presents itself to cells for some receptors of which it has an affinity. The haptophorous atom group of its molecules joins with the haptophorous atom group of the receptor. The toxophorous atom of the toxin group exerts its action upon the receptor and is neutralized by the zymophorous group of the latter unless the toxin is in too great quantity. The cell, in case of injury, repairs itself by forming an excess of the particular kind of receptors having affinity for the particular toxin. These receptors become detached and float in the blood, and there have the same affinity for the toxin. These are called *receptors in the blood,* and constitute what is known as *antitoxin.* They are known to be formed by the body cells and not by the blood, as they have been found in the tissue juices of blood-making organs immediately after the introduction of toxin, while at the same time

not found in the blood, though they afterward appear, as might be expected (Fig. 28).

The antitoxin receptor (with affinity for the toxin molecule) has an haptophorous atom group which combines with the haptophorous group of the toxin molecule, which, having found its affinity in the blood, is satisfied, does not further affect the cells proper, and thus cell injury is prevented. This occurs naturally in each case of diphtheria, and probably recovery or death is dependent upon the ability of the body cells to furnish (1) antitoxin sufficient to antagonize the toxin and (2) another body to be described which antagonizes the bacteria.

Fig. 28

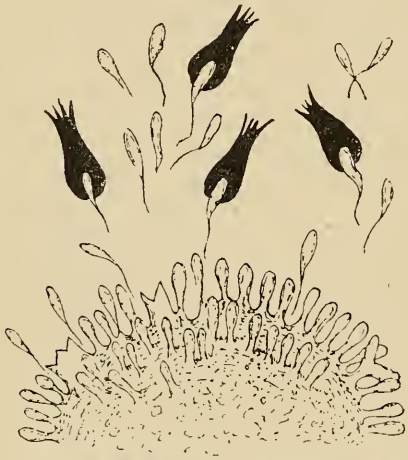

Showing separation of antitoxins, and combinations of toxins (dark) with free antitoxins in the blood.

Fig. 29

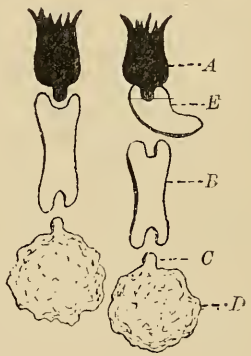

Showing the action of anticomplement: *A*, complement; *B*, intermediary body; *C*, receptor; *D*, cell; *E*, anticomplement.

In the case of diphtheria-serum therapeutics, the horse is compelled by method No. 4 to form these antagonizing substances, and the serum is then injected into the individual suffering an attack or threatened, thus furnishing him ready made the antagonizing substances (antitoxin, etc.). A special antitoxin is supposed to be formed for each kind of toxin. Ehrlich believes an antitoxin molecule to be capable of satisfying 200 toxin molecules, and that they combine chemically. In old sera the toxin undergoes a chemical change into *toxoid,* and the injection of this causes an increase of receptors *on the cell,* and thus renders the animal more susceptible to the action of the toxin. An antitoxin unit is the amount of antitoxin necessary to neutralize an arbitrary amount of a particular toxin.

Toxon is a third body produced by the bacteria which has some affinity for antitoxin, but the combination is still somewhat toxic (has a different toxophorous group of atoms), and in diphtheria is credited with the production of postdiphtheric paralysis. The attempt to make antitoxins has not been successful in most cases.

The Theory of Acquired Bacterial Immunity.—When bacteria enter the tissue of an animal by inoculation and are not destroyed by the alexins and phagocytes, they develop and produce toxins and may themselves enter the blood. A reaction of the body cells occurs, as shown by fever, and not only antitoxin, but a new body is produced by the cells, which, with the aid of still another substance called *complement,* is capable of destroying the particular bacterium causing the infection. This body is *another form of receptor* having two haptophorous groups, by which it links the complement with the receptor of the bacterium, and thus enables the complement to destroy the bacterium through its zymophorous atom group. The doubly haptophorous receptor is called from this fact the *amboceptor* (also intermediary or immune body) (Fig. 26). A different amboceptor is produced for each bacterium and the host is immunized against this bacterium only.

The complement, of which there are several in association in the blood (Ehrlich), is probably produced by the leukocytes, and is classed among the alexins. As stated, it has a zymophorous atom group, and also has an haptophorous atom group with which it joins the amboceptor. The complement is destroyed at 55° C. (is thermolabile). The amboceptor requires a higher heat (is thermostabile).

In natural bacterial immunity it is thought that some of the amboceptors are inherited from immune ancestors, and that they exist together with complement in the blood ready to act. Metchnikoff claims that amboceptor and complement are products of the leukocytes. The elements in blood serum which destroy bacteria are termed *bacteriolysins,* and the new bodies formed by cells as a protection are called *antibodies.*

Agglutination.—When body cells react to infection, and attempt to or effect immunity, the blood plasma may acquire the property of clumping the bacteria together, and they settle to the bottom of a test serum, leaving the fluid clear. It is supposed to be exhibited only toward the bacterium causing the infection, but experimentally out of the body (*in vitro*) others are sometimes affected.

The substance producing agglutination, called agglutinin, evidently exists in blood as the result of cell reaction. It is of the nature of liberated amboceptors, but has a zymophorous group. It

therefore acts by combining by an haptophorous group and acting through a zymophorous group.

The reaction is useful in making an early diagnosis of the kind of existing infection. Thus if typhoid bacillus be suspected as a cause of disease present and be the cause, the blood serum drawn from the patient will agglutinate living typhoid bacilli placed in it. This is known as Widal's reaction.

Precipitins.—A substance of nature and origin similar to agglutinin causes precipitation instead of agglutination. It is used in diagnosis and in differentiating the blood of animals, a matter of importance in murder cases.

Opsonins.—Wright found that when bacteria were mixed with leukocytes in the absence of serum phogocytosis did not occur, but if serum was then introduced it did occur. Also if leukocytes were washed with sodium citrate-chlorid solution to free them from serum, and bacteria that had been previously treated with serum were introduced, phagocytosis occurred. Obviously, then, the serum contains a substance or substances capable of favoring phagocytosis.

It is regarded that this substance prepares the bacteria for the phagocytic process, and from this fact Wright named these substances *opsonins,* which are therefore classed among the alexins. Opsonins have an haptophorous group of atoms prehending the bacteria and a zymophorous group acting upon them. Other observers have determined that opsonins are multiple in normal blood. The degree of activity of the opsonin related to a particular infection when compared with that of a healthy person is called the opsonic index.

The Opsonic Index.—To test the opsonic index, an even emulsion of the bacteria, the serum of the infected patient, the serum from each of several healthy persons, and healthy leukocytes from the healthy persons are necessary.

1. *The Emulsion.*—The pure culture is isolated. A 2 per cent. nutrient agar medium has sterile milk, milk serum, or blood serum added in the proportion of 1 part to 3 of the nutrient agar. In tubes of the selected medium slant cultures are made, and incubated at 37.5° C. for eighteen to twenty-four hours. (Gildersleeve.) These are then washed from the surface of the medium with 0.85 per cent. sodium chlorid solution and the solution placed in a sterile bottle with sterile glass beads or sand and shaken to remove clumps. The number of bacteria in each cubic centimeter is then estimated (standardized) and a dilution made on the basis of this estimated count with 0.85 per cent. sodium chlorid solution, so that when opsonized with normal serum each leukocyte will take up from 5 to 8 of ordinary bacteria. (Gildersleeve.)

2. *The Sera.*—These are obtained from the patient and healthy persons by congesting the finger with a rubber band and bleeding into a capsule or pipette, which is then sealed and the blood allowed to clot in the incubator for 15 to 20 minutes.

The *leukocytes* are obtained by filling with blood a centrifuge tube, three-fourths full of a 1 per cent. solution of sodium citrate in 0.85 per cent. solution of sodium chlorid. After shaking, the tubes are centrifugalized, the fluid drawn from the buffy coat, and the latter then carefully pipetted and drawn in and out to mix thoroughly.

The preparations being ready, equal volumes of bacterial emulsion, the serum to be tested, and leukocytes are drawn into a marked pipette, each volume being separated by a bubble of air. These are then mixed by drawing in and out, and the end of the pipette is sealed and the pipette placed in an opsonizer for fifteen or twenty minutes. The pipette end is then broken, and the contents spread evenly on several glass slides by means of another slide. (Gildersleeve.)

These are then air dried and stained. The bacteria in a given number of leukocytes are counted and the total divided by the number of leukocytes counted, thus obtaining the average of bacterial ingestion per leukocyte. This gives the *phagocyting* index for the infected individual.

The same procedure exactly is carried out with the normal sera, and the average phagocyting index determined. The index is calculated by dividing the patient's phagocyting index by the normal phagocyting index, or the same thing may be done by the following proportion:

Normal index : patient's index :: 1 : x.

If x is above 1, the patient's index is high.

If x is below 1, the patient's index is low or subnormal.

Vaccine Therapy.—Wright found that when a large number of the bacteria causing the infection were killed and then injected into the patient, their bodies contained substances which produced a cell reaction resulting in an increase of opsonin and phagocyting power in the leukocyte of the individual—this determined by the opsonic index.

For a time—twenty-four or forty-eight hours—the index became lower. This Wright called the *negative phase;* afterward it gradually rose to a maximum. This stage he termed the *positive phase.* The object sought, then, is to increase the resistive power of the patient to the infection through an increase in the phagocytosis.

The Vaccine.—This is prepared by producing an emulsion of the pure culture as for the opsonic index. The emulsion is then standardized by an estimation of the bacteria in each cubic centimeter. The bacteria are then killed by heating the sealed container in a water bath and are then diluted with 0.85 sodium chlorid solution (with 0.2 per cent. of tricresol or phenol added) to the desired strength.

The proper number of bacteria for one maximum dose should be contained in 1 c.c. of the diluted emulsion. To determine the dilution the estimation in 1 c.c. of standardized emulsion is divided by the number desired as a dose, and the quotient less 1 equals the number of c.c. of the diluting solution to be added to 1 c.c. of the emulsion.

The Injection.—The hypodermic syringe is sterilized and filled with the diluted emulsion and an injection made into a convenient site, which should be previously sterilized with 2 per cent. phenol solution, followed by sterile water and absolute alcohol (Gildersleeve). The needle should be inserted into the subcutaneous tissue of the outer side of the arm, or, if preferred, of the leg or thigh, or below the angle of the scapula, whichever would prove most convenient for the purpose.

Gildersleeve[1] recommends smaller doses when the index is low, in general infection, in acute conditions, in children, and in individuals markedly depressed, than in the opposite conditions. He gives the following dosage of the various vaccines employed in treating infections of the oral cavity:

Micrococcus aureus and albus	50,000,000 to 600,000,000
Streptococcus pyogenes	10,000,000 to 100,000,000
Pneumococcus	10,000,000 to 100,000,000
Micrococcus catarrhalis	25,000,000 to 100,000,000
Influenza bacillus	25,000,000 to 100,000,000

The Reaction of the Blood.—According to Michaels[2] (following Gautrelet), individuals in whom the oxidations are below normal, and who have a tendency to arthritic diseases because of an excess of the acid constituents or waste products in the body fluids, are denominated hyperacid individuals. The hyperacid have oxidations above the normal, together with a superabundance of saline chlorids; and these he regards as more subject to infection. There are three ways in which the predisposition of the hypoacid might be accounted for:

[1] American Text-book of Operative Dentistry. This article should be read for a more extended description.

[2] Sialosemiology.

1. The increased amount of alkaline elements may permit an increased alkalinity of the blood, rendering it favorable to bacteria as a culture medium.

2. The systemic change may introduce a substance into the blood which is a suitable pabulum for the bacteria, as, for example, excess of glucose in diabetes (according to Kirk[1] this occurs in the saliva in those susceptible to caries).

3. Certain immunizing substances, opsonins, alexins, etc., may fail to be formed.

Per contra, the hyperacid may be immune for opposite reasons. Whether this be a rational explanation or not, it is certainly shown by Wright that therapy will increase the opsonic index, and it may be that in the hyperacid the continuous cell irritation by the acid elements, as CO_2, uric acid, etc., may cause a tissue reaction increasing alexin or opsonic power.

The foregoing is merely a synopsis of the main facts governing immunity. There are many details which are omitted and for which the reader is referred to works on bacteriology.

EXTERNAL ANTIBACTERIAL INFLUENCES.

Many chemical substances and physical forces prevent the growth and reproduction of bacteria without necessarily killing them; these are called antiseptics; a weak solution of boric acid is an example, agitation is another, dryness another. Low temperatures also prevent fermentation. Other substances or forces kill the bacteria after an exposure to their influence for a sufficient length of time; these are germicides—*e. g.*, a 1 to 1000 solution of mercuric chlorid in water, boiling water, or streaming steam; sunlight for some bacteria. Other substances destroy both the bacteria and their products; these are disinfectants—*e. g.*, sodium dioxid or other substances liberating nascent oxygen. Formaldehyde and iodin are also disinfectant.

[1] Dental Brief, 1907.

CHAPTER IV.

DISTURBANCES OF NUTRITION.

Disorders of nutrition are of three classes: (1) due to an excess of nutritive material of all classes, or of one class; (2) due to a deficiency of nutritive material, active or relative; (3) due to the presence in the blood of material which, instead of serving the purpose of metabolism, disturbs it; (4) an inability of the cells to appropriate a proper quantity and quality of food.

EXCESS OF NUTRITION; HYPERNUTRITION.

An excess of nutrition may be either general or local. If local, it is associated with an overfulness of the bloodvessels (hyperemia). If the individual possess a general richness of blood, he is said to be plethoric. Sthenic plethora is such a richness associated with activity of the circulation and a consequent increase of the vital processes due to plentiful cell nutrition, and with an active repair of even excessive waste of cell protoplasm.

In asthenic plethora, on the contrary, the individual is full-blooded, but the circulation is sluggish; waste products are probably accumulated in the blood and the vital processes are sluggish in consequence. Instead of the rich color and active movements associated with sthenic plethora, the asthenic have a purplish appearance and the movements are more labored.

Local Hypernutrition.—An increased stimulation of the nerves of a part invites more blood to it, which within certain limits increases the nutrition to the cells of the part. This results in increased irritability, contractility, and general functional activity of the functionating cells. If this be maintained, the cells grow or multiply, or both, and the part is enlarged and capable of an increased amount of work.

Stimulation beyond this point causes irritation or overstimulation of cells, and the vital processes become fretful; incomplete chemical changes occur in the cells, and the functional activity is disordered. The cells are wearied, and if the overstimulation be continued paralysis from overwork results.

Hypertrophy.—Though strictly meaning an excess of nutrition, this term signifies an increase in the size of a part as the result of stimulation and destruction, with a compensatory rebuilding of cell material in excess (a cell hyperplasia) (Weigert[1]). The new growth must be practically normal in structure. As a rule, both the size (simple hypertrophy) and the number of the cells (numerical hypertrophy or hyperplasia) are increased. The caliber of the bloodvessels is increased to comply with the stimulus to their controlling nerves—the vasomotors. Hypertrophy is frequently exhibited in tissues subjected to an unusual amount of work short of marked fatigue. An increase in its function occurs; its capacity for work becomes greater, and if the strong stimulus (mild irritation) implied be continued the cells increase in size and it may be in number, all three phases of the expenditures of an increase of vital energy being represented—functional, nutritive, and reproductive. If the heart be subjected to an increase in the strain ordinarily brought upon it, an increase in the volume of the muscular fibers follows, causing hypertrophy of the walls. The same is true of the muscles of the gravid uterus, in which the cells increase to many times their normal length. When one organ, as a kidney, takes up alone the work usually performed by two it increases in size (hypertrophies). This is called compensatory hypertrophy. It may occur in an organ which endeavors to supply the deficient function in another organ of different sort. Hypertrophy also occurs in many inflammatory conditions, and is due to the area of hyperemia surrounding every focus of inflammation. Thus the epithelium about the edges of an ulcer may thicken or new bone may be formed about an area of inflamed bone tissue or periosteum. The bone tissue may become more compact, a condition termed sclerosis of bone, as it results in the formation of formed (intercellular) tissue at the expense of the cellular elements.

The removal of an accustomed resistance often produces an irritation resulting in mild hyperemia, and thickening or hypertrophy results—*e. g.*, non-occlusion of teeth frequently produces hypercementosis.

A form of cellular hypertrophy appears to occur in certain leukocytes, resulting in the formation of a multinucleated cell or "giant cell."

Under irritation the nucleus subdivides, but the cell body fails of division, and instead of complete reproduction a large cell with many nuclei is formed (Fig. 30). These giant cells appear where tissue is

[1] See Abbott's Principles of Bacteriology, p. 601, for an amplification of this idea.

to be removed, as in the case of aseptic foreign bodies or the roots of deciduous or even of permanent teeth. (See Resorption of Temporary Teeth.) An hypertrophy or excessive development may occur during intra-uterine life and is spoken of as congenital hypertrophy. A low grade of inflammation may lead to a numerical hypertrophy, as in the case of hypertrophy of the dental pulp (which see).

Hyperplasia.—Hyperplasia, sometimes called false hypertrophy, is an increase in size partly due to an increase in the number of the cells, though the individual cells may be smaller than normal. It occurs mostly in the connective tissues, though it ordinarily plays a part in most hypertrophies. The part is usually asymmetrical. Examples: elephantiasis and hyperplasia of the dental pulp.

FIG. 30

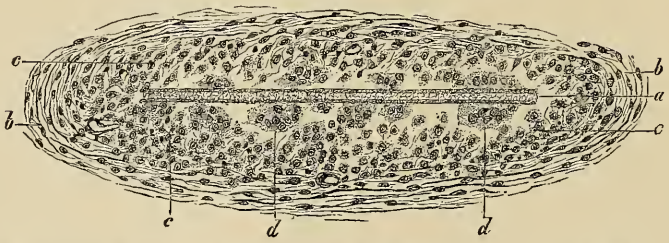

Dog's hair encapsulated in subcutaneous tissue: *a*, hair; *b*, fibrous tissue; *c*, proliferating granulation tissue; *d*, giant cells. Preparation hardened in alcohol, stained with Bismarck brown, and mounted in Canada balsam. × 66. (Ziegler.)

Cyst and Tumor Formation.—A cyst is an enlargement containing a cavity which in turn contains liquid, gelatinous, or pultaceous material, about which is a capsule condensed from the surrounding structures. The accumulation of the fluid or semifluid contents produces the enlargement of the part even if bony (Fig. 31).

They differ from tumors in being strictly localized, though they may be large, and in their generally benign character, though tumors may at times have a cystic character.

Cysts may be formed by the retention, secretion, or extravasation of fluid in several ways: (1) By the retention of normal secretion of a gland owing to the obstruction of its duct—*e. g.*, ranula. These are called retention cysts. (2) By abnormal secretion into ductless cavities—*e. g.*, bursæ (exudation cysts). (3) By the extravasation of blood into a ductless cavity (extravasation cyst). (4) Independently in tissue as a result of mucoid or fatty changes or liquefaction necrosis, the surrounding tissue becoming condensed into a capsule (liquefaction or colliquation cysts). (5) Independently as a collection

of fluid in connective-tissue spaces, which enlarge and fill. The surrounding tissue condenses into a cyst wall. (6) Independently as a result of chronic irritation by foreign bodies, extravasated blood, or parasites, as in dentigerous cysts[1] (Fig. 31). Cysts may have but one cavity (simple cysts) or have numerous intercommunicating cavities known as loculi (compound or multilocular cysts). Forming within bony walls, these may be largely distended, and the walls are usually thin. There is generally a crackling sound produced upon pressure. Dentigerous and other cysts are usually lined by epithelium peculiar to the part. The explanation of Malassez, that epithelial remnants (of the enamel organs) develop, forcing the connective-

FIG. 31

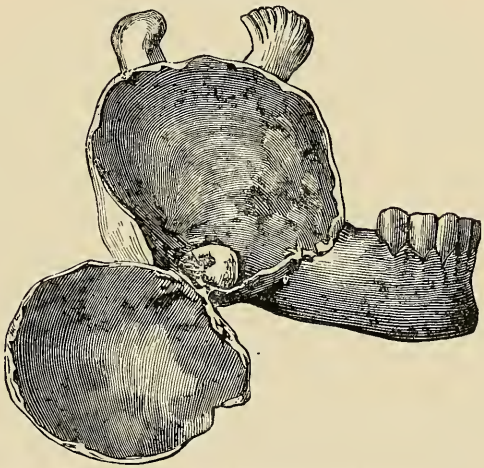

Cyst of the lower jaw, having its origin about an undeveloped tooth. (Garretson.)

tissue elements outward as a covering to them, is probably the correct one. Meanwhile, fatty degeneration of developed epithelium and the collection of fluid account for the fluid or pultaceous character of the cyst contents. This proliferation of epithelial remnants is well proved by the development of epithelial products in the interior of dermoid cysts. (See Fig. 98.)

Dermoid cysts are cystic tumors of widely varying sizes found in various parts, such as the ovary, neck, base of brain, orbit, etc. They contain fatty and epithelial debris, and are lined with epithelium, outside of which is a corium with its papillæ, and outside of this subcutaneous adipose tissue. The whole is inclosed in a fibrous capsule of connective tissue. The epithelial lining may contain

[1] Green.

and develop the characteristically dermoid structures, hair, teeth, sebaceous and sweat glands (Fig. 34).

Broomell[1] states that the hair is often several feet long, usually of a light brown color, regardless of the color on the outside of the body, and becomes white as age whitens the outside hair, and is usually absent in dermoids in bald persons. Hair follicles are present.

He states: "Dermoids of the mouth are usually found in the hard and soft palates, infrequently in the former, but when found are complicated, while the more frequently found in the soft palate

FIG. 32

Longitudinal section of a tooth from an ovarian cyst: *a*, *b*, *d*, tissue filling absorption cavities; *c*, narrow band of connective tissue through which the organ *a* received its nourishment; *d*, absorption of enamel. (Miller.)

are simpler. In these situations they range from the size of a pea to that of a hen's egg, the larger being pendulous. They are also found on the floor of the mouth and dorsum of the tongue. Brown instances a case in which one lay under the jaw and extended down the side of the neck.[2]

"The teeth range in shape from the simple cone to multicusped complex forms, the crowns of the same being well formed. The

[1] Dental Cosmos, 1905.

[2] Ibid., 1908.

roots are usually not fully calcified or developed, or, perhaps, partly developed. A follicular wall is present. The enamel may be smooth or pitted.

"The cementum is usually absent or but slightly developed.

"Radicular odontomes evidenced by tumor-like growths on roots are due to aberration of the dentinal germ. The pulp canal was always present in cases examined. Fusion of teeth has occurred in these cysts. In histology the teeth are similar to ordinary teeth, with some slight aberration due to the peculiar condition."

FIG. 33

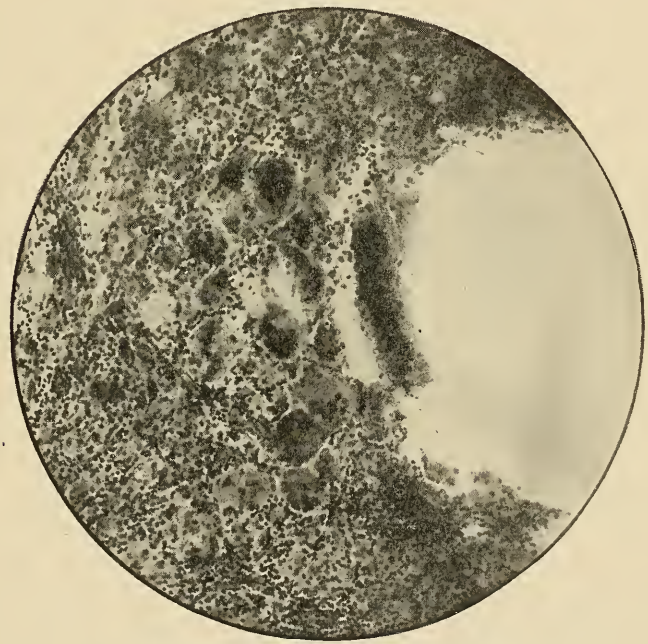

Absorption tissue, from cavity *a* in Fig. 32.

According to Eccles and Hopewell-Smith,[1] the teeth may be found imbedded in alveoli in bone; that a small jaw with normal-sized teeth may exist.

Miller[2] states that the cystic contents include fatty acid, oxalic acid, large quantities of tyrosin and leucin, which substances furnish the acid for the decalcification of teeth occasionally found, but that no bacterial action, such as occurs in the second stage of dental

[1] Proceedings of the Royal Society of Medicine.
[2] Dental Cosmos, 1905.

caries, could be found. He stated that in those teeth having living pulps transparency might be found.

Tumors.—A tumor is a new growth conforming to a degree to the normal histology of a part, but having no physiological function and no typical limit of growth. They are classed as benign or malignant, accordingly as they are strictly localized and comparatively harmless, or tend to sap vitality and to spread dangerously, or to be transferred to other localities (metastasis).

Fig. 34

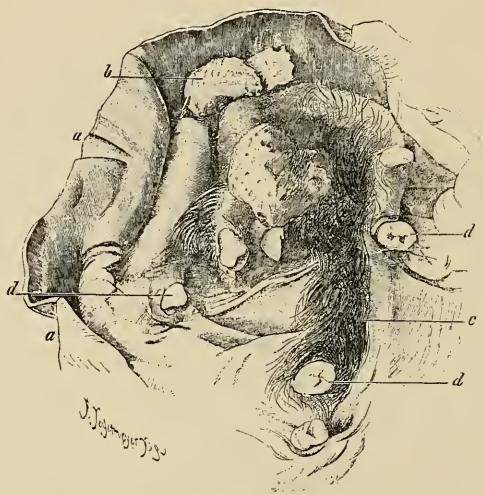

Portion of a wall of an ovarian dermoid cyst: *a*, wall of the cyst; *b*, projecting portion made up of fatty and cutaneous tissue; *c*, hairs; *d*, teeth. (Ziegler.)

The growth of a tumor is attended by a sapping of the vitality of a sufferer—the degree of the debility produced being apparently in direct ratio to the size and the rapidity of the growth. Besides the size and the rapidity of development of individual tumors, another element determines their malignancy, their position, and, furthermore, their occurrence in other parts resulting in multiple tumor formation. A tumor victim acquires a peculiar appearance—a cachexia whose intensity and rapidity of advance are directly dependent upon the degree of malignancy, and the effects produced upon general nutrition by the toxic substances entering the circulation.

Tumors introduce no new form of tissue element; they are reproductions of the cells of the tissues of the body. They may have the same cell formation as the tissue from which they spring, and are

then called homologous tumors; or they may have a different histological structure from the tissue in which they are found, being then called heterologous tumors. For example, a bony tumor growing from bone would be homologous; a cartilaginous tumor growing from gland tissue would be heterologous.

Etiology.—The causes of tumor formation are unknown; it has been believed that their growth is due to parasites, especially the protozoa; this, however, has not been proved. A certain proportion of tumor formations, 7 to 14 per cent.,[1] appear to be caused by traumatic injury; as, for example, in cases of mammary tumor, a history of a blow or fall may be at times obtained.

Long-continued, sluggish inflammation appears to be causative of tumor formation in an unknown percentage of cases. A chronic irritation of certain portions of the body, such as the junction between the mucous and skin surfaces of the lip, the sides of the tongue, etc., is a frequent antecedent to their formation. Ziegler gives a reasonable explanation of the origin of certain epithelial tumors in organs which are undergoing atrophy; for example, in advanced age the connective tissue of the body is undergoing atrophy and there is relaxation of its strata; the epithelium of the surface (or of glands), still possessed of its power of reproduction, proliferates and invades the connective tissue, producing cancer.

Cohnheim advanced the theory that embryonic remnants or "rests" are included in the tissues and in time reassert their proliferative powers.

Tumor formation consists in the reproduction of the cells of one or more tissues, and in the growth thus formed bloodvessels are developed. Tumors do not contain nerves, though they may develop in nervous tissue.

"The bloodvessels of tumors have comparatively fragile and poorly developed walls. In the malignant growths or rapidly developing tumors of any sort the vessels are mere spaces between the tumor cells, with little attempt at the development of firm walls."[2]

About the more slowly developing tumors a condensation of connective tissue occurs in many cases, forming a distinct limiting wall or capsule from which the tumor may be enucleated.

The two great classes of tumors, those of mesoblastic and those of epiblastic and hypoblastic origin, may be subdivided into orders according to their histological peculiarities.

[1] Ziegler.
[2] Stengel, A Text-book of Pathology.

Classification of Tumors.

TUMORS OF THE MESOBLASTIC TISSUES.

Those usually benign:

- Bony tumor, or osteoma.
- Cartilaginous tumor, or chondroma.
- Fibrous tumor, or fibroma.
- Fatty tumor, or lipoma.
- Mucous tumor, or myxoma.
- Tumor of lymphatic vessels, or lymphangioma.
- Tumor of bloodvessels, or hemangioma.
- Tumor of nerve fibers, or neuroma.
- Tumor composed of neuroglia, or glioma.
- Tumor composed of muscle fibers, or myoma.

Those usually malignant:

Tumors of connective tissues with rapid cell proliferation and little intracellular substance:

Sarcomata:
- Spindle-celled sarcoma.
- Round-celled sarcoma.
- Giant-celled sarcoma.
- Angiosarcoma.
- Sarcomatous cylindroma.
- Melanosarcoma.
- Mixed sarcomata, as fibrosarcoma, etc.

TUMORS OF THE EPITHELIAL AND ENDOTHELIAL TISSUES.

Those usually benign:

Papilla of skin or mucous membrane—papillomata.

Tumors of epithelial glands—adenomata.

Those malignant:

"Epithelial growths atypically reproducing certain glandular or other structures and showing a manifest tendency to irregular extension."[1]

Carcinomata:
- Epithelioma consists of surface epithelium:
  - Squamous.
  - Cylindrical (columnar).
- Glandular carcinoma (histologically resembles racemose gland).
- Colloid cancer.
- Syncytioma malignum (carcinoma of placental site).

[1] Stengel, A Text-book of Pathology.

Tumors are rarely composed of but one type of tissue; several types may be present, the tumor receiving its name from the tissue predominating. When the distinguishing feature of a tumor is two predominating tissues, the tumor is given a compound name; as, for example, when, in a sarcomatous growth, numerous large multinucleated cells characteristic of bone-marrow are found it is called a myelosarcoma. When fibrous and sarcomatous tissue are distinguishing features the tumor is called a fibrosarcoma.

Tumors are dangerous in several ways: The size of the tumor may cause pressure upon important structures. The rapidity of growth may sap the vitality of the individual. If the tumor degenerate or suppurate, it may produce hemorrhages, or the absorption of the poisonous products may produce toxemia with anemia, emaciation and weakness, and a train of malnutritional conditions due to intoxications (p. 100). The metastasis of portions of tumors as emboli reproduces the tumor in a new locality. In the connective tissues the sarcomata are the malignant types and the sarcomatous element in a mixed tumor determines the malignancy, *e. g.*, in fibrosarcoma. In the epithelial tissues the carcinomata are the malignant tumors, and in mixed tumors determine the malignancy.

Malignant tumors are often associated with disturbance of the general health from their inception. They tend to recur after ablation and either invade the adjoining tissues which may cause grave local disturbance or the morbific material they form enter the circulation or lymphatics and thus are transplanted to other localities (metastasis).

Since the malignancy of a tumor is due primarily to the size and the rapidity of its growth, it is clear why sarcomata are more malignant than fibromata, and why some forms of sarcomata are more malignant than others. To illustrate:

Begin observation at the different stages of connective-tissue development, when connective-tissue cells have first divided, reproduced; the tissue produced is at the indifferent stage, as seen in section of the embryonic jaw (Fig. 35).

Mesoblastic cells at this early period are in an indifferent stage; some of the cells shown in the figure will form bloodvessels, others will become bone corpuscles, others will form fibrous and others muscular tissue. This structure has its analogue among tumors in a soft, fleshy, rapidly growing growth, called the round-celled sarcoma. As cells expend their vital energy in three ways (nutritive, functional, and reproductive activity) the embryonic cells of such a growth may expend their energy in nutrition (growth), and will then grow out of the indifferent stage into a more mature form of

connective tissue, the ultimate form of one type being a fiber; an embryonic round cell undergoing a series of form changes from a small round cell to a long fiber (Fig. 36). The growth may cease at any stage of this form change, the tumor composed of such cell forms receiving a corresponding name. The embryonic connective-tissue tumors, as stated, are called sarcomas, the form of the cells composing them giving them a qualifying title.

Fig. 35

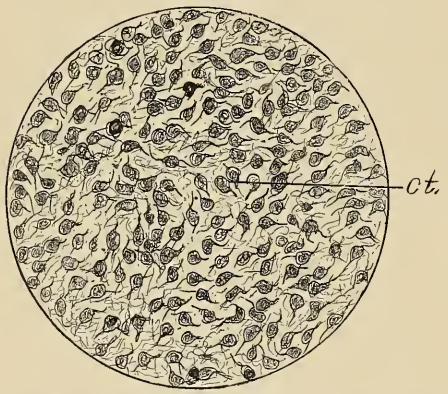

Porcine embryo: *ct*, embryonic connective tissue of mesoblast. 2.5 cm. × 250.

In Fig. 36 are represented the stages of development of a connective-tissue fiber from a round cell. If growth cease at stage 1, and the cell energy thereafter expend itself in reproduction, a rapidly growing tumor composed of small round cells is formed—a small round-celled sarcoma, markedly malignant. If the cells expend a portion of energy in growth of cell size, a large-celled sarcoma is formed, less malignant than the former. If the cells expend a portion of their energy in forming intercellular substance, reproduction and malignancy are less active. So the spindle forms, 3 and 4, represent less rapid reproduction and lesser malignancy than 1 and 2, although

Fig. 36



the form 4, which should be of less rapid reproduction than 3, because of more mature organization, is frequently more malignant, because less intercellular substance is formed, as shown in Figs. 37 and 38, the energy represented in that process being used up in reproduction. The nearer the approach to the mature form (6, Fig. 36) the slower the growth of the tumor, which, when composed of tissue of this type, loses its fleshy (sarcomatous) appearance and becomes fibrous, and is hence called a fibroma.

When a sarcoma begins its growth from bone, its histological character is frequently modified (Fig. 39). It contains large marrow

cells which have undergone incomplete reproduction, forming giant multinucleated cells; this is a common form of tumor emerging from the sockets of teeth. Some of the cells of a sarcomatous growth

Fig. 37



Small spindle-celled sarcoma (from a tumor of the leg). × 200.

Fig. 38

Large spindle-celled sarcoma. To the left the cells have been separated by teasing, so that their individual forms are apparent; to the right they are in their natural state of apposition, such as would be seen in a thin section of the tumor. (Virchow.)

may go on to maturity, while others remain at some stage of their developmental career. Malignancy will be modified according to the amount of mature tissue formed.

Fig. 39

Myeloid epulis from lower jaw: *a*, multinucleated giant cells; *b*, oval cells. × 265. (Pepper.)

Fig. 40

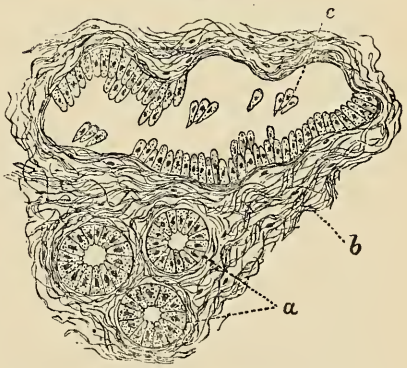

Adenoma of the breast: *a*, group of glandular acini; *b*, fibrous stroma; *c*, cells broken away from their attachment. × 265. (Pepper.)

Epithelial Tumors.—Growths arising from epiblastic or hypoblastic tissues may be benign or malignant. What are called the adenomata may be taken as the type of the benign epithelioma; that is, compara-

tively benign. They present all of the characters of typical glandular tissue; numerous acini lined with epithelial cells and surrounded by connective tissue (Fig. 40). Tumors of this type may lose their comparative benignancy and become of the succeeding epithelial type.

Carcinomata.—These are growths arising from preëxisting epithelial tissue, which possess the characteristics of epithelium developing without limitations of a basement membrane. Beginning upon a skin, or mucous surface, or in a gland, the reproduced epithelial cells are not sharply marked off from the connective tissue by a limiting membrane, but, gaining entrance to the alveoli of connective tissue, they proliferate there, find their way into lymphatic vessels and lymphatic glands, and reproduce epithelial growths in such places of lodgment, so that a tumor having its origin in one part may give rise to tumors in other parts of the body —metastasis (Fig. 41). Carcimomata of the mouth are frequently due to chronic irritation, as from smoking or pipe-stems, jagged teeth. Bay[1] states that it is rare in European women while common in men; that women of Ceylon and India excite it by betel-nut chewing.

Fig. 41

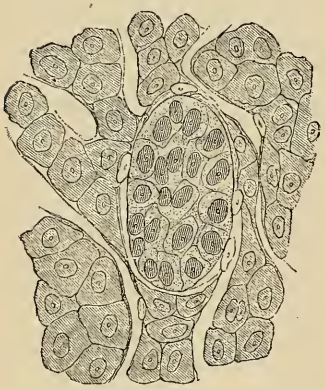

Section through an aggregation of very young cancer cells, lodged like an embolus within a capillary of the liver. The parent growth was an adenocarcinoma of the stomach. Preparation stained with hematoxylin. × 300. (Ziegler.)

Like the connective-tissue tumors, types of carcinoma differ as to rapidity of growth in their original situation and in the degree of transference; these factors determine their malignancy. Tumors of the sarcoma group may also give rise to growths in other parts, the tumor cells being carried thence by lymph vessels or bloodvessels.

After a period, tumors frequently suffer such interference with their nutrition that degeneration occurs in them.

After removal, some varieties of tumors, both those which infiltrate surrounding tissues and those which are metastatic, show a tendency to recurrence; that is, removal does not effect a cure, and the tumor upon reappearance assumes another and a more malignant character.

Epithelial tumors never become tumors of the connective-tissue

[1] Dental Cosmos, June, 1913.

type; and, *vice versa*, connective-tissue tumors cannot become epithelial tumors.

The distinction formed between epiblast and mesoblast in the embryo is maintained throughout life. Tumors show a great variety of histological characteristics, for which works on general pathology should be consulted.

While the treatment of tumors is not a part of this book, it may be said that, unless the cause of a tumor can be located and its benign character determined, it is wise to view it as dangerous. They should be usually removed surgically unless inoperable. The *x*-rays, radium rays, or Finsen light rays, etc., are useful in some cases after operation or in inoperable cases.

Cooley, of New York, has suggested a toxin for injection which inhibits sarcoma and at times cures. Its use after operation is held advisable.[1]

The writer has been urged to introduce material upon tumors of the jaws. This seems inadvisable, as space does not permit. A tumor is readily seen and should be viewed with suspicion. If not dental as described hereafter, it should be referred to a surgeon for further diagnosis.

DEFICIENCY OF NUTRITION; HYPONUTRITION.

If the quantity or quality of the blood delivered to a part be deficient, the nutrition of the cells of the part is impaired. First, atony, a lessened activity of the vital processes of the part, occurs. Cell chemistry is disordered, and waste products are either retained in or about the cells.

The function of the cells is diminished: If secretory, its secretion is lessened; if muscular, the cell has a lessened contractility; the relations between nutrition and waste are disturbed; the part becomes physiologically wearied sooner than usual.

Hypoplasia.—If the process cause interference with the development of an organ, so that it is much below normal in size, or the development of a part is arrested, whether from lack of nutrition or disturbance of developmental cells, the resulting condition is termed hypoplasia.

If the parts fail entirely of development, the condition is called agenesia.

Atrophy.—If the process of hyponutrition be marked, the waste in a previously normal part may exceed repair, and the part affected

[1] Clinton, Dental Cosmos, 1910, p. 316.

becomes diminished in size or atrophied (Fig. 42, *B*). Atrophy may be general or local. In general atrophy there is a general loss of tissue, due to an excessive waste or faulty assimilation of food by the tissues. There is a loss of body weight, due first to a loss of the fat, later to shrinkage in the tissue cells. The shrinkage in size of the tissue cells causes shrinkage of the entire organ. The cells and fat may recover their size when the faulty waste or assimilation is corrected. During atrophy many cells are lost through the process of fatty degeneration and removed by the phagocytes (leukocytes), so that atrophy may, like hypertrophy, be both simple and numerical. An atrophied part is pale and shrunken, contains less fluid, and is tough and fibrous. At times the fibrous portion or connective tissue may increase as the cells diminish (sclerosis).

Causes.—General atrophy is caused:[1] (1) By a deficient supply of food material delivered to the tissue cells. This may be due to a primary food deficiency or any interference with its preparation for absorption or with its proper absorption or circulation. (2) By excessive waste of the tissues generally, as in fevers, prolonged suppuration, etc. (3) By impaired vital activity of the cells themselves, as in senile conditions.

FIG. 42

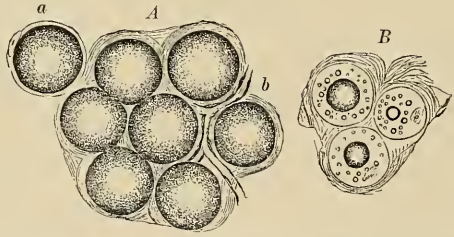

Adipose tissue: *A*, normal; *B*, atrophic, from a case of phthisis; *a*, single fat cell, with cell wall, nucleus, and drop of fat. × 300. (Virchow.)

Local atrophy may be caused: (1) By a lessened circulation in a part due to obstruction of the arteries, veins, or capillaries, as, for example, by pressure. (2) By diminished functional activity or disuse of a part, as in the case of unused muscles or even bones. Certain organs are atrophied or resorbed as a part of the cycle of life, *e. g.*, the umbilical cord, the roots of deciduous teeth, the thymus gland, the mammary glands after the menopause. (3) The loss of nervous connection of a part with the nerve centres controlling it (trophoneurosis), or through interference with nervous centres

[1] Green.

having trophic influence upon a part. (4) Excessive functional activity may cause atrophy by producing a degenerative condition due to overstimulation.

Degeneration.—If cells have reached the limit of their life cycle or have been subjected to influences markedly disturbing their nutrition, the proteids of which they are composed are replaced by new substances of somewhat obscure origin, which appear in the parenchymatous cells and connective tissue, markedly altering the histology and producing a pathological anatomy peculiar to each form of degeneration. If the change is due to chemical changes within the tissues, it is a true degeneration. If the new substance enters the cell, it is an infiltration.

FIG. 43

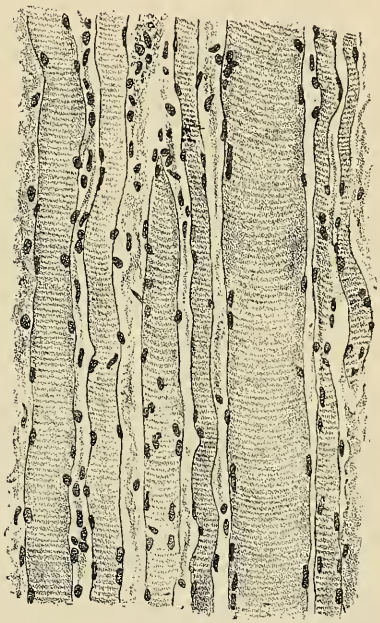

Muscle fibers in simple atrophy. (Schmaus.)

Fatty Infiltration. — In this condition the fat is found in globules in the cells, which globules tend to coalesce. The nucleus may be pushed aside. It is regarded as simply the storing of fat in healthy cells, though possibly an infiltration may occur in a debilitated or degenerated cell (Fig. 44).

Fatty Degeneration. — Fatty degeneration is a condition in which the pathological accumulation of fat is found in the substance of cells. The cell appears granular and fat-droplets appear within the substance of the protoplasm and give a black reaction with 1 per cent. osmic acid. These do not tend to coalesce, as in the case of fat infiltration. "The larger the amount of cell albumin replaced by fat the nearer is the whole cell to death"[1] (Figs. 45 and 46).

Three theories are held as to the origin of the fat:

1. That the proteid of the cell is changed to fat.

2. That fat is a normal part of cell proteid and simply becomes more visible because set free through the action of poison (such as

[1] Green, Pathology and Morbid Anatomy.

bacterial ferments or phosphorus) acting upon the combinaton of fat proteids in the cell. The administration of phosphorus to animals produces it.

3. That the fat is infiltrated from the blood, as in fatty infiltration, but into diseased cells. Thus animals were poisoned with phosphorus and then fed with fat foreign to the animals; the foreign fat was found in the degenerated cells.

Fig. 44

Liver cells in various stages of fatty accumulation. × 300. (Rindfleisch.)

Fig. 45

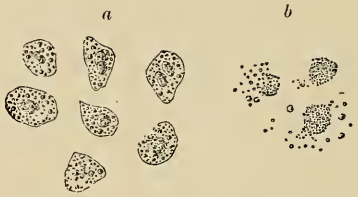

Fatty degeneration of cells: *a*, from a cancer; *b*, from the brain in chronic softening. × 200. (Green.)

Fig. 46

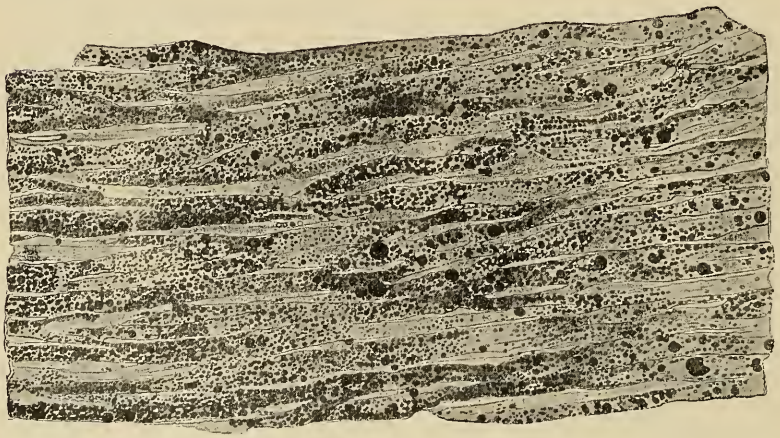

Fatty degeneration of the heart, from a case of pernicious anemia. The protoplasm is replaced by globules of various sizes stained black by osmic acid. The outlines of the fibers are irregular, owing to inequality in their distention. × 400. (Green.)

Causes.—Depression of vitality is always the proximate cause, and as primary causes producing this depression may be mentioned:

Tissue starvation from any cause, as from an altered food supply. The lack of oxygen in acute hemorrhage (suboxidation). The introduction into the blood of toxic substances, such as mineral poisons,

e. g., arsenic, mercury, or phosphorus; chemical compounds, as carbon monoxid; leukomains, as in diabetes and chronic anemia; toxins, as in fever of bacterial origin or from a focus of infection. Locally, interference with the circulation, if not sufficiently overwhelming to produce death, may cause fatty degeneration of cells by interfering with the food supply, as in venous hyperemia, aseptic infarcts, and simple inflammation. The products of infection can produce fatty degeneration in the cells of the inflamed area. (See Pathology of Inflammation.)

FIG. 47

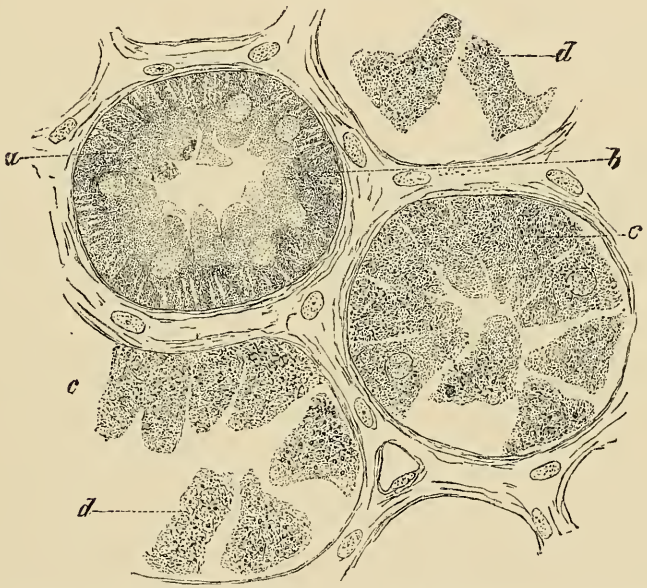

Cloudy swelling of kidney epithelium: *a*, normal epithelium; *b*, epithelium beginning to be cloudy; *c*, advanced degeneration; *d*, cast-off degenerated epithelial cells. From a preparation which had been treated with ammonium chromate. × 600. (Ziegler.)

In areas which have undergone fatty degeneration a cheesy substance may be formed out of the degenerated elements existing in the part. The fluid is gradually absorbed and a mass composed of atrophied cells, fatty debris, and cholesterin crystals is left. This process is known as caseation. Encapsulation of the caseous mass by fibrous tissue may take place, or its liquefaction or its calcification may occur. Fatty degeneration may occur in many tissues, and the danger is proportionate to the importance of the tissue involved.

Cloudy Swelling (Parenchymatous or Granular Degeneration).—Cloudy swelling is a change occurring in the parenchyma (essential

cells) of a part as the result of the presence of toxic substances in the blood, or even as the result of aseptic disturbance of nutrition, such as a severe burn. The same causes which produce fatty degeneration may produce it.

Pathology.—The cell absorbs fluid, swells, its contents become granular, and the histological structure is lost. In the early stages the change is albuminous; no fat is demonstrable; later, however, it appears, so that the change is regarded as a first stage in the production of fatty degeneration, by which process many of the cells are lost, though the organ may recover if the patient withstands the original disease (Fig. 47).

Glycogenic Infiltration.—Normally, glycogen is found in some other tissues than those of the liver, notably in muscle. If it appear in tissue not normally containing it, or in excess in those in which it is normal, a glycogenic degeneration or infiltration exists. It may be produced by any influence which alters the behavior of cells, especially those having secreting activity toward the carbohydrate food element (glucose), as in diabetes, and, while mostly within the cells, may exist in the intracellular tissue. (Stengel.) It is stained brown by iodin and converted by ptyalin or amylopsin into sugar, the color reaction then not occurring.

It does not seem to be clearly shown as a direct infiltration of glycogen, but rather as an appearance of glycogen in the cells, which may readily be glucose changed to glycogen within the cells. It has not been satisfactorily shown to be a degeneration from proteid constituents. (Stengel.)

Cook[1] calls attention to the fact that the tissues become capable of diverted action, and that the glycogen may, even experimentally, be so acted upon by oxidizing agents as to be converted into acid derivatives, probably lactic acid, paralactic acid, and sarcolactic acid, and that these may be broken up by the zymotic action of tissue cells or by certain bacteria. The degenerative change in the tissues renders them susceptible to bacterial action, as in case of the gum tissue.

The mucous membrane of the gums has been shown by the same author to be capable of this degeneration if overstimulated by chemical agents followed by the use of a stiff brush, and he argues that acid derivatives may be liberated either by the tissue or by bacteria in contact with them, and thus possibly account for certain phases of tooth destruction, as erosion. He emphasizes the fact that infiltration of tissue, with abnormal quantities of a normal constituent

[1] Dental Cosmos, 1907.

of the body, is more likely to take place in the lymphoid and mucous cells of the body than in any other tissue structure.

Hyaline Degeneration.—In various forms of arthritis, in arteriosclerosis, during infection, in septic processes, and in other conditions a retrogressive process, characterized by the appearance of a homogeneous proteid substance, occurs. It is closely allied to amyloid, mucoid, and colloid degeneration, and to coagulation necrosis. The new tissue is of a glistening, waxy, homogeneous appearance, and stains with great affinity with acid anilin stains, as acid fuchsin, taking a brilliant red color. The cells of the part may show fatty degeneration.

Location.—Seats of interest are the endothelium of bloodvessels, which is proliferated, making the wall thickened, and the lumen narrowed or obliterated. (See Endarteritis Obliterans.) Upon mucous membranes it causes opaque plates or pseudomembranes. It occurs in interstitial tissues and also within the cells. Its proximate etiology and pathology are obscure.

FIG. 48

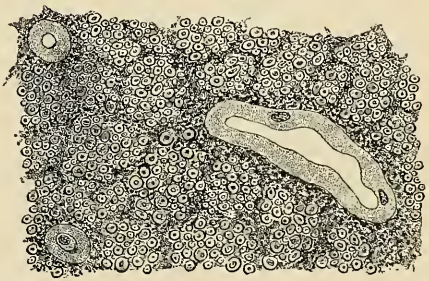

Hyalin degeneration of small vessels in the cord. × 350.

The hyalin material can be reconverted, absorbed, and removed. It does not injure the cells to an extreme degree. It may be converted into other albuminoid degenerations, may undergo caseation and calcareous infiltration. (Stengel.) It has been found in the epithelium of the mouth by Cook, but without established significance.

Mucoid Degeneration.—In this form of degeneration the proteid protoplasm of cells is transformed into mucin, a glycoproteid characterized by affinity for basic anilin stains, as methylene blue. It occurs in catarrhal mucous membranes, connective tissue, tumors, etc. Mucin absorbs water, but is not soluble in it or dialyzable. In the catarrhal mucous membranes the goblet cells show excess in number, and are swollen and distended with mucin. (Stengel.) The cell becomes vacuolated and the nucleus granulates and stains with a basic stain. About the necks of teeth the mucus becomes stringy and tenacious, its chemical and physical character being changed and chondroitin present. (Cook.)[1]

[1] Dental Cosmos, 1907.

According to this author this substance combining with water might give rise to sulphuric acid in contact with the teeth. $C_{18}H_{27}NSO_{17}+H_2O=H_2SO_4+C_{18}H_{27}NO_{14}$. Mucic acid might be produced from glycuronic acid found in mucin. Cook observed mucoid degeneration of epithelial cells and submucous structure in cases in which strong astringents were used on the mucous membrane; the contraction of the cells caused a retention of mucin leading to a chemical change in the mucin itself. (See Erosion.)

Fig. 49

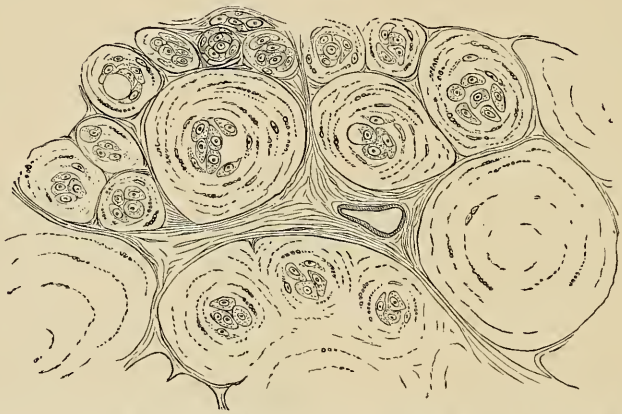

Colloid cancer, showing the large alveoli, within which is contained the gelatinous colloid material. × 300. (Rindfleisch.)

Colloid Degeneration.—This consists of the abnormal appearance of a non-dialyzable substance like mucin, but differing from it in preference for acid stains, by not being precipitated by acetic acid and alcohol, by lack of absorption of water, also by causing a more profound disturbance of cells in which this is found and in which it remains much longer. Salts, as calcium oxalate, are apt to be precipitated in it, and may be again dissociated. The etiology is obscure, but probably analogous to that of mucoid degeneration.

Dropsical Infiltration.—This is an infiltration of an excess of plasma into cells. It is a part of cloudy swelling, or may occur as large droplets of plasma enlarging the cell compressing the nucleus and protoplasm, and may even cause the cell to burst. Fatty degeneration of the protoplasm may occur as a sequence to dropsical infiltration. The process occurs in general dropsy, in burns, in skin lesions connected with vesiculation, and in inflammation of organs.

Lardaceous Degeneration.—This type of degeneration is known as amyloid, albuminous, or waxy. The formation of the material from which this condition derives its name is preceded by an unknown

type of degeneration of the cells of the part affected. The degenerative processes appear to be the result of long-continued suppuration due usually to tuberculous disease. In the connective tissue about the degenerated cells (not in the cells) a substance akin to albumin is deposited, which causes swelling and a pseudohypertrophy of the organ affected. The substance gives a reaction with iodin resembling that of starch; hence the name amyloid (*amylum*, starch). It may affect any organ of the body. It usually appears first in the connective tissue lying between the inner and middle coats of small arteries. The swelling caused by the infiltration markedly lessens the caliber of the vessels and diminishes the nutritive supply of the parts supplied by the artery, which may lead to fatty degeneration and atrophy of the insufficiently nourished parts.

FIG. 50

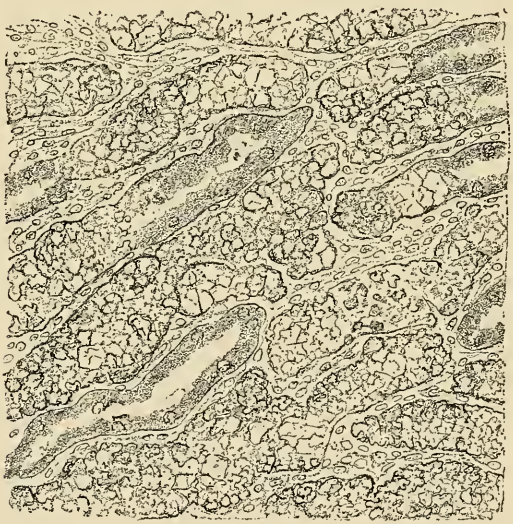

Calcareous infiltration of renal epithelia. From the edge of an old infarct; a few tubules still to be recognized. × 250. (Schmaus and Ewing.)

Calcareous Infiltration.—In tissues which have undergone previous degeneration, calcium, sodium, or magnesium salts may be deposited as an infiltration from the blood plasma. The parts are thus petrified. The cells take no active part in the process.[1]

It is believed, however, that the deposit of salts in the dying tissue is more than a mere precipitation, and that calcification results from a combination of the salts with an albuminous base and with fatty

[1] Green, Pathology and Morbid Anatomy.

acids, such an affinity being favored by the degenerative changes. Ordinarily, the carbonate and phosphate of calcium are the infiltrating salts, but in gout uric acid salts are deposited, owing to an excess of uric acid in the form of biurates and quadurates in the body fluids. A sluggish circulation in the part favors the deposition of the salts. The calcification may occur in both the cells and in the intercellular substance.[1] (See Calcific Degeneration of the Pulp.) In the early stages the salts are found as fine granules in the intercellular substance.

"The white, fibrous tissue is the form of connective tissue usually affected, but concretions may occur in the connective tissue surrounding the bloodvessels."[2]

As a secondary process after degeneration, calcification of the middle coats of the arteries may occur, rendering them inelastic. This renders them incapable of regulating the blood supply to parts, and these suffer more or less nutritive disturbance, and, in some cases, actual death of the part (gangrene). Calculi are found in tumors at times. Many forms of free calculi are formed in the body. These occur most frequently in ducts or cavities lined with epithelium, *e. g.*, the salivary ducts and the bladder.

"All free concretions have an organic basis or nucleus," with which are combined the calcium salts, oxalates, cholesterin, etc., making up the inorganic or crystallizable part of the combination. The organic part may consist of inspissated feces, as in enteroliths, mucus, or mucin, as in the calculi upon the teeth; epithelial scales, mucus, etc., in the urinary passages.[3] The fine crystals or granules are probably soluble in some cases. The larger calculi are probably permanent and cause degeneration of adjacent tissue.

Calcareous infiltration is clearly to be distinguished from the normal calcification of the hard tissues, bone, enamel, dentin, and cementum. These are composed of calcoglobulin, in which calcium and magnesium salts are combined under the superintendence of certain living cells with albuminous bases derived probably from their own substance.

Pigmentary Infiltration (see Tooth Development).—Pigmentary infiltration is the infiltration of coloring matter into the tissues. There are four varieties:

1. Extrinsic, derived from outside the body, *e. g.*, coal dust in lung tissue or general staining from silver salts taken up in the intestines.

2. Hematogenous, derived from hemoglobin or its derivatives. They are:

[1] Ziegler, General Pathology. [2] Ibid. [3] Ibid.

(*a*) Hemoglobin, dark red.
(*b*) Hemin, reddish brown or bluish black.
(*c*) Methemoglobin, brownish red.
(*d*) Hematin, dark brown or bluish black.
(*e*) Hematoidin, orange or reddish brown.
(*f*) Hemosiderin, yellowish or brownish.

These are decomposition products of hemoglobin. Hemoglobin and hemosiderin contain iron.

3. Hepatogenous, or biliary.

4. Metabolic, resulting from cellular activity within the body, and termed melanin.

The hematogenous pigments are of chief interest, inasmuch as they occur in the staining of teeth by devitalized pulps and sometimes by living pulps in a state of venous hyperemia. In these discolorations there is an analogy to the colors manifested in an old bruise, which undergo various color changes as the chemical character of the pigment is altered. (See Moist Gangrene of the Pulp.)

NECROSIS.

Necrosis (from *nekros*, dead) signifies, in its broadest sense, death of tissue. It is due to profound disturbance of its nutritional function or to direct injury to its elements.

Necrosis proper (*per se*) signifies death of tissue in mass from any cause.

Necrobiosis means the death of cells through the process of atrophy or degeneration, which are successive changes leading to death.

Necrosis of bone signifies the circumvallation and death of bone through the process of inflammation, which causes thrombosis of its vessels and cessation of its nutrition. The dead part, when separated, is called a sequestrum. The solution of continuity is effected by leukocytes massed about the portion in which nutrition has ceased.

Caries of bone is that form of bone death in which the bone is honeycombed and molecularly broken down rather than sequestrated. (See Osteoporosis.)

Gangrene is a term used to signify death, *en masse*, of a part, the soft parts being included. The dead part undergoes drying (dry gangrene) or putrefactive softening (moist gangrene). (See Gangrene.)

Etiology.—The causes of necrosis are as follows:

1. *Circulatory obstructions,* as (*a*) stoppage of an artery supplying a part, the nutritive supply being cut off by any cause; (*b*) venous hyperemia of a part, the vein being unable to carry off the blood charged with cellular waste, which accumulates about the cells, intoxicates them, and prevents access of fresh blood (food supply); (*c*) occlusion of the capillaries by any cause has a similar effect. Inflammation may be placed in this general class of causes.

2. *Trophic Disturbances.*—The nerves controlling the metabolism of a part being diseased, the part undergoes degeneration and slight causes produce necrosis, *e. g.*, necrosis of eyeball when excision of the Gasserian ganglion has been practised.

3. *Direct destruction* of the vital activities of cells by any physical or mechanical agents, or chemical substances, including among the latter the poisonous substances produced through the action of bacteria. (See Fig. 77.)

Injuries, blows, the tension of exudate, pressure, excessive heat or cold, the passage of powerful electric currents, and the *x*-rays are all influences which directly injure or permanently destroy vital activities of cells. The application of chemical agents which so act upon cell substance as to change its character produces necrosis.

While this is particularly true of such substances as powerful acids and alkalies, or alkaloids, which immediately destroy cell integrity, it is also true of milder agents acting for longer periods. Certain poisons, particularly those of bacterial origin, paralyze the vital activities of cells, and necrosis results.

The occurrence or non-occurrence of or the liability to necrosis will largely depend upon the degree of vital energy of cells prior to the action of the active causes of necrosis. Parts debilitated from any cause are more liable to necrosis than those which have suffered no debility. A part chronically ill-nourished, subjected to the causes producing degenerations, is liable to suffer necrotic changes, for the several degenerations and atrophy are but successive stages leading to necrosis.

A necrosed part acts as an irritant to the tissues about it, inaugurating an inflammatory reaction which marks off the dead from the living parts. The dead part is sequestered, and hence is called a *sequestrum,* or, in case of soft parts, a "*slough,*" or *sphacelus.*

Necrosis may be of several types, of which the following are the chief forms:

Coagulation Necrosis.—When a dying tissue contains coagulable material and the necessary ferments, the parts undergo coagulation. (See Coagulation.) The cells and parts about become solidified, the cells lose their nuclei and do not stain as usual, and the part appears

glazed, pale, and waxy. It occurs in suppuration, and is due to the coagulating ferments of pyogenic cocci. (See Bacterial Ferments; also Fig. 63.)

The thrombosis of the vessels about an area of infective inflammation is probably due to the same ferments.

Fat Necrosis.—This is a peculiar form of fat death in which the fat is split into glycerin and fatty acid by lipase (a ferment). The fatty acid remains and combines with inorganic salts.

Liquefaction Necrosis.—This is the death of tissue with liquefaction of the proteid material in the area, which is usually rich in exudates. The process is probably due to enzymes capable of liquefying the tissue.

GANGRENE.

When death, *en masse*, of a part occurs as the result of an interference with its nutritive supply, the process is termed gangrene, regardless of the subsequent results in the dead tissue.

Causes.—It may occur as the result of an inflammation produced by a particular bacterium, as in noma or malignant edema; from arterial obstruction, as arterial thrombosis; or capillary obstruction, as in freezing or venous obstruction, may produce it. (See Venous Hyperemia of the Pulp.) Ergot may produce it through contraction of the bloodvessels.

Dry Gangrene.—In parts which ordinarily contain but little fluid the obstruction of the artery may be associated with but little obstruction of the veins and lymphatics. Under such circumstances the dead part is drained of the little fluid it contains, and a fresh access of fluid is prevented. Exposure to the air aids a further loss of moisture by evaporation. The conditions are not favorable to the development of microörganisms, and the part changes from pale appearance to a dark, shrunken one. The process of gradual drying is also called mummification. (See Dry Gangrene of the Pulp.) It is usually circumscribed.

Moist Gangrene.—Under opposite conditions—*i. e.*, a venous obstruction with a fair arterial supply—there is much venous engorgement and extravasation of blood into the tissues, which are stained red by the hemoglobin from disintegrated red corpuscles. Abundant effusions also cause the part to be swollen. Death of tissue occurs from interference with nutrition; when bacteria are the direct cause, the part is inflamed and edematous. The moisture present favors the development of bacteria, and they enter the tissue through the skin. Putrefaction with the evolution of malodorous gases, such as hydrogen sulphid (H_2S), hydrogen phosphid (HP_3),

and ammonium sulphid $(NH_4)_2S$, causes the part to have an offensive odor.

If the gangrene be due to infective inflammation, or the surrounding tissue be debilitated from any cause, the area of gangrene may spread —*i. e.*, invade the living tissue (spreading gangrene). This is probably due to the presence of bacteria, which irritate and progressively destroy the surrounding tissue. The poisons produced, if absorbed, may cause death. If the adjacent tissue be healthy and resistant, a line of demarcation is established, consisting of leukocytes, which dissolve all fibers or firm connections between the dead and living parts. Suppuration occurs at the line, and the dead portion is separated as a sphacelus or slough. Occurring in bone, this is called

FIG. 51

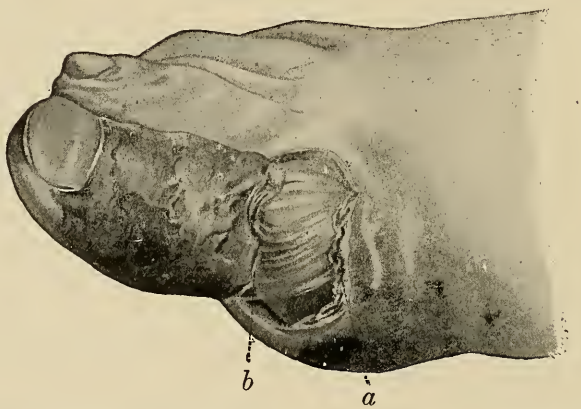

Senile gangrene of the great toe, from a case of arterial thrombosis. The toe is shrunken and its epidermis is being exfoliated. At the line of demarcation the skin has retracted (*a*) and the deeper parts are separating (*b*). (Green.)

a sequestrum. An ulcerated surface is left. The latter form is circumscribed gangrene. If gangrene be deep-seated and septic, suppuration occurs, which establishes one or more fistulæ upon the surface of the body or in one of its cavities. (See Moist Gangrene of the Pulp.) A sequestrum may be cast out through one of these. Occasionally the part being internal is encysted and the contents may be absorbed and the sac calcified.[1] In the aged atheromatous or calcareous changes in the arteries produce a slow circulation in the extremities. A slight injury to a vessel wall may induce extensive thrombosis (which see). The result is gangrene of a part or all of an extremity, known as senile gangrene (Fig. 51).

[1] Stengel, A Text-book of Pathology.

GENERAL MALNUTRITION.

By the term malnutrition is meant a more or less general disturbance of the metabolic processes of the cells of the body, which may simply lower the body resistance or health standard, or may be of such profound character as to incapacitate an individual for ordinary functions.

According to Howell,[1] some fourteen amino-acids and four diamino-basic bodies represent the construction of the proteids of the body which individually may contain all or a portion of the list. These amino-acids and polypeptids, making up the proteid-making food material in the blood, are thought to be derived by synthesis in the intestinal wall or liver of the elements derived from proteid food taken at the mouth through gastric (peptic) and pancreatic digestion in the alimentary canal, which are said to be completely hydrolized therein. When these amino-acids and polypeptids present at the cell the cell enzymes construct such as they require into cell proteid. Carbohydrate materials, fats and salts and oxygen, are also utilized by the cells. In cell catabolism the specific chemical substances which are the waste products of the special protoplasm of particular cells, probably go to other organs, as the liver, and are there changed. The ammonia salts are changed to urea, which is the most constant and bland of nitrogen excretions. The monoamino-acids and diamino bases are also changed to urea. Uric acid is also in part changed into urea, and even food (as simple amino-acids) may be formed into urea without entrance into tissue formation.

The purin bodies have a common purin nucleus or basis which with one atom of oxygen added forms hypoxanthin, two atoms of oxygen added form xanthin, three atoms form uric acid, which, as stated above, may be changed into urea. Adenin and guanin, two other purin bodies, are considered to be hydrolized by adenase and guanase or deaminizing enzymes into hypozanthin and zanthin respectively; these again are oxidized by another enzyme (zanthin oxidase) into xanthin and then into uric acid.

Some purin bodies come directly from food (also urea, see above), but also in part are formed in the body.

The catabolism of sugar in the body is uncertain, it being thought that enzymes produce intermediate products which oxidases change to carbon dioxid and water and that the internal secretion of the pancreas is in some way essential. The fats are supposed to be

[1] Text-book of Physiology.

changed into fatty acids and glycerin under the influence of lipase, controlled by the liver through an unknown series of changes.

If imperfect digestion, assimilation, or elaboration of food materials or its circulation, or an imperfect relation between the amount of oxygen and food material at the cell exist, or if a great excess of food material be assimilated which cells cannot appropriate, and the excess acts as material to be gotten rid of, or if the food taken be of an irritating nature, or if such material as retained body waste products, toxins derived from foci of infection, or from alimentary canal, or drugs absorbed are presented to the cells in excess, or if the drain upon the body cells reduce the amount of cell protoplasm, and the replacement of the cell constituents is not rapid enough to restore the protoplasm wasted in energy, it is plain that a general disturbance of body cells may result, and the altered metabolism in turn furnishes its share of irritating, unfinished catabolic products to further increase the general disturbance through the production of a pathological condition of the blood (a humoral condition, Michaels). The gradual action of one or other of these classes of causes, acting either by starving the cells or by irritating them (auto-intoxication), produces a condition with tendency to diseases of certain type, and the tendency is called diathesis (acquired).

According to Michaels,[1] following Gautrelet, the abnormal vital processes tend in mankind to pathological conditions, which we may classify under two humoral conditions (or diatheses), viz., hypoacidity and hyperacidity. The first state ("lymphatism") is the expression of a vital overactivity, and has, as consequences, the contagious diatheses (scrofula, tuberculosis, syphilis). The oxidations are overactive, and the hydrations are superior to the normal; hence there is a decrease in organic acidity and an increase of saline chlorides excreted by the economy. Hypoacidity favors chemical changes in the tissues. (Ducleaux.) In the hypoacid diathesis all the oxidations are exaggerated, and are above the normal.

"In the hyperacid diathesis (arthritism), gout, rheumatism, sclerosis, oxidation is insufficient; there is incomplete oxidation with a consequent increase of organic acidity or hyperacidity, and a peculiar state of the organism characterized in a general way by a slowness in the biochemical changes. The reaction of the blood with the ordinary reagents (litmus, for example) is normally alkaline,[2] but if we study the distribution of the acids and bases of the blood plasma we see that the reaction is really acid (Gautrelet, Drouin, and Hugeounenq), and thus acidity is increased and the blood

[1] Sialosemeiology, Proceedings Third International Dental Congress, 1900.
[2] Neutral to Phenolphthalein (Howell).

may become relatively acid by the accumulation of acid waste products which are not eliminated, the secretions and excretions becoming then of acid reaction. It is on this account that a certain number of chronic diseases have constant characteristics in regard to semeiology; increase of the normal acidity of the urine, as well as the increase in the normal acidity of the saliva." Following Gautrelet, he gives four effects of the exaggerated and retrograde processes that diathesis produces: (1) a chemical modification of the plasma; (2) modifications affecting the chemistry of secretions and excretions (as detailed above); (3) histological modifications in the tissues; (4) modifications due to the creation of a special field for microörganisms. It will be seen that the above effect begins with a change in the blood or its contents, which successively acts upon glandular and other cell physiology and later alters their histology, and in total may bring about a predisposition to bacterial invasion through the loss of vital potential or resistance. The hyperacid diathesis may be inherited or acquired by individuals who take a liberal supply of food requiring oxidation and take insufficient exercise in the open air, while in the hypoacid the oxidation is superior to normal.

These diatheses are the forerunners of many of the diseases of malnutrition, and evidence of approaching disease may be obtained from both saliva and urine by analysis of their contents through physical, chemical, and micropolariscopic examination of either or both fluids. The contents of each fluid being taken out of the blood through glandular activity represent fairly the faulty elements. The presence of altered physical characteristics when fresh or upon standing, of unusual chemical substances determinable either by the aid of reagents or microscopic or micropolariscopic examination, leads to the inference that unusual chemical changes have occurred in the cells, or that the waste products found represent an undue waste of tissue, or that cell waste has been altered after leaving cells or not sufficiently changed into the normal waste products.

In the accentuated disease condition one or more organs, as the liver and kidney, may be diseased, and it may be a nice point to determine whether the disease begins with the liver and proceeds to the diathesis, or with the diathetic condition or its cause and proceeds to disturb the liver. At the same time the same course might act upon both; for example, overfeeding with food requiring oxidation, and this not supplied by exercise, could induce a disturbance of the function of liver cells quite as readily as of any other body cells.

According to Kirk,[1] the disproportion between pabulum and oxygen resulting in hyperacidosis produces a greater ratio of carbon dioxid to oxygen in the blood than is normal. Temporarily this would be corrected by the action of the renal epithelium in which a reaction occurs between the carbonic acid of the blood and the basic phosphates, as follows: $HNa_2Po_4+H_2Co_3=H_2NaPo_4+HNaCo_3$. The sodium bicarbonate formed is returned to the blood, maintaining its alkalinity, and the acid sodium phosphate is eliminated as the normal acid salt of the urine. In the same way acid calcium phosphate is formed.

When the disproportion between pabulum and oxygen are continued, the suboxidation becomes chronic, the kidney is no longer sufficient to maintain alkalescence of the blood by eliminating the excess of acidity as acid phosphate, the carbonic acid seeks other channels of elimination, and the epithelium of the buccal glands and sweat glands may take up the action normal to the kidney and excrete acid sodium phosphate and acid calcium phosphate, producing in the case of the buccal glands a certain class of erosion of the teeth, and in the case of the sweat glands frequently giving rise to eczematous eruptions. Dental caries is not ordinarily introduced in this stage, but if begun the carious matter is changed to a dark brown color, crumbly, semihard texture, and the further process is one of decalcification rather than a true carious process.

"The continued suboxidation and hyperacidosis by carbonic acid thus leads to the great loss of basic phosphates as acid phosphates, which are more readily soluble and osmosed through kidney epithelium than basic phosphates, and for that reason are rapidly eliminated, thus establishing a phosphaturia, with consequent phosphatic starvation and ill health, as shown by neurasthenia, with its irritability, despondency, migraine, cerebral hyperemia, or hysterical phenomena. A point of depletion is reached and they are found only in minute quantity in the urine and saliva. At about this time lactates of sodium, calcium, and magnesium, in the order named, appear in the saliva, then double lactates of sodium and calcium, then lactophosphates of calcium and magnesium, then oxalate of sodium or double oxalate of sodium and calcium, while oxalate of magnesium may appear in the urine. With the appearance of the lactophosphate a general rather than a localized erosion appears. (See Erosion.) The nervous irritability is markedly increased, and a rapid loss of weight occurs. Later, acetone and diacetic acid appear in the secretion along with creatin, and in some

[1] Dental Review, 1903.

cases cystin, at which period profound mental torpor, at times almost amounting to coma, is not infrequently manifested, or there may be extreme nervous irritability amounting almost to hysterical mania.

"Coincident with the loss of the phosphates, nitrogen with carbon as a cyanogen radial (ammonium cyanate), which probably should have gone to form urea, is lost. Evidences of imperfect oxidation of proteids are manifested in the saliva and urine by the presence of lactate of ammonia (a forerunner of urea), lactate of calcium, creatin, acetone, and oxalates, with increase of urate of ammonia and amorphous urates. The urine often contains indican, especially in cases complicated with disordered liver and habitual constipation. The saliva is usually constantly acid, due to the presence of acid phosphates, and the dental lesions are ordinarily erosion, or, where the acidity is absent, pyorrheal invasion of the peridental membranes. Many of these cases develop epithelioma or leukoplakia buccalis, or both together, and in view of the fact that there is constant irritation of epithelium by the exudates, they may have an etiological relation." (Free quotation, Editor.)

The diet indicated by Kirk for these cases would apply to those diseases and cases of pyorrhea in which the predisposition is due to this diathetic fault, and consists in reducing the necessity for oxygen by largely eliminating the carbohydrate portion of the diet. Succulent vegetables, gluten bread, milk, albumin, and a moderate ration of proteids in the shape of fish, oysters, game, light meat of fowls, are allowed. Small doses of phosphorus, or of arsenic iodid, and glycerophosphates of lime and soda are continuously administered. The exercise and rest are adjusted, and attention is given to general hygiene.

"Michaels found the saliva of but few individuals to be in a perfectly normal condition and the teeth perfect, while most of them are out of equilibrium and the teeth are affected either by caries or erosion or pyorrhea alveolaris. He states that lesions of the liver and kidneys cause the appearance of acid waste, also that the organism constantly produces acids, such as uric, oxalic, lactic, volatile fatty acid, etc., which, under normal conditions, are also destroyed, but that abnormal conditions arise which retard the oxidations of these organic acids, which must then accumulate in the organism among the waste products arising from incomplete dissimilation; many have acid properties.

"The serum of venous blood, while weakly alkaline, has a real acidity (acid elements) stronger than that of arterial blood. Fever is accompanied by an acidity of the blood, as in diabetes (β-oxy-

butyric acid), rheumatism, arthritism (gout). The alkalinity is reduced (real acidity increased) in anemia, leukemia, and all cachexias.

"He regards the liver as determining the majority of nutritive changes, and that it suffers from the influence of all sorts of toxins, whether the result of microbic activity or due to an excess of alkaloids (leukomains). The cells of diathetic individuals constantly elaborate products, some of which are positively poisonous to the hepatic gland. The acid salts and biliary pigments are toxic. Their absorption is deleterious and the inactivity of the hepatic cells creates a danger to the organism. The danger arises from the fact that the liver has to eliminate from the circulation all kinds of debris. If the neutralization of the products of fermentation is incomplete; if the harmful ammoniacal compounds have not been changed into urea; if the liver does not have a reserve of glycogen, or if its generators, which are supposed to play a role in the metamorphosis of alkaloids, if through its inactivity there is a retention of waste products, the secretions are necessarily contaminated with the morbid principles; the toxic products present in the blood poisons the organism and constitutes the different diatheses (auto-intoxication)."

This conception includes the views of physiologists that the liver is both a secreting, excreting, and food-elaborating organ. He argues that if the bacterial fermentations, by their presence or by the presence of their toxins, are capable of modifying the enzymic secretions, they necessarily influence the action of the physiological fermentations. It follows from this that these toxic principles saturate, in a given period of time, the organic secretions and produce a cacochymic state (morbid state of the body fluids).

Michaels has found in the saliva of hypoacid individuals glycogen, albumin, perhaps inosite, mucin, basic chlorids with ammonia in greater quantites than normally, sulphocyanids and biliary acid in less proportion than normally, and concludes that it is an ideal medium for the development of microbic contagion. He has found glycogen in the saliva of adolescents generally, and susceptible of reduction and fermentation under the influence of ptyalin in the presence of earthy salts, a fact emphasized by Kirk with a view to its establishment as a prominent factor in susceptibility to caries (which see). In the saliva of hyperacids he found sulphocyanids and mineral and organic acids, acid phosphates of sodium and potassium, ammoniacal oxalates, biliary elements, and urobilin in greater proportions than normally.

The increased importance of the consideration of metabolic diseases in their relation to dental diseases by the dentist warrants the introduction of a brief summary.

Inanition.—This is ultimately tissue starvation, whether due to any of the following causes:

1. Want of proper amount of food.
2. Gastric diseases interfering with digestion by altering the quality or quantity of hydrochloric acid or pepsin.
3. Disease of the liver, etc.
4. Abnormal intestinal digestion.
5. Occlusion of the sorbefacients by retained excrementitious matter or other local disease.

Effects.—The tissues are not properly supplied with food to maintain themselves, and waste exceeds repair; the unimportant parts are first consumed and make good the deficiency. The surplus food materials, first the fats, are first consumed, then the carbohydrates, next the nitrogenous tissues, first muscles and glandular organs, and, lastly, the osseous and nervous tissues.

This is general atrophy necessarily accompanied by degeneration. There is loss of energy and temperature, and the vital organs are weak; death occurs from exhaustion.

Overfeeding.—The excessive use of proteids in food leads to a necessity for elimination from the blood of the excess absorbed, and to intestinal fermentation of the unabsorbed excess. The proteid food maintains the proteid equilibrium, and any more than is required for this is in excess.

Energy is largely supplied by the carbohydrates (eventually glucose) and the fats. An excess of these leads to the storing of fat to a degree normal and useful as a reserve, but in combination with a sedentary mode of life, pathological fat or obesity, in which oxidation is reduced. A tendency to fat production exists in individuals. The presence of food excess means an overstimulation of metabolism with possible alteration, which may lead to general disease of malnutritional type and predispose to infections, etc.

Excessive Tissue Destruction.—The tissues may be excessively wasted by many causes, and in many cases the food supply is deficient as well. These causes are, briefly:

1. Fevers.
2. Continuous hemorrhage.
3. Long-continued suppuration.
4. Tumors, especially carcinoma.
5. Chronic infectious diseases, as tuberculosis.

The increased waste is due either to increased oxidation of the proteid elements, due to stimulation of nervous centres controlling catabolism, or to the ferment contained in the toxic substances produced and entering the blood, which may cause cellular waste

in the effort to produce antitoxins (see Ehrlich's Side-chain Theory), while at the same time normal food appropriation is interfered with if the amount of food supplied is not indeed lessened, as in continuous hemorrhages.

Intoxications.—These may be divided into extrinsic and intrinsic intoxications. The principal classes are:

1. **Intestinal Intoxications.**—In intestinal putrefaction, particularly in constipation, the aromatic products, acetone, tyrosin, indol, skatol, phenol, cresol, and paracresol, may be absorbed and produce a form of intoxication of tissue cells which lowers the vital potential of all cells and the resistive force of tissues to bacterial infection. In intestinal putrefaction in children a marked readiness of the muscular system to fatigue has been noted, also in cases of persons who have suffered from indicanuria for a long time, showing a markedly poisonous effect upon muscle and probably upon other tissue.

The absorption of indol and its modification in the liver lead to its appearance in the urine as indican, or indoxylsulphate of potassium,[1] which, therefore, indicates an abnormal intestinal putrefaction with absorption of deleterious products.[2]

That indican in the urine is caused by abnormal tissue metabolism is not well supported by evidence.[3]

It is found in carcinoma and chronic peritonitis. It is generally present when suppurations are in progress; probably indol is absorbed from the focus of putrefaction. The ingestion of pus from pyorrheal pockets in the mouth may easily lead and has led to chronic gastritis and intestinal putrefaction, in which latter Bacillus coli communis plays an important, assistant part. The liver may be disordered primarily, thus favoring the condition owing to lessened formation of bile, or, secondarily, owing to its increased function as a poison destroyer. The intestinal putrefaction causes the formation of indol, etc., thus leading to the presence of indican in the urine. The excessive use of proteid food not only overloads the intestine, but invites putrefaction therein; also, the amount absorbed being excessive, the eliminative functions are overtaxed, leading to disease.

2. **Drug Intoxication.**—The use of arsenic, phosphorus, or other inorganic poisons, or the vegetable alkaloids, as morphin, cocain, atropin, etc., or the continued contact with lead salts, all undoubtedly affect metabolism—some beneficially—when employed

[1] Thompson's Practical Medicine.

[2] Test for indican: Add nitric acid to urine—shake with chloroform—a bluish color is imparted to the chloroform on standing.

[3] Leathes, Problems in Animal Metabolism.

in suitable doses in diseased conditions, or injuriously in continued excessive use. Thus atropin in small doses checks secretion—*e. g.*, of the salivary and mammary glands. Phosphorus continued produces fatty degeneration.

3. **Bacterial Intoxication.**—The toxic products of bacterial action (apart from the aromatic products), as the ptomains and albumoses (toxins), act as ferments upon proteid tissue, causing cellular waste either by ferment action (destruction) or by stimulation of the cells, either directly or through the nervous system, leads to the production of antitoxic substances in excess, which by Ehrlich are claimed to be discharged into the blood. No doubt the cell is also rendered less capable of anabolism. (See Side-chain Theory.) This is seen in fevers in which emaciation (excessive waste) is proved by the increased output of urea.

4. **Intrinsic Intoxication.**—In this class may be placed all intoxications produced by substances originating in excess within the body proper as a result of metabolic disturbance, resulting from disease of the nervous centres controlling metabolism or of organs which fail to perform their duty of elaboration for metabolism or elimination or elimination proper, in part or entirely. In some cases compensatory elimination by other organs occurs, which may be effectual or may lead to disease of said organ or organs. A good example of compensatory elimination is seen in health during sudden changes of atmospheric temperature. Thus on the warm days perspiration is free and elimination by the urine lessened; the avenue of elimination is largely reversed on the cold days. These intoxications may also be classed:

Uremia.—In this there is a retention of urea (as ammonium carbonate or its congeners) in the system which should be eliminated in the urine. The body cells are chronically or acutely poisoned, according to the degree of the retention, death resulting in the complete form. Nephritis is a common cause.

Diabetes Mellitus.—In this disease probably the essential lesion is a hyalin degeneration of the islands of Langerhans, of the pancreas, or injury to the floor of the fourth ventricle of the brain (diabetic centre), which may be caused by even strong mental emotion, as grief.

Carbohydrate assimilation is interfered with: an increased amount of sugar appears in the blood (hyperglycemia) and urine (glycosuria), and the cells are unable to appropriate it. Protein destruction with increased production of urea occurs (excessive waste).[1] An

[1] Stengel, A Text-book of Pathology.

excess of phosphoric and sulphuric acids, β-oxybutyric and diacetic acids are formed or retained, and hyperacidosis results.

The sugar in diabetes is probably first formed from carbohydrates, later from proteids, the carbohydrate radicals being probably dissociated in the proteid disruption.

Therefore, patients who form sugar after the elimination of sugar from the diet furnish a grave prognosis. The chief aim in the treatment is the almost entire elimination of carbohydrate food or proteid food containing glycogen.[1] All cells have a lessened resistance to bacteria, as shown by an increased tendency to pneumonia and tuberculosis,[2] and a similar predisposition to pyorrhea alveolaris is probable. The opsonic index is lowered in all forms of glycosuria and, according to Stengel, immunity to bacteria is lowered even in experimental cases.

Symptoms.—Great thirst; frequent micturition (polyuria); increased amount of urine and the excess of sugar in it; indicated by high specific gravity and analysis; excessive appetite; emaciation; dyspeptic symptoms; hypochondriasis; insomnia; skin diseases, as furunculosis, are common. The glycosuria in diabetes mellitus may account for the cervical caries seen in diabetics by introducing a factor in lactic acid fermentation, viz., glycogen (starch). (See Dental Caries.)

Peculiar Intrinsic Intoxications.—Without question, intense emotion results in the production of intrinsic intoxicants having some influence upon metabolism. A most notable example is the classic one of a mother, who, shortly after intense rage at an insult, nursed her child, with fatal result to it. In another case a child was poisoned by the milk of a wet-nurse who spent a night in debauchery (J. Lewis Smith). The causes were of slightly different classes, the *modus operandi* much the same. Intense anxiety also has a disturbing influence. The nervous influence no doubt alters metabolism, and the products act as poisons in a degree corresponding to their amount.

Acid Intoxication.—Many acids may be accumulated in the blood, producing the condition known as hyperacidosis or general hyperacidity. The accumulation is probably the result of an increased production by metabolism or the incomplete reduction to urea, etc., of normal, acid cell excreta. The condition probably arises as the result of gastro-intestinal disturbances or altered nerve influence, or the failure of function in an organ, as in diabetes in which acidosis exists. The acids are carbonic, lactic, sarcolactic, sulphuric, phos-

[1] See works on Practical Medicine.
[2] Stengel, A Text-book of Pathology.

phoric, uric, diacetic, and β-oxybutyric. The symptoms probably result from the acidosis rather than from any one acid.

Suboxidation always accompanies the condition. Some of the acids combine with the alkaline elements, and, therefore, reduce the normal alkalinity, while the acids left disturb metabolism, thus leading to further disturbances.

Gout.—Gout, or podagra, is a recurrent non-suppurative arthritis associated with the deposits of sodium biurate in the joints, and often with constitutional symptoms. It may be acute or chronic, by some thought always chronic, with occasional acute manifestation. It is largely hereditary or the result of inherited tendency to luxurious and indolent life.

The excessive rise of uric acid from proteid waste is held to be the cause of the presence of biurates of sodium, as mechanical irritants to the joints, in which, owing to increased age (thirty or over) and its tendency to lessened use of joints, a sluggish circulation with increased acidity of the fluids of the part favoring precipitation is established. The salts crystallize in the synovial tissue and excite inflammation. A slight excess of uric acid in the blood is sufficient if the local conditions are as stated. Ebstein claimed that degeneration or necrotic changes in the tissues cause the precipitation. The sluggish circulation leads in this direction. (See Venous Hyperemia and Calcareous Infiltration.)

The conditions leading to a rise of uric acid are many:

1. Richly cooked foods, especially proteid and sugar, with wines.
2. Sedentary life combined with the above, or overwork and underfeeding, with the use of malt liquors.
3. Chronic lead poisoning.
4. Defective elimination; the output in the urine is lessened just before the arthritis and increased after it. (Haig.)

Chronic Gout.—After an acute attack in one joint others may be attacked, and tophi (concretions of sodium biurate) form in the ear or nasal cartilages, joints, sheaths of tendons, etc. In some cases crepitation of the joints may be felt and heard. The joints may be distorted and enlargements by the tophi occur; the skin over them may be smooth and shiny, but not inflamed. The neighboring veins are prominent.

Constitutional Symptoms. — Complications. — Weakness, anemia, cachexia, digestive disturbances, dyspepsia, gastric and intestinal, with constipation, failing nutrition, deformity, inability to exercise mental irritations and dulness, granular atrophic kidney, cardiac hypertrophy and dilatation with arteriosclerosis, chronic gastritis, asthma, bronchitis, cerebral or other thrombosis, sciatica, eye-skin

lesions, obesity, diabetes, cholelithiasis, gravel, and vesical calculi. (Thompson.)

Goutiness.—(*Gouty Diathesis*).—This is the inherited or acquired condition underlying the acute and chronic forms of gout, or a tendency to gouty symptoms in parts other than the joints, as the vital organs, skin, and nervous tissues. According to Ewart, "in its functional aspect it is due to the *abnormal acidity of tissue juices*, while a delicacy of tissues is produced or inherited, causing *increased irritability and lowered resistance.*" The following diseases and symptoms may be associated as results, and in themselves show the force of Michaels' claim for a general hyperacid classification of individuals with these symptoms.

Fig. 52

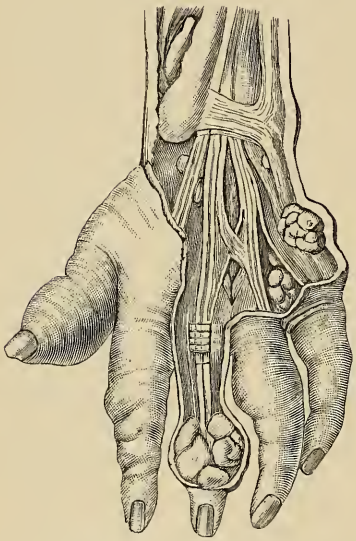

Tophi of gout. (Ziegler.)

Vascular System.—Arteriosclerosis, an increase of the fibrous elements of the arterial walls and indicated by their thickening and the high tension.

This induces overwork of the heart, resulting in cardiac hypertrophy, and this occurring in the coronary arteries produces failing nutrition of the heart and myocarditis with appropriate symptoms.

Respiratory System.—Asthma, emphysema, and obstinate recurrent bronchitis; bronchial catarrh in the young.

Genito-urinary System.—Uric acid sediment with hyperacidity, hematuria, urethritis, oxaluria, albuminuria, glycosuria in some cases, menstrual disorders, and uterine and ovarian disturbances.

Nervous and Muscular Systems.—Neuralgias, muscular soreness, lumbago, sciatica, bursitis, sore heels, hemicrania, or migraine, neurasthenia.

Digestive System.—Acid dyspepsia, acid eructation. Tongue may show glossitis or leukoplakia, gingivitis, suppurative tonsillitis (infection added), bilious headaches, chronic gastritis, colic.

Skin.—Harsh, dry, tending to eczema, pruritus, urticaria, erythema, acne, pityriasis, furunculosis, herpes, exfoliative dermatitis, perspiration acid. Early gray hair, alopecia. Nails have longitudinal striæ and are brittle.

Eyes.—Iritis, glaucoma, conjunctivitis. Lesions of retinal vessels, retina and optic nerve, keratitis and panophthalmitis.

These symptoms vary widely in different subjects.

The chief points of interest to the dentist, apart from diagnosis of goutiness, is the *peculiar tissue delicacy*, and the general hyperacidity as a cause. Without doubt this form of auto-intoxication (acidosis) in some cases leads to thickening of small arteries in the pericementum, leading to endarteritis obliterans, as shown by Talbot, and while not the only form of chronic gingival irritation, is probably one cause predisposing to gingival infection leading to the more complicated, persistent, and recurrent forms of pyorrhea alveolaris.

It may be regarded as established that goutiness may exist and lead to "declared" gout, or merely act as a chronic tissue irritant.

TREATMENT.—The accepted medical therapeutics of goutiness, which lies within the special province of the dentist, may well be given here.[1]

Diet.—Three moderate meals a day. Eating between meals to be avoided. Any meat, except pork, once a day only; fresh fish, eggs, lean ham or bacon, oysters or shell-fish at the other meals if desired; oatmeal, hominy, cornmeal, cracked wheat, stale bread and crackers, fresh green vegetables and potatoes, leguminous vegetables, apples, oranges, cream or other cheese as proteid, soups, tea and coffee in moderation, custard and gelatin preparations. Alkaline mineral waters, or plenty of plain water, before meals and at bedtime, or the tablets of lithium citrate or bitartrate may be taken dissolved in water. To be avoided are much meat, sweet dishes and confectionery, pastry, fried foods, pickles, spices, curry, cakes, griddle cakes, alcoholic and malt liquors.

Hygiene.—Brisk exercise in the open air to increase oxidation and elimination through the induction of perspiration, and Turkish baths if no organic disease as of the heart and kidneys exists, and then only as advised according to the advance of the disease. Daily cold bathing with brisk rubbing; wearing of woollen clothing. Sea bathing or medicated baths. The bowels should be kept freely open with cascara sagrada or aloes if necessary.

Special Therapeutic Indications.—For anemic and neurasthenic cases, Fowler's solution, with iron and cod-liver oil, or blood-making preparations.

For feeble digestion:

℞—Tincture nux vomicæ . . . . . ♏x
Compound tincture gentian or cinchona . . . . . f℥j
S—Take before meals.

[1] Acknowledgment in part to Thompson's Practical Medicine.

For constipation, cascara sagrada, aloes, Carlsbad water, thialion (a laxative salt of lithium).

For gastric catarrh with constipation and high vascular tension:

℞—Sodium sulphate 3j
S.—Take in a half-tumblerful of hot water one hour before meals, two or three times a day.

For persistent high vascular tension:

Nitroglycerin . . . . . gr. $\frac{1}{100}$ every three hours.

Or,

Sodium nitrate . . . . . gr. iij three times a day.

Or,

Chloral hydrate . . . . . gr. v three or four times a day.

Lithemia.—This is a condition occurring in individuals who overfeed, drink too little fluid, exercise little, and are under various nervous strains or overwork. A neurotic disposition and stimulants enhance the disturbances of nutrition.

Cold weather, adding to the above a lessened perspiration and increase of work by the kidneys, increases the difficulty. Tobacco and alcohol increase the ill effects.

There may be no symptoms of gout in even marked cases. There is acidosis with lithuria (uric acid in the urine) or oxaluria; eventually renal, vascular, and hepatic scleroses develop, together with liability to localized inflammation chiefly in serous membranes, as the pleura or synovia.

The hypothesis is that uric acid or some proteid toxin irritates the capillaries to contraction, thereby raising vascular tension, and by this twofold toxic and mechanical action causing arteriosclerosis, which in turn induces cardiac hypertrophy, sclerotic kidney changes, and vascular hepatic cirrhosis. It tends toward neurasthenia.

Symptoms.—Nervous Symptoms.—Vertigo, tinnitus aurium, insomnia, restlessness, burning or pricking sensation in the palms or soles, darting pains in the limbs, hebetude of mind, hypochondriasis, hemicrania, or diffuse basilar or frontal headache, general nervous irritability.

Digestive Symptoms.—Lost or capricious appetite; coated red or dry tongue, often fissured; aphthous ulcers, thirst, metallic taste in the mouth, pyrosis, hiccough, gastric oppression, nausea, gastralgia, vomiting, flatulence; constipation or irregular, dark-colored, frothy stool; palpitation of the heart (an hour or two after meals), hepatic tenderness.

Urine.—Scanty, dark, strongly acid, of high specific gravity, with often brick-dust sediment of urates. Perhaps temporary albuminuria; perhaps inflammation of urinary passage.

Skin.—Eczema, pruritus, urticaria or lichen.

Therapeutics.—The condition of life should be reversed as to previous eating and drinking, and exercise to avoid the overstimulation by proteid food waste and to increase elimination. Stimulants are to be avoided, sodium phosphate given for its action upon the liver in promoting the excretion of bile, and also for its mildly cathartic effect. It also furnishes an element for regeneration of nervous tissue, and renders the body fluids more alkaline. Lithium preparations are of little value. Potassium acetate, bicarbonate, and citrate are useful. The bowels are to be kept open. Headaches may be relieved by:

℞—Phenacetin . . . . . gr. xxxvj
Salol,
Caffein . . . . . āā gr. xxiv
M. and ft. capsulæ no. xii.
S.—A capsule three or four times a day.

For the neurasthenic cases treat with arsenic and glycerophosphates.

The diet is to be regulated as in goutiness. The use of much fat, meats, or carbohydrates is to be avoided, to lessen the necessity for oxidation and for work by the liver. The use of a largely vegetable diet, to render the body fluid more alkaline. Plenty of water between meals, to flood the system. Hygiene, rest, and exercise, as in goutiness.

Rheumatism.—Rheumatism is an acute fever, probably of infective origin, characterized by constitutional toxic symptoms, inflammation of the joints, muscles, serous membranes, skin, or even tonsils. It may be classified as acute, chronic, or muscular rheumatism.

Etiology of Acute Rheumatism.—It may be transmitted to the newborn, or a constitutional tendency to it may be inherited. It is most common to young adults (fifteen to twenty-five years), but no age is exempt. It is most common in males.

Climate, exposure to cold, injuries and overwork of parts, occupation inviting exposure to hardships, chronic alcoholism, nervous shock, debility, starvation, anemia, and chorea are other predisposing causes.

The exciting cause is supposed to be largely due to the Diplococcus rheumaticus, having its origin in some focus of infection, as the tonsil or gum margin. The streptococcus or pneumococcus may be absorbed from some focus of infection and produce metastatic joint inflammation similar to rheumatism and be isolated from the

blood or joints of rheumatic patients, but it is also induced by a diet of meat or the fermentation produced by overuse of sugar and starches, causing a rise of lactic or uric acid in the blood.

Clinical History.—It presents the following clinical difference from acute gout:[1]

	Acute gout.	Acute rheumatism.
Exciting cause	Often errors in eating and drinking.	Sometimes cold and damp.
First attack	Commonly in one great toe.	Commonly in large joints.
Later attacks	Both toes, fingers, knees, etc.	Rare in toes, often shoulder or hip.
Appearance of joint	Color dark red, shiny, and tense.	Lighter red.
Pain	Worse at night or early morning, localized.	Migratory from joint to joint.
Subsidence	Leaves thickening and deformity with repeated attacks.	Leaves normal joints.
Tophi	In lobes of ear, finger-joints, etc.	Never present.
Age and sex	Common in middle-aged men; very rare in children.	Common in young persons, children, and women.
Effect of treatment	Salicylates have but little effect; colchicum marked effect.	Salicylates have marked effect; colchicum no effect.

Symptoms.—Pain and inflammation of joint, which may be preceded by headache, indigestion, constipation, lassitude, muscular aching, chilliness, mild inflammation of tonsils, pharynx, and larynx. Tongue coated, pale, and indented by the teeth; breath foul. Fever 103° or 104° F., sometimes hyperpyrexia. Sweating during the height of convalescence, with acid odor from decomposition of fatty acid, but may be neutral or alkaline in parts of same person, therefore not an effort at elimination of acid.

Saliva.—Acid, excess of potassium sulphocyanid.

Urine.—Hyperacid, urates increased, chlorids diminished, uric acid abundant, sometimes albuminuria.

Heart.—Pericarditis and endocarditis in one-fourth of all cases.

Mind.—Clear except in hyperpyrexia.

Skin.—Urticaria, petechiæ, ecchymoses, purpura, eczema at times; subcutaneous nodules in youth.

Complications.—Conjunctivitis occasionally; chorea frequently.

Prognosis.—Uncertain as to period before recovery; relapses, or recurrence common.

Therapeutics.—Sodium salicylate and oil of gaultheria, internally, relieve the pains and inflammation. Cold baths to reduce the temperature. Blisters as counterirritants; protection from jarring by

[1] Thompson's Practical Medicine.

cotton and fenders; guaiacol with glycerin, oil of wintergreen, etc., as local lotions. The diet is much the same as in gout.

Chronic Rheumatism.—This form has much the same etiology, but is more common after the fortieth year. It appears in much-used joints, and is most common in females.

Morbid Anatomy.—Fibrous thickening and contraction produce moderate thickening and distortion of joints; atrophy of muscles about joints may occur.

Symptoms.—Symptoms are of slow onset; general health good unless inability to exercise produces alteration. Pain absent except when joint is overworked or in damp weather. The fingers may be deflected laterally and flexed by contraction of tendons. Febrile attacks, 101° F., occur from time to time, but the urine is normal.

Prognosis.—Disease progressive; no recovery, but temporary improvement by treatment so that the joints may remain quiescent for years. Never fatal.

Systemic Therapeutics.—Simple alkalies or alkaline waters, arsenous acid, 20 gr. t. i. d., cod-liver oil for debilitated and anemic, Carlsbad salts or sodium phosphate for constipation.

Local.—Drenching with hot (105° to 110° F.) and cold (70° F.) water alternately, followed by massage and wrapping the joint in flannel. Sweating in an inclosing box with hot air, 240° or 250° F., followed by Swedish movements. The lotions used for acute rheumatism are also used. The diet is much the same as for goutiness.

Muscular Rheumatism.—In this form of rheumatism the disturbance is in the muscles, with little constitutional disturbance. The essential lesion is probably an inflammation of the muscles, though the nerves may suffer.

Symptoms.—Local tenderness and pain increased by every contraction of the muscle. Pain stationary, worse by night and during barometric disturbances; oxaluria in some cases.

Scorbutus (Scurvy).—This is a subacute or chronic disease, characterized by inanition, anemia, and asthenia, with purpura and a tendency to swelling of the gums.

While of doubtful origin, defective hygiene and the use of improper foods, especially the lack of fresh vegetables and fruits, and the use of salted foods, the improper absorption of food owing to chronic intestinal maladies, as dysentery, or to cachexias, as in malaria, cancer, and syphilis, are the chief causes, though infection has been held to act upon those debilitated by the above causes. In young children it is due to the use of proprietary foods instead of fresh food, and appears mostly from the eighth to the twelfth month, rarely before the sixth or after the sixteenth month.

The circulation is feeble and the blood impoverished.

The gums are red and swollen, protrude over and between the teeth if present, and bleed; the breath is offensive, owing to putrefaction of the blood.

The stomach shows great irritability, and there is thirst and craving for acid foods.

The joints are swollen and painful, owing to the hemorrhages.

The urine is high colored; the acidity and temperature lowered.

Treatment.—As a prophylactic and cure, lime, lemon, or orange juice, together with the use of fresh vagetables and fruit in adults, or their juices in infants. Fresh milk modified, white of egg, and beef juice, or breast feeding, are to be substituted for proprietary foods or table feeding in infants.

Rachitis (Rickets).—This is a disease found in infants, developing typical deformities in the bones, and due to a deficiency of lime salts in them, in turn probably due to an absorption of that present, by hyperemic tissue present, and a diminution in the deposition of a fresh supply. There is usually, also, hypertrophy of the liver and spleen. The prolonged lactation of the child upon unfit milk, poor in fat, and the overuse of proprietary foods lacking the proper food elements, as farinaceous food or exclusively a condensed milk diet. The teeth develop slowly and are apt to be of faulty structure. The general line of treatment is much the same as for scorbutus.

Neurasthenia.—This is a condition of nervous exhaustion, no reserve nerve matter being held for even slight effort. It is often accompanied by nervous excitability, insomnia or disturbed sleep, apprehension, melancholia, failure of appetite, and feeble digestion.

Nervous energy is lost and irritability remains. It may be caused by continued excitement or overwork of the nervous system, and responds to rest, regulated diet, general tonics, treatment by glycerophosphates of lime and soda in the serious cases, while in mild cases exercise in the open air, baths, sea or mountain air, combined with the tonic treatment and abstinence from stimulants, effect a cure.[1] In view of demonstrations upon animals that nerve tissue is actually used up in nervous energy, the above treatment probably permits a gradual restoration of the elements of nerve tissue.

Oxaluria.—The increase of sodium and calcium oxalate crystals in the urine indicates:

1. That food rich in oxalic acid (as tomatoes or rhubarb) has been used in increased quantity.

[1] See Thompson's Practical Medicine.

2. That intestinal fermentation is existent and forming it from glucose. (Baldwin.)

3. That intrinsic increased production of oxalic acid by oxidation of uric acid, in turn derived from the purin bases of the nucleins, and nucleo-albumin of the tissues is present.

It frequently accompanies the increase of uric acid in the urine, and is regarded by Simon[1] as due to impairment of normal oxidation processes in the liver. Thus it may be found in goutiness and lithemia. It is also associated with dyspeptic and nervous symptoms, producing a condition known as oxalic acid diathesis. It also sometimes accompanies diabetes.

Continued oxaluria may result in the formation of calcium oxalate calculi. It is frequently associated with nervous irritability, hypochondriasis, and neurasthenia. Oxalates are found in the urine and saliva. (See p. 96.)

Phosphaturia.—The tribasic, phosphoric acid, H_3PO_4, is a normal product of metabolism, and like other acids combines with salts before elimination. Its alkaline combinations are sodium phosphate, Na_3PO_4; calcium phosphate, $Ca_2(PO_4)_2$; and magnesium phosphate, $Mg_3(PO_4)_2$, which may also be found in alkaline urine. Its neutral combinations are di-sodium hydrogen phosphate, Na_2HPO_4; calcium hydrogen phosphate, $CaHPO_4$; and magnesium hydrogen phosphate, $MgHPO_4$, all found in the blood and in neutral urine. Its acid combinations are sodium di-hydrogen phosphates, NaH_2PO_4, and calcium di-hydrogen phosphate, $Ca(H_2PO_4)_2$, found in acid urine, and to which the normal acidity is partly and chiefly due.

Ammonium magnesium phosphate ($NH_4MgPO_4+6H_2O$) or triple phosphate is also found.[2]

Many of the phosphates are derived from the food, but some are formed by proteid catabolism; one-third of all excreted is eliminated in the intestinal secretion; some are eliminated in the saliva, as shown by the formation of salivary calculi. In diseases requiring increased phagocytosis, as febrile conditions, the elimination of phosphates falls, the phosphates probably being utilized in the formation of leukocytes. The excretion is increased in diabetes and tuberculosis.

A very large increase in the total amount of phosphates eliminated (7 to 9 grams in twenty-four hours) is called phosphatic diabetes, and has been associated with four classes of symptoms:

(*a*) Cases with marked polyuria and marked nervous symptoms.

(*b*) Cases preceding or accompanying pulmonary diseases, especially tuberculosis.

[1] Simon, Clinical Diagnosis.

[2] Kirke's Physiology.

(*c*) Cases in which phosphaturia alternates with or coexists with glycosuria.

(*d*) Cases in which oxaluria, polyuria, and slight albuminuria are present, and in which some relationship with gout exists.

An increase in the amount of phosphates in the blood tends to the production of calculi.

As nerve tissue contains a considerable amount of lecithin or phosphorized fat essential to it, excessive drain upon this may result in a loss of this substance by catabolism, with loss of phosphates doubtless masked by the preponderance of phosphates derived from the food.

This is borne out by the beneficial use of glycerophosphates of lime and soda, rest, and general tonic treatment in neurasthenia. (See p. 110.)

Albuminuria.—The presence of albumin in the urine may be either (1) transitory, remittent, or cyclic (recurring with regularity), as the result of functional disturbances, as anemia, adolescence, in general malnutrition, after severe exercise or cold baths; or (2) due to organic disease of the kidney, as acute and chronic nephritis, renal arteriosclerosis, and amyloid degeneration of the kidhey; or (3) to fevers, as typhoid and yellow fever, and is due to the presence of bacterial toxin in the blood; or (4) to circulatory disturbances, as organic heart disease, or to local circulatory disturbances, as compression of renal veins by a pregnant uterus; or (5) to impeded outflow of urine; or (6) to hemic changes, increasing the diffusion of albumin, as in scurvy, leukemia, pernicious anemia, jaundice, and diabetes; or (7) to toxins in the blood other than febrile, as turpentine, salicylic acid, phosphorus, arsenic, etc., probably producing circulatory disturbances and irritation of glandular epithelium of the kidneys; or (8) to neurotic disturbances, as epilepsy; or (9) to ingestion of excessive amounts of cheese, eggs, and other albuminous food; or (10) to accidental admixture after urine excretion by the kidneys[1]

It is, therefore, like oxaluria and phosphaturia, more a symptom than a disease.

[1] Simon, Clinical Diagnosis.

Fig I

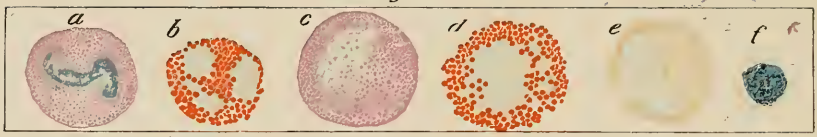

Fig II.

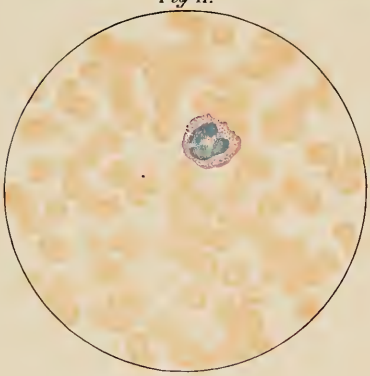

Fig III

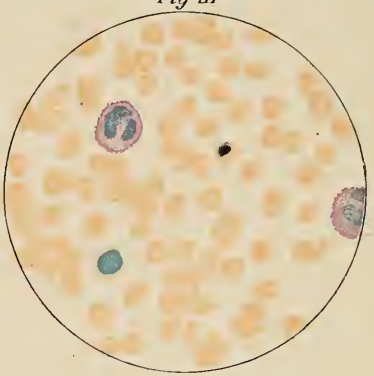

Fig IV.

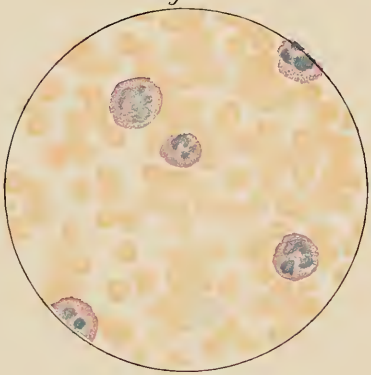

Fig.V.

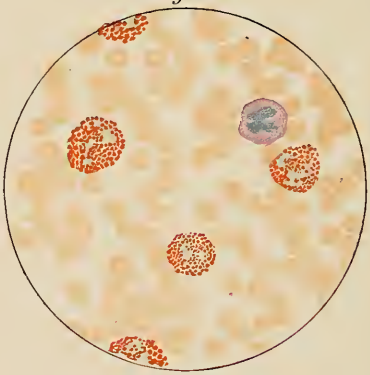

Fig VI.

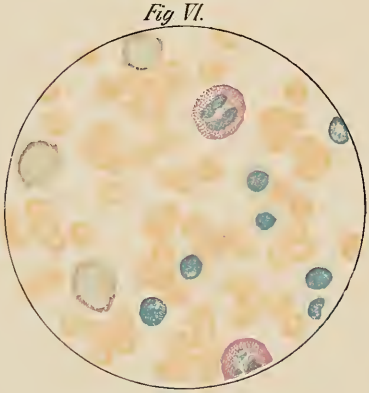

Fig.VII.

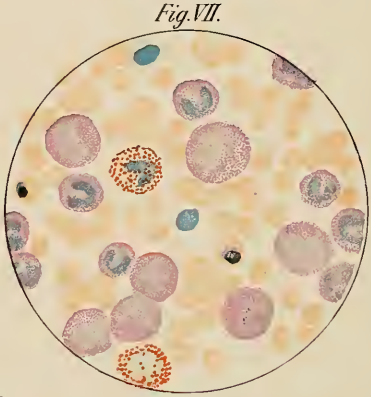

Fig.VIII



DRAWN BY J.N.Z. CHASE

BLOOD.

(Ehrlich triple stain.)

(Prepared by Dr. I. P. Lyon.)

Fig. I. TYPES OF LEUCOCYTES.

a. Polymorphonuclear Neutrophile. *b.* Polymorphonuclear Eosinophile. *c.* Myelocyte (Neutrophilic). *d.* Eosinophilic Myelocyte. *e.* Large Lymphocyte (large Mononuclear). *f.* Small Lymphocyte (small Mononuclear).

Fig. II. NORMAL BLOOD.

Field contains one neutrophile. Reds are normal.

Fig. III. ANÆMIA, POST-OPERATIVE (secondary).

The reds are fewer than normal, and are deficient in hæmoglobin and somewhat irregular in form. One normoblast is seen in the field, and two neutrophiles and one small lymphocyte, showing a marked post-hæmorrhagic anæmia, with leucocytosis.

Fig. IV. LEUCOCYTOSIS, INFLAMMATORY.

The reds are normal. A marked leucocytosis is shown, with five neutrophiles and one small lymphocyte. This illustration may also serve the purpose of showing the leucocytosis of malignant tumor

Fig. V. TRICHINOSIS.

A marked leucocytosis is shown, consisting of an eosinophilia.

Fig. VI. LYMPHATIC LEUKÆMIA.

Slight anæmia. A large relative and absolute increase of the lymphocytes (chiefly the small lymphocytes) is shown.

Fig. VII. SPLENO-MYELOGENOUS LEUKÆMIA.

The reds show a secondary anæmia. Two normoblasts are shown. The leucocytosis is massive. Twenty leucocytes are shown, consisting of nine neutrophiles, seven myelocytes, two small lymphocytes, one eosinophile (polymorphonuclear) and one eosinophilic myelocyte. Note the polymorphous condition of the leucocytes, *i.e.*, their variations from the typical in size and form.

Fig. VIII. VARIETIES OF RED CORPUSCLES.

a. Normal Red Corpuscle (normocyte). *b, c.* Anæmic Red Corpuscles. *d-g.* Poikilocytes. *h.* Microcyte. *i.* Megalocyte. *j-n.* Nucleated Red Corpuscles. *j, k.* Normoblasts. *l.* Microblast. *m, n.* Megaloblasts.

CHAPTER V.

DISTURBANCES OF THE VASCULAR SYSTEM.

A SUITABLE amount and quality of blood normally flows through the circulatory apparatus, and is in close relation to processes of nutrition.

The amount of blood in the vessels may be increased (plethora), though not permanently. It may be decreased rapidly in quantity, as by hemorrhage, or its red corpuscles may be gradually lessened in number (acute or chronic anemia). The proportion of white corpuscles to red ones may be increased abnormally (leukemia). The hemoglobin of red corpuscles may be deficient (chlorosis). Locally the amount of blood in a part may be increased (hyperemia or inflammation) or diminished (ischemia).

Normally the blood contains floating in the plasma 5,000,000 red corpuscles, or erythrocytes, and from 5000 to 10,000 (1 to 500 red) white corpuscles, or leukocytes, to each cubic millimeter. (See Plate, Fig. II.) A marked increase in the number of erythrocytes is termed polycythemia; a marked decrease, oligocythemia. The temporary increase in number of white corpuscles is leukocytosis; a persistent increase, leukocythemia or leukemia.

The blood corpuscles may be classified as follows:

			See Plate, Fig. 53	Fig. VIII
Erythrocytes (non-nucleated red corpuscles)	Normal to blood.	Normocytes (normal size)	1, 2, 3, 4.	*a*
	Pathological indicators.	Microcytes (small size)		*h*
		Macrocytes (large size)		
		Megalocytes (very large size)		*i*
		Poikilocytes (irregular form)		*d e f g*
Erythroblasts (nucleated red corpuscles derived from red marrow of bones)	Pathological indicators.	Normoblasts (normal size)		*j k*
		Microblasts (small size)		*l*
		Megaloblasts (large size)		*m n*

			See Plate, Fig. 53	Fig. I
Leukocytes (white corpuscles)	Normal to blood.	Lymphocytes (small)	22%	5 *f*
		Lymphocytes (large)	6 "	6 *e*
		Polymorphonuclear neutrophiles	70 "	7 *a*
		Polymorphonuclear eosinophiles	2 "	8 *b*
	Pathological indicators.	Basophilic leukocytes or mast cells.		
		Neutrophilic myelocytes from bone-marrow		*c*
		Eosinophilic myelocytes		*d*

FIG. 53

Normal blood (triacid stain): 1, normal red cell, flatly spread and evenly stained; 2, normal rouleau; 3, normal red cells varying slightly in size, thickly spread, showing central clear areas; 4, normal red cell, of slightly altered shape; 5, lymphocyte, medium size; 6, large mononuclear leukocyte, incurved nucleus; 7, polynuclear neutrophile leukocyte; 8, eosinophile leukocyte. Separate nuclear lobes. (Schmaus and Ewing.)

ANEMIA.

Anemia is a condition in which the blood is lessened in quantity or partly deprived of its essential constituents—*i. e.*, red corpuscles and hemoglobin—in consequence of which the tissues receive less oxygen and the general nutrition is impaired.

Acute Traumatic Anemia occurs as a result of copious hemorrhage. The individual becomes temporarily pale and weak. The arterial pressure is lessened, the circulation slowed, and the pulse is frequent and small. Recovery is, as a rule, prompt, the water being first restored and later the corpuscles being regenerated.[1] Frequent hemorrhages cause the blood to become watery and debility results from impaired nutrition. (See Plate, Fig. III.)

[1] Ziegler, General Pathology.

Symptomatic Anemia.—A diminution in the number of red corpuscles may occur as a result of protracted overwork, anxiety, study, or long-continued illness, such as a fever.

The number of red blood corpuscles may be reduced to one-half the normal amount, and there is a corresponding debility. The condition may disappear with appropriate removal of the cause.

Chlorosis.—This is a form of anemia occurring, for the most part, in girls and young women, and characterized by a great deficiency in the hemoglobin of the red corpuscles without a corresponding reduction in the number of the red corpuscles. In the watery blood very small red corpuscles (microcytes) are seen; also a few very large ones (macrocytes), and some of irregular outline (poikilocytes).[1] Myelocytes are occasionally seen. (Stengel.) The pathology is uncertain. If prolonged, the red corpuscles may sink in numbers to 3,000,000 or 2,000,000 per cubic millimeter and 20 per cent. of hemoglobin.

Being, as a rule, readily cured by a course of iron, it is inferred that the body is starved of iron, an essential constituent of hemoglobin. It is often associated with gastric disturbances, constipation, defective hygiene, and irregular habits, which apparently have a causal relation. The skin and mucous membranes are pale and have a slightly greenish tinge.[2] In recovery the number of corpuscles is first increased, then the hemoglobin.

Leukocytosis.—This is not a form of anemia, but a temporary increase in the number of multinucleated leukocytes, apparently derived from the lymphoid structures of the body in response to some demand for leukocytes. Thus it occurs after a full meal, in the later months of pregnancy, in acute fevers, in tuberculosis, and in conditions accompanied by suppuration.[3] Its presence during the course of surgical disease has been held to be diagnostic of pus formation[4]—*e. g.*, in abdominal surgery from 8000 to 20,000 per cubic millimeter. (See Plate, Fig. IV.)

Leukemia.—Leukemia is a disease characterized by a considerable increase in the number of white corpuscles of the blood, by a diminution in the number of the red corpuscles, and by enlargement of some of the lymphatic organs. The proportion of one white to ten red corpuscles is common (1 to 5 often, occasionally 1 to 1). The spleen may be hypertrophied (splenic leukemia). The lymphatic glands may be hypertrophied (lymphatic leukemia). In these latter cases the blood contains an excess of uninuclear leukocytes. It is rare

[1] Green, Pathology and Morbid Anatomy.
[2] Ibid.
[3] Ibid.
[4] Cabot, Boston Medical and Surgical Journal.

except when combined with other forms. When the marrow of bones is hypertrophied (myelogenic leukemia) large mononuclear leukocytes with neutrophile granules are found[1] (myelocytes) and the lymphocytes and polymorphonuclear forms are increased.[2] The blood contains toxic substances generated by the destruction of leukocytes, xanthin bodies, and acids (lactic, acetic). The urine frequently contains an excess of xanthin bases and lactic acid. (See Plate, Figs. VI and VII.)

Pernicious Anemia.—This is a comparatively rare but generally fatal disease, characterized chiefly by a great fall in the number of red corpuscles to one million or less per cubic millimeter, those remaining being altered in form and size and showing evidences of degeneration. The total hemoglobin is reduced, but the relative amount may be increased. Degeneration is shown by peculiarities of staining. Normal red corpuscles (normocytes), nucleated red corpuscles (megaloblasts), large nucleated red corpuscles (gigantoblasts), microcytes, and poikilocytes are found. The blood platelets and leukocytes are somewhat diminished.[3] The oxygen-carrying power is markedly lessened and all tissues suffer from malnutrition. The power of coagulation of the blood is lessened. Marked fatty degeneration of the heart muscles is apt to occur[4] as well as fatty changes in the kidneys and liver.

The causes are obscure, but gastro-intestinal disorders, intestinal parasites, pregnancy and lactation, hemorrhages, malaria, syphilis, tuberculosis, and infections are the chief causes supposed to produce it.

Aplastic anemia is a severe type of progressive pernicious anemia, in which the bone-marrow fails to develop myelocytes and erythroblasts owing to lack of marrow cells (hypoplasia of bone-marrow.)

COAGULATION OF THE BLOOD.

The blood when drawn from the body or in contact with a wounded surface of injured vessel wall undergoes a process of solidification called coagulation. The nature of the process is in some doubt, but it is now thought that the injury of white corpuscles, blood platelets and tissue cells liberates a ferment called thrombokinase, which with the aid of calcium salts converts the prothrombin in the blood plasma (thrombogen) into thrombin. This combines chemically with the fibrinogen of the plasma to form fibrin which takes the form of a

[1] Ziegler, General Pathology.
[2] Stengel, A Text-book of Pathology.
[3] Green, Pathology and Morbid Anatomy.
[4] Ibid.

network, in the open spaces of which the corpuscles are entangled (Fig. 54).[1] Coagulation may occur in the living vessel, as a thrombus, or in the interstitial tissue, as in inflammation and infarction.

Fig. 54

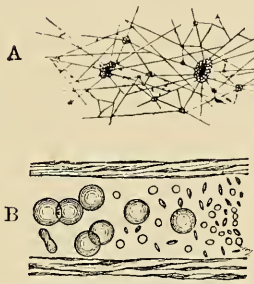

Fibrin filaments and blood tablets. *A*, network of fibrin, shown after washing away the corpuscles from a preparation of blood that has been allowed to clot; many of the filaments radiate from small clumps of blood tablets; *B* (from Osler), blood corpuscles and elementary particles or blood tablets within a small vein.

Thrombosis. — The formation of thrombi or clots within the living vessel may occur in the heart, arteries, veins, or capillaries. If the blood stream be somewhat retarded, an increased number of white corpuscles and blood platelets occupy the peripheral zone and

Fig. 55

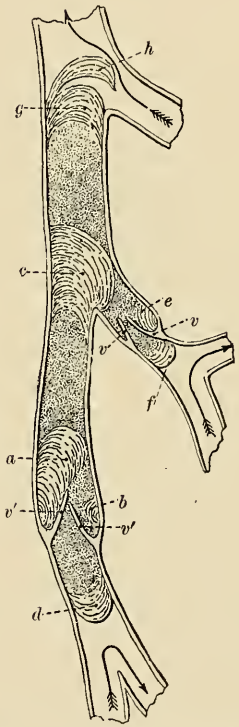

Diagram to show phenomena of venous thrombosis: *v*, *v*, valves of veins; *a*, *b*, primary thrombus (white); *c*, *d*, *e*, *f*, *g*, secondary white thrombi connected with primary white thrombus by various red thrombi; *h*, piece of white thrombus becoming detached by blood current. (Green, modified from Thoma.)

Fig. 56

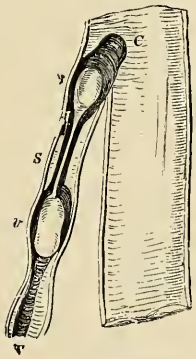

A thrombus in the saphenous vein, showing the projection of the conical end of the thrombus into the femoral vessel: *S*, saphenous vein; *T*, thrombus; *C*, conical end projecting into femoral vein. At *v*, *v*, opposite the valves, the thrombus is softened. (Virchow.)

[1] Howell, Text-book of Physiology.

adhere to the vessel wall. If the vessel wall be injured, the blood platelets become attached to it. With these platelets the white corpuscles and sometimes the red become deposited. Fibrin forms and the corpuscles are included. The thrombus is red when red corpuscles are included in it; white when only white corpuscles are present. The causes of thrombosis are these: (1) a retardation of the blood current at some point from some cause; (2) local changes in the walls of the vessels and (3) probably pathological changes in the blood.[1]

Fig. 57

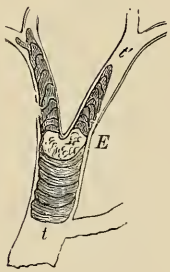

Embolus impacted at the bifurcation of a branch of the pulmonary artery, showing the formation of thrombi behind and in front of it, and the extension of these as far as the entrance of the next collateral vessels: *E*, embolus; *t*, *t'*, secondary thrombi. (Virchow.)

Fig. 58

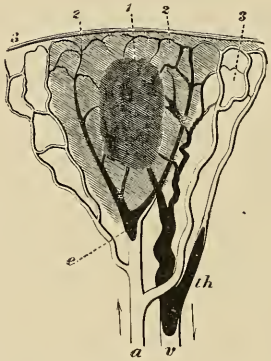

Diagram of a hemorrhagic infarct: *a*, artery obliterated by an embolus (*e*); *v*, vein filled with a secondary thrombus (*th*); 1, centre of infarct which is becoming disintegrated; 2, area of extravasation; 3, area of collateral hyperemia. (O. Weber.)

Older thrombi are firmer than those recently formed. Thrombi are also formed in the capillaries, a circumstance which favors the spontaneous cessation of hemorrhage. They may form in the vessels in inflammation. Remaining in the situations in which they were formed, they either undergo simple or puriform softening or are calcified, or are resorbed and replaced by connective tissue. (See Regeneration.) The calcified varieties are called phleboliths in the veins; arterioliths in the arteries. In senile gangrene a thrombus may extend a great distance.

Embolism.—Portions of the softened varieties of thrombi may become detached and float about in the blood; these are called emboli. Other foreign substances may act as emboli—*e. g.*, air or fat globules. In important parts it may cause local anemia, necrosis, or slow or rapid death.

[1] Ziegler, General Pathology.

If the thrombus be septic, as in the case of puriform softening, the emboli may lodge in small vessels and cause secondary septic disease processes, as, for example, in the cases of pyemia accompanied by infarctions.

Infarction.—When an embolus occludes a terminal artery, that is, an artery whose branches spread like those of a tree without anastomosis, the part first becomes ischemic, but soon the backward pressure from the vein upon the blood in the capillaries causes an extravasation of blood into the interstitial tissue of the wedge-shaped area, forming what is called a hemorrhagic infarct. A clot forms, degeneration of the clot occurs, and if aseptic it is absorbed and replaced by connective tissue (see Regeneration); if caused by a septic embolus, it may be involved in the resulting septic process—*e. g.*, in pyemic metastatic abscess. Infarcation has been held by Black to occur in the dental pulp. A demonstration has been made by Hopewell-Smith. (See Diseases of the Pulp.) (See Fig. 58.)

Hemorrhage.—By hemorrhage is meant the escape of blood from the vessels. It may be arterial, venous, or capillary. If the vessel is ruptured, it is *hemorrhage by rhexis*. If it occurs by diapedesis, as in infarction (from veins and capillaries only), it is *hemorrhage by diapedesis*. The diapedesis occurs through the capillary wall rather than the stomata; pressure is the cause. Hemorrhage usually ceases *spontaneously* through thrombosis.

If hemorrhage occurs into the tissues it receives the following designations, the escape itself being called an effusion or extravasation:

Ecchymosis, an effusion of moderate extent into tissue beneath a surface, as into subcutaneous tissue.

Petechia the same, but small and circumscribed; when an extensive area is involved it is termed a suffusion.

Infarction, when the area involved is that supplied by terminal and non-anastomosing arteries.

Hemorrhage involves an injury to vessels by traumatism, or disease rendering them incapable of retaining the blood, or by increased pressure, as in violent exertion, or in congestion of local vessels, as in venous hyperemia, or as the result of diminished atmospheric pressure, as in high altitudes. The extravasated blood corpuscles may be disintegrated into pigments (see p. 88), and be absorbed or deposited in the tissues, as in a bruise; or excite inflammation or cyst formation (extravasation cyst). Acute hemorrhages or repeated extravasations lead to anemia (which see).

Hemorrhagic Diathesis.—This is a condition, largely hereditary, in which coagulation does not close wounds readily, and ordinarily

trivial wounds may, in spite of surgical aid, induce death by hemorrhage. Hereditary hemorrhagic diatheses (hemophilia) is usually transmitted through the female to the male descendants—*i. e.*, from grandfather to grandson through the grandfather's daughter—and seven or more generations of hemophiliacs have been recorded.[1] Males suffer more than females in the ratio of about 11 to 1.

In a family of 207 members, in four generations, 37 were hemophilics, all of the male sex; almost half died from hemorrhages, usually in infancy, while the tendency to bleed lessened as they grew older.[2]

According to Legg,[3] "It is of three degrees of severity:

"1. Characterized by external and internal bleedings of every kind, and by joint affections.

"2. By spontaneous hemorrhages from mucous membranes, but no traumatic bleeding or ecchymoses, and no joint affections.

"3. A tendency simply to ecchymoses. The first seen most frequently in men, the second in women; the third may appear in either sex."

The joint affections are due to hemorrhage, and simulate rheumatic affections. Hemophiliacs are apt to be thin-skinned, neurasthenic, and liable to sudden flushings and vasomotor disturbances.[4] Blondes suffer more than brunettes.[5]

The injured part may bleed from the first, or a normal clot may form and secondary hemorrhage or capillary oozing occur. Death may rapidly occur, or the patient bleed to fainting or until almost dead, and hemorrhage then cease. This may require any period, even weeks. One case is said to have continued for a year.[6]

The pathology of the condition is uncertain. Fillebrown[7] reports a fatal case in which the arteries were excessively thin. Porter points out that the blood may clot in the receptacle, yet not in the small vessels of the wound, and infers that some hereditary deficiency exists which interferes with the action of the vasoconstrictors.

Hemophilics usually manifest a history of bleeding before puberty, and hemophilic infants have died from hemorrhage due to gum-lancing, circumcision, etc. Certain surgical cases in which secondary hemorrhages have been due to the action of the continuous use of acetanilid have been reported. The therapeutic measures indicated are hemostatics internally, local styptics, compresses, etc. Potassium permanganate, made into a paste with vaselin, is recommended as a

[1] Porter, International Dental Journal, 1900.
[2] Losser, International Journal of Surgery.
[3] Musser, Medical Diagnosis.
[4] Porter, Loc. cit.
[5] Thompson, Practical Medicine.
[6] Scott, Dental Cosmos, 1912, p. 60.
[7] International Dental Journal, 1900.

styptic. A solution of calcium chlorid, gr. xxx, and water, ℥j, has been used on cotton with satisfaction.

In case of tooth extraction reimplantation has been urged, but must be done under aseptic precaution, as any infected dead pulp or even a root infected by contact with the hands, saliva, etc., may substitute a condition almost as bad as the hemorrhage.

In a severe hemorrhage upon the palate, as after lancing an abscess, finger pressure may be used, or, if necessary, a vulcanite plate may be made to produce the necessary pressure.[1]

Sodium sulphate, gr. iss, every two hours, has been of service in marked hemorrhages.[2]

The following is useful:

℞—Calcii chloridi . . . . . gr. lxxv to cl
Syrupi menthæ . . . . . ℥v
Aquæ destillatæ . . . . . f℥iiiss—M.

Tablespoonful doses or a clyster containing 75 grains calcium chlorid and a few drops of tincture of opium.[3]

For persistent postextraction hemorrhage, Endelmann has recommended:

℞—Vini ergotæ, U. S. . . . . f℥ij
Sig.—Teaspoonful every two hours.

Dilute sulphuric acid and hydrastis canadensis are used, also gelatin locally and by injection.[4] The gelatin may contain tetanus spores and should be sterilized for forty minutes or longer at 100° or 120° C.[5] Suprarenal extract, gr. xx to ℥j, topically, gr. x by mouth, every four hours, is also useful. Absolute quiet and the withholding of food for two days; the hunger to be relieved by small doses of opium and thirst by iced water in small quantities.[6] The acute anemia induced requires treatment.

Individuals known to be hemophilic should live a hygienic life and avoid all injuries, however slight, possible to avoid, in the hope of an eventual outgrowing of the condition. If operation be unavoidable, they should be treated with calcium chlorid, gr. iij *ter in die*, for not more than four days, as thereafter the coagulability of the blood is decreased.[7] Much larger doses, gr. xxx to ℥j, have been satisfactorily given for cure and prevention.[8] Scott states three cases in which it was of no value, and suggests strontium lactate 15-grain dose to be used by the patient. Calcium lactate, first dose 20 grains, five

[1] Joly, see Dental Cosmos, 1909, p. 488.
[2] Reverdin, Dental Cosmos, February, 1904, p. 162.
[3] Rosod, New York Medical Journal.
[4] Hare, Practical Therapeutics.
[5] Journal American Medical Association.
[6] Porter, loc. cit.
[7] Hare, loc. cit.
[8] See Dental Cosmos, 1908, p. 185.

grains each hour thereafter, increasing to 20 grains, was successfully used by C. F. Jones in a case lasting several weeks.[1] P. Emile Weil has suggested the injection of 20 c.c. of fresh human, horse, or rabbit serum before operation, for the prevention of hemorrhage in hemophilics, or every three months as a curative measure.[2] Dr. E. W. Scott[3] reports the use of 30 c.c. of normal serum by large hypodermic syringe as immediately curative of a hemorrhage lasting two and a half days after extraction, and 20 c.c. as curative in three to four hours in a case of stab wound. Both were blacks. The back was selected as the site of injection. To obtain human serum he suggests a willing volunteer, not a black or relative, a large blister to be raised.

LOCAL DISTURBANCES OF THE CIRCULATION.

The amount of blood in a part may be increased or diminished. The types of local disturbance of the circulation differ as to causes, phenomena, and effect, and as to the indicated treatment for each.

In health the bloodvessels are maintained at a proper caliber through the action of two sets of vasomotor nerve fibers:

1. The vasoconstrictors, which control the involuntary muscles of the vessel wall, and which, when stimulated, cause contraction of the vessel.

2. The vasodilators, which, when stimulated, inhibit the muscular action and permit dilatation.

Ischemia.—This is local anemia. The quantity of blood in a part is less than normal. It is *direct* when some cause obstructs the flow from an artery into a part, as when pressure of any sort is applied directly to a part or to the artery leading to it, or when an injection of fluid has been made into a part, as in cocain injections. Disease of an artery may deprive a part of blood, as in thrombosis or arteriosclerosis. Anastomotic circulation may eventually relieve a part; if not it remains pale and cold, atrophies, and may undergo degeneration or necrosis. An infarct may remain ischemic.

Arterial Hyperemia.—Arterial or active hyperemia is a more or less prolonged increase in the amount of blood in the dilated arteries of a part. It expresses the reaction which occurs as the consequence of the presence of an irritant, the action of which lessens the arterial tension and permits dilatation with a consequent excess of blood.

Etiology.—The lessened arterial resistance is produced either by a stimulation of the vasodilator nerves or a sedation or paralysis of the

[1] New Jersey Dental Journal, October, 1913.
[2] Dental Cosmos, 1908, p. 436.
[3] Ibid., January, 1912.

vasoconstrictor nerves. Certain causes act to produce constriction of the vessels, but later the muscle cells of the walls are fatigued and dilatation results—*e. g.*, the reaction after the prolonged application of cold.

The removal or diminution of pressure, to which vessels have become accustomed, is also a cause of their dilatation; often sudden enough to cause bursting.

Irritants and mild injuries act upon the sensory nerves of a part, and by reflex action through the vasomotors (sympathetic system) produce hyperemia of the part itself—*e. g.*, heat as a cause.

Irritation of sensory nerves may induce a reflex hyperemia in other parts to which branches of the same nerve are distributed—*e. g.*, the peripheral hyperemia of neuralgia, induced by irritation of a tooth pulp.

A similar effect may be produced in deep-seated organs to which other nerves are distributed—*e. g.*, hyperemia of deep organs through the application of irritants to the skin over them or hyperemia of the intestinal wall (tenth nerve) as the result of the stimulation of a pulp underlying an erupting tooth (fifth nerve).

Collateral hyperemia is induced by the diminished flow of blood to other parts—*e. g.*, by the bandaging of parts or through the chilling of the surface of the body. A part having a lessened resistance may become hyperemic.

Compensatory hyperemia may occur through the removal of one of a pair of organs; the other receives the excess of blood, sometimes becomes hypertrophied, and takes upon itself an increased amount of work. (See Hypertrophy.) A physiological hyperemia occurs in organs during periods of activity, the work required acting as a stimulus to the vasomotor nerves.

Arterial hyperemia is produced as the first step in the process of inflammation, but can be independent of it. (See Inflammation.)

Pathology.—The arteries are dilated; there is an increased flow of blood through them and also to them through their own nutritive arteries; the pressure in the veins rises as the veins are enlarged to accommodate the blood. As exudation sometimes does not increase markedly, the lymph pressure is not increased except in marked cases, in which some edema may occur. The function of the part may be disturbed in the more marked cases. (For illustrations, see Hyperemia of the Pulp.)

Results.—Continued arterial hyperemia, as a rule, results in an increase of nutrition, even to the arteries themselves via the vasa vasorum. The arteries may be permanently enlarged, their walls thickened, and the tissues about them hypertrophied in consequence

of the increased capacity for work in the part. Hyperesthesia of nerves and nervous tissue is often a result. In marked hyperemia with function altered there is a tendency to the degenerations. (See Arterial Hyperemia of the Pulp.)

Symptoms.—These naturally would be and are increased redness, temperature, and sensibility; more or less throbbing in marked and pathological cases, in some cases swelling and throbbing pain. The increased temperature is due to the increased oxidation. (See p. 131.)

Degrees of Hyperemia.—It is to be borne in mind that the hyperemia may be of several grades, varying from a very mild exaltation of function and sensation to a distinctly pathological condition with altered function. The effects may be constructive in character or destructive, the former due to the increased nutrition, the latter to interference with it. (See Constructive and Destructive Diseases of the Pulp.)

Hyperemia as a Resistance to Infection.—According to Biers and others the induction of hyperemia in an infected part increases the opsonic power of the excess blood, and therefore is antagonistic of infection. No doubt this is the natural process in inflammation. It has been occasionally noticed that stimulation, as in the use of a capsicum plaster in acute apical abscess, has produced resolution. Usually confined abscessses are enlarged and not cured by such stimulation.

Therapeutics.—The principle underlying the treatment is to remove the cause and procure surgical rest. The symptoms, as a rule, then subside promptly. It may be that the conditions require treatment irrespective of the cause, which may not be determined or be absent, the vessels being dilated as the effect of a previously acting cause. The effect aimed at is the reduction of the dilated vessels. This is attempted at times through the use of drugs; for example, ergot stimulates the vasoconstrictor system and lessens the caliber of all the vessels, including those affected. Aconite, the antagonist of ergot, reduces the heart action by sedating the motor apparatus of the heart, thus reducing the arterial pressure.[1] Less blood is delivered to a part in a given time. Many cases of superficially seated hyperemia are amenable to local treatment.

Local sedation of sensory nerves and contraction of vessels are produced by application of dry or wet cold (ice bags, ice wrapped in muslin, cloths taken in succession from a block of ice, the Leiter coil, etc.); also by the application of sedative astringents, as the liquor plumbi subacetatis in the well-known formula of lead-water and laudanum:

[1] Biddle, Materia Medica and Therapeutics.

℞—Tincturæ opii . . . . . f℥j
Liq. plumbi subacetatis . . . . . f℥j
Aquæ . . . . . Oj—M.

in which to the astringent effect of the lead is added the sedative effect of the opium; if cold sedation and contraction are added.

The principle of derivation is also employed. What is known as counterirritation is a common means of treatment. An irritant such as a mustard plaster or a blister or dry cup applied at a distance to the affected part induces a flow of blood to the point of application and lessens the amount of blood in the area of hyperemia. The volume of the blood being in definite amount, if an excess exists in any part a deficiency will be found in other parts.

The hot pediluvium acts upon this principle by drawing a considerable excess of blood into the vessels of the lower extremities. This action is increased by adding a small quantity (two or three tablespoonfuls) of mustard to the hot water. It is suggested by Endelmann that the water be at first only warm and the hot water added as the vessels relax.[1]

FIG. 59

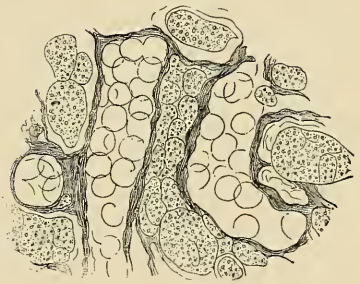

Venous hyperemia of the liver. Two capillaries near central hepatic vein, showing the thickening of the walls and the accumulation of red blood corpuscles within them. × 500. (Green.)

The volume of the blood may be actually reduced and a derivative hyperemia of the sweat glands be produced by the use of diaphoretics. Cathartics lessen the blood volume and cause mild hyperemia of the alimentary canal. Diuretics act in a similar way upon the kidneys. In deep-seated hyperemia counterirritation is valuable alone or conjoined with other forms of derivation.

Venous Hyperemia.—Venous (mechanical or passive) hyperemia is an excess of blood in a part beginning in the veins, which are dilated in the hyperemic area, though they may be occluded between it and the heart.

Etiology.—1. Any mechanical interference with the passage of the blood through the veins on its way to the heart—*e. g.*, the action of bandages, tumors pressing on veins, thrombi in veins, etc.

2. Insufficiency of any of the mechanical forces aiding the propulsion of the blood through the veins—*e. g.*, diminished cardiac power or valvular insufficiency; obstructions, dilatations, or rigidity

[1] Dental Cosmos, 1904.

of arteries; insufficient muscular contraction upon or valvular incompetency in veins, or lessened or excessive thoracic aspiration, etc. The second class of causes produces a collection of blood in the veins and a consequent reduction of volume in the arterial system.

Pathology.—The veins are dilated, the current is slowed, and the intravenous pressure is increased, in consequence of which watery (serous) exudations occur in the parts about them (edema). For the same reason in marked cases diapedesis of red corpuscles may occur (hemorrhage by diapedesis), and their hemoglobin may be dissolved out. The blood in the parts not being sufficiently changed, and in some cases in a state of stasis, there is a lessened food supply and waste removal, and cell nutrition suffers accordingly. Vital processes are lessened, secretion is diminished, there is less oxidation, and hence less heat is produced and less work is done. Fatty degeneration, atrophy, and in markedly continued cases necrosis may occur. Long-continued venous hyperemia with great intravenous pressure may produce dropsies. If the walls of the veins are weak and are permanently distended or thicken under pressure and become tortuous, the condition is called varicosity of the veins (varicose veins). The exudate of venous hyperemia differs markedly from that of inflammation.[1]

Hyperemic Exudate.	Inflammatory Exudate.
Poor in albumin.	Rich in albumin.
Rarely coagulates in the tissue.	Usually coagulates in the tissue.
Contains few cells.	Contains numerous cells.
Low specific gravity.	High specific gravity.
Contains no peptone.	Contains peptone (product of cell disintegration).

This is probably due to an increased permeability in the vessel wall in inflammation permitting the albumin of the blood to pass through.

Therapeutics.—The treatment consists of the removal of the mechanical obstruction to the return of the blood and mechanical support of the engorged vessels, with a view to recovery of the tone of their muscular walls. This latter is accomplished by means of elastic bandages or compresses, and in situations in which these cannot be used astringents may be employed. The part is elevated, when possible, to aid in the return of the blood to the heart. In certain circumstances, as in an engorged tooth pulp, actual depletion of the engorged part must be resorted to by bloodletting. (See Destructive Diseases of the Pulp.) In cases due to failure of blood-propelling forces these are to have appropriate treatment.

[1] Park's Surgery.

INFLAMMATION.

Inflammation may be defined as a series of hyperemic changes expressive of the reaction of living tissue to irritation, and characterized chiefly by an excessive diapedesis of leukocytes and exudation of coagulable lymph from the bloodvessels.

Etiology.—Any irritant or injury capable of producing a lesion of the bloodvessel wall not involving its immediate death can produce inflammation. In case direct death is produced, the inflammation, if any, occurs in the tissue contiguous to the dead part.

The causes of inflammation may be divided first into non-septic and septic or infective. The non-septic causes may be extrinsic or intrinsic. The extrinsic non-septic causes are: (1) Physical irritants, such as violence, mechanical irritation, pressure or traumatism, excessive heat or cold, and electrolytic action. (2) Chemical irritants—*e. g.*, the action of acids, caustics, etc. (3) Nervous or vital irritants—*e. g.*, rubefacients, epispastics, arsenic, etc. These act only on living tissue through the medium of the nerves.

An intrinsic non-septic cause may produce inflammation—*e. g.*, urates in tissue, mechanical strains upon tissue, temporary lack of blood in a vessel or central nervous disturbance, as in herpes from locomotor ataxia.

Non-septic causes, as a rule, produce only such mild inflammatory phenomena as are concerned in circumvallation of an irritant, absorption of it, and in repair or production of new tissue. No pus is produced unless pyogenic bacteria gain ingress. This class of inflammation is termed *simple inflammation.*

Septic or Infective Causes.—These are fungi or their products, and the classes of inflammations produced are much more severe, continuous, and destructive in their nature, and are termed *infective inflammations.*

Pathology of Simple Inflammation.—If to the web of a frog's foot tincture of capsicum be applied, or if its mesentery be exposed to the air, and either be examined under the microscope while the animal is living, it is noted that after a possible short period of contraction of the arterioles dilatation of arteries at once begins and is gradually followed by dilatation of the veins and capillaries. This continues to steadily increase for about twelve hours. During the first hour of this period the blood current is accelerated and the first stage of an inflammation is thus an *arterial hyperemia.* Following this acceleration the blood flow is increasingly retarded. The retardation is due to the action of the leukocytes, large numbers of the mononuclear and polymorphonuclear forms of which fall out of the central

blood stream into the periaxial stream and collect along the walls of the small veins (Fig. 60, *b*). Several layers of leukocytes may thus form. Probably some peculiar attraction exists between the leukocytes and the wall of the vessel, or a positive chemotaxis exists as in infective inflammation.

This massing of leukocytes compels the red corpuscles to the centre of the stream (Fig. 60, *a*), and their passage is mechanically interfered with; thus the further dilatation of the vessel becomes a process of *venous hyperemia*. The vessels are increased in size and length and become more tortuous. Pulsation is noted.

Fig. 60

Small vein in mesentery of dog, after exposure for half an hour and irrigation with salt solution: *a*, red corpuscles; *b*, leukocytes adhering to wall of vein; *c*, red corpuscles; *d*, leukocytes which have escaped from vessel; *e*, leukocyte in act of escaping; *f*, fibrous tissue. × 340. Modified from Thoma. (Green.)

Coincident with retardation of the blood flow, the leukocytes are seen to work their way by an ameboid movement through the walls of the veins and to some extent of the capillaries into the perivascular spaces—*i. e.*, into the adjoining tissue—in which they may move far from their point of escape and mass about the irritant if one be present. This process is called emigration (Fig. 60, *e*). At the same time a fluid rich in albumin, and thus capable of coagulation, escapes by the same route into the tissue (Fig. 61). Some red corpuscles also escape through the walls (diapedesis) (Fig. 60, *c*). (While inflammation involves an arterial hyperemia as its first stage and

a venous hyperemia as its second stage, these two conditions are not necessarily inflammation, and may exist as entirely distinct conditions when produced by causes not leading to inflammation; also, it must be remembered that the results of venous hyperemia or infarction, *e. g.*, extravasation, may lead to a subsequent inflammation. This does not make them identical.)

As the venous hyperemia of the inflammation increases, the flow of red corpuscles in the veins is increasingly retarded until stopped, when a to-and-fro motion (oscillation) begins. Finally all motion ceases, diapedesis ceases, and stasis is complete. This blood may remain fluid in the vessel for several days (*i. e.*, without coagulation), and if the blood flow be reëstablished the separate red corpuscles are seen one by one to roll away from the general mass until all are in movement and stasis ceases. (Thoma.)

Coagulation (thrombosis) may, however, occur in the vessels involved in the stasis, and the part be later removed through the process of resorption. (See Resorption of Clot.) With the inflammation fully established there are in the tissue the following elements: (1) Leukocytes and some red corpuscles and lymphocytes from the tissue lymphatics. (2) Coagulable lymph. (3) Later new embryonic cells formed by mitosis from preëxisting connective-tissue cells which surround the leukocytes massed about the irritant. These are fibroblasts ready to form scar tissue—*i. e.*, they are the elements composing granulation tissue.

The disposition of these elements of inflammation is as follows: The leukocytes mass about the irritant, exert a certain amount of phagocytic activity (ferment action), and may in turn be injured, liberating fibrin ferment, which, acting upon the fibrinogen of the lymph, produces fibrin, which in turn forms a coagulum. This coagulum blocks the lymphatic vessels leading from the part involved, thus causing a retention of fluid in the tissue.

Fig. 61

Inflammatory edema of skin. The large spaces shown were filled with exuded fluid. × 2.5. (Boyd.)

In the later stages of non-infective inflammation the tissue cells undergo multiplication, forming cells larger and having more power of ameboid movement and phagocytosis than the leukocytes. These become mingled with the leukocytes in the area of inflammation. They are fibroblasts from which all the connective tissues develop, and to the action of which regeneration is mainly due. Around and about the focus of inflammation the bloodvessels are in a condition

of arterial hyperemia, and about this is an area of normal tissue. These areas shade off into each other.[1] The phagocytes cause dissolution of coagula and dead aseptic tissue, and remove them. If the irritant be thus removable it is eaten away. If the dead tissue be superficial, the connection with the living tissue beneath is eaten through and the latter thrown off. If the superficial tissues have been previously removed, the wound is covered with the exudates and leukocytes, which dry into a scab, beneath which regeneration occurs. If inflammation occur in a mucous surface, the exudate and

FIG. 62

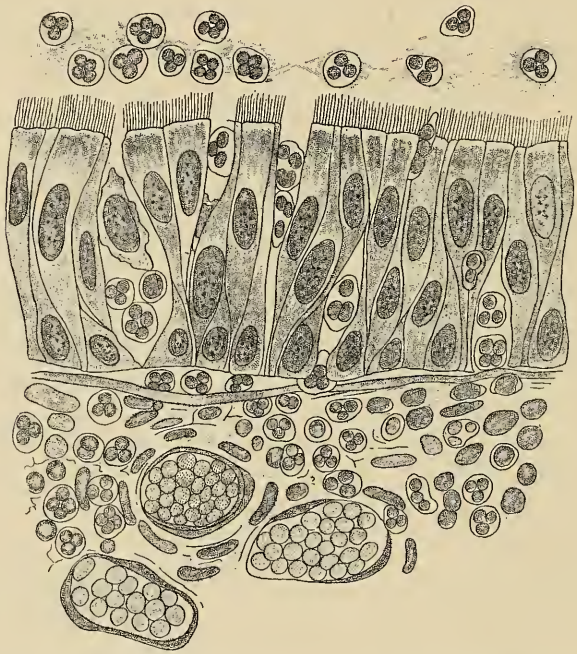

Acute bronchial catarrh: Passage of leukocytes through the epithelium of the bronchus between the ciliated cells. × 700. (Thoma.)

corpuscles escape from the submucous tissue between the epithelial cells as a catarrhal discharge (Fig. 62). If the inflammatory exudate be highly coagulable and coagulate, firm swelling is caused, apt to lead to organization of tissue, hence called fibrinous inflammation. If it be productive of hypertrophy, it is called productive inflammation. If the exudate be watery, poor in albumin, and hence not

[1] Fig. 64 serves to illustrate these areas, excepting the fact that the central area of pus is absent and occupied entirely by an area there termed lesser inflammation—*i. e.*, translate lesser inflammation into simple inflammation.

readily coagulable, the inflammation is called serous inflammation. In the later stages of simple inflammation the coagula are dissolved, the leukocytes undergo fatty degeneration, and both are absorbed, together with such tissue as has undergone liquefaction. The lymphocytes and embryonic cells push into the area and regenerate the tissue. This is the phenomenon of resolution.

Symptoms of Simple Inflammation.—These are:

1. *Redness* due to the excess of blood in the vessels and in the tissue. In some cases the part may have a dusky hue. The color is deepest in the area of greatest stasis.

2. *Heat* due to the increased oxidation in the area of hyperemia about the area of stasis. It has been shown that there is no increased heat in the area of stasis. In this area chemical action is lessened.

3. *Swelling* due to the excess of blood in the vessels, the exudates of leukocytes and fluid, and the multiplication of tissue cells. The hardness of a swelling is due to coagulation of the fluid exudate.

4. *Pain.*—The result of the pressure of the effusion upon sensory nerve terminals; it is frequently throbbing in correspondence with the heart beat; the impulse causes temporarily increased pressure upon the nerve terminals. Gravitation also increases the pressure and pain in a dependent part—*e. g.*, in a hand or foot or in recumbency in case of pulpitis (which see).

5. *Impaired function* is an evident result of a disturbance involving such pathological phenomena as have been described. The part cannot be used owing to pain and stiffness due to the swelling, also nutrition of any part being impaired, it loses its normal function.

There are no general disturbances in simple inflammation beyond a slight traumatic fever due to absorption of some aseptic material from the seat of inflammation—*e. g.*, fibrin ferment.[1] There may, however, be general disturbance due to pain, loss of sleep, appetite, etc. Shock due to widespread inflammation, as from burns, may be serious.

Infective Inflammation. — If microörganisms enter the tissue through a wound or puncture or an abraded surface, or if they locate upon predisposed or non-resistant mucous membrane, their multiplication causes irritation and inflammation of the tissue about them. This at first resembles a simple inflammation, but later becomes more severe, prolonged, and may spread into the surrounding tissue, or in some cases cause inflammation in another place in no way connected with it except by the blood or lymphatic channels (metastasis). Briefly the process may be described as beginning with the

[1] Green's Pathology and Morbid Anatomy.

entrance or location of the organisms and their multiplication. An injury of the vessel walls and degeneration of some tissue occur and the phenomena, such as occur in simple inflammation, begin. There is arterial hyperemia, later retardation of the blood current; diapedesis of leukocytes occurs, and a copious exudate of coagulable lymph is poured out into the intravascular tissue. By positive chemotaxis the leukocytes are attracted to the bacteria, surround them, and apparently endeavor to limit their activity, or, perhaps, to digest them. If the bacteria be few in number and not too virulent, the phagocytes are successful and the phenomena of resolution occur. If, however, the contrary be the case, the leukocytes are overcome and the inflammation spreads. In case of much toxin formation, negative chemotaxis occurs and phagocytic phenomena are held in abeyance. The central or most involved area dies. It is thus seen that there may be two terminations of an infective inflammation—resolution and necrosis.

Resolution.—If the phagocytes destroy or wall up the bacteria, so that they die in their own products or are killed by the protective juices of the part (alexins), the phagocytes undergo fatty degeneration, the lymphatics are unblocked, the circulation is reëstablished, the tissue that has died is removed by resorption and replaced by scar tissue if the loss be considerable. No evident pus or externally evident necrosis is produced, and the part exhibits phenomena much like those of a simple inflammation. This is the only termination for a simple (non-infective) inflammation.

Necrosis.—Death of a part may result from infective inflammation, either with or without pus formation.

Suppuration.—If the irritant in the tissue consists of pyogenic organisms, such as the Staphylococcus pyogenes aureus or albus, the Streptococcus pyogenes, the Bacillus pyocyaneus, Bacillus typhi abdominalis, Bacterium pneumoniæ, or the gonococcus, pus will be formed, provided the germs be not killed. The Staphylococcus pyogenes aureus is most frequently the organism infecting wounds. It is practically universal.

Entering a part, the bacteria distributed in the tissue act as irritants and excite the phenomena of inflammation as described. Some of the cocci are taken up by the fixed connective-tissue corpuscles, the leukocytes, and the endothelial cells of the capillaries, and some lie free in the tissue. The cocci multiply and the polymorphonuclear and eosinophile leukocytes increase in number by diapedesis and surround them. The original tissue cells, including those of the bloodvessels, undergo coagulation necrosis as the result of the action of bacterial ferments and do not take up staining reagents (Fig. 63). Coagulation

of the exudates occurs. The leukocytes and tissue cells are in part degenerated into pus corpuscles by the action of the unorganized

FIG. 63

Miliary abscess in a case of septic embolism of the kidney: *a*, leukocytes advancing toward and surrounding (*b*) a mass of cocci, in whose neighborhood all trace of structure has disappeared; *c*, renal epithelium too damaged by bacterial products to take the stain; *d*, kidney tissue staining normally; *e*, vein from which leukocytes are making their way to the commencing abscess. × 100. (Green.)

ferments of the bacteria—*i. e.*, their nuclei are fragmented, and they undergo fatty degeneration. Some cocci die. The exudate is pep-

tonized into a fluid, which, together with the cocci, dead leukocytes, and tissue remnants, constitutes *pus*. About this pus is a circumvallating wall of living leukocytes, and about this again a zone of fibroblasts arranged about new capillary loops (granulation tissue). The whole constitutes, when confined within tissue, an abscess. When upon a surface the granulation tissue is upon the under side only, the whole constitutes a suppurating ulcer.

FIG. 64

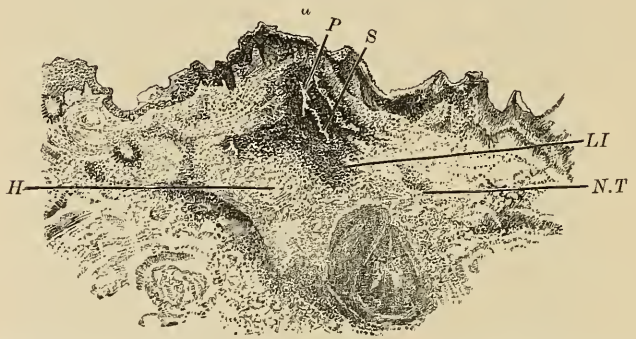

An abscess in the skin. The horny layer has largely disappeared, and the Malpighian layer is pushed upward by the subjacent abscess (*a*). The mass of pus corpuscles is just breaking down to form a cavity (*P*), the walls of which are thickly infiltrated with similar cells or the area of stasis (*S*). Outside is the area of lesser inflammation (*LI*), and still farther away are the areas of arterial hyperemia (*H*) and normality (*N.T*). Interpretation modified by editor. (Boyd.)

While the leukocytes may overcome the bacteria, the reverse is often the case, and the pus cavity enlarges in the same manner as at first by a new formation of coagulation necrosis, more circumvallation, further liquefaction of the coagulum, etc. The path offering the least vital or mechanical resistance is usually followed until the surface of the body or some internal cavity is reached. The last portion of tissue overlying the forming pus is tumefied and a soft, yellow spot appears. This is called *pointing*. The tissue is ruptured by the internal pressure and the pus escapes. The tract from the point to the abscess cavity is a *fistula* or sinus. As soon as this occurs granulation tissue springs up upon the sides of the abscess cavity and usually soon fills it with scar tissue. (See Regeneration.) If the cause continues to act, as, for example, in case of a portion of dead and septic bone beneath soft tissue, a gangrenous pulp in a tooth root or infected crypts of the abscess walls, the granulation tissue breaks down, and the condition is one of ulceration or a chronic abscess with a fistula. If, in the course of abscess formation, bone be encountered by the pus, it may be and often is molecularly broken down into pus. (See

Acute Apical Abscess.) It does not always happen that the pus finds escape either naturally or through surgical aid: the patient may die before this occurs, or the tissues around the seat of pus formation may form a boundary wall which the organisma fail to break down and thus die starved out. The abscess contents undergo changes resulting in caseation, or later the mass may calcify. In tubercular caseations the tubercle bacilli may live for a long period. (See p. 83.) The Streptococci pyogenes may multiply laterally, following the subcutaneous cellular tissue, and produce violent spreading inflammation with but little pus formation—*e. g.*, some forms of apical abscess and erysipelas.

The products (toxins) from an abscess or infective inflammation may find their way into the blood, and a general toxemia result, or the organisms themselves may enter the blood and a general infection result (septicemia). There are various varieties of pus which have names describing the chief characteristics:

Creamy pus is the erroneously called laudable pus associated with an acute abscess or ulcer which progresses, as a rule, toward a cure. It is of a yellowish-white color, creamy consistency, and without odor.

Curdy pus contains flakes.

Ichorous pus is thin, odorous, and irritating.

Mucopus is pus containing mucus.

Seropus is pus containing much serum.

Sanious pus contains blood.

Cause.—The cause of suppuration is the development in tissues of pyogenic organisms. The action of these causes is favored by the presence in the part of a hyperemia or simple inflammation, such as the injury introducing the organisms may cause. These as well as depraved or debilitated tissues favor the action of bacteria—*i. e.*, act as predispositions.

Symptoms.—The symptoms of suppuration are both general and local.

Local Symptoms.—The symptoms of inflammation—redness, heat, pain, and swelling—occur, but usually much aggravated. The pain is often of a lancinating character, sudden darts often following comparative quiescence. On the other hand, the throbbing pain may be continuous and intense, especially when the pus is confined by bone or tense tissues, as in the case of a felon or an acute apical abscess. Recalling that around the pus area there is an area of stasis, next one of active but lesser inflammation, and about that hyperemic, then normal tissue (Fig. 64), one may judge of the degree of involvement of deeper parts by the appearance of the surface above them. Thus,

for example, hyperemia at the surface indicates inflammatory action directly beneath, with a pus cavity still deeper, while inflammation at the surface, together with hardness and tumefaction, shows a more involved condition of the tissue directly beneath it—*i. e.*, a more advanced state of inflammation or even of suppuration.

The softening of the apex of the swelling gives a feeling of lessened resistance, indicating pointing or pus at the surface. In large, superficial abscesses the sensation known as fluctuation may be obtained by placing one finger on one side of the swelling and gently tapping upon the other. Yellowness of the apex, together with softness, indicates that the abscess is about to discharge its contents. A fistula or sinus upon the surface is indicative of a discharged abscess, and leads to a pus-forming area beneath (chronic abscess).

General Symptoms.—If toxemia be produced there may be chills, and, at the same time, fever as high as 104° F. A full, bounding pulse accompanies this, the patient is constipated, has a coated tongue, is exhausted by loss of sleep and often disturbed nutrition due to the pain. There may be other evidences of septic intoxication, which may become profound. (See Septic Intoxication.)

Leukocytosis after surgical disease is considered pathognomonic of suppuration, the count running up to 15,000 or 20,000 per cubic millimeter. (See p. 115.)

Fig. 65

Tuberculous ulcer of the intestine: *a*, mucosa; *l*, submucosa; *c*, muscularis; *g*, ulcer; *t*, tubercle in the mucosa; *t'*, focus caseating in the middle. × 12.

Ulceration.—The development of microörganisms upon a free surface causes tissue degeneration and death, as described under Abscess.

Numerous forms of pathogenic organisms are capable of causing tissue degeneration and death of a mucous or skin surface. If infection take place through a hair follicle, or if organisms develop upon an abrasion, or in the epithelium in conditions of general or local debility, the epithelium is destroyed over an area, and in the subepithelial tissues the organisms multiply and cause tissue loss. If the organisms

be pyogenic—and ulcerous surfaces are usually infected by these bodies—pus is formed (Fig. 65). Under some conditions, as in debilitated and neglected children, the ulcerous process may spread rapidly, as in the cheek in cancrum oris; or when specific bacilli, which excite much swelling and quick death of the tissues of the cheek, proliferate, causing the condition called noma. (See Index.)

Prognosis.—Abscesses tend, as a rule, to spontaneous cure without marked systemic disturbance. If the pus discharge persist after evacuation of the abscess, persistence of the cause, or infection of the abscess walls through reinfection or by retention of bacteria in the crypts, is to be suspected. The recurrence of rigors (chills) and high fever is a danger signal. A fluttering, weak pulse and clammy extremities indicate profound septic intoxication, and are indications for local disinfection and systemic treatment.

Therapeutics of Inflammation.—If the cause of inflammation be in evidence it must be removed; good examples of removable causes are a splinter in the flesh, a gangrenous tooth pulp, etc. Ordinarily the pus of an abscess or an ulcer contains the cause (bacteria) within it; therefore the pus should be removed by opening the abscess, if its situation can be determined, after which the pus cavity is syringed out with germicides, which destroy the pus and the organisms. Hydrogen dioxid in 3 per cent. aqueous solution is commonly used; it is made more effective by the addition of mercuric chlorid (1 to 1000).

In ulceration the pus and organisms are destroyed in a similar manner, though at times sloughing tissue requires removal by the curette, caustic agents, or by digesting agents, as caroid, papoid, brewers' yeast,[1] etc.

Dead bone acts as a septic irritant and requires removal, and at times an abscess will remain persistently infected, requiring surgical removal of tissue. The abscess or ulcer, if protected from further infection, usually heals by formation of granulation tissue. A deeply seated abscess may require to be packed with antiseptic gauze (nosophen), in order that it may granulate from the bottom out; otherwise a small orifice may heal, permitting a re-collection of pus beneath.

Ulcers are usually dusted with antiseptic powders, iodoform, aristol, or nosophen, which cause drying of the surface and prevent the access or action of organisms. Under certain circumstances the presence of suppuration is not certain, though phlegmonous (spreading) inflammation is somewhat pathognomonic of it. In such cases hot, moist applications, such as hot poultices, soften the surface above the abscess and determine its direction of discharge, thus limiting burrow-

[1] Park's Surgery.

ing. Counterirritants applied directly above the inflamed area also hasten in such cases. The stimulation may aid resorption (destruction by phagocytosis) of the pus and resolution occur.[1] The vascular engorgement in an inflamed part may be reduced by local bloodletting.

Nancrede found, on dividing a vein upon the distal side of an area of inflammation, that after a brief period the flow of blood was established through the inflamed area. Local bloodletting by leeches (Gensmer) produced even more marked effects. Drugs which stimulate the vasoconstrictors (ergot), and those which paralyze the constrictors (aconite), lessen the blood pressure in the inflamed area; so that if administered in the early stages of inflammation they may modify its severity. If, on the contrary, they are administered after stasis occurs, they increase the stasis—ergot actively and aconite passively. If the flow of blood through the inflamed area be reëstablished by local bloodletting, then the arterial sedatives are distinctly useful in lessening the flow of blood to the part.

When, owing to vascular engorgement, throbbing pain is a prominent symptom, applications of cold are useful in lessening the caliber of vessels and in relieving pain. But if there be firm exudation and marked stasis, cold is a detriment. Heat then gives relief through inducing a more free flow of blood in the collateral circulation. Very hot applications act as do cold applications, by causing contraction of vessels, and may be used to abort an inflammation.

In certain situations, as in case of an inflamed tooth-pulp, sedative applications, antiphlogistics, are required. Conjoined with local measures of reducing vascular engorgement, the use of counter-irritants and general derivatives are indicated. (See Treatment of Hyperemia.)

General sedatives are at times demanded for the relief of pain. Morphin used in small and continued doses not only relieves pain, but causes a contraction of small vessels. Other anodynes are also used in this connection, as acetanilid or trigemin. Quinin and salol are useful as correctives of the intestinal disturbance, and mercuric chlorid in small doses is useful as a preventive of general infection. (See Acute Apical Abscess.)

REGENERATION OF TISSUES.

Connective tissues that have been lost by inflammatory process or operation are replaced by granulation tissue arising by mitotic division of cells of the connective-tissue group. The forms of healing are by

[1] Park's Surgery.

first intention, second intention or granulation, healing under a scab, and healing under a clot. Epithelial tissues are replaced only by

FIG. 66

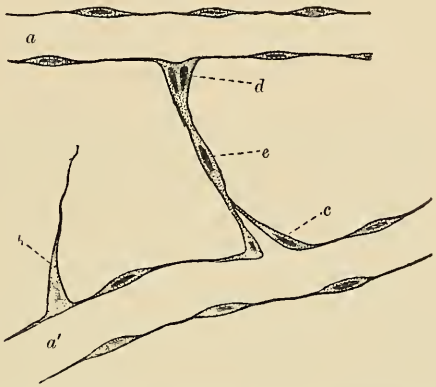

Regeneration of capillary bloodvessels: *a*, normal capillaries; *b*, capillary process; *c*, new capillary appearing in divided process; *d*, process undergoing division; *e*, connecting cell in which no sign of division has yet appeared. Diagrammatic. (Green.)

FIG. 67

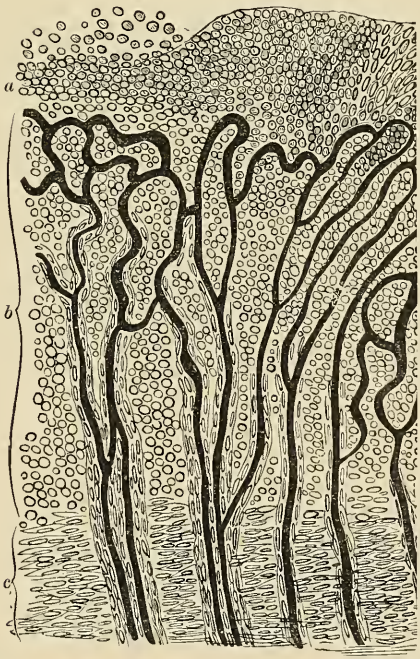

A granulating surface: *a*, layer of pus; *b*, granulation tissue with loops of bloodvessels; *c*, commencing development of the granulation tissue into a fibrillated structure. × 200. Diagrammatic. (Rindfleisch.)

multiplication of epithelial cells. The forms of healing are practically alike by formation of granulation tissue, the form being simply a modification (of extent) of healing by second intention. This granulative tissue is transformed into fibrous tissue, the original tissue rarely being reproduced to any great extent though bone may be regenerated.

Fig. 68

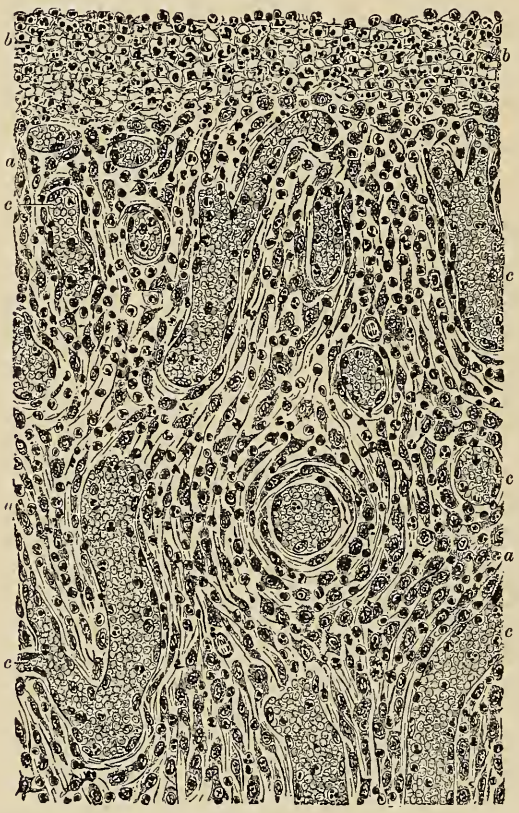

Transverse section of granulation tissue from an open wound with fibropurulent deposit: *a*, granulation tissue; *b*, fibropurulent deposit; *c*, *c*, bloodvessels. × 150. (Ziegler.)

Healing by Second Intention or Granulation.—Shortly after evacuation of pus from an abscess the process of repair is instituted. The leukocytes come to the surface of the wound in great numbers; some of these may degenerate into pus cells. Immediately beneath the uninjured connective-tissue cells multiply, forming embryonic cells (fibroblasts); at the same time the endothelial cells of the capillaries multiply at points, throwing out solid-pointed projections or buds

from the sides of the capillaries (Fig. 66, *b*). These lengthen and join buds from other capillaries (Fig. 66, *c*, *d*, *e*). By mitosis the nuclei divide horizontally, lying side by side (Fig. 66, *d*). Later these separate into two cells, discovering a lumen into which blood enters from the parent capillary (Fig. 66, *a'*, *c*). In this manner loops are formed, about which the fibroblasts are arranged (Figs. 67 and 68).

Together these form minute red elevations upon the surface of the abscess cavity or wound, called granulations. Repeated, the process gradually fills the abscess cavity.

FIG. 69

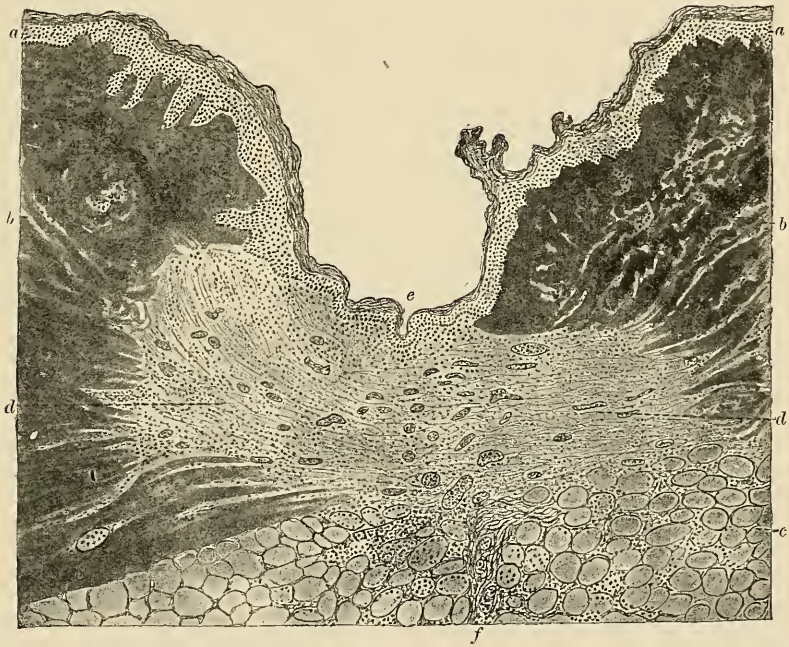

Laparotomy wound—sixteenth day: *a*, *a*, epithelium; *b*, *b*, corium; *c*, subcutaneous fat; *d*, vessels in scar tissue of corium; *e*, newly formed epithelial layer; *f*, vessels in subcutaneous scar tissue. × 40. Modified from Ziegler. (Green.)

Naturally, collapse of the walls or apposition of cut edges of a wound lessens the amount of granulation tissue necessary; hence, in the latter case, healing by first intention (with a minimum amount of granulation or scar tissue).

The wound having been filled up, epithelium grows from the sides and covers the granulations (Fig. 69, *e*). The granulation tissue, at first highly vascular, later contracts, and many vessels are obliterated so that it becomes whiter than normal tissue—cicatricial tissue (cicatrix).

The indifferent embryonic cells may have the function of forming any of the connective tissues. If cartilage is to be formed, chondrification takes place about the specialized cells. If bone is to be formed, certain cells form islets, about which calcification proceeds. Nerves require a month or more to pierce the cicatricial tissue (Eichhorst).[1] In spite of this assertion the writer finds that granulations are very sensitive to touch, which seems clinical evidence of error in this observation.

In healing beneath a scab the exudation and leukocytes upon the surface of the wound dry into a scab beneath which granulations and an epithelial covering are formed. Later the scab falls off. If prematurely lost the granulations are exposed.

FIG. 70

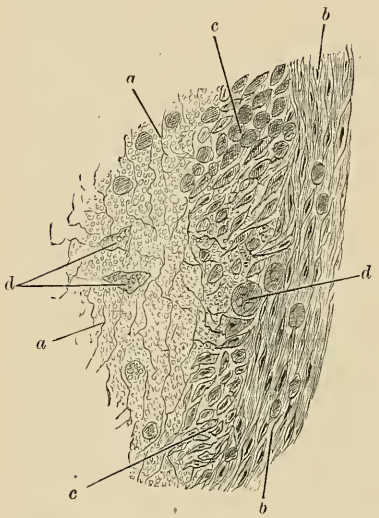

Absorption of blood clot. Section through the margin of a clot formed among the tissues by extravasation, showing the growth of granulations by which it is removed: *a*, *a*, portions of clot; *b*, *b*, original tissue; *c*, *c*, granulations springing from the original tissue and projecting into the clot; *d*, *d*, wandering cells or leukocytes that seem to have taken red blood disks into their interior. (Section cut in gum arabic and stained with hematoxylin.) × 350. (Black.)

In healing under a clot the clot is invaded by leukocytes, which have a solvent action upon it. Granulation tissue forms upon all sides of it, grows into it, and, at the same time, removes it by resorption (Fig. 70). If the clot become septic the granulations may become infected and break down, as scar tissue in its early vascular stages is of but feeble resistive power, though it does not absorb toxins. (Park.)

Healing under a clot is the form commonly seen after tooth extraction. It is an interesting point that the alveolus is finally filled with bone, while the original bony margins of the alveolus are resorbed.

In certain cases of abscess with contracted fistulæ or openings of discharge, the orifice may close before the granulations have filled the pus cavity. If pus or an excess of exudate be now formed within the cavity, a second discharge may occur. To obviate this difficulty, abscesses are often packed with antiseptic gauze, so that healing

[1] Ziegler, General Pathology.

may occur from the bottom of the cavity, while drainage is assured. In other cases the placing of a tent or drain tube in the fistula together with asepsis suffice for the attainment of the object. In other cases, as in bone cavities, semisolid materials, such as Beck's bone paste are introduced to occupy the cavity to exclude infective and foreign material while granulations form about it and gradually absorb it.

INFLAMMATION OF BONE.

"Active inflammatory changes may occur in the periosteum, the medullary canal, the medullary spaces of the spongy bone, and the Haversian canals, the compact tissue and ground substance remaining passive."[1] The inflammation is termed periostitis, osteomyelitis, or osteitis, the terms referring to the point of location of the inflammation—*i. e.*, the periosteum, the medulla, and the spaces —the bone being involved in all cases. Inflammation of bone may be non-infective or infective; the latter is usually due to pyogenic organisms—*i. e.*, suppuration occurs.

Proliferative Periostitis.—This is a proliferation of cells of the deeper layers of the periosteum combined with emigrated leukocytes. A node is thus formed which may ossify.

Suppurative Periostitis.—Pyogenic organisms may enter an injured periosteum or one weakened by previous disease (*e. g.*, by scarlet fever). The origin of the bacteria is by way of the blood, either directly or by way of the medulla (as a secondary effect of osteomyelitis), or by way of the skin.

Pus forms beneath the periosteum, raises it, and destroys its connection with the bone. The vessels are stretched, damaged, and thrombosis occurs. Superficial necrosis of bone results, which may be total if other sources of blood supply are also cut off.

Acute Osteomyelitis.—This is a suppuration occurring in the bone-marrow, which infects the bone proper, causes much thrombosis of vessels, coagulation necrosis of bone cells, and may rapidly cause much necrosis of medullary tissue. Occurring in large bones, much toxin is produced, which may rapidly cause death. The organisms and thrombi formed, becoming emboli, may rapidly lead to pyemia.[2] Prompt surgical interference is called for.

Inflammation of bone may lead to its rarefaction (rarefying osteitis or osteoporosis), its condensation (condensing osteitis or osteosclerosis), or its death (necrosis and caries).

[1] Schmaus and Ewing, Pathology and Pathological Anatomy.
[2] Park's Surgery.

Rarefying Osteitis (Osteoporosis).—In the rarefying process which occurs in chronic inflammation, granulation tissue is formed, which enters the Haversian canals and spaces of spongy bone and destroys (resorbs) the bone, owing to the presence of osteoclasts. They thus form new channels between the spaces—perforating canal resorption (Fig. 71). With suppuration (ulceration) added, the granulations break down, leaving the bone as a dead, spongy, or honeycombed mass. This is *caries of bone*. In the early stages the inflammation may cease, and the bone not only be restored, but condensed.

Fig. 71

Trabeculæ of bone with perforating canals. × 50.

Condensing Osteitis (Osteosclerosis).—In chronic inflammation, of lesser degree, instead of rarefaction, construction occurs and the trabeculæ of bone may increase in thickness, so that all spaces and Haversian canals become smaller. The bone becomes very compact and less vascular, and if built up in excess of its original dimensions, constitutes the condition known as *exostosis;* if very dense, as "ivory

Fig. 72

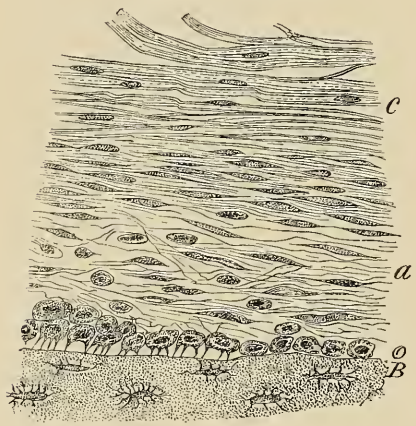

Section of bone and periosteum covering it: *B*, bone; *c*, outer fibrous layer; *a*, inner layer of white fibrous tissue; *O*, layer of osteoblasts, some of which reach the bone with their prolongations. Normal bone. (Black.)

Fig. 73

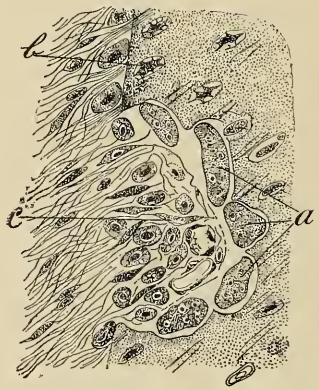

Section of bone and periosteum covering it: *a*, osteoclasts, cells that absorb bone; *b*, surface of bone, showing fibers of periosteum penetrating it and a Howship lacuna. Lacunar resorption. (Black.)

exostosis." Both condensing and rarefying osteitis occur about the alveolar process and the roots of teeth. (See Hypercementosis and Resorption.)

Necrosis of Bone.—Necrosis of bone following rarefying osteitis is known as caries. It is a molecular death of bone. Subperiosteal death of bone occurs from infective periostitis, and is due to the compression of vessels by the exudation and to thrombosis. Nutrition ceases; death results. The dead piece is demarked by a line of leukocytes (phagocytes), solution of continuity or rarefying osteitis occurs at the line of union with the living bone, and the piece is thrown out as a *sequestrum*. New bone inclosing a sequestrum is termed an *involucrum*. (See Gangrene.)

Fig. 74

Lattice-work figures in halisteresis. (After v. Recklinghausen.)

Fig. 75

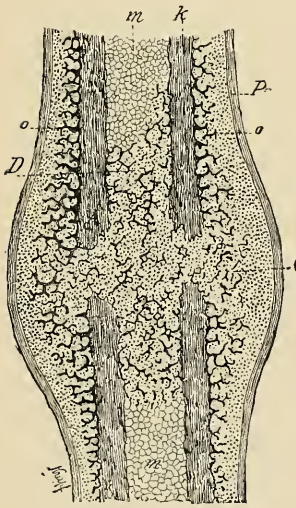

Diagram of healing fracture. From a guinea-pig ten days after injury: *K*, ends of the bone: *m*, marrow; *c*, periosteal callus; *d*, medullary callus; *o*, osteoid tissue. × 6.

Fig. 76

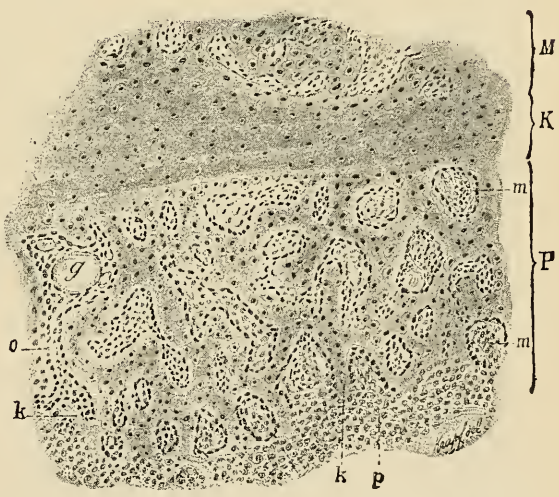

The same preparation: *M*, myelogenous callus; *P*, periosteal callus; *K*, ends of the bone; *k*, osteoid trabeculæ; *o*, osteoblasts in rows; *p*, thickened periosteum. × 250. (Schmaus and Ewing.)

Resorption of Bone.—Under conditions of chronic inflammation bone is often removed by neighboring tissue in one of several ways.

Lacunar Resorption.—In this form the bone is excavated by giant cells into bays called Howship's lacunæ, which may enlarge, or later a reconstructive action may occur and osteoblasts may fill up the bays with bone. (See Hypercementosis and Resorption of Roots.)

Perforating Canal Resorption.—This has been described under Osteoporosis. The canals connecting medullary spaces are enlarged by the granulation tissue formed in them (Fig. 71).

Halisteresis Ossium.—In this form of resorption the bone first undergoes decalcification and the matrix is later removed (Fig. 74). It occurs in conditions of osteomalacia, as in pregnancy, senility, etc. It also occurs in the alveolar process, and is, at least in part, the cause of the cleanly symmetrical resorption of the gum and alveolar margins. (Talbot.[1])

Regeneration of Bone.—Bone lost by suppuration is first replaced by provisional tissue of the connective-tissue type, in which appear osteoblasts. Calcification then proceeds under superintendence of these (Figs. 72, 75, and 76).

FEVER.

The term fever is applied to a condition the most prominent feature of which is an elevation of the bodily temperature above the normal, 37° C. To constitute a fever this rise in temperature must continue for some length of time.

Etiology.—Fevers are commonly caused by the presence in the circulatory fluids of substances which act as poisons upon, probably, the nerve centres controlling heat production. As a rule, the offending substance is a poison generated in the body through the action of microörganisms. The character and type of the fever are determined by the nature of the offending substances—*i. e.*, the variety of infection.

Classes.—Fevers are divided into periodical or continued, according as to whether there is a periodical fall of temperature and a subsequent rise, or whether the fever continues practically unabated from the beginning to the termination of a disease. Fevers are classed in severity according to the maximum temperature, and, again, according to their duration. A temperature of 100.5° to 101.3° F. is called slightly febrile; 101.3° to 103° F., moderate fever; 103° to 105° F., marked fever. A temperature above 106° F. is termed hyperpyrexia.

[1] Interstitial Gingivitis.

Symptoms.—The most characteristic symptom of fever is the elevation of temperature; accompanying this there is an increased frequency of the pulse. In acute inflammatory diseases the pulse is full and bounding, the eyes injected, the bowels constipated, and the urine scanty, containing an excess of urea. On standing, the urine throws down a brickdust deposit (urates). In fevers of a lower type, or in many fevers which begin as described, the high, bounding pulse is succeeded by a soft, quick pulse, and evidences of great debility. In fevers in which the temperature runs high there is commonly evidence of intoxication, more or less delirium, and reflex muscular action. With a persistent temperature and a pulse becoming softer and more frequent, there is increasing debility.

Pathology and Morbid Anatomy.—In all cases of continued high temperature the fat of the body rapidly disappears and granular degeneration occurs in the muscles and viscera of the body. If the fever be long continued and of an adynamic type, this degeneration may become marked. Its occurrence in the muscles of the heart is common and is an element of danger. There are an increase in the amount of carbon dioxid formed and exhaled from the body, and an increased amount of oxygen inhaled. This, with the increase of urea, the product of the oxidation of nitrogenous tissues (muscles, glands, etc.), indicates that the oxidation of the tissues is largely increased; hence the elevation of temperature. As repair does not equal waste in fevers, the nutritive processes being profoundly disturbed, the essential elements of the tissues suffer from the increased oxidation and undergo degenerative changes.

Prognosis.—The higher the temperature and the longer it continues, the greater drain there is upon the vital forces. As a rule, a temperature of 106° F. persisting more than twenty-four hours presages death. If the vital forces flag and the heart action becomes weakened, and if there be evidence of profound intoxication, such as twitching of tendons, low, muttering delirium, and a clammy surface, the outlook is bad. Favorable signs are: falling temperature, a clear eye, tongue losing its coating, free action of the bowels, free perspiration, free action of the kidneys, and a good vascular tension.

Treatment.—In the light of present knowledge efforts should first be made to discover the nature of the cause of the fever and to remove it, if possible. If not, attention should be directed to maintaining the vital forces until the body rids itself of the offending causes. As many fevers are self-limited in course and duration, this latter treatment becomes an important consideration. The temperature should be kept within safe limits by the administration of antipyretics, when the condition of the heart will permit their use, and also by

cool sponging or cool baths. The action of the heart should be sustained by the administration of concentrated nutriment, and by stimulants when necessary. The bowels must be kept open.

In any form of fever there is no therapeutic measure comparable with the removal of the cause, provided this be discoverable, identified, and removable.

TOXEMIA.

By toxemia is meant a more or less general disturbance of the ecomony as the result of the presence in the blood of substances poisonous to a tissue or the tissues. The substance may be a normal constituent of the blood which has accumulated owing to faulty elimination—*e. g.*, urea—or be derived from the alimentary canal as the result of unusual fermentation therein. Such an effect is known as auto-intoxication. It may be due to the action of drugs of toxic character—*e. g.*, alcohol or iodoform. This is drug toxemia. Again, it may be due to the action of the products of bacteria, which products, absorbed from certain foci of infection, produce general effects, such as fever. Again, similar results can be produced by the introduction of toxic products from bacterial culture *in vitro* or in experimental animals.

Septic Intoxication.—By septic intoxication is meant the absorption into the blood of the products of bacterial activity, which products are produced at some focus or foci of infection as the result of tissue or tissue-juice decomposition. These bacterial products produce symptoms of general poisoning or intoxication, which are mild or severe, according to the character of the poisonous body produced. The organisms do not necessarily enter the blood, hence the blood is not infectious if inoculated into another person (or experimental animal).

Two varieties of septic intoxication may be distinguished:

1. Intoxication by the products of the action of specific bacteria developing upon living tissue.

2. Intoxication by the action of bacteria upon non-vital materials (sapremia).

The action of the bacilli of diphtheria, Asiatic cholera, and tetanus are examples of the first class. Their toxins are virulent, but the bacteria are confined to the pharynx, intestine, and the wound respectively.

Sapremia.—The entrance of putrefactive or the pyogenic organisms into such material as a large blood clot or gangrenous area may, by putrefaction, cause the formation of large quantities of toxins. These, if absorbed, produce rapid and profound symptoms of intoxi-

cation. The symptoms vary according to the nature of the toxin and the quantity absorbed, but ordinarily occur in the following order: Malaise, rigor, fever and its symptoms, nausea, vomiting, headache, diarrhea, prostration, delirium in some cases, muscular weakness, clammy skin, feeble pulse, quick respiration, and in fatal cases coma and death. The symptoms are similar to those of septicemia, but appear more rapidly—*i. e.*, septicemia requires time to spread. There is a putrid wound which is the source of the toxic substance. The condition is usually complicated by septicemia.

SEPTICEMIA (GENERAL SEPTIC INFECTION).

By septicemia is meant a condition in which the bacteria, usually one of the pyogenic varieties, gain entrance to the living tissues, enter the circulation, and are carried to inaccessible parts, where their development continues and from which point their toxins are absorbed (Fig. 77).

This process requiring more time than mere absorption of toxins, the symptoms are much more delayed than in sapremia. The blood is highly infective to susceptible animals in minute amount, as it contains bacteria.

Pathology.—There is a septic wound in which incubation occurs for several days. The lymphatics leading from the part and the nearest lymphatic glands become inflamed. In pronounced cases the spleen is enlarged. There is marked leukocytosis.

Examination made after death due to the septic intoxication produced by both sapremia and septicemia exhibits fairly constantly enlargement of the spleen and disintegration of the red corpuscles, with staining of the intima of the vessels and heart. The lungs are congested. Death occurs through heart-failure.[1]

Symptoms.—These are similar to those of sapremia, except that the periods of incubation about the body cause delays.

Therapeutics.—For sapremia and septicemia, the treatment is both local and general. The local treatment involves the opening and disinfection of all wounds, even the extirpation of a part and of neighboring glands being sometimes necessary for removal of the cause. If possible, the part is immersed frequently in hot water, which may occasionally have mercuric chlorid added to it.

An antiseptic salve, consisting of resorcin, 5 parts; ichthyol, 10 parts; unguentum hydrargyri, 40 parts; lanolin, 45 parts, is to be applied to the area of infection.[2]

[1] Green, Pathology and Morbid Anatomy.

[2] Park's Surgery.

Credé's silver ointment may be applied to the unbroken skin for the systemic antiseptic effect of the silver.

The general treatment consists in: (1) Clearing the alimentary canal by means of cathartics and maintaining its asepsis by means of mercuric chlorid in small doses, salol, or other suitable antiseptic. (2) Supporting the heart action by means of alcohol and strychnin. (3) Supporting the strength by concentrated liquid nourishment, such as egg albumen, beef peptonoids, beef juice, peptonized milk,[1] to

FIG. 77

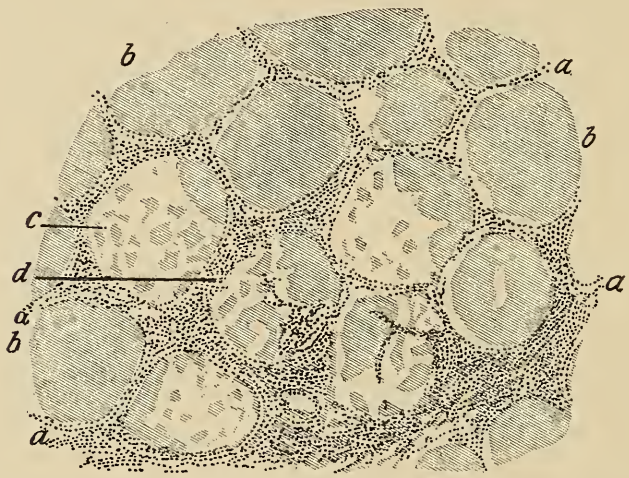

Pectoral muscle beset with large numbers of the Streptococcus pyogenes, from a case of phlegmonous inflammation of the subcutaneous and intermuscular connective tissue, due to cadaveric poisoning (the phlegmon of the wall of the chest developed two days after the finger was injured, and the intermediate lymph vessels of the arm showed no evidences of being involved): *a*, perimysium internum full of streptococci; *b*, transversely cut muscular fibers, still intact; *c*, transversely cut muscular fibers which are beginning to degenerate; *d*, muscular fibers into which the cocci have penetrated. (Preparation treated with gentian violet and vesuvin, and mounted in Canada balsam. × 350 diameters.) (Ziegler.)

which diet fruit may be added.[2] (4) Reducing the temperature by means of cold sponge baths or quinin. (5) Maintaining the eliminative action of the kidneys until the system has rid itself of the toxins. For the more profound cases, Park recommends the intravenous infusion, as an intravascular germicide, of from 500 c.c. to 1000 c.c. of a solution of Credé's soluble silver, 1 to 1000 of sterilized water at 105° F. Streptococcus antitoxin is sometimes used. Vaccine therapy is of value. (See p. 63.)

[1] Thompson, Practical Medicine.

[2] Park's Surgery.

PYEMIA.

By pyemia is meant a form of septicemia or septic infection by pyogenic organisms, which, locating at favorable spots, as in the capillaries, multiply and produce numerous abscesses known as miliary or metastatic abscesses. From these foci toxins are absorbed, which produce a septic intoxication.

The organisms may enter the blood from some focus of suppuration as free cells or be taken up by leukocytes, or thrombosis may occur at the original focus of infection, and portions of clot be carried in the blood as septic emboli to terminal arteries, where the results of septic infarction are set up. (See Infarction.)

Symptoms.—The symptoms of pyemia are, in general, those of septicemia; their appearance is delayed from the date of the reception of an injury or the outbreak of the primary suppuration. The onset of pyemia is usually by a chill or a succession of chills. Each fresh area of pus formation is believed to be announced by a chill and a rise of temperature. The temperature is subject to remissions, and sudden variations in its height are noted. The general symptoms are those of an adynamic fever. Local symptoms appear according to the point of lodgment of septic emboli. Pus centres may be found in the lungs, and cause symptoms of dyspnea; collections frequently occur in joints, causing loss of mobility; eruptions appear on the skin, the swellings being apparent; typhoid symptoms become more pronounced, and an increasing debility ushers in a usually fatal ending. At times both septicemia and pyemia may become chronic.

Therapeutics.—The treatment of pyemia should be preventive. The carrying out of rigid antiseptic precautions has much lessened the frequency of pyemia. If areas of infection are removable, they are removed no matter what extent of operation may be necessary. The general treatment is the same as in septicemia, with much less hope of recovery.

A consideration of the infective surgical processes in connection with dental and oral diseases is of the utmost moment to the practitioner of dentistry. Nearly all of the diseases which the dentist is called upon to treat are infective from their inception. Moreover, the saliva, holding in suspension numerous forms of bacteria, both saprophytic and parasitic, and their waste, is a highly infective fluid.

It has been clearly demonstrated by the researches of Miller[1] that many forms of bacteria found in specific diseases, and found inhabiting the intestinal tract, are more or less constantly present in the

[1] Microörganisms of the Human Mouth.

human mouth, and that the pathway in many general infections is no doubt *via* the oral cavity. A wound made in the human mouth is necessarily an infected wound. In the vast majority of cases the body exercises its protective function in a phagocytosis,[1] or through immunizing processes, which disposes of invading bacteria or renders them innocuous. In other cases it is beyond question that this protective provision fails and infection occurs, especially if new forms be introduced.

THE EXANTHEMATA.

Certain acute specific diseases, such as rubeola, rötheln, scarlatina, varicella, and variola are accompanied by skin eruptions generally distributed over the body, and which represent an infective dermatitis; indeed, the eruptions of many of these diseases are contagious to other individuals. Syphilis, a chronic specific disease, due to the Treponema pallidum, produces similar effects.

The special interest lying in the exanthemata is that occurring during the development of the teeth; the latter are often profoundly affected, so that malformations, sometimes serious in character, occur in the teeth. It is to be recalled that teeth are dermoid structures, certainly in so far as the enamel is concerned. (See Malformations of the Teeth.) Again, after or during exanthematous diseases, notably scarlet fever, the oral tissues are much debilitated, so that abscesses about the teeth may produce much necrotic tissue or the disease itself may produce necrosis.

[1] Hugenschmidt, Dental Cosmos, 1896.

SECTION II.

EMBRYOLOGY, ANATOMY, AND HISTOLOGY.

CHAPTER VI.

THE DEVELOPMENT, ANATOMY, AND HISTOLOGY OF THE JAWS AND TEETH.

As malformations of the parts about the mouth and of the teeth are dependent upon defective development of the same, it is incumbent that certain facts concerning their embryology should be stated. In like manner, as the processes of pathology are modified by the peculiar anatomy of the teeth and associated parts, it is necessary that a previous knowledge of these be acquired before the special dental pathology can be comprehended. The embryology of the mouth begins at a very early period—before the twelfth day the future mouth may be located (His, Fig. 78). The mouth and nasal cavity are circumscribed by parts which are developed by outgrowths from the head fold of the fetus. Those structures immediately concerned are the lateral tubercles arising from the frontal prominence (Fig. 79), which grow downward and fuse, forming the nose, the nasal septum, the intermaxillary bones, and anterior portion of the upper lip (Figs. 80 and 81). From the sides of the head fold at the level of the mouth and neck appear

FIG. 78

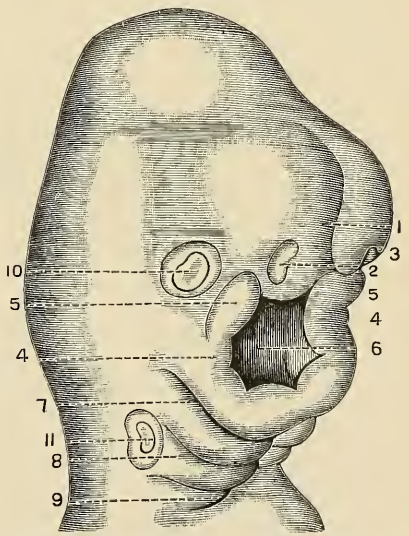

Face of an embryo of twenty-five to twenty-eight days (magnified fifteen times): 1, frontal prominence; 2, 3, right and left olfactory fossæ; 4, inferior maxillary tubercles, united in the middle line; 5, superior maxillary tubercles; 6, mouth or fauces; 7, second pharyngeal arch; 8, third; 9, fourth; 10, primitive ocular vesicle; 11, primitive auditory vesicle. (Gray.)

certain lateral protuberances, or pharyngeal arches. The first pharyngeal arches (Fig. 78, 4) divide into (1) the superior maxil-

FIG. 79

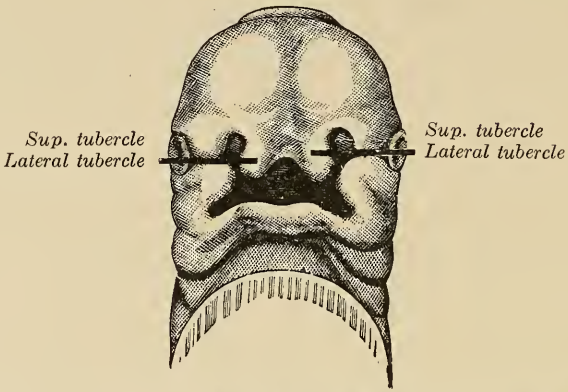

Head of an early human embryo, showing the disposition of the facial fissures and the superior and lateral tubercles. (His.)

FIG. 80

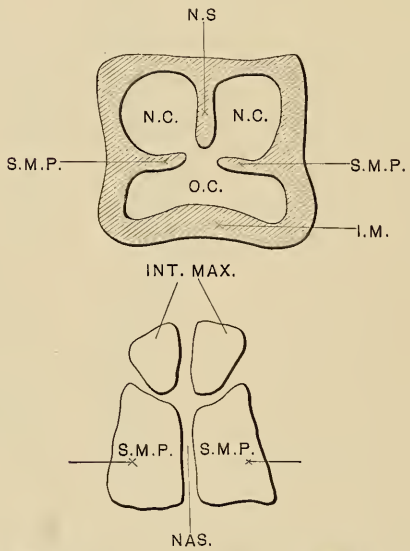

Diagram illustrating scheme of union of the processes: *N.S.*, lateral tubercles forming internal maxillary bones, *INT. MAX.*, and nasal septum; *S.M.P.*, superior maxillary processes forming palatal processes of superior maxillæ, *S.M.P.*; *N.C.*, nasal cavity; *O.C.*, oral cavity; *I.M.*, inferior maxillary processes united.

lary processes (Fig. 78, 5) and (2) the inferior maxillary processes (Fig. 78, 4, shown just beneath the oral cavity and united in the median line).

Fig. 81

Complete bilateral fissures (coloboma) of face. (Guersant.)

Fig. 82

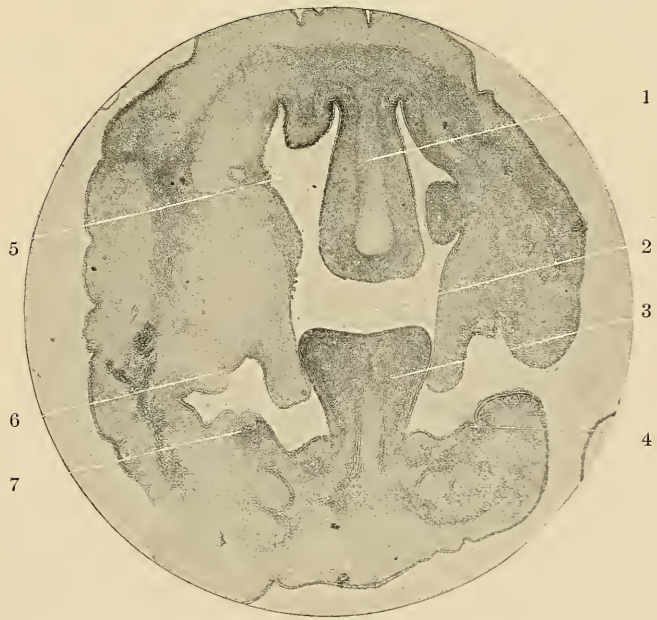

Vertical transverse section through head of human embryo, about the tenth week: 1, nasal cartilage; 2, buccal cavity; 3, tongue; 4, dental ridge, lower jaw; 5, nasal cavity; 6, dental ridge, upper jaw; 7, dental ridge, lower jaw. × 30. (Broomell.[1])

[1] Anatomy and Histology of the Mouth and Teeth.

The superior maxillary processes develop the palate bones and the superior maxillæ. They form the balance of the upper lip. The arch itself forms the cheek. Fig 81, from a case of arrested development, illustrates the unions and parts naturally formed, but here incomplete. Fig. 82, in which the union of the processes is still incomplete, shows how this and cleft palate can occur.

Secondary processes develop horizontally toward each other, form the palatal portions of the superior maxillæ and palate bones, and unite at the median line (Fig. 80, *S.M.P.*, also Fig. 82), forming the vault of the mouth and floor of the nasal cavity. Union occurs with the lateral processes, later forming the intermaxillary bones and bearing the germs of the incisor teeth (Fig. 83), thus completing the formation of the upper jaw and lip.

FIG. 83

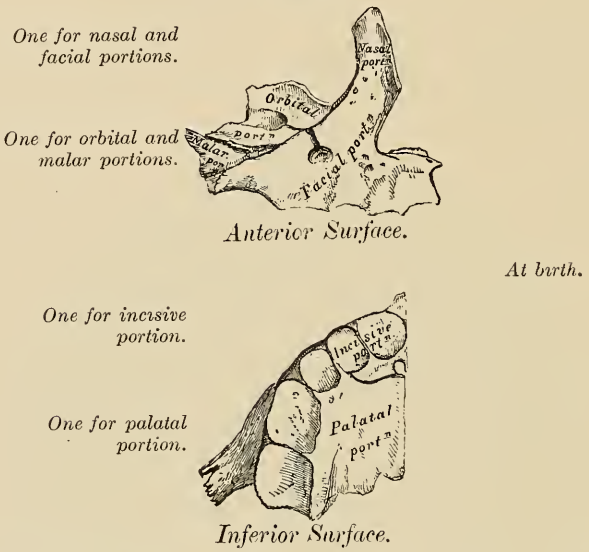

Development of the superior maxillary bone by four centres, also development of intermaxillary bones. (Gray.[1])

The inferior maxillary processes grow forward and unite at the median line, developing the inferior jaw and lip. Fig. 86, an arrested case, shows this.

The structures of the floor of the mouth and neighboring structures are formed from the second, third, and fourth pharyngeal arches and a tubercle arising near the first pharyngeal arch. The fusions of the lateral portions of the upper maxillæ begin first anteriorly at about

[1] Gray's Anatomy.

the eighth week, and progress posteriorly until complete at about the eleventh. Malformations due to non-union, therefore, date from this period, and consist of the following typical varieties:

Fig. 84

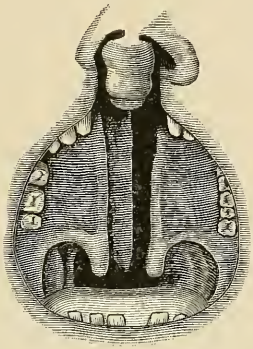

Cleft of hard and soft palate; rudimentary intermaxillary bone placed in advance of lips. (Mason.)

Fig. 85

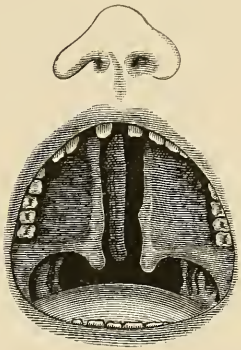

Cleft of hard and soft palate. (Mason.)

Fig. 86

Median fissure of the lower lip and chin. (Marshall, after Wöfler.)

1. Non-union of lip on one or both sides—simple hare-lip.
2. Non-union of lip and of maxilla and intermaxillary bone on one side (hare-lip, Fig. 84).
3. Non-union of lip and intermaxillary bone on both sides (double hare-lip, Fig. 81).

4. Non-union of all horizontal processes in the median line (cleft palate, Figs. 84 and 85).

5. Non-union of halves of soft palate (cleft velum).

6. Non-union of halves of the uvula (bifid or cleft uvula).

Combinations of cleft velum and cleft palate or of cleft palate and single or double hare-lip may exist.

Figs. 81, 82, 84, and 88 show the parts in their ununited state.

The failure of the inferior maxillary processes to unite is rare, but is occasionally seen (Fig. 86). The inferior maxillary tubercles develop a transitory support to the lower jaw known as Meckel's cartilage. The cartilages of the right and left side do not fuse together at the future symphysis. (Hertwig.) (See Figs. 82 and 87.)

FIG. 87

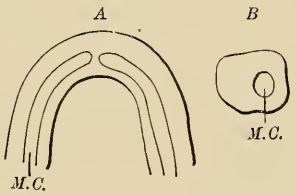

Showing Meckel's cartilage (*M.C.*) in longitudinal and transverse section.

FIG. 88

Osteology of hare-lip. (Museum of the Philadelphia Dental Coellge.)

It acts as a support to the fetal jaw, undergoes atrophy at about the sixth month of gestation, and at birth but few fragments are found near the symphysis. At birth ossification has occurred, and the bone consists of two halves united by a fibrous symphysis in which ossification takes place during the first year.

The end of the cartilage in the base of the inferior maxillary process becomes the future malleus (one of the bones of the middle ear). The portion of the cartilage running from the malleus to the formed bony lower jaw becomes transformed into the internal lateral ligament of the inferior maxilla. (Hertwig.)

A case of failure of development of the intermaxillary bones has been reported,[1] the space between the cuspid teeth being about one-eighth inch.

[1] Jeffery, British Dental Journal, July, 1904.

It is to be remembered that these processes are formed by the outgrowth of the mesoblastic layer of the blastoderm, and are covered by epithelial tissue springing from the epiblast. Both are concerned in the formation of the teeth. Epithelium is reflected over the face and oral cavity. All tissues between these layers of epithelium excepting the dental band and enamel organs and the nerves are of mesoblastic origin.

DEVELOPMENT OF THE TEETH.

At about the sixth week of gestation, while the maxillary processes are but ill-defined masses of mesoblastic tissue surrounded on all sides by epiblastic tissue (Fig. 89), the "*dental band*" develops as a continuous depression of the stratum Malpighii of the mucous membrane extending from end to end of the fetal jaw (Figs. 90, *b*, and 91, *b*), over which depression is a mound of epithelial cells developed from it, and called the "dental ridge" (maxillary rampart of Kolliker and Waldeyer (Fig. 92, *mr*).

FIG. 89

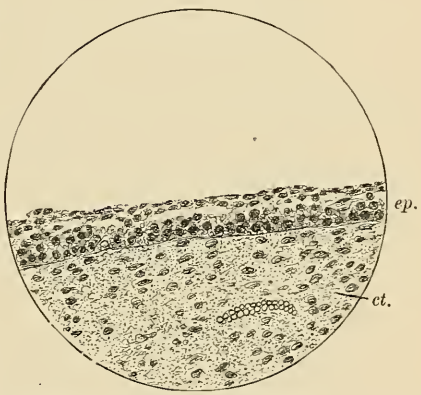

Porcine embryo: *ep*, epithelium, infant layer or stratum Malpighii; *ct*, embryonal connective tissue with large intercellular interspaces. 1.5 cm. × 250. (Sudduth.)

At ten points on these bands in each jaw, at about the seventh to the eighth week, a further depression of the stratum Malpighii occurs, of a more or less definite saccular form, the sac also containing embryonic epithelial cells (Figs. 90, *c*, and 92, 3). This enlarges by an interiorward growth of epithelial cells, while the attachment to the mucous membrane remains constricted. At the ninth week the mesoblastic tissue beneath has somewhat condensed, evidencing the first appearance of the dentinal papilla. At this stage the cord (enamel organ) has been likened in appearance to a Florentine flask (Fig. 93, 2). The dentinal papilla pushes up the base of the enamel organ, which gradually adapts itself over the papilla, assuming first the shape of a Phrygian cap (Fig. 94), and finally a saddle shape (Fig. 95). Just before the connection of the enamel organ with the epithelium of the mucous membrane is lost (as shown in Fig. 95); the cord for the corresponding permanent tooth is given off from the side of the temporary cord. Fig. 95, *cp*, shows this after the separation.

At the sixteenth week the enamel organ has developed so as to contain three distinct formative parts concerned in enamel deposition.

1. Next to the papilla the cells of the stratum Malpighii develop into nucleated columnar cells, collectively defined by an inner and an outer limiting membrane; the ameloblasts, the office of which is to deposit enamel (Fig. 97, *e*, and Fig. 99, *c*).

2. Those next interior develop into large cells nutritively associated with the ameloblasts and collectively called the stratum intermedium (Fig. 99, *b*); also shown in Fig. 97 between *b* and *c*).

3. Those in the central portion of the enamel organ are large cells rich in calcific material and polygonal from mutual pressure, and called collectively the stellate reticulum. They furnish the first nutritive material for the enamel cells (Fig. 94, 1, and Fig. 97, *a*).

The dentinal papilla develops a reticulum of bloodvessels, nerves, and branched stellate connective-tissue cells lying in a gelatinous matrix. Upon the surface of the papilla elongated nucleated connective-tissue cells called odontoblasts are found, the office of which is to deposit dentin (Fig. 99, *e;* also Fig. 122, *Od.*). About the enamel

FIG. 90

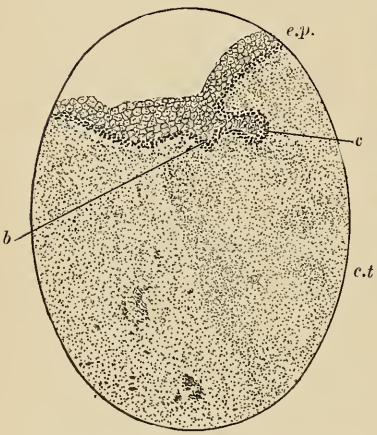

Vertical section through band from jaw of porcine embryo: *ep*, epithelium; *b*, band; *c*, cord; *ct*, connective tissue. 3.5 cm. × 60. (Sudduth.)

FIG. 91

Longitudinal transverse section of the inferior maxilla of a porcine embryo: *b*, band, solid at anterior portion, but divided posteriorly into band and lamina. 3 cm. × 40. (Sudduth.)

organ and dentinal papilla a fibrous sac develops from the mesoblastic tissue, incloses them, and is called the follicle wall (Fig. 95, *c. ct.*), and will become the pericementum or cementum organ. The entire wall and its inclosures are called the dental follicle (Fig. 95). At the sixteenth week the cord of the temporary enamel organ gives off from its side a cord which will form the enamel organ of the succeeding permanent tooth, and a cord is given off from the mucous membrane for the first permanent molar (Fig. 95, *cp.*). At the seven-

FIG. 92

Section of jaw, embryo of pig, showing growth of enamel organ: 1, epithelium; 2, stratum Malpighii; 3, first stage in growth of enamel organ of temporary tooth; 4, embryonic connective tissue; 5, developing bone of jaw; *mr*, maxillary rampart. (Andrews.)

teenth week dentin deposition begins by the extrusion of small calcospherites formed within the odontoblasts, composed chemically of calcium and magnesium salts combined with albumin, a combination known as calcoglobulin. A cement substance is formed within the odontoblasts in a manner similar to the formation of interprismatic substance in the ameloblast (Fig. 101). This is extruded and the calcospherite pushed into it. An examination of Fig. 123 shows this (as black lines). These calcospherites are evidently piled

into the cement substance previously deposited against the ameloblasts, and later against each other, and around protoplasmic prolongations of some of the odontoblasts, which prolongations remain in similarly compiled tube-like structures known as tubule walls or sheaths of Neuman, while the odontoblasts themselves recede, leaving behind them a portion of their substance in the tubules, and known

Fig. 93

Section of jaw, embryo of pig, showing growth of enamel organ: 1, epithelium; 2, second stage in growth of enamel organ; 3, embryonic connective tissue. (Andrews.)

as the dentinal fibrils. They finally persist upon the surface of the pulp (Figs. 99, 100, 110, 122). Fig. 123, a stained specimen of formed dentin, shows the arrangement of the compiled calcospherites. It is apparently almost analogous to enamel formation. After some dentin has been deposited enamel deposition begins (at about the fifth month). The ameloblasts in like manner form within themselves calcospherites or enamel globules, also an amorphous substance

called interprismatic cement substance. Both are calcoglobulin, and yet contain less organic matter, at least finally, than the dentinal calcoglobulin.

The ameloblast first extrudes a drop of interprismatic cement substance against the dentin, and into it deposits an enamel globule. (Williams.) (Fig. 101, *e*.) This is repeated, the ameloblasts meanwhile receding, the result in finished enamel being a rod composed of enamel globules united in a row by intervening layers of inter-

Fig. 94

Section of jaw, embryo of pig, showing growth of enamel organ and dentin germ: 1, enamel organ; 2, dentin germ; 3, growth of jaw; 4, tongue. (Andrews.)

prismatic cement substance. Williams demonstrates plasmic strings which unite the various enamel globules to each other—probably these give the accurate relation end to end. The scheme of formation is shown in Fig. 101, and the orderly arrangement in Fig. 118. The hexagonal arrangement shown in transverse section (Fig. 119, *B*) is due to mutual pressure of the globules. Each rod is united laterally to its neighbor by interprismatic cement substance, which flows there during deposition of each layer of the enamel. The striæ of the enamel represent periods of incremental activity. That the

enamel rod is not formed by calcification of the ameloblast is proved by the fact that the ameloblast lies at an angle to the developing rod.

FIG. 95

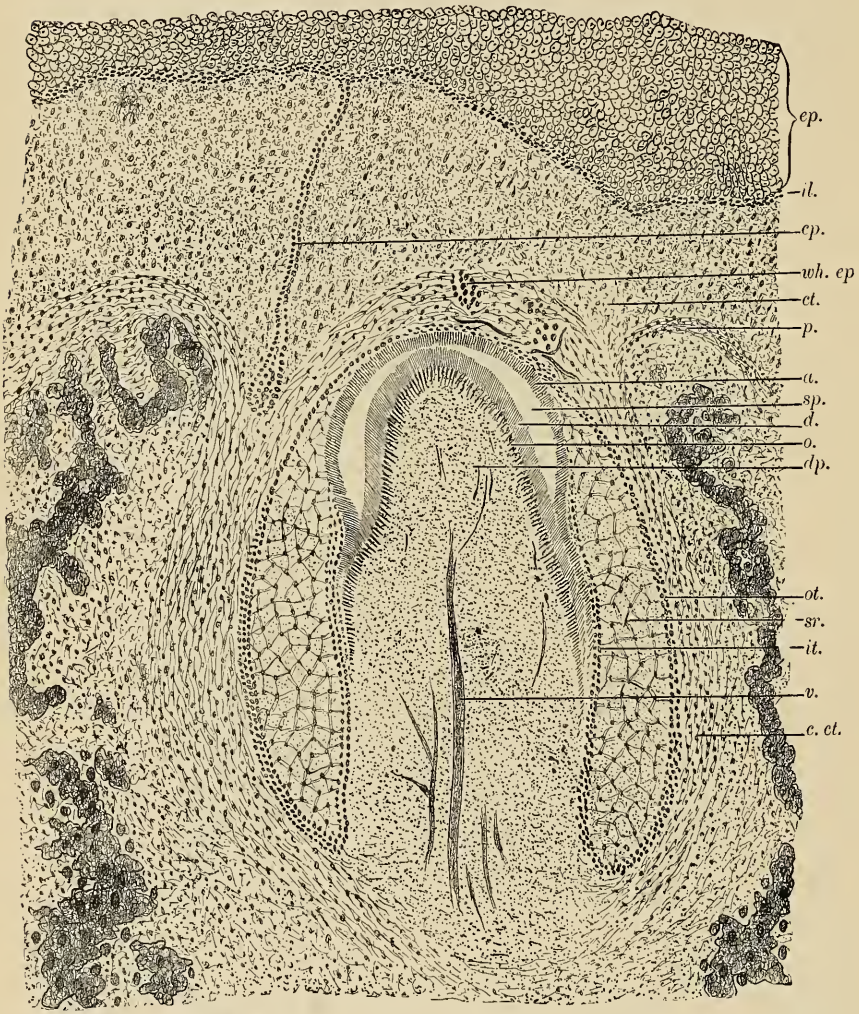

Vertical transverse section of jaw of porcine embryo, injected: *ep*, epithelium, with (*il*) infant layer; *a*, layer of ameloblasts; *o*, layer of odontoblasts; *cp*, cord for permanent tooth; *ot*, outer tunic; *it*, inner tunic; *sr*, stellate reticulum; *wh. ep*, whorls of epithelium forced from outer tunic and stellate reticulum; *d*, dentin; *dp*, dentinal pulp; *v*, bloodvessels of pulp; *ct*, connective tissue; *c. ct*, follicular wall; *p*, periosteum; *sp*, space. 10 cm. × 60. (Sudduth.)

The function of the stellate reticulum is to furnish calcoglobulin for the first enamel deposition. This is probably elaborated in the

stratum intermedium and passed on to the ameloblasts, which construct the calcospherites and interprismatic cement substance. After the first deposition of enamel the stellate reticulum disappears and the papilla-like structure of the stratum intermedium comes into relation with the capillaries of the follicle wall, from which its cells derive further nutrition and become the originators of the calcoglobulin used in enamel deposition (Fig. 101, *D*, in which *b* of Fig. 97 is supposed to have disappeared). After enamel completion the ameloblasts and remains of the enamel organ persist as Nasmyth's membrane, a structure epithelial in character, $\frac{1}{500}$ in. in thickness

FIG. 96

Nasmyth's membrane, showing marks of hexagonal ends of enamel prisms. (Section by Barrett.)

(Hopewell-Smith), and quite resistant to acids. Andrews[1] describes this as somewhat horn-like and believes it due to a final merging of the ameloblasts and cells of the stratum intermedium with an imperfect degree of calcification. M. T. Barrett shows that its under surface may bear the hexagonal impress of the enamel rods (Fig. 96). As the tooth is pushed up the enamel organ is carried with it, but leaves behind it epithelial remnants which become included in the follicle walls as the epithelial root sheath of Hertwig (Fig. 98). These are claimed by Hertwig to be epithelial remains or resting cells in the pericementum, which have been described by Black as pericemental glands. As shown by Kirk, these structures have been previously described by Hertwig as an epithelial root sheath, the remains

[1] Dental Cosmos, 1912, p. 53.

or trailings of the enamel organ left as the tooth advances through the area previously wholly occupied by the enamel organ. During the development of the follicle, bone is formed in islets which appear

Fig. 97

Section of developing tooth of an embryo calf: *a* and *b*, nuclei of reticulum of enamel organ, showing spongiose character; *c*, outer ameloblastic membrane; *d*, inner ameloblastic membrane; *e* and *f*, enamel globules faintly showing nuclear network. × 1000. (Williams.)

in the mesoblastic structure between the follicle wall and the periosteum (Figs. 92 to 95). These gradually coalesce until a bony wall is formed which constitutes the greater bulk of the fetal jaw. The cavities in the bone are called crypts, are divided by septa, and are

nicely shown in Fig. 104, which also shows the relation of three permanent tooth sacs to those of their predecessors. In this figure the outer plate of bone is removed, and one is looking at the outside of the sac or follicle wall, of which Fig. 102 is a transverse section.

Fig. 98

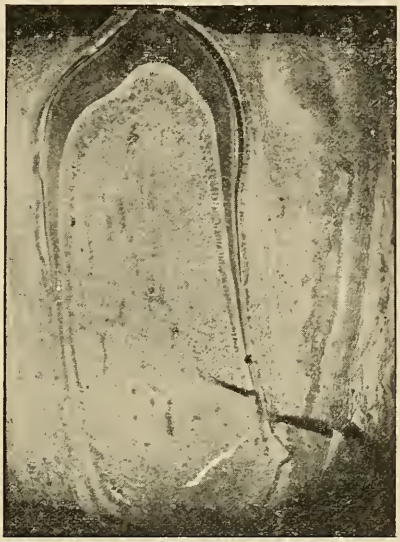

Developing tooth showing Nasmyth's membrane over enamel; also, Hertwig's root sheath. (See text.) (Section by Addison.)

Fig. 102 shows a dental follicle in an advanced stage of enamel and dentin development, viz., at birth. Root formation then begins, and is carried on by the odontoblasts in the papilla and cementoblasts in the follicle wall (Fig. 110). The odontoblasts in the papilla form dentin, which protrudes beyond the dentin covered by enamel. In this first formed dentin are spaces containing organic matter, and collectively known as the granular layer of Tomes (Fig. 124, *J*). The tubules near this are highly branched and anastomotic. Coincidently with dentin formation the osteoblasts in the follicle wall also develop within themselves calcospherites and probably cement substance, which together they deposit as cementum against the dentin as a modified bone (subperiosteal deposition) and recede, leaving some osteoblasts in lacunæ (Figs. 105 and 124, *K*). The finished cementum shows strata representing periods of incremental activity (Fig. 124). It will be noted that the general mode of calcospherite and interspherite cement substance formation and deposition is practically the same in the ameloblasts, odontoblasts, and osteoblasts;

not as to finished product, but in principle. The follicle wall is caught between the developing cementum and bone, and persists as a pericementum, the fibers of which attach them to each other (Figs. 102, *C*, and 110, *PER*). Fig. 103 shows the various stages of root formation, the bifurcation of roots being effected by an upward pressure by the follicle wall against the pulp, in the same manner as the

Fig. 99

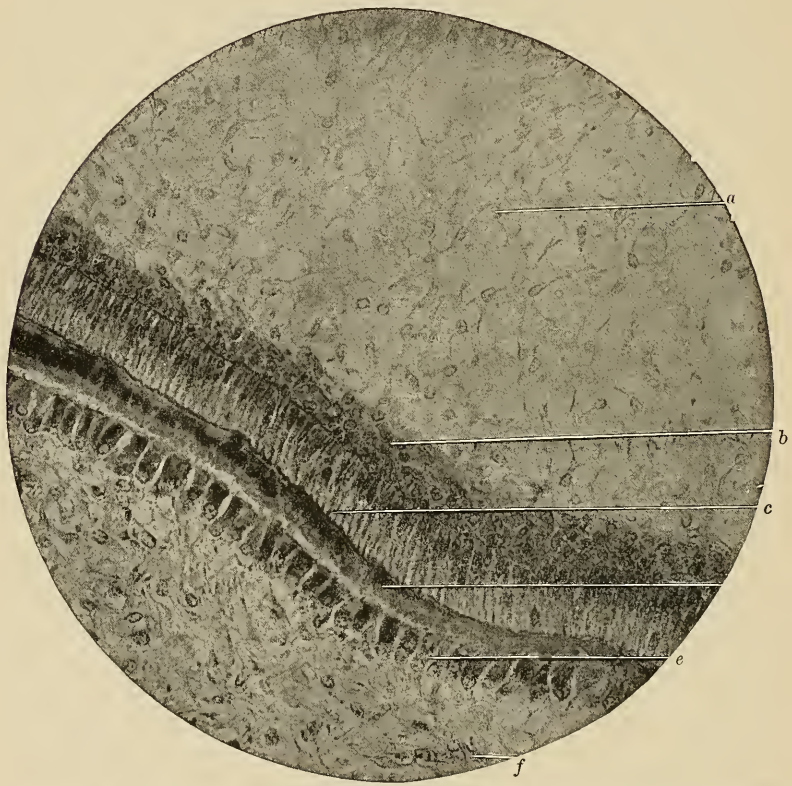

Section of developing tooth of an embryo calf: *a*, stellate reticulum of enamel organ; *b*, stratum intermedium; *c*, ameloblasts; *d*, dentin; *e*, odontoblasts; *f*, blood-vessels—corpuscles *in situ*. × 275. (Williams.)

enamel organ is indented by the papilla. The lower first permanent molar in Fig. 115 and the third figure in Fig. 103 show plainly, by the aid of a little imagination, how this is accomplished. The diagram (Fig. 107) gives the ages at which root calcification is complete in the temporary set. The end of the root is composed entirely of cementum and is therefore finished by the follicle wall (pericementum).

FIG. 100

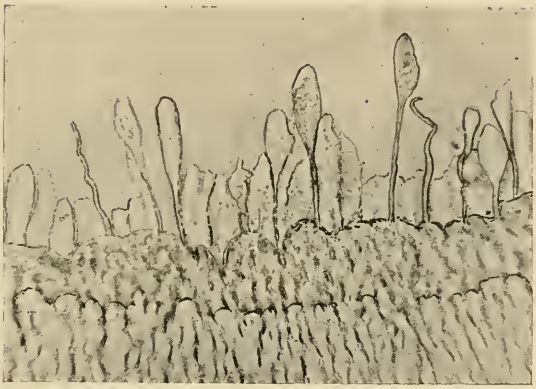

Section of growing tooth of calf at birth, showing fibrils, fibril cells, and odontoblasts; also the layer of calcoglobulin and the forming dentin. (Andrews.)

FIG. 101

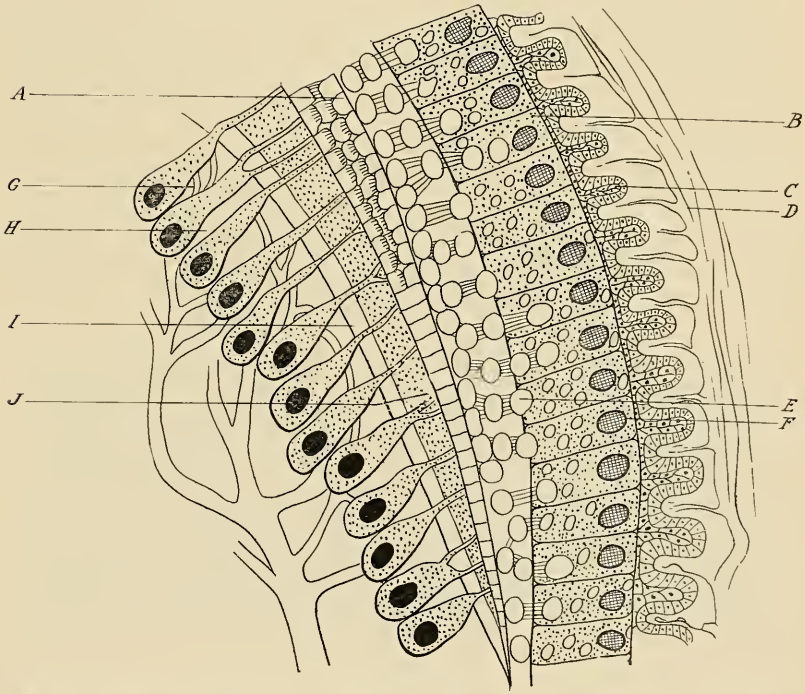

Mode of enamel deposition: *A*, formed enamel; *B*, ameloblasts; *C*, secreting papillæ of stratum intermedium; *D*, bloodvessels in external fibrous coat and to secreting papillæ; *E*, enamel globules with connecting plasmic strings; *F*, nuclei of ameloblasts; *G*, blood supply of odontoblastic layer; *H*, odontoblasts; *I*, unformed dentin; *J*, formed dentin. The interprismatic cement substance is shown as smaller bodies within the ameloblasts. Semidiagrammatic. (Williams.)

The Permanent Teeth.—These are nearly all formed from cords given off at the sixteenth week from the sides of the cord of the corresponding temporary teeth as far back as the bicuspids, which are given off from the cords of the first and second temporary molars (Fig. 95); the sacs are formed and lie lingual to and above the sacs of the temporary teeth (Fig. 113 and 114). At the fifteenth week of fetal life the cords of the first permanent molars are given off from the mucous membrane, at the third month after birth the cord for the second molar is given off from that of the first molar, and at three years after birth the cord of the third molar arises from that of the second molar. After eruption and root completion in the temporary teeth and some development of the crowns of the permanent teeth the relation of the crypts of the permanent teeth to the temporary teeth is as shown in Figs. 112 to 115.

Fig. 102

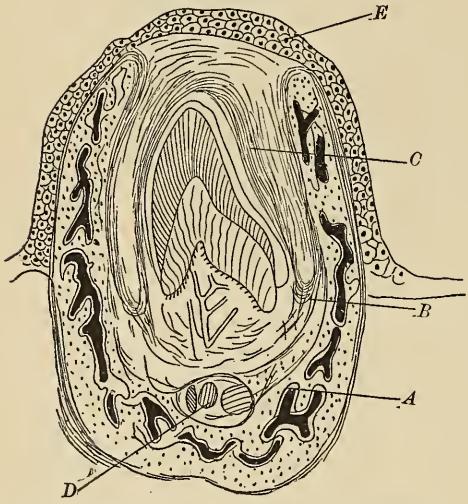

Developing tooth at birth: *A*, developing bone; *B*, tissue reflected from follicular wall and forming alveolar periosteum; *C*, follicular wall; *D*, vessels and nerves; *E*, epithelium of gum.

Fig. 103

Pulp cavities of the superior first bicuspid, from the seventh to the twelfth year. (Broomell.[1])

[1] Anatomy and Histology of the Mouth and Teeth.

The roots of the permanent teeth are developed during the period of the descent of their crowns into the alveoli of the temporary teeth,

Fig. 104

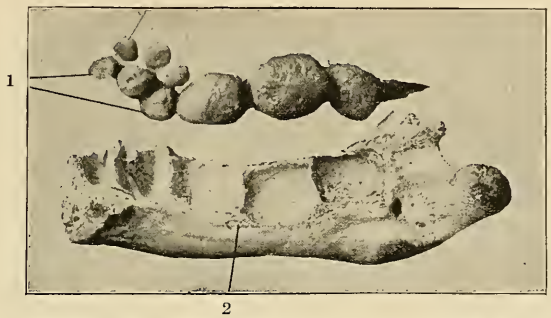

1, tooth sacs of deciduous teeth turned out of crypts; 2, lingual surface of mandible. The interior of the crypts and septa shown. (Broomell.)

which occurs coincidently with the resorption of the temporary roots, which permits the descent. After the shedding of the deciduous teeth

Fig. 105

Transverse section through fused roots of molar tooth, showing interdentinal cementum: 1, interdentinal cementum. × 30. (Broomell.)

and the eruption of the permanent ones the roots are completed after variable periods, graphically shown in Fig. 116. Coincidently with

this the jaws enlarge in all directions by resorption and new deposition of bone. Both the development of the crowns and roots are similar to those occurring in the temporary teeth.

Fig. 106

Persistence of Nasmyth's membrane in occlusal fissure. (M. F. Barrett.)

The Histology of the Teeth.—Some of the histology of the teeth has been given with the description of the development of the teeth, and extended explanation is unnecessary in a work devoted to dental pathology. Some of the structures, however, require some notice as a basis for pathological variations, and will be specially described.

Fig. 107

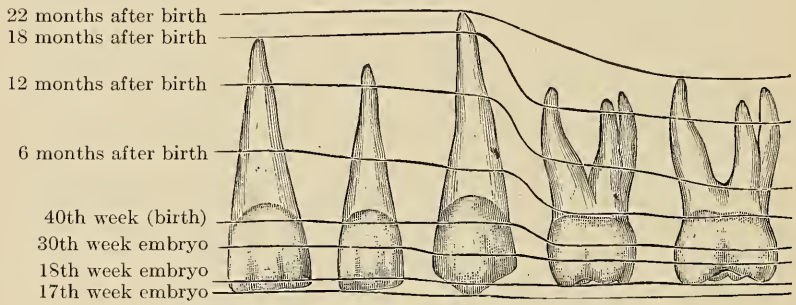

Calcification of the deciduous teeth. (Peirce.)

The Enamel.—The rods radiate as shown in Fig. 117, but in the fissures Nasmyth's membrane persists and rarely completes a perfect

groove, so that a convenient location for food and microörganisms remains, and dental caries is most common at this point. The rods are wavy in outline, though sometimes twisted or gnarled.

Fig. 108

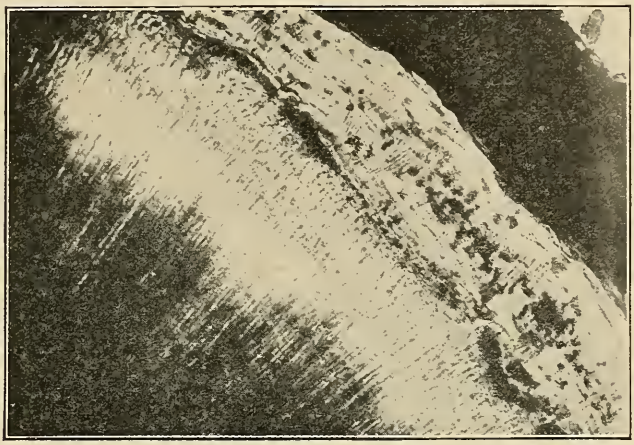

Injected tooth, showing connection between dentinal tubules and lacunæ of cementum. (Von Beust.)

Fig. 109



Injected tooth, showing connection between dentinal tubules and enamel tubes. (Von Beust.)

They are hexagonal in cross-section (Fig. 119). The enamel is thin at the cervix, and is usually overlapped by the cementum, but may

overlap it, or lie edge to edge with it (Choquet). The striæ of Retzius are pigmented bands, or colored increment. The stripes of Schreger are cloud-like markings, shown by Caush to be due to the presence of tubes in the enamel and containing organic matter.

Caush and, later, others have shown that the enamel contains tubes into which the dentinal fibrils penetrate (see Figs. 179, 182, and 184). The outer surface also may contain openings indicative of present or past organic contents. Each rod is composed of

Fig. 110

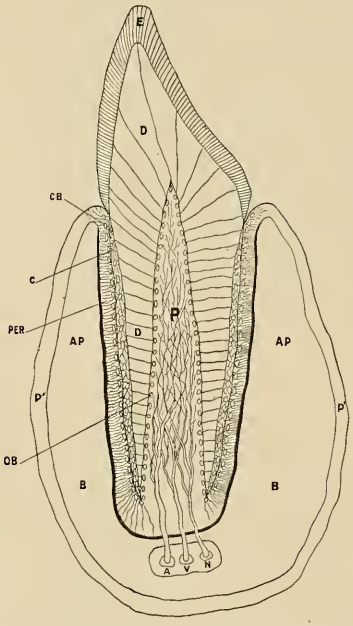

Diagram illustrating root development and condition of an incomplete root: *E*, enamel; *D*, dentin; *P*, pulp containing odontoblasts, *OB;* *AP*, alveolar process; *B*, bone; *C*, cementum; *P'*, periosteum of bone continuous with the pericementum; *PER*, pericementum containing cementoblasts, *CB;* *A*, *V*, *N*, arteries, veins, and nerves.

Fig. 111

Condition of third molar at thirteen years of age. (Skiagraphed by Custer.)

Fig. 112

Showing the relation of permanent tooth follicle to the root of the temporary tooth.

enamel globules united end to end by interprismatic cement substance, which also unites adjoining rods longitudinally (Fig. 118). Von Beust[1] has shown by injecting pulp canals with a strong solution of fuchsin, also by an arrangement merely dipping the root apex in the above solution, that force or even capillarity will carry the staining fluid through the dentin into enamel and cementum (see Figs.

[1] Dental Cosmos, June, 1912, p. 660 and 662.

Fig. 113

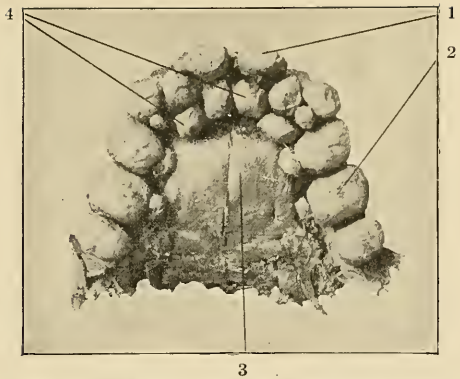

Tooth follicles for deciduous and permanent teeth, three months after birth: 1, 2, tooth sacs of deciduous teeth; 3, periosteum of hard palate; 4, tooth sacs of permanent teeth. (Broomell.)

Fig. 114

Deciduous molars with tooth sacs for permanent bicuspids attached to the gingival tissue. (Broomell.)

Fig. 115

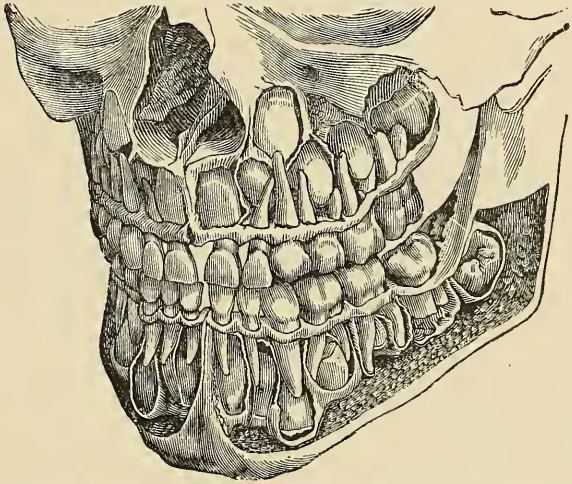

View of the upper jaw of a child, aged about six and one-half years. The anterior teeth are slightly separated by the partially developed permanent teeth, lying behind or posterior to them, pushing forward to occupy a more anterior position. The equal height which the crowns of the deciduous teeth originally occupied is also being disturbed by the advancing permanent teeth. (Peirce.)

107 and 108), and shows conclusively the presence in enamel of canals communicating with the dentinal tubules and at least permeable by fluids; also that the dentin and cementum communicate by canals.

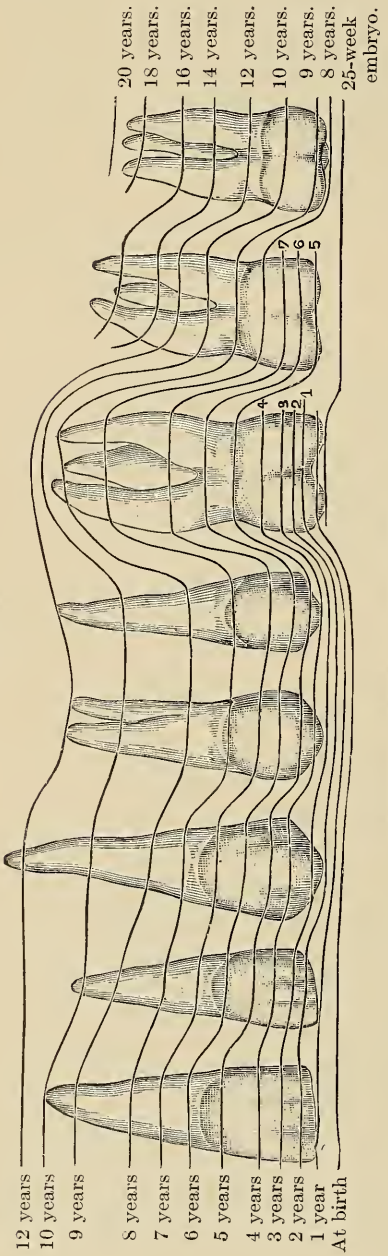

Fig. 116

Calcification of the permanent teeth. (Peirce.)

The Dentin.—The dentin is composed of tubules and their contents and intertubular substance. Each tubule contains a prolongation of an odontoblast, also called a "fiber of Tomes," or dentinal fibril. The wall, differing from intertubular dentin, is called the sheath of Neuman (Fig. 121).

The tubules are wavy in direction, but radiate in the crown and lie at right angles to the pulp in the root dentin. At the periphery the tubules branch and anastomose freely, and some may penetrate the enamel. There are also fine anastomatic connections at other points (Fig. 121). Both the tubules and intertubular substance seem to be composed of calcospherites and cement substance (Fig. 123).

The tubules are curved in outline and sometimes show a series of short, sharp curves on a general curved level at the points at which a new period of increment has occurred. They are the stripes of Schreger in dentin or "incremental lines" of Salter (Fig. 190).

The Pulp.—This consists of a gelatinous matrix in which are imbedded branched connective-tissue

Fig. 117

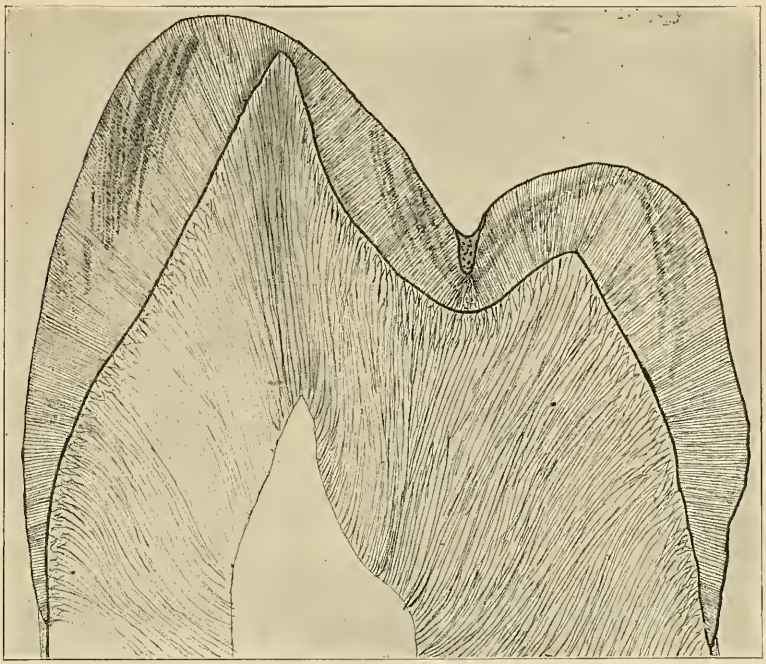

Diagram of enamel-rod directions and tubule curves. From a photograph of a bucco-lingual section of a superior bicuspid. (Noyes.)

Fig. 118



Section of enamel of human tooth. Photographed with Zeiss apochromatic lens and Powel and Leland apochromatic condenser. The optical parts accurately centred and the focus "critical." The enamel rods are seen to be resolved into distinct sections (enamel globules), the cement substance often passing entirely between the sections. × 400. (Williams.)

cells. The odontoblasts lie upon the surface next to the dentin, with their fibrils extending into the tubules up to the enamel, and, as shown by Caush, often into it, forming organic matter in enamel, and in some cases accounting for a sensitivity which is, however, rare.

Fig. 119

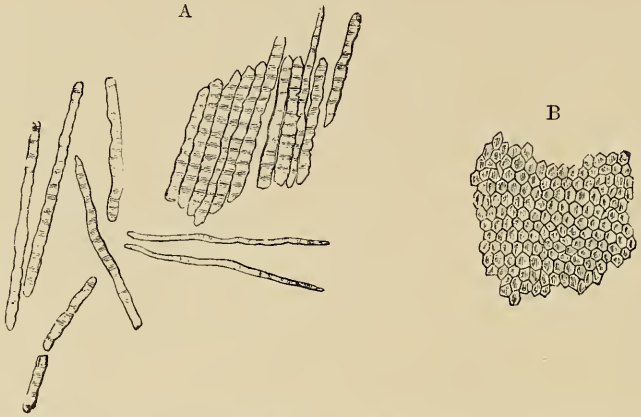

Enamel prisms: *A*, fragments and single fibers of the enamel isolated by the action of hydrochloric acid; *B*, surface of a small fragment of enamel, showing the hexagonal ends of the fibers. × 350.

Fig. 120



Enamel showing both striation and stratification. × 80 (about). (Noyes.)

One or more arteries enter the apical foramen or by several foramina, and several veins may emerge. The arteries subdivide in the

Fig. 121

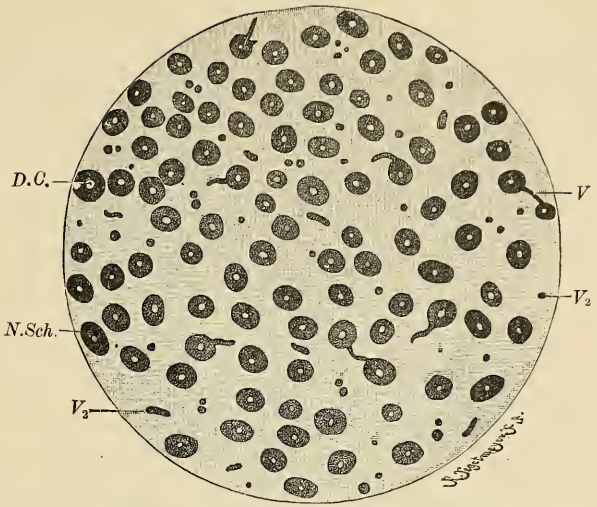

Transverse ground section through the dentinal tubules of the first molar of a child, aged seven years: *V*, small connecting tubule. Koch's and Golgi's methods combined. × 1200. (Röse.)

Fig. 122

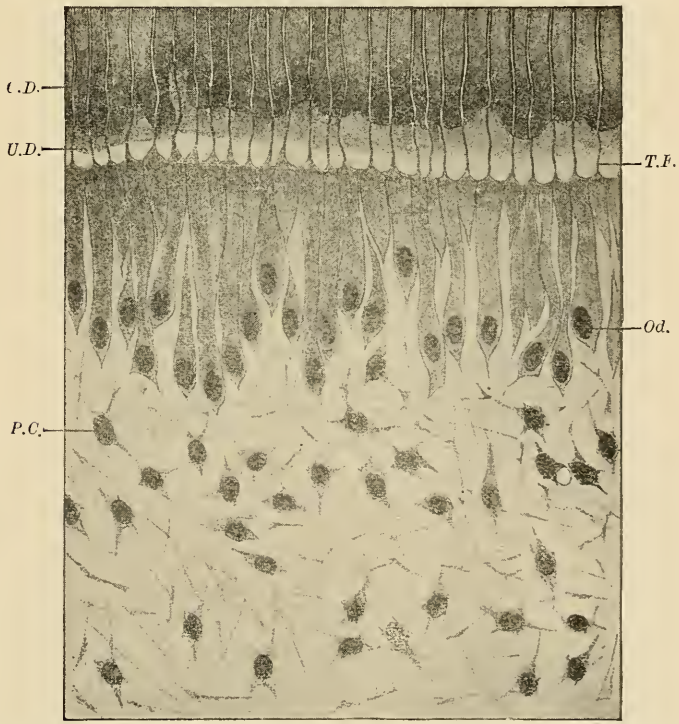

Section of pulp, showing the relations of the odontoblasts to the dentin; *Od.*, odontoblasts; *T.F.*, Tomes' fibers—odontoblastic processes; *U.D.*, uncalcified dentin; *C.D.*, calcified dentin; *P.C.*, pulp cells. × 800. (Röse and Gysi.)

central portion of the pulp and form a rich network of capillaries beneath the odontoblasts.

The arteries are not branches entering the foramen directly from the bone, but rather branches of arteries in the pericementum.

The arteries of the pulp soon lose almost entirely their muscular coat, and their external coat is reduced to an inconsiderable amount of fibrous connective tissue. There is little if any anastomosis of the arteries of the pulp, so that collateral circulation is impeded, though not necessarily prevented, as pathological cases show. The veins remain for an unusual distance without a muscular coat, and are stated by Hopewell-Smith to be non-valvular and non-collapsible.[1] These histological data have great clinical significance. (See Diseases of the Pulp.)

FIG. 123

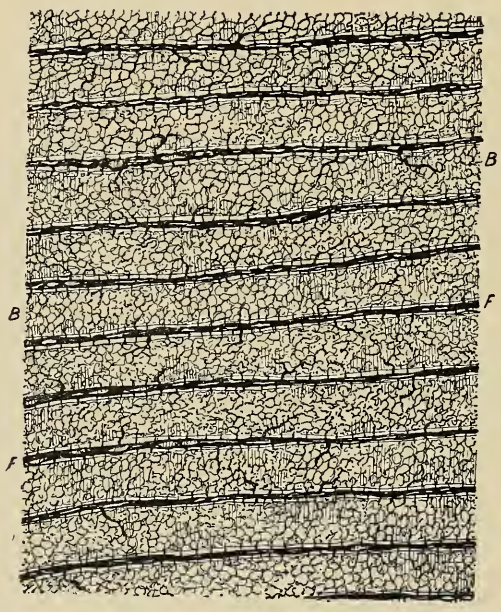

Main mass of dentin of a temporary tooth, stained with chlorid of gold, decalcified with acetic acid: *F*, *F*, dentinal fibers, partly vacuolated; *B*, *B*, basic substance, traversed by a reticulum. × 1200. (Hart.)

The vascularity of the pulp decreases with age. "In young teeth there are a number of arterial trunks entering the apical foramen, which lessen in number as the passage lessens in size." Finally only one may enter. (Black.)

The passage of arteries and veins through a constricted foramen has important consideration in connection with pulp diseases. It

[1] Dental Cosmos, 1907.

has been shown by Stein[1] that the arterial supply is through the bone rather than by direct arterial continuity. (See Venous Hyperemia of the Pulp.)

Mummery[2] recently described the nerves of the pulp as follows:

The nerves enter by several bundles, and if medullated follow the course of the bloodvessels, give off lateral branches, then lose the medullary sheath, near the periphery of the pulp, where they break up into numerous fine fibers, or axis-cylinders, and combine into a plexus beneath the odontoblasts (the plexus of Raschow).

Fig. 124

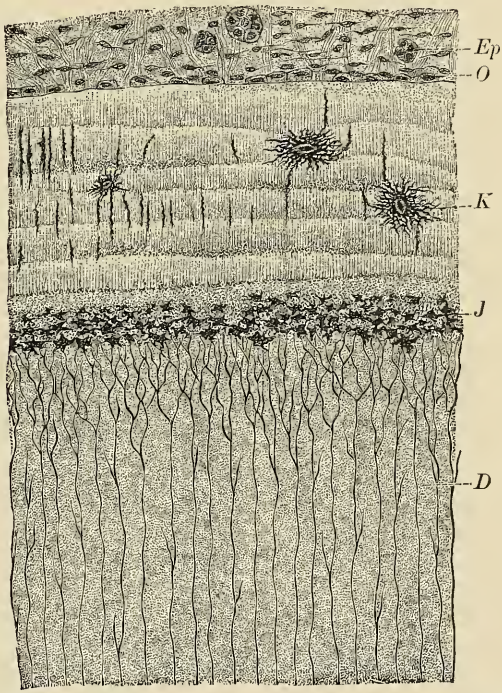

Ground section through the root of a human premolar: *D*, dentin; *K*, cement corpuscles; *O*, osteoblasts; *Ep*, remains of Hertwig's epithelial root sheath or pericemental glands of Black;[3] *J*, interglobular spaces. × 200. (Röse.)

From this plexus fine fibers pass between and around the odontoblasts, which may be inclosed in a fine network. From these networks fine fibers pass into the tubules and continue to the periphery of the dentin and into the anastomotic fibrils.

The phenomena of sensitive and hypersensitive dentin shown an evident physiological connection. The nerves of the pulp do not

[1] Items of Interest. [2] See Dental Brief, 1912.
[3] The editor has taken the liberty of altering the interpretation.

possess tactile sense; so their pains are not localized, but reflected, as a rule. The pulp contains no demonstrable lymphatics, though lymph spaces probably exist; their office is probably performed by the veins, which in other parts may take up this function.[1] The pulp becomes more fibrous and less vascular with age. During health it preserves the translucency of the tooth through its relation with the fibrillæ and under certain circumstances renews its formative activity and produces secondary dentin. The forms of the pulps and pulp cavities are shown in Figs. 128 to 138.

Fig. 125

Section of a tooth pulp: *B.V.*, main bloodvessels of pulp; *C.*, origin of capillaries; *N. T.*, main nerve trunk; *N. F.*, subdivisions of nerve into fibrillæ; *Od.*, odontoblastic layer; *S.D.*, secondary dentin; *C.G.*, masses of calcoglobulin. × 30. (Röse and Gysi.)

The Cementum.—The cementum is a modified bone distributed over the dentin of the root. It meets the enamel either edge to edge, overlaps it, or is overlapped by it (Choquet). In some cases they do not meet at all, and leave the dentin exposed.[2] It contains lacunæ and canaliculi, but only rarely an Haversian canal. It

[1] Green, Pathology and Morbid Anatomy.
[2] Hopewell-Smith, Dental Cosmos, 1909, p. 1375.

contains a fibrillar structure, which represents the remains of Sharpey's fibers (Fig. 126).

The physiological function of the cementum is to afford a means of attachment of the teeth to the maxillary bones through the medium of the pericemental fibers. In case of death of the pulp, and, therefore, of cessation of nutrition of the dentin, the vital relations of the

Fig. 126

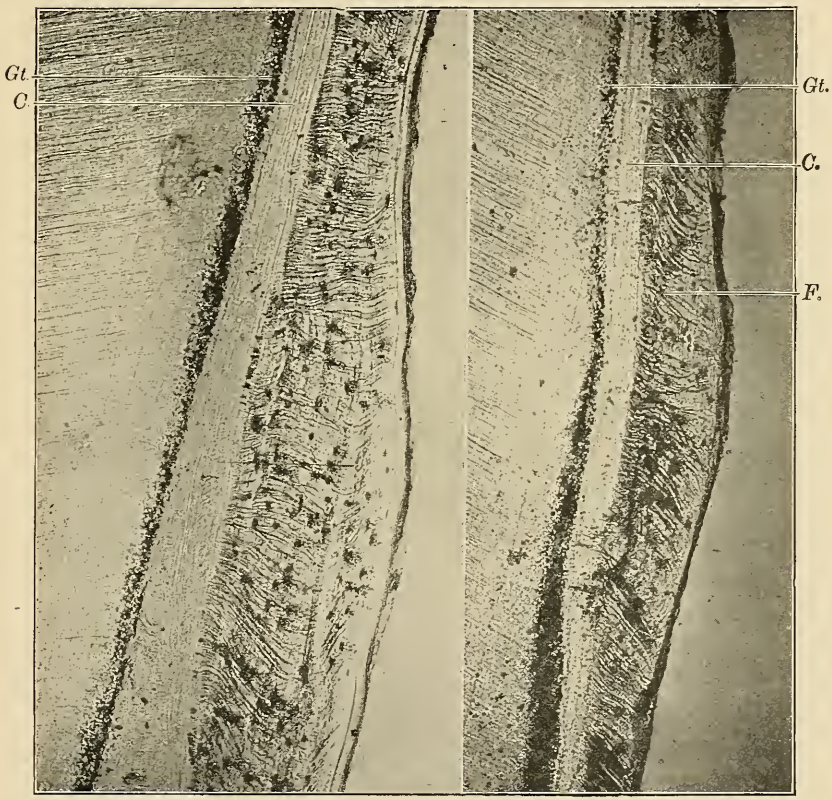

Two fields of cementum, showing penetrating fibers: *Gt.*, granular layer of Tomes; *C.*, cementum not showing fibers; *F.*, penetrating fibers. × 54 (about). (Noyes.)

cementum and alveolar process are thus maintained and the usefulness of the tooth assured. Whether the dentin can ever receive nourishment from the cementum after pulp death has never been scientifically shown, and the fact that it may contain dead and even putrefied material while a healthy cementum may persist, renders it extremely doubtful.

The Pericementum.—(*Syn.*, *Peridental Membrane*).—The pericementum is the highly organized remains of the follicle wall. As the alveolar bone and cementum develop on either side of it, it forms also the periosteum lining the alveolus. It is, therefore, the means by which the teeth are retained in their sockets and a certain degree of motion permitted. The pericementum subserves the office of a membranous attachment not altogether unlike that found in the sutures of the cranial bones.

FIG. 127

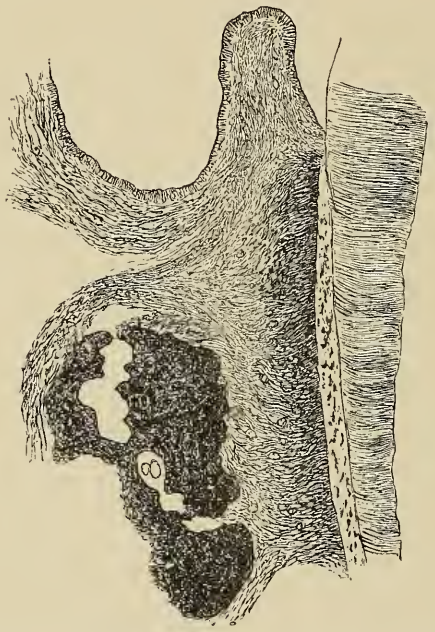

Portion of the side of a root of a tooth, the gum and alveolodental membrane, and the edge of the bone of the alveolus. A band of fibers is seen passing over the surface of the alveolus and dividing, some passing upward into the gum, others passing more directly across to the cementum. Numerous orifices of vessels cut across transversely are seen between the tooth and the bone. (Black.)

It is considered by some observers that there are two distinct portions to the pericementum, cemental and alveolar. Photomicrographs generally do not demonstrate this, and it is a matter of difficulty to imagine the pericemental bands divided into two portions.

It is continuous with the periosteum on the outside of the alveolar process, as the sutural membrane is with the pericranial membrane.

Its outline study divides the pericementum into three portions—a gingival, an alveolar, and an apical portion.[1]

[1] Noyes, American Text-book of Operative Dentistry.

FIG. 128

Transverse section of the peridental membrane in the occlusal third of the alveolar portion (from sheep): *M*, muscle fibers; *Per*, periosteum; *Al*, bone of the alveolar process; *Pd*, peridental membrane fibers; *P*, pulp; *D*, dentin; *Cm*, cementum. (Noyes.[1])

[1] American Text-book of Operative Dentistry.

It is composed largely of white fibrous tissue with interlaced blood-vessels, nerves, and glands. It also contains functional cells, fibroblasts, cementoblasts, osteoblasts, and osteoclasts.

Fig. 129

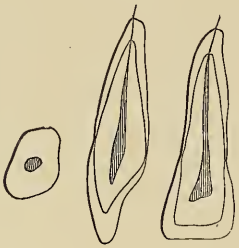

Fig. 130

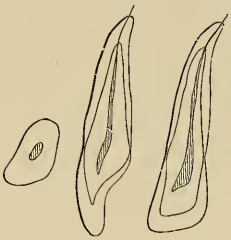

Fig. 131

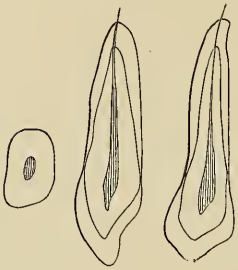

Fig. 132

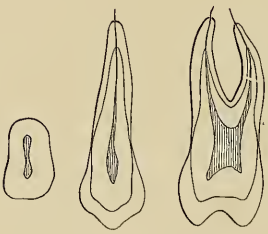

Fig. 133

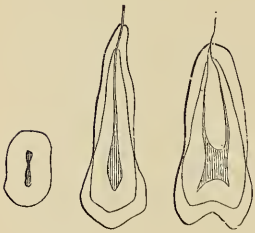

Fig. 134

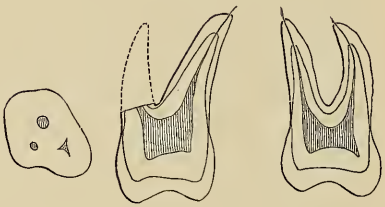

Fig. 135

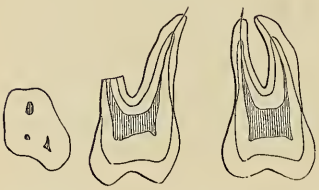

Fig. 136

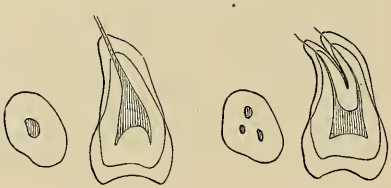

Longitudinal and transverse sections of upper teeth, showing shapes of pulp chambers and their positions.

FIG. 137

Formalin-gelatin casts of pulp cavities, showing pulp irregularities. (Richards.)

FIG. 138

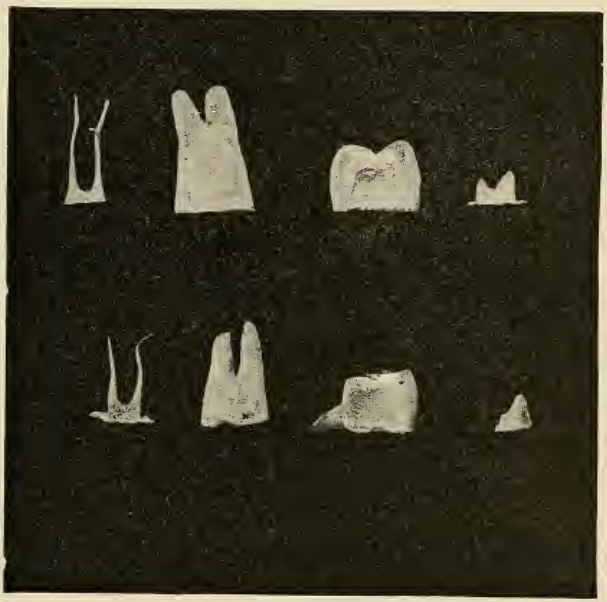

Formalin-gelatin casts of pulp cavities compared with the teeth themselves. (Richards.)

The fibrous tissue is made up of principal fibers and indifferent fibers.[1]

The principal fibers are grouped for the most part in bands or bundles (Fig. 128).

In the alveolar portion these bundles run for the most part from the cementum to a higher point on the alveolar process. The attachment is secured by the penetration of the fibers into either structure. This secures to the tooth, support against direct pressure into the socket and against rotary motion.

Fig. 139

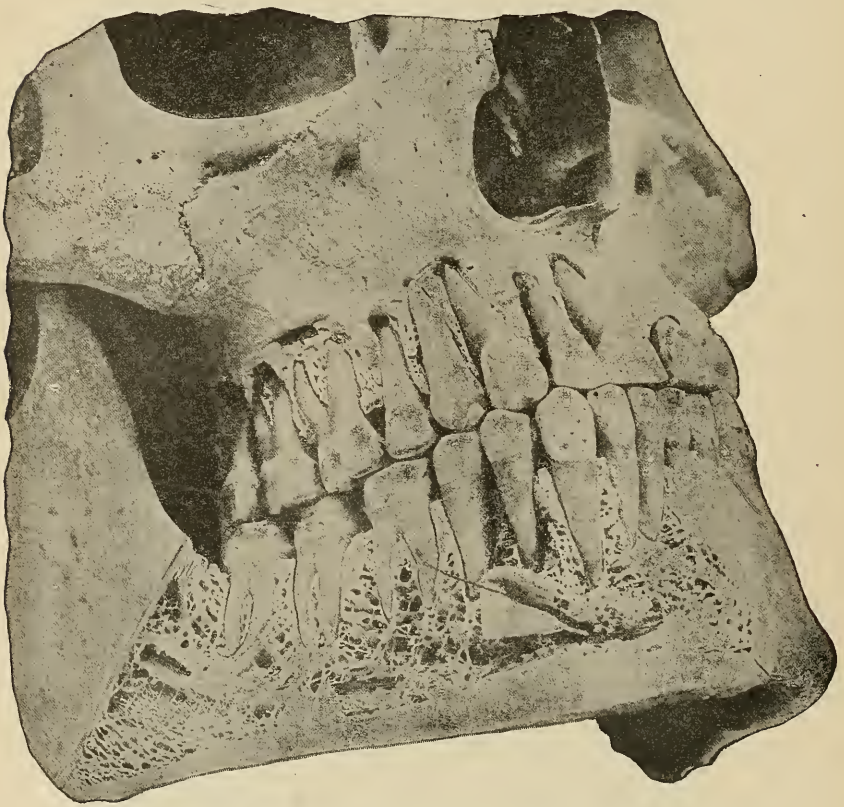

Showing the buccal surfaces of the crowns and roots in position. (Cryer.)

At the apical portion the bands have a fan-like distribution. In the gingival portion the fibers are directed outward and slightly toward the edge of the alveolar process for tooth support, or outward and downward over the edge of the process to become continuous

[1] Noyes, American Text-book of Operative Dentistry.

with the periosteal fibers, or outward and upward with the submucous gingival tissue, to aid in the support of the gum margin. Some of the gingival fibers pass from the cementum of one tooth to that of the next (Fig. 127).

Fig. 140

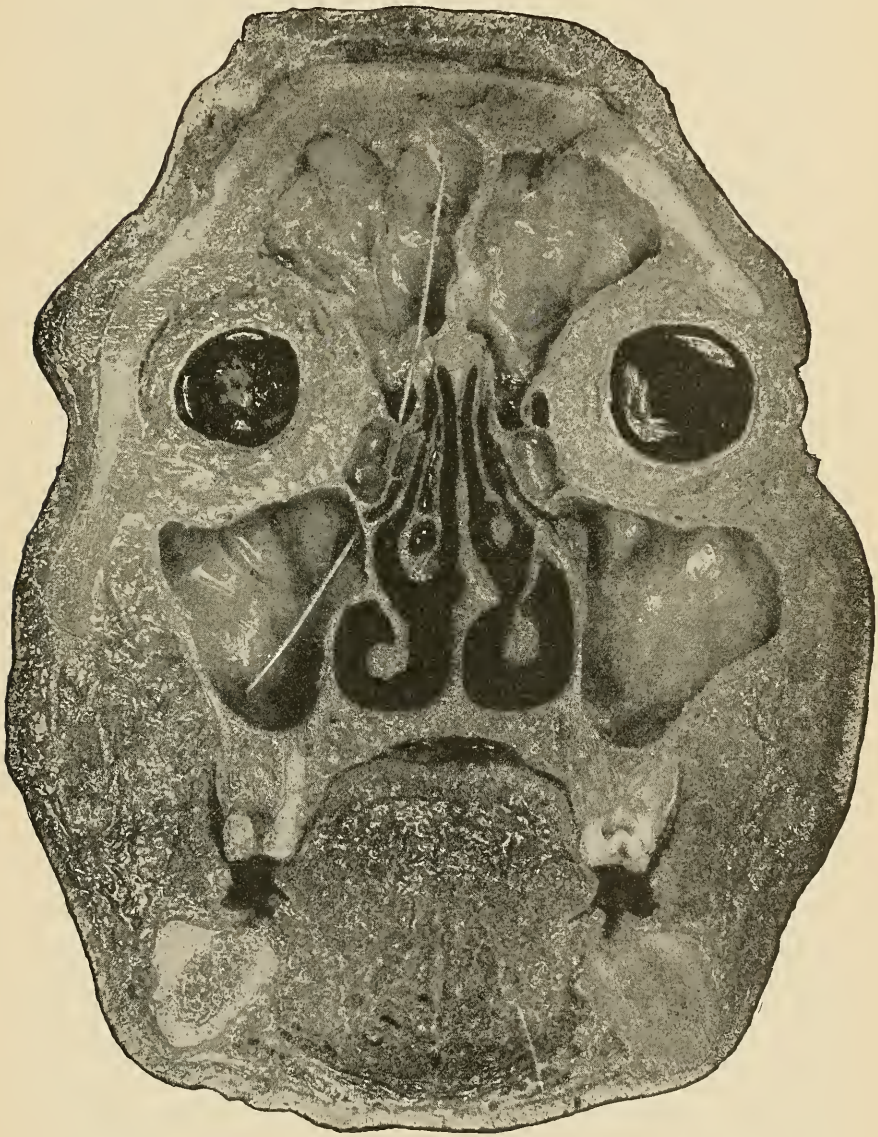

Vertical section of a frozen head, rear view. Shows relations of roots of molars and the maxillary sinus, and of the maxillary sinus with the frontal sinus. Wire passes from the latter through the infundibulum, the hiatus semilunaris, and the ostium maxillare, into the maxillary sinus, establishing a connection. (Cryer.)

The bloodvessels of the pericementum are derived from several sources: (1) From vessels entering the membrane through the Haversian canals of the alveolar process and bone, and anastomosing with branches from the descending arteries; (2) from the vessels of the outer periosteum, coming over the edge of the alveolar process.

It has been shown that the destruction of main arteries as the infra-orbital or inferior dental does not cause pulp death, hence the collateral blood supply is the most important.

There are comparatively few capillaries. The vessels lie mostly in the outer or alveolar half of the pericementum.

FIG. 141

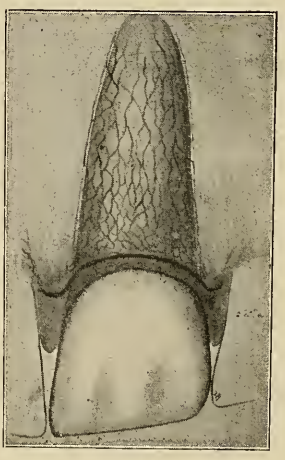

Diagram of glands of peridental membrane. (Black.)

This disposition of the arterial blood supply insures nutrition to the peridental membrane in case of loss of the apical tissue, as in case of apical abscess, and also insures a collateral blood supply to the pulps in case of loss of main arterial trunks, as, for example, in operations upon the inferior dental canal, in which case pulps do not die.[1]

The arteries thus furnishing blood to the teeth are, for the upper jaw: The anterior dental branch of the infra-orbital, to the upper anterior teeth; the superior dental branch of the alveolar, to the upper bicuspids and molars and the bone about their root ends; the descending palatine and its anastomotic connection, the sphenopalatine, supplied to the palatine side of the upper alveolar process, etc.; the alveolar, supplied to the buccal side of the upper alveolar process.

[1] John Bethune Stein has experimentally proved this by operation of removal of the contents of the inferior dental canal. The pulps did not die, and the teeth developed as usual. Items of Interest, May, 1910.

In the lower jaw the inferior dental artery and its incisor branch supply the apical tissues of the lower teeth from the inferior dental canal. Its mylohyoid branch supplies the gums and lingual periosteum of the lower alveolar process, the mental branch supplies the lower buccal process anteriorly, while a branch of the facial artery anastomoses with the mental anteriorly, and the facial sends branches to the coverings of the buccal aspect of the lower jaw posteriorly.

FIG. 142



Glands of Black. Epithelial structures: *Ec*, epithelial cord, apparently showing a lumen; *Cb*, cementoblasts; *Cm*, cementum; *D*, dentin. (See p. 193) (Noyes.)

With the exception of those branches derived from the facial artery, all the blood comes from the internal maxillary artery. Stein has shown that the blood is supplied to the pericementum, which, by collateral circulation, supplies the pulp.

The veins return the blood by similar channels.

The nerves of the pericementum enter by several trunks in the apical tissue, and also enter from the alveolar wall and over the alveolar edge. While their distribution is not yet fully described, some of them possess the tactile sense, as touch upon the teeth is

Fig. 143

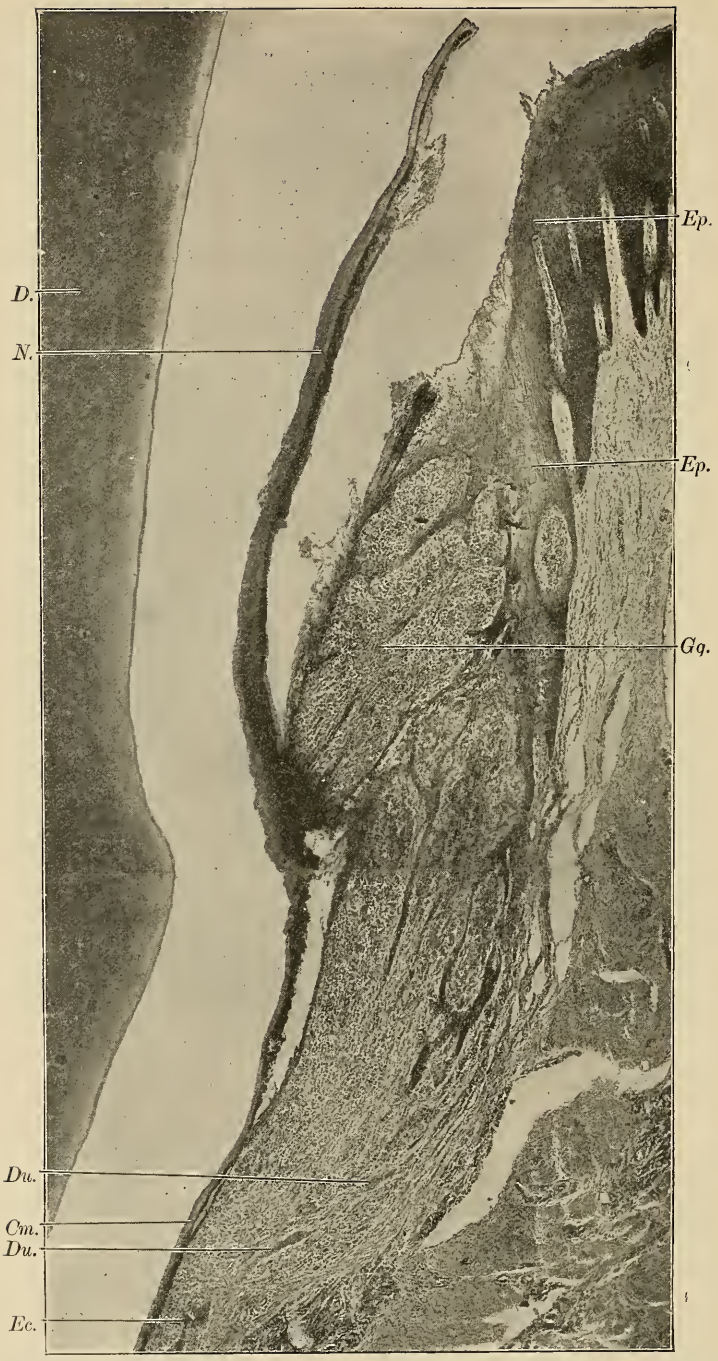

Longitudinal section: *Ep*, epithelium lining the gingival space; *Gg*, gingival gland so-called; *D*, dentin; *N*, Nasmyth's membrane; *Du*, duct-like structure stretching away toward the gingivus from the epithelial cord, seen at *Ec*; *Cm*, cementum, separated from the dentin by decalcification. × 50 (about). (Noyes.)

fully localized. They are derived from the fifth nerve and the sympathetic.

The Pericemental Glands.—Black has described gland-like structures lying in the pericementum, nearer the cementum than the alveolar wall. These are distributed over the root in a network, as shown in Fig. 141.

They are convoluted cords of epithelial cells invested with a delicate basement membrane, and can be traced to the epithelium of the gingival space, but not to the surface.

Traces of a lumen have been seen, which, if established as common, would constitute them as tubes. Their function is not definitely known, but it is presumptive that they may be secreting glands or lymphatics. Some consider these glands as resting epithelial cells derived from the enamel organ during the upward movement of the tooth, *i. e.*, the epithelial root sheath of Hertwig (Figs. 124, 141, and 142). The entrance of bacteria from the gingival space to deep portions of the pericementum, there to develop, may possibly be favored by their presence. They are also considered as the tissue in which cysts arise. (See p. 165.)

Glands of Serres.—At the deepest portion of the gingival space is found a gland-like body which has been given the above name. Its function is not known (Fig. 143).

The Cellular Elements.—The fibroblasts are spindle-shaped cells destined to become mature fibers. They lie among the other fibers. The cementoblasts lie along the cementum and are the cementum builders (Figs. 72 and 110). Osteoblasts are found engaged in bone construction along the alveolar wall.

Osteoclasts, large multinucleated cells, lie at points along the cementum of teeth and alveolar bone. Their office is the removal of bony tissue. They remove both the organic and inorganic material, and their effects are seen upon the cementum and dentin of the roots of teeth undergoing resorption, also upon resorbed alveolar process. The excavations in which they lie at work are called Howship's lacunæ (Fig. 73).

Calcospherites are sometimes found within the substance of the pericemental membrane, and may have some significance in relation to its diseases.

The pericementum in the young is comparatively large and vascular, and in the old becomes much attenuated, more fibrous, less vascular, and subject to degeneration.

Union of alveolar bone and cementum but rarely occurs, though a mechanical attachment by fibrous pericementum may occur. (See Synostosis.) On the other hand, the union of the cementum of one tooth with that of another is not uncommon. (See Concrescence.)

CHAPTER VII.

DENTITION: ITS PROGRESS, VARIATIONS, AND ATTENDANT DISORDERS.

The process of teething, eruption, or dentition comprises that series of vital operations which causes the teeth to leave their crypts in the maxillæ, to pierce the gum, and to take their places in the dental arches. It is a continuation of the process of dental development, and is accompanied and succeeded by root, alveolar, and maxillary developments, which are also to be considered in connection with it.

Physiologically, dentition is divided into (1) the first dentition, or that of the temporary teeth, and (2) the second dentition, or that of the permanent teeth.

Examination of Fig. 102 will show the state of tooth development at a period shortly after birth (a central incisor being under consideration). The crypt is roofed over at birth by a membranous structure. During the period from then to perhaps six months after birth, about one-third of the root will have been formed. (See Fig. 107.) The root end is widely open (incomplete) and the margins are thin and sharp. A very vascular tissue occupies the space between the root and the bone, and fills the interior of the root. Meanwhile the crown cusp will have advanced from the situation shown in Fig. 102 to a point just beneath the mucous membrane, which is pressed up and stretched over the advancing tooth crown, presenting to oral view a tumefied condition more or less corresponding to the form of the crown. This is nicely shown in Fig. 144, *A* and *B*.

These anatomical data serve for the consideration of the causes and process of eruption.

Causes of Eruption.—It is evident that there are forces which can bring about the elevation of a tooth crown from its bed in the crypt to its position in the mouth.

The consideration of these has led to the development of the following rational theories, as well as others now obsolete:

1. That crown elevation is due to the lengthening of the root—*i. e.*, as root tissue is formed by the pulp and follicle wall lying beneath and to the side of its edges, the tooth is mechanically pushed up, the tissues lying above it are stimulated and absorbed, and as more root

is formed, a further extrusion occurs. It is to be noted that the root end occupies the same level, at all stages of eruption, in the developing jaw that was occupied by the cervical edge of the crown (Fig. 145). As no two bodies may occupy the same space at the same time, the root-forming pulp and follicle wall push the tooth up, to gain room for more root formation. The mild continued pressure is quite competent to do this. The pressure of the soft tissues against the root end is explained by Constant to be derived from the normal blood pressure.[1] That such an internal pressure exists is shown by the extrusion of ordinarily confined parts when released from the accustomed pressure. A simple accident demonstrated this to the editor. While excavating with a large bur, the softened dentin about a decayed pulp chamber, the cementum was widely removed from the pericemental tissue beneath, which latter fortunately remained unbroken. It immediately protruded into the perforation. Constant also cites the extrusion of a tooth in pericementitis as an evidence of the influence of the blood pressure. Another evidence is the occasional rapid advance of a tooth after lancing of the gum.

FIG. 144

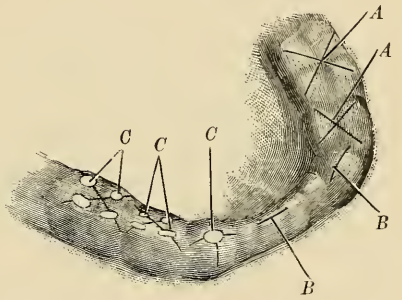

Lines of incision in lancing: *A*, *A*, over the molars; *B*, *B*, over the cuspids and incisors before eruption; *C*, *C*, *C*, over the molars and cuspids after partial eruption.

2. The process of tooth development is a vital process, and that of eruption has been held also to be. (Tomes.) That cells concerned in development seem to have a predestined end or function cannot be denied; at the same time, throughout dental development, defined resistances to opposing forces seem to play a part in the moulding of the soft and hard tissues—*e. g.*, the depression of the enamel organ by the papilla.

3. Peirce[2] holds that the impact of blows upon the jaws causes the tooth to rise toward the gum. He explains the eruption of crowns without roots upon this theory.

4. Tomes explains the eruption of teeth, after development of the root, upon the theory that the closing in of the alveolar process or contraction of the alveolus upon the pericementum (follicle wall) causes the lifting up of the tooth. That such a closure occurs about

[1] International Dental Journal, June, 1903. [2] American System of Dentistry.

the extruding roots of teeth left after the breaking away of the crowns, is shown by examination of the sockets of such roots. An abnormally shallow alveolus closed by deposition of bone at its apex will be found in cases of small apical portions of roots so extruded.

It is well known that mild hyperemia is produced in pericementi which do not receive a normal resistance, which would account for both the elevation and bone deposition on the ground of blood pressure. (See Arterial Hyperemia.)

Fig. 145

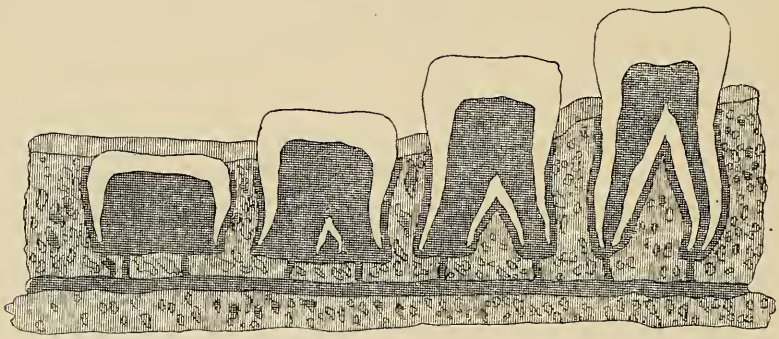

Diagram showing the upward movement of the crown during eruption and root development. (Constant.)

The Process of Dentition.—At varying ages, according to the state of tooth development, the formed crown of the tooth advances and presses upon the follicle wall overlying it; this is irritated, and giant cells are developed, which by resorption remove this as well as the upper edge of the wall of the crypt. The mucous membrane is pushed up and moulded over the crown, thereby causing a tumefaction.

The mucous membrane, at first normal in color, becomes slightly hyperemic, and then may change to an ischemic condition and whiten, owing to the removal of the blood by the pressure of the underlying crown. Resorption from beneath causes a break in the continuity of the mucous membrane, and the crown tip erupts into the mouth (Fig. 144, *C*).

The rate of resorption and crown advance are equalized in perfectly normal dentition. (See cause of pathological dentition p. 199.)

The crown rises from the gum, is directed by the tongue and lip or cheek, and, finally, meets its antagonists of the opposite jaw. The interlocking of cusps and meeting of occlusal surfaces limit further movement of position.

Meanwhile root development proceeds, and as it occurs the alveolar

process is built about the pericementum, which consist of the follicle wall drawn up. By this means the roots are firmly implanted. The further development of the root proceeds until complete, and so remains until normal resorption of the temporary roots occurs, and for life in the permanent teeth.

The state of formation of the roots of temporary teeth at any given age may be judged by the table of averages shown by Peirce in Fig. 107. Being but averages, allowance for delays must be made.

Apart from the presence of the temporary teeth, the process of eruption is identical in both sets of teeth.

Periods of Eruption.—As a general rule, the eruption of the deciduous teeth may be said to begin about the seventh month after birth, and is completed somewhere about the twenty-fifth month. This rule, however, varies within wide limits; some children may be born with teeth erupted; again, the initiation of the process may not occur until the twelfth month, or even later.

The incisor teeth are usually erupted in pairs, the molars and cuspids making their appearance in fours, the first molars in one group, the cuspids in another, and the second molars in a third group. The several groups require different lengths of time to complete their eruption, the time occupied in the eruption of the first molars being longer than that required for the eruption of the other groups. Between the appearance of additional groups of the teeth an interval elapses, no doubt a physiological provision, for, as will be shown later, the process of dentition is usually accompanied by evidences of more or less local disturbance, frequently by disturbances throughout the intestinal tract, and even reflex disorders of the central nervous system occur. It is believed, therefore, that the period which elapses between the eruption of the dental groups permits the organism to recover from the effects of previous disturbance before the new source of irritation appears.

TABLE.[1]

Group 1	Lower central incisors	Time of eruption, 7 months	Duration of eruption, 1 to 10 days	Interval, 2 to 3 months.
Group 2	Upper central and lateral incisors	Time of eruption, 9 months	Duration of eruption, 4 to 6 weeks	Interval, 2 months.
Group 3	Lower lateral incisors	Time of eruption, 12 months		
Group 4	First molars	Time of eruption, 14 months	Duration of eruption, 1 to 2 months	Interval, 4 to 5 months.
Group 5	Cuspids	Time of eruption, 18 months	Duration of eruption, 2 to 3 months	Interval, 3 to 5 months.
Group 6	Second molars	Time of eruption, 26 months	Duration of eruption, 3 to 5 months	

[1] Coleman's Dental Surgery (Stellwagen).

In the above table it will be noted that the time of eruption of the lower lateral incisors is later than that of the eruption of the upper lateral incisors. The reverse course is frequently observed; indeed, it has usually been accepted as the rule of precedence in the United States. All tables, as to periods of eruption, give but the approximate times; while variations are extremely common. The ages given in this table are those at about which the several teeth may be expected to make their appearance. Stellwagen (the American editor of *Coleman*), in commenting upon this table, states that the periods of eruption in this country are from one-seventh or more, earlier than the dates given. He suggests that the difference in food habit may account for the differences in time.

Accompanying the development and eruption of the teeth, occur developmental changes in all of the glandular appendages of the alimentary canal; probably the alterations in their structure, and no doubt in their physiological chemistry, are accompanied by dental provision for the mechanical subdivision of foods of postinfantile character.

Symptoms of Eruption.—Slight local disturbances are so common in even so-called normal first dentition as to be accepted as physiological. The resorption of soft tissue around the tip of the crown of the tooth implies a condition of mild non-septic inflammation at that point. In more marked cases there is evidence of some irritation cognizable to the infant; the gum is of a somewhat deeper color and its temperature is elevated. Relief is afforded by pressure, which temporarily reduces the hyperemia, and the child is pleased to have its gums rubbed, to bite upon its own or the nurse's fingers, upon rings or other objects. Still more marked is the soothing effect of biting upon cold substances, such as ice, which, in addition to mechanically lessening the blood supply, causes contraction of the dilated vessels.

Slight reflex disturbances are evidenced by the stimulation of the salivary glands, which produces an increased flow of saliva.

Reflex disturbances of more severe character occur in pathological dentition, to be considered later.

PATHOLOGICAL FIRST DENTITION.

The local disturbances may be exaggerated beyond that degree accepted as physiological, and may be accompanied by nervous, alimentary, pulmonary, or cutaneous disturbances. This is pathological dentition, and may be of several grades of severity.

Causes and Pathology.—The primary cause of pathological dentition may be stated as an inequality in the rate of gum resorption and crown advance. The advancing crown pressing upon the gum tissue causes irritation; the hyperemia or mild aseptic inflammation resulting, instead of remaining at a point favoring the development of giant cells and resorption, passes the physiological point and causes a disturbance of function. Inflammation, simple or even infective, may occur in the area.

Swelling of the gum occurs, which, being distributed in all directions, presses upon the crown, depressing it upon the pulp beneath the sharp root margins; at the same time the blood pressure of the pulp tends to press the tooth upward. The simple lack of resorption of the gum would be almost equally effective in preventing eruption.

The sharp edges of the root must irritate the sensitive and delicate pulp tissue, which becomes inflamed, and swollen, and still more strongly urges the tooth upward. Two sources of disturbance now are possible: (1) the irritated gum tissue and (2) the irritated pulp. The latter is the more likely to cause reflex disturbances. Through the intimate sympathetic relations of the fifth cranial nerve, supplied to the pulp, with the seventh, ninth, and tenth cranial nerves in and about the floor of the fourth ventricle of the brain, salivary, muscular, nervous, alimentary, and pulmonary disturbances become possible.

Though the pulp is more likely to produce the reflex disturbance, a gum inflammation, if intense, is often capable of producing even prostrating symptoms. Any systemic disturbance—*e. g.*, measles, general debility, or lesser disturbance, etc.—which lowers the general nutritive function also in the parts associated with the teeth, may favor the production of local pathological phenomena. Again, systemic disturbance readily produces a hyperesthesia of the nervous system, favoring the production of nervous phenomena.

Pathological dentition may occur in the absence of an evident hyperemic gum tissue. The tissue may be white, showing ischemia from pressure, a binding down of the root end upon the pulp being proved by the subsidence of symptoms after lancing, and sometimes by the rapid, partial eruption of the tooth immediately after lancing.

Again, pathological phenomena have been noted where no superficial local disturbance was evident. In these cases the deeper tissues may exert a restraining influence upon the crown, but the swelling is just as probable.

It is to be understood that the nervous and digestive systems of the child are in a developmental condition, and therefore in unstable physiological equilibrium, so that any added physiological work, such as unusual growth or dentition, may be more than the organism

can endure without a definite loss of general vital potential. This may be further complicated by hereditary defects of tissue, such as neurotic, degenerative, or syphilitic taint, or conditions of hygiene or feeding tending to lower the health standard.

Ottofy offers the following report, by the Bureau of Health of Manila, of 3250 deaths before twelve months of age:

Before completing one month	647
During second and third months	302
Various causes not dental	959
Four to twelve months due to convulsions and eclampsia	1342
Total	3250

Showing a large number of deaths due to causes in which dentition may have been a determining or complicating factor.

Dr. William P. Spratley, medical superintendent of an institution for epileptics, states it as his opinion that pathological first and second dentition is a determining cause of epilepsy in children having neuropathic taint in that direction.[1]

Symptoms.—The symptoms of pathological dentition are both local and general.

Local Symptoms.—The local symptoms are usually those of inflammation, red and swollen gum tissues at times assuming a dusky hue. The gums may be white, and often glistening, indicating their tense stretching over the crowns. In the gum over the erupting tooth there may exist a vesicular enlargement containing fluid.[2] Evidence of local irritability is given by the fact that the child resists the touching of the gums, seizes the breast or bottle nipple, and immediately releases it.

The readiness with which the child will take cold substances, ice or iced water, is notable and self-explainable. Alternate, excessive flow of saliva and oral dryness are present.

In the more marked cases of local disturbance, evidences of bacterial infection of the mucous membrane of the mouth may make their appearance, such as ulcerative stomatitis. While, as a rule, the breaking down and ulceration of the tissue are confined to the parts overlying the erupting teeth, a general stomatitis or widely scattered patches of ulceration may make their appearance. The localized condition has been called odontitis infantum.

General Symptoms.—The general symptoms may be differentiated into mild and severe.

The mild symptoms are such as are attendant upon severe and painful inflammations about the face at almost any age; thus anorexia,

[1] Dental Cosmos, 1905.

[2] Tomes, System of Dental Surgery.

fretfulness, anger, restlessness, sleeplessness, thirst, mild fever, and evident desire for the upright position occur. The pain is at times paroxysmal, but may become continuous.

These symptoms subside upon the eruption of the tooth or lancing, though erupting cuspids, bound by a ring of tense gum tissue or by adjoining teeth, may continue the irritation even when apparently erupted (Fig. 144, *C*). Again, the cuspids may be caught between the lateral and first molar. The more severe general symptoms are such as are brought about by reflex neuroses.

The roots of the fifth cranial nerves supplied to the teeth are in intimate relation with the roots of the seventh, ninth, and tenth cranial nerves in the floor of the fourth ventricle, as well as with other cranial nerves. It may be argued upon *a priori* grounds that irritation of the peripheral ends of the fifth in the pulp tissue may therefore readily produce neurotic results in the brain, salivary glands, skin, lungs, or larynx, intestinal canal, or muscles of the face or extremities.

Taking the intestinal canal as the most complicated example, we find the following data: The stomach and intestines are under the influence of the pneumogastric nerve, which sends to its muscular coats both stimulant and inhibitory fibers. Likewise it sends vasomotor fibers to the intestines, division of which leads to inhibition of the muscular fibers of the vessels and leads to vasodilatation and a great increase of very watery succus entericus.[1]

Intestinal Disturbances.—That intestinal disturbances may arise independently of teething is self-evident. They are most liable to so occur during the very period during which teething may be supposed to act as a primary cause of intestinal troubles; hence differentiation becomes important.

That the conditions may be associated is also evident. As a rule, intestinal disturbances arise from improper feeding, the food acting as an indigestible irritant to the stomach and intestines. Even an excessive quantity of good breast or bottle milk may, if not regurgitated, act as an intestinal irritant. The milk of an excited, exhausted, or debauched nurse may also act deleteriously. Fermentation due to bacteria ensues, and diarrhea and colic are a natural result.

Musser[2] attributes these cases to development of the Bacillus coli communis and Bacterium lactis aëriformis existing harmlessly in the normal intestine, but developing under the abnormal conditions.

This occurring in warm weather, when the child suffers from intense heat has a very debilitating if not fatal result.

[1] Halliburton, Kirke's Physiology, 1896, p. 684.

[2] Medical Diagnosis.

The condition may be viewed as an infective diarrhea following a vasomotor disturbance of the intestinal walls, set up by reflexes primarily caused by the indigestible food. The vital resistance is lowered by the disturbed alimentation and the pain.

A similar train of circumstances may be caused by teething. Peripheral irritation of terminals of the fifth nerve in the pulp may, through the tenth nerve, cause a reflex vasomotor dilatation in the walls of the intestines—*i. e.*, hyperemia, a condition which favors bacterial invasion. Intestinal digestion is disordered, the vital resistance lowered, and an infection ordinarily resisted occurs.

Diarrhea may follow. In either case alimentation is interfered with and the general nutrition suffers. The child is debilitated by lack of nutrition; moreover, toxic substances are generated in the intestine, which cause a toxemia, to which many of the general symptoms may be attributed, such as fever, meningitis, stupor, coma, and death. The general debility also further interferes with the process of dentition.

Diagnosis.—A diarrhea due to improper feeding would not be preceded by symptoms of pathological dentition; would have a history of improper feeding, and possibly of unhygienic conditions, such as unsterilized milk or milk bottles, filthy surroundings, etc. There is a catarrhal diarrhea accompanied by vomiting and constant acid, watery stools. The stools may have a chopped-spinach character. There is colic due to collections of gas.

Such an infective diarrhea may readily follow the reflex and debilitating effects of pathological dentition, as shown above.

White[1] has noted that a choleraic diarrhea may accompany and be a sign of pathological dentition. Barrett[2] states that a diarrhea due to dentition will probably be followed by constipation.

A symptomatic diarrhea will, as a rule, be accompanied by signs of pathological dentition at points in the jaws, at which teeth should be in process of eruption.

Nervous Disturbances.—Disorders referable to the central nervous system are the most alarming, and are those indicating the higher grades of severity of irritation.

The milder forms of these are faint muscular twitchings and evidences of slight cerebral disturbance.

Either of these may be the result of poisons absorbed from the alimentary canal during the course of intestinal fermentation, but as cases of even convulsions have occurred without other cause than

[1] American System of Dentistry.

[2] Oral Pathology and Practice.

teething apparent, and been relieved by lancing alone, the possibility of direct connection between teething and central nervous disturbance must be admitted.

A distressing symptom, not easy to elicit on account of the age of the patient, is headache. The child is sleepless, and cries without apparent cause; it becomes quiet, partially from exhaustion, and after a period again commences sobbing. The indication of central disturbance may at times be noted in the contracted pupils of the eyes and in throbbing arteries. The usual treatment, the administration of chloral hydrate and potassium bromide, with cold applications to the head, furnishes relief which is frequently not complete without attention to the dental organs.

In the more severe and dangerous cases, the evidences of disorder of the central nervous system become unmistakable. These appear as clonic convulsions or symptomatic eclampsia. While it is probable in many cases that reflex irritation from the process of dentition in itself is but a secondary cause of convulsions, yet evidence is sufficient to warrant its being regarded as a determining factor. In very many cases teething convulsions appear to indicate a neurotic family taint, and eclampsia may attend many disorders in children of this type, notably the mechanical and chemical irritation induced by the presence of large masses of indigestible food in the intestines.

So-called teething convulsions occur usually at a time when several teeth are in process of eruption. The onset of the convulsion is rarely, although apparently often, sudden. If the child be closely observed, it is noted that a period of cerebral disturbance—fretful crying, evidences of headache, sleeplessness, etc.—is followed by a period of dulness and somnolence, or the child may lie with eyes half open. Twitching of one or more groups of muscles may be observed; the orbicularis oris and other muscles of the lips, and the muscles of the eye, notably the superior and internal recti, may contract spasmodically. A common muscular spasm ushering in convulsions, is that of the abductor muscles of the thumb; the thumbs are drawn toward the palms of the hands. The abductor muscles of the feet contracting, the feet are drawn inward. This period may be ushered in by a sharp cry, the eyes roll upward with the lids half open, and consciousness is lost. The symptoms may disappear, the child awakening dazed and fretful; or it may sink into sleep. Unless the source of irritation be removed, or active therapeutic measures be instituted, the eclampsia may return and in severe cases be the precursor of death.

Infantile paralysis of a group of muscles, or even a single muscle, has been recorded, lasting from a few days to months, appearing with

dentition and disappearing after it. In some cases it persists for life.[1] Strabismus, if produced, may also persist.

Skin Disorders.—It is so common as to be almost termed the rule, to find that when there are intestinal symptoms there are eruptions observable on the skin. The mildest form of these is an herpetic eruption about the mouth; in other cases papular and vesicular eruptions are observed upon the skin of the body and limbs.

Occurring within the mouth, infection may be added and ulcerative stomatitis may occur upon the gums, tongue, lips, or inside of the cheek.

Pulmonary Symptoms.—Pulmonary irritation may be expressed in laryngeal cough attending the eruption of teeth, and disappearing thereafter.

Treatment of Pathological First Dentition.—This may be divided into prophylactic and remedial. The prophylactic measures include care as to pasteurization of milk or modified milk diet, sterilization of bottles, bottle nipples and rings, the prevention of the introduction of unclean fingers into the mouth of the child, and the antiseptic care of its mouth by frequent washings with a saturated solution of boric acid in water. This last may be applied to the mouth on a soft, linen rag wrapped on the forefinger. These measures, together with the proper feeding, ventilation, and care as to clothing, which should give comfort and not be in any way irritating, tend to prevent intestinal fermentation and to reduce the general irritability of the infant.

Remedial Measures.—To reduce local hyperemia of the gum above an erupting tooth, a common domestic measure is valuable, viz., a small block of ice is placed in a corner of a clean napkin, and confined in place by a thread; the infant places it in its mouth at pleasure if old enough, or the nurse permits the child to bite upon it. The mechanical effect of biting upon a hard substance has added to it a degree of cold which lessens the local vascular engorgement.

Any severe local irritation about erupting teeth should be relieved by thorough lancing of the gum. It is irrational that the child should be permitted to suffer from local irritation which may develop into more serious complications.

This operation is performed by dividing the gum lineally over the incisors and cuspids before eruption, crucially over the cuspids after eruption of the cusps only, crucially over the upper first molar, and with an X-incisor over the upper second and lower first and second molars (Fig. 144).

For severe cases Flagg advised the removal of a block of gum

[1] White, American System of Dentistry.

from over a molar. A cut is made parallel with the lingual side of the crown, a second parallel with the buccal side, a third parallel with the mesial side. A tenaculum is thrust into the block of gum, which is drawn tense, and then divided at the distal portion, preferably with a pair of curved gum scissors. Lacking these latter, the bistoury may be used.

The cut over the upper incisors should, if possible, be made a little to the outside of the cutting edge, that for the lower to the inside, in order that their crowns may take a proper direction toward occlusion.

The instrument to be used is a sharp-pointed bistoury, as it penetrates well and permits a free draw cut. It is to be wrapped with tape or a strip of linen cloth until only one-quarter of an inch of the point is exposed. This precaution prevents accidental wounds. The child must be securely held by an assistant, the least sympathetic available.

Flagg's method was to place the child upon its back across the lap of the assistant, who, in one position, places his left hand over the child's eyes, securing the head; his right hand secures the hands upon the abdomen, while the legs are held against his body by the right arm. The position may be exactly reversed. The feet should be placed toward the light for the upper jaw, the reverse for the lower jaw. In another position the child sits upon one thigh of the assistant, the back of the head resting upon the chest, and the hand of that side (usually the right) pressed upon the child's forehead to hold the head firmly. The other hand and forearm hold the child's hands and legs firmly.

The operator encloses the gum about the part to be cut with the thumb and forefinger of the left hand, so that the bistoury cannot slip and cut lip, cheek, or tongue. Incision over the erupting tooth should be made until the knife-blade is felt to touch the enamel surface. The operation of scarifying the gums, making merely a few scratches to relieve engorged vessels, is but temporizing with the condition; the cut should be of sufficient extent to entirely remove tension from above the tooth. The little finger of the right hand may rest upon the chin of the child as an additional guard.

If the child bite, a cork with a string attached for safety may be used as a prop.

More or less bleeeding follows upon the operation, and, as a rule, ceases spontaneously. A short period of bleeding is desirable, so that vascular engorgement may be reduced. Suckling by the breast or bottle usually serves to check the bleeding; the tissues about the cut surfaces are compressed by tongue and lips during suckling, and

bleeding ceases. In the event of the bleeding continuing, the mouth should be carefully examined, and a piece of ice in a napkin may be given to the child to suck. The child may swallow the blood and later regurgitate it. Obstinate bleeding may require the use of styptics, but these should be of a character to cause only coagulation of the blood, not the destruction of tissue. A little powdered tannin laid upon the cut acts promptly, as does also a small amount of powdered alum. In some cases the internal treatment may be necessary. (See Hemophilia.)

Death has occurred from hemorrhage due to lancing, in cases of presumably hemorrhagic diathesis; so that inquiry as to family history would be a wise precaution. Obtaining such a history, the gravity of the symptoms alone warrant the operation. In the absence of such a history the operation is to be held as trivial. If it occurs, it should be treated as indicated. (See Hemophilia.)

The operation of lancing is warranted, even when the gum may be likely to heal over the tooth by formation of cicatricial tissue, provided symptoms demand it. It is contra-indicated in diphtheria and erysipelas, owing to the danger of infection.

Shock has occurred in long-continued debilitated cases, and if feared, a trifle of brandy in water may be given previous to the operation.

It is within the knowledge of the writer, that a physician has refused to lance the gums in a case diagnosticated as cerebral meningitis, even when death was prognosticated and though the child was at an age rendering pathological dentition possible, and in spite of a history of pathological dentition in a previous child at the same age. J. Lewis Smith[1] concedes the similarity of occasional symptoms of pathological dentition and cerebral meningitis, so that the above therapy was foolish, to say the least, and especially so in view of the probable death, which did occur. In many desperate cases, lancing has effected marvelously rapid recoveries, aided by judicious handling of the accessory symptoms, even though all hope from ordinary therapy had been abandoned.

Treatment of Stomatitis.—Should general stomatitis, with or without stomatitis ulcerosa, make its appearance, the mouth is to be promptly and freely sprayed with a 3 per cent. solution of hydrogen dioxid, followed by a spray of potassic chlorate (gr. xx to ℥j), which usually affords prompt relief. Should the spots of ulceration not disappear promptly, the mouth and tissues about the ulcer are to be guarded by soft linen napkins; each ulcer is dried and touched

[1] Diseases of Children.

with carbolic acid, full strength. The spraying is to be repeated at intervals of three hours during the waking period.

Treatment of Skin Eruptions.—The eruptions which appear upon the skin during dentition may be a source of annoyance to the child by causing itching. As a rule, measures directed toward a regulation of the intestinal functions cause a disappearance of the skin affections. If the eruption be widespread and cause much itching, a wash of phenol-sodique, diluted to one-third with water, usually affords relief. If the surfaces be then dried and talc powder dusted over them the condition is much alleviated. About the mouth and over excoriated surfaces a zinc oxid ointment is useful.

Treatment of Intestinal Symptoms.—The fermentative material in the bowel, together with the great mass of bacteria present, should be removed by the use of a cathartic. It is indicated in both constipation and diarrhea. Castor oil serves well, and is readily taken by children. To lessen the irritation of the bowel, laudanum and powdered acacia may be added.

The following formula may safely be used even at six months of age:

℞—Tincturæ opii . . . . . gtt. x
Olei ricini . . . . . f℥iss
Pulveris acaciæ . . . . . ℥ij
Saccharini . . . . . gr. ij
Aquæ cinnamomi . . . . . q. s. ad f℥iij—M.
Sig.—Shake the bottle, and give one teaspoonful each two hours if needed.

For an additional six months of age, ten drops more of laudanum may be added to the general formula. In mild cases, olive oil in half-teaspoonful doses may be substituted.

Following catharsis, antacid sedative astringents and intestinal antiseptics are indicated:

℞—Saloli . . . . . ℥j
Bismuthi subnitratis . . . . . ℥ij
Misturæ cretæ . . . . . ad f℥iij—M.
Sig.—One teaspoonful every four hours. (Biddle.)

℞—Tincturæ opii . . . . . gtt. xvj
Bismuthi subnitratis . . . . . ℥ij
Misturæ cretæ . . . . . f℥iss
Syr. simp. . . . . f℥iss—M.
Sig.—Shake well, and give in teaspoonful doses every four hours. (Barrett.)

The virtues of both formulæ may be obtained by including the laudanum (gtt. xii) with the salol formula.

Listerine in 10-drop doses, in water, every three hours, serves as an intestinal antiseptic.

The gums are, of course, to be lanced at the outset, if the diarrhea be due to pathological dentition. Following the intestinal antisepsis, the general debility and possible intestinal toxemia (see p. 207) are to have careful attention, and the child's food is to be properly adjusted to its needs.

J. Lewis Smith claims that upon the following diet, ill-conditioned children under his care in the hospital escape summer diarrhea and thrive; the diet is therefore here introduced.

For children not nourished on breast milk of good quality, and those over three months, he recommends the following substitutes:

1. Heat barley flour in a double boiler, the water in the outer vessel to be kept boiling for five to seven days, to burst the starch granules (Robinson's prepared barley flour can be bought).

2. Take of this flour one tablespoonful, add 25 or 30 tablespoonfuls of boiling water, and boil and mix for five minutes. Cool to blood heat, add 1 dram of diastase to change the starch to dextrin and maltose. Forbes' diastase or Taka-diastase can be bought. Of the latter, 1 grain will change 150 grains of starch to sugar.

Pasteurize milk by heating for twenty minutes to 160° F. Cool quickly on ice and let the cream separate. To two and one-half ounces of the upper half, add a little peptogenic milk powder (Fairchild's), to peptonize it. He mixes the peptonized milk with three and one-half ounces of the dextrinized gruel at a meal, and feeds the infant nine or ten times, at two-hour intervals. Before feeding, administer a few drops of a digestive ferment.

For use in emergency, he recommends two heaped teaspoonfuls of condensed milk to fifteen teaspoonfuls of boiled water, as equivalent to seventeen teaspoonfuls of ordinary milk.

He gives the following table of quantities of food required by infants; either breast or modified cow's milk to be used.

At each feeding.		Number of daily feedings.	Total daily quantity.
During the first week	1 ounce	10	10 ounces
At the third week	1½ ounces	10	15 "
At the sixth week	2 "	8	16 "
At the third month	3 "	8	24 "
At the fourth month	4 "	7	28 "
At the sixth month	6 "	6	36 "
At the tenth to twelfth month	8 "	5	40 "

White, following Starr, gives the following schedule of the diet of a hand-fed infant from birth upward,[1] which will serve as a suggestive and useful guide:

[1] Diseases of the Digestive Organs in Infancy and Childhood, by Louis Starr, M.D.

Diet During the First Week.

Cream	f℥iij
Sugar of milk	gr. xv
Whey	f℥ss, f℥ij
Water	f℥ss, f℥ij

This portion to be given every two hours from 5 A.M. to 11 P.M., and in some instances once or twice during the night.

Diet from the Second to the Fifth Week.

Milk	f℥ss
Cream	f℥ij
Sugar of milk	gr. xv
Water	f℥j

This portion to be given every two hours from 5 A.M. to 11 P.M.

Diet from the Fifth Week to the End of the Second Month.

Milk	f℥j, f℥ij
Cream	f℥ss
Sugar of milk	gr. xxx
Water	f℥j, f℥ij

This portion to be given every two hours.

Diet During the Third Month.

Milk	f℥iiss
Cream	f℥ss
Sugar of milk	5j
Water	f℥j

This portion to be given every two and one-half hours.

Diet During the Fourth and Fifth Months.

Milk	f℥iiiss
Cream	f℥ss
Sugar of milk	3j
Water	f℥j

This portion to be given every three hours.

Diet During the Sixth Month.

Milk	f℥ivss
Cream	f℥ss
Sugar of milk	3j
Water	f℥j

This portion to be given four times daily.

Two other meals—morning and mid-day—may be as follows:

Milk	f℥ivss
Cream	f℥ss
Mellin's Food	3j
Hot water	f℥j

Dissolve the Mellin's Food in the hot water, and add, with stirring, to the previously mixed milk and cream.

In the *seventh month*, the Mellin's Food may be increased to two teaspoonfuls and given three times daily.

Throughout the *eighth* and *ninth months*, five meals a day will be sufficient—at 7 and 10.30 A.M., 2, 6, and 10 P.M.

Milk	f℥viss
Cream	f℥ss
Sugar of milk	℥j
Water	f℥j

This portion for the first and last meals.

For the other three meals, 1 tablespoonful of Mellin's Food may be added, or 1 teaspoonful of "flour-ball" may be given twice daily, instead of the Mellin's Food—say at the second and fourth meals.

DIET FOR THE TENTH AND ELEVENTH MONTHS.

First meal, 7 A.M.:

Milk	f℥viiiss
Cream	f℥ss
Mellin's Food	℥ss
(Or "flour-ball" or barley jelly	℥ij)
Water	f℥j

To be used only when Mellin's Food is employed.

Second meal, 10.30 A.M.: Eight ounces of warm milk.

Third meal, 2 P.M.: The yolk of an egg lightly boiled with stale bread crumbs.

Fourth meal, 6 P.M.: Same as first.

Fifth meal, 10 P.M.: Same as second.

On alternate days the third meal may consist of 1 teacupful (f℥vj) of beef tea containing a few stale bread crumbs.

Beef tea, for an infant, is made in the following way: One-half pound of fresh rump steak, free from fat, is cut into small pieces, and put with 1 pint of cold water into a covered tin saucepan. This must stand by the side of the fire for four hours, then be allowed to simmer gently (never boil) for two hours, and, finally, be thoroughly skimmed to remove all grease.

A further variation can be made by occasionally using mutton, chicken, or veal broths instead of beef tea.

DIET FROM THE TWELFTH TO THE EIGHTEENTH MONTH
(FIVE MEALS A DAY)

First meal, 7 A.M.: A slice of stale bread broken and soaked in a breakfastcupful (f℥viij) of new milk.

Second meal, 10 A.M.: A teacupful of milk (f℥vj) with a soda biscuit or thin slice of buttered bread.

Third meal, 2 P.M.: A teacupful of beef tea (f℥vj) with a slice of bread, 1 good tablespoonful of rice, and milk pudding.

Fourth meal, 6 P.M.: Same as first.

Fifth meal, 10 P.M.: One tablespoonful of Mellin's Food with 1 breakfastcupful of milk.

To alternate with this:

First meal, 7 A.M.: The yolk of one egg slightly boiled, with bread crumbs; 1 teacupful of new milk.

Second meal, 10 A.M.: A teacupful of milk with a thin slice of buttered bread.

Third meal, 2 P.M.: A mashed boiled potato, moistened with 4 tablespoonfuls of beef tea; 2 good tablespoonfuls of junket.

Fourth meal, 6 P.M.: A breakfastcupful of new milk with a slice of bread, broken up and soaked in it.

Fifth meal, 10 P.M.: Same as second.

The fifth meal is often unnecessary, and sleep should not be disturbed for it. At the same time, should the child awake an hour or more before the first meal time, he should break his fast upon a cup of warm milk, and not be allowed to go hungry until the set breakfast hour.

DIET FROM EIGHTEEN MONTHS TO THE END OF TWO AND ONE-HALF YEARS (FOUR MEALS A DAY)

First meal, 7 A.M.: A breakfastcupful of new milk; the yolk of one egg lightly boiled; two thin slices of bread and butter.

Second meal, 11 A.M.: A teacupful of milk with soda biscuit.

Third meal, 2 P.M.: A breakfastcupful of beef tea, mutton or chicken broth, a thin slice of stale bread, a saucer of rice, and milk pudding.

Fourth meal, 6.30 P.M.: A breakfastcupful of milk with bread and butter.

On alternate days:

First meal, 7 A.M.: Two tablespoonfuls of thoroughly cooked oatmeal or wheaten grits, with sugar and cream; 1 teacupful of new milk.

Second meal, 11 A.M.: A teacupful of milk with a slice of bread and butter.

Third meal, 2 P.M.: One tablespoonful of underdone mutton, pounded to a paste; bread and butter, or a mashed potato moistened with good plain dish gravy; a saucer of junket.

Fourth meal, 6.30 P.M.: A breakfastcupful of milk, a slice of soft milk toast, or a slice or two of bread and butter.

The foregoing schedule must, of course, be regarded as an average. Many children can bear nothing but milk food up to the age of two

or even three years, and provided enough be taken, no fear for their nutrition need be entertained. The rule to adopt is, if a child be thriving on milk, it is never to be forced to take additional food, merely because a certain age has been reached. Let the healthy appetite be the guide.

The following is recommended by Starr as a modified milk diet, and as a substitute for mother's milk while weaning:

Pasteurized cream	f℥ss
Pasteurized milk	f℥iiss
Sugar of milk	℥ss
Water, boiled	f℥j

Should this not satisfy the infant, increase the ingredients (except cream) to 6, 8, or 12 ounces.

Hare[1] recommends the following diet list, followed in his hospital practice:

DIET FOR A CHILD AGED TWO YEARS.

Breakfast, 7.30 A.M.: Milk. The lightly boiled yolk of an egg; thin bread and butter (the bread to be one day old).

Lunch, 11 A.M.: Milk. A thin slice of bread and butter.

Dinner, 1.30 P.M.: Beef tea, or small piece of minced roast beef or mutton, devoid of gristle. One well-mashed potato, moistened with gravy. Rice and milk.

Supper, 6 P.M.: Milk. Bread and butter.

For drink: Boiled or filtered water.

DIET FOR A CHILD AGED ONE YEAR (FIVE MEALS A DAY).

First meal, 7 A.M.: 2 teaspoonfuls of grated flour-ball (prepared as directed below) in ½ pint of milk.

Second meal, 10.30 A.M.: ½ pint of milk with 4 tablespoonfuls of lime water.

Third meal, 2 P.M.: The yolk of one egg, beaten up in 1 teacupful of milk.

Fourth meal, 5.30 P.M.: Same as the first.

Fifth meal, 11 P.M.: Same as the second.

Flour-ball is to be made by taking one pound of good flour—unbolted, if possible—tie it up *very tightly* in a pudding-bag; put it in a pot of boiling water early in the morning, and let it boil until bedtime, then take it out and let it dry. In the morning, peel off the surface and throw away the thin rind of dough, and with a grater,

[1] Practical Therapeutics.

grate down the hard, dry mass into a powder. To use this, take from 1 to 2 teaspoonfuls of the powder, rub it down until smooth with a tablespoonful of cold milk, and add 1 tumblerful of hot milk, stirring it well all the time.

DIET FOR A CHILD AGED FROM SIX TO TWELVE MONTHS (FIVE MEALS A DAY).

First meal, 7 A.M.: Mellin's Food, 1 tablespoonful; or flour-ball grated, 1 or 2 teaspoonfuls (prepared as directed above); hot water, 4 tablespoonfuls; warm milk, enough to make ½ pint. Dissolve the Mellin's Food, or rub down the grated flour-ball in the hot water by stirring, then add the milk; mix thoroughly.

Second meal, 10.30 A.M., and third meal, 2 P.M.: A breakfast-cupful of milk, with 4 tablespoonfuls of lime water.

Fourth meal, 5.30 P.M.: Same as first.

Fifth meal, 10.30 P.M.: Same as second.

TREATMENT OF NERVOUS CONDITIONS.—If nervous reflexes, great irritability, or cerebral congestion appear, attention should be directed to the condition of the bowels and the teeth.

If constipation or diarrhea exist, a cathartic is given and the gums are lanced. A cerebral sedative is to be prescribed.

℞—Chloralis hydratis . . . . . gr. ij
Sodii bromidi . . . . . gr. v
Aquæ menthæ piperitæ . . . . . f℥ij—M.
Sig.—Per orem. One dose; enlarge formula for repetition as needed.

If convulsions be threatened, the clothing should be loosened and cool applications made to the head.

If the child be in convulsions, it should be immersed to the waist in water as hot as can be borne, to which has been added 2 tablespoonfuls of common mustard flour, and cool water poured over its head, when, as a rule, the symptoms promptly subside. Chloroform, which children endure well, may be administered.

After immersion, a rectal injection of 1 dram of glycerin or a glycerin suppository will usually cause a free stool. A cerebral sedative should be administered.

℞—Chloralis hydratis . . . . . gr. ij
Sodii bromidi . . . . . gr. v
Starch paste . . . . . ℥ij—M.
Sig.—To be administered per rectum. (Atkinson.)

It is well also to administer a cathartic, to unload the intestines of irritating substances possibly present.

After sleep, if appearances indicating dental irritation be observed, gum lancing is practised. It is wise that this operation be thus deferred, as convulsions may be precipitated by the act of lancing when the nervous system of the child is overexcited. The removal of intestinal irritants, by a cathartic given *per orem* is also in order, before lancing.

It has been repeatedly noted that when evidence of marked cerebrospinal irritation is present, for which no probable source can be assigned, and an examination of the gums shows no apparent local disturbance, yet if it be at a period when one or more teeth are in process of eruption, but are still covered or bound down by gum tissue, if gum lancing be practised, relief is immediate and the lancing may even avert a threatened attack of eclampsia. It is presumed that these are cases of pulp irritation, in which a failure of resorption of tissue in advance of the tooth crown has caused pressure upon the pulp forming the root end.

CONSTITUTIONAL STATES MODIFYING DENTITION.

Children who are the victims of hereditary syphilis, usually cut their teeth very early; the alveolar process being in many cases insufficient. Cases are recorded where children have been born with crowns of teeth visible upon the gum, there being no evidence of root formation, the crowns being loosely held to the gum by fibrous tissue. It is necessary to remove these loose crowns, to permit the infant to suckle. Children affected with rachitis have the process of eruption much delayed. It is seen, therefore, that the presence of loose crowns of teeth is a condition pointing to, though by no means diagnostic of, hereditary syphilis. Long-delayed eruption of teeth should prompt a search for further indications of rachitis. Particularly in children in whom a history of hereditary syphilis is obtainable, the process of dentition may be accompanied by rapid and frequently widespread breaking down of the soft tissues, over and about erupting teeth. Local measures of treatment seem to be of but little avail, except that antiseptic treatment undoubtedly prevents complications from extraneous infection.

In children classified indefinitely as strumous, which may mean the children of syphilitic or tuberculous parents, or those with no such history whose surroundings are of the most unhygienic kind, the process of dentition may not only have an untoward course, but phagedenic ulcerations may occur. It is usually in the degree of a child's debility, either inherited or acquired through improper care, that dentition assumes morbid features. The treatment of such cases

must be directed to raising the health standard. As local therapeusis, no measures seem more effective than the sprays of hydrogen dioxid first; next, potassium chlorate, and, if conditions indicate it, sprays of dilute listerine, which is stimulant, antiseptic, and slightly astringent.

Infantile Scurvy.—Cases are reported in which the improper feeding of children has been followed by evidences of scorbutus. It occurs usually in bottle-fed babies confined to patent foods, the nutritive element being lacking. The gums become tumid, and hemorrhagic extravasations occur in their substance; the periosteum is stripped from the margins of the alveolar walls, the soft tissues hanging in discolored, pendulous masses about and beyond the teeth if any be erupted.

The child is peevish, listless, and feeble. There is apparent pain in the limbs.[1] The urine may be bloody even, as a first sign.

The treatment is largely systemic, and consists of using fresh cow's milk modified to conform to human milk, and in the administration of fresh lemon juice, preferably boiled, allowed to settle, and the supernatant fluid used,[2] or orange juice is also used.

The mouth should be sprayed with sedative antiseptics, such as potassium chlorate in hydrogen dioxid. (See p. 206.)

THE SECOND DENTITION.

By reference to Fig. 115, it will be seen that at six and one-half years of age, the twenty temporary teeth are still all in position, and that taking their places in the line of the arch, are the four permanent first molars, the roots of which are still incomplete.

These molars do not replace any temporary teeth, but during the "change" support the jaws with the assistance of the temporary molars until the permanent incisors are fully erupted, and with the aid of the incisors, until the bicuspids come into occlusion. Their office as jaw props and organs of mastication during the change is, therefore, very important. Of their later function, more will be said farther on.

At six and one-half years, the crowns of the permanent incisors lie in the relations shown, with the temporary central roots resorbed and the lateral root partly so. Their crowns are practically complete, but the roots are unformed.

The cuspid crown in its crypt, lies well above and lingual to the unresorbed temporary cuspid root. The roots of the first and second

[1] Hare. [2] Ibid.

temporary molars, a trifle resorbed upon the inner side, embrace the formed crowns of the first and second bicuspids.

In their crypts back of the first molars, lie the forming crowns of the second permanent molars. The third molars are not in evidence in the illustration, but their development is in progress.

It will be seen that the permanent central and lateral incisors replace the temporary central and lateral incisors, the permanent cuspid the temporary cuspid, and the first and second bicuspids the first and second temporary molars, respectively.

From this age to adult age, as previously, the jaw undergoes constant change, enlarges by constant resorptions and depositions of bone, and changes its contour to conform to the changes occurring throughout the body, and to accommodate the permanent teeth, which are in general terms larger and more numerous than the temporary teeth.

It may be said that the alveolar process built about the roots of temporary teeth and the roots of the temporary teeth are all resorbed during the replacement of the latter, and that when the crowns of the permanent teeth are fully erupted, new alveolar process is built up about their roots. Any subsequent change in the position of the permanent teeth is accompanied by an alteration in the alveolar process, and after extraction the latter is resorbed, but upon an implantation (which see) being done, new process will form. Its dependence upon the teeth is, therefore, evident.

The following table gives the approximate ages for the eruption of the permanent teeth:

First molars	5½ to 7 years
Central incisors	7 to 8 years
Lateral incisors	8 to 9 years
First bicuspids	10 to 11 years
Second bicuspids	11 to 12 years
Cuspids, the lower usually preceding by a year or more	12 to 14 years
Second molars	12 to 15 years
Third molars	16 to 20 years and indefinitely beyond

The Process of Resorption of the Temporary Roots.—After completion of formation, the roots of the temporary teeth remain in this state but a short time, as their successors are ready to advance to their places.

Comparing the ages at which resorption begins with the ages at which it is complete (eruption of permanent teeth) (see Fig. 146), it will be noted that approximately three and one-half years are required in all cases for the removal of the temporary roots. Therefore, to determine the age at which absorption begins, deduct three and one-half years from the date of eruption of the corresponding permanent tooth. The degree of resorption at any age is shown in the table.

At the time the permanent tooth begins its advance, it lies in a bony crypt above and lingual to its predecessor, except in the case

Fig. 146

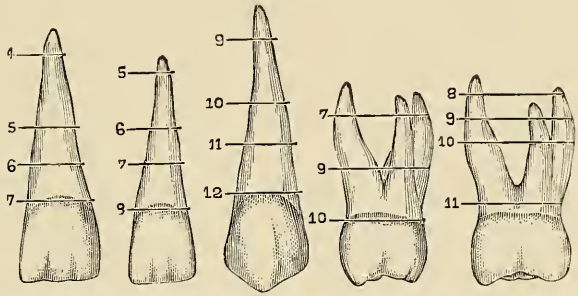

Decalcification of the deciduous teeth. The numbers indicate years. (Peirce.)

Fig. 147

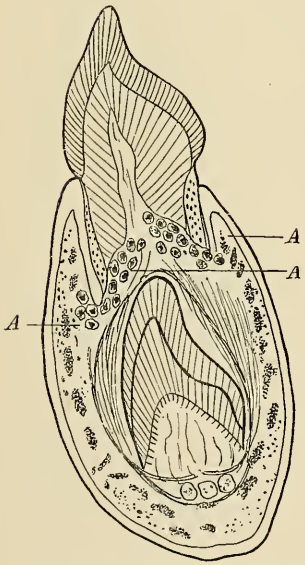

Showing the relations of an erupting permanent tooth to its deciduous predecessor. *A*, *A*, *A*, odontoclasts in absorbent organ.

Fig. 148

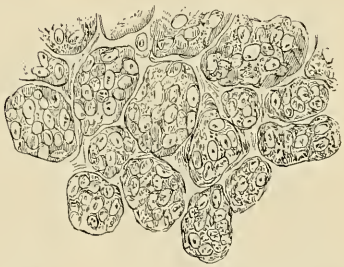

The structure of the absorbent organ, showing multinucleated or giant cells (odontoclasts). (Tomes.)

Fig. 149

Imprisonment of second temporary molar; resorption of its roots, with absence of second bicuspid. (Skiagraph by Custer.)

of the bicuspids, which lie between the roots of the temporary molars (Fig. 112 to 115).

Each crypt has its own follicle wall enclosing a permanent tooth crown.

In the follicular wall overlying the crown, appear large multinucleated cells, the origin of which is unknown, but which by some are thought to be transformed osteoblasts, by others leukocytes (Figs. 147 and 148). The latter is the probable explanation, as analogous cells are found about tissues or foreign bodies about to undergo resorption anywhere in the body. (See Resorption.) In the particular situation under consideration they are called odontoclasts. The tissue between the root and crown has by Tomes been given the name of the "absorbent organ" (Figs. 147 *A*, and 148). These giant cells have a solvent or digestive function not understood, but

FIG. 150

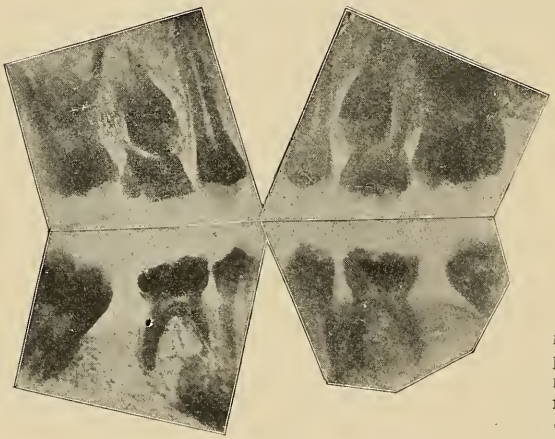

Phases of resorption of temporary roots. (Skiagraph by Price.[1])

FIG. 151

Diagram illustrating the relation of a resorbed temporary root and the permanent tooth, also the involvement of the pulp as a part of the resorbent organ. Resorption of the interior of crown of a temporary tooth. From actual case.

which is competent to remove both the organic and inorganic matter of cementum and dentin, and evidences of action upon enamel in other situations are not wanting. (See Resorption of Enamel.) That the solvent is acid, is shown by the evidence of decalcification about the area of resorbed enamel of unerupted crowns of some permanent teeth. It is a curious fact that no evidence of decalcification of the permanent crown has been demonstrated to result from the proximity of the multinucleated cells in cases of physiological resorption of roots. In all probability the enamel is protected by the presence of Nasmyth's membrane, which is resistant

[1] Items of Interest, 1901.

to acids. These cells are probably invited by irritation due to pressure of the advancing permanent tooth crown, as the resorption is almost always found at the point of approximation of the crown with the root, or, in other words, at the pressure point (Fig. 150).

Cases of resorption of temporary roots without the presence of a permanent crown are, however, noted and explained by Tomes upon the ground that resorption is a vital act independent of the pressure exerted (Fig. 149). As resorption of permanent roots, however, has often occurred from pressure of the crown of another tooth and occurs at the pressure point in physiological resorption, localized irritation, even in the absence of a permanent crown, must be credited with a large influence in the process. It is to be remembered also that in the absence of the pressure, resorption often does not occur, at least for twenty-five or more years—*e. g.*, when laterals are absent and the permanent cuspids erupt to the side of the deciduous cuspids (Fig. 153).

According to Tomes, redeposition of cementum occurs in previously resorbed areas upon temporary roots; a fact corresponding with effects noted in permanent roots.

Teeth frequently erupt lingually or labially to their corresponding temporary teeth, both remaining in the mouth. It is almost invariably the rule, upon extraction to find that an oblique resorption has occurred, as is shown in the right upper skiagraph in Fig. 150, and generally a decided hyperemia is seen in the pulp extending upward for perhaps a quarter of an inch.

Doskow[1] has shown by the prompt loss, by absorption, of a fairly firm deciduous cuspid, crowned to bring it up to level and so to usefulness, that such an operation is inadvisable because of an inherent tendency of an absorbent organ to become established. Again, a permanent tooth undergoing resorption often remains firm, until suddenly the strain becomes too great.

As the root of the temporary tooth disappears, the pulp continuously fuses with the absorbent organ, so that when the crown alone remains, the pulp is still vital (Figs. 147 and 151). At times, it seems to take up the resorbent function and resorbs the crown dentin in some cases almost entirely. In one specimen, a circumscribed portion of the cementum and of enamel were removed by it, at the point of junction. This constituted practically a case of perforation by resorption (Fig. 151). The tooth was at first thought to be suffused with hemoglobin, as it was of a pink color. After extraction the absorbent organ was found as a papilla attached to the gum. At

[1] Dental Cosmos, 1907.

times, bay-like excavations in the crown dentin occur (Fig. 209, *D*). When the root resorption reaches the point shown in the central incisor in Fig. 115 the temporary tooth is loosened, moves about, and annoys the child, who may pick it out, or it is removed by extraction.

Formation of the Roots of Permanent Teeth.—The extent of root development at any age is of great importance in view of canal therapeutics. Incomplete roots present a mechanical difficulty of sealing the apex of the canal. The size of the pulp at the apical foramen of such teeth contraindicates the use of arsenic, and even pressure anesthesia is often unsuccessfully applied.

Fig. 152

Absence of upper left lateral incisor, with permanent cuspid in its place; two temporary cuspids retained. Man, aged twenty-five years.

The roots are developed in precisely the same manner as in the case of the temporary teeth, by the combined deposition of cementum by the osteogenetic cells of the follicular wall, which is drawn up on the root as a pericementum, and by the odontoblasts of the papilla, which is drawn up as a pulp (Fig. 110).

The extent of development of any of the permanent teeth may be seen at a glance by reference to the valuable table of Peirce (Fig. 116). So graphically does this table give the desired information that explanation becomes unnecessary.

Irregularities of Second Dentition.—Some temporary teeth may be retained long after adult age is reached. The teeth most subject to this are the cuspids and second temporary molars.

In the case of the cuspids, the permanent cuspid is delayed or takes an unusual direction, erupting lingually or labially, or at times being directed into the place normally occupied by the lateral incisors, which are wanting, or very rarely, the cuspid erupts posteriorly to the first bicuspid. At about forty years of age, the temporary cuspids may be lost by resorption of their roots, but until such time should be retained if usefully filling a space. If in interference with proper alignment or eruption of the permanent cuspid, they should be extracted. Their late resorption is somewhat pathological in character, and probably due to or incited by a partial resorption of the root end during the descent of the permanent cuspid.

FIG. 153

Absence of upper lateral incisors and right bicuspid. Retention of temporary cuspids. From an adult.

The late enforced loss of the temporary cuspid indicates the advisability of an implantation operation (Fig. 153).

The molars are retained, as a rule, because of an absence of permanent crowns to cause resorption, although this may occur without such pressure (Fig. 149). I have seen a case of an adult lady with eight deciduous molars in place. The question of the abnormal development or absence of permanent germs, or of the state of the roots of the temporary tooth may be settled by the *x*-rays (Figs. 150 and 154).

The question of extraction or retention depends upon the diagnosis. A firm temporary tooth should never be extracted simply to

allow a permanent tooth to erupt unless the presence of a permanent tooth in the jaw, as determined by skiagraph or other means, gives reasonable inference that the permanent tooth is held back by the temporary tooth. In most cases a reasonable delay is advisable. A patient of the editor wore a plate for thirteen years because of the injudicious extraction of an upper temporary cuspid, the permanent tooth appearing at twenty-six years of age.

Fig. 154



Retained temporary molar with bicuspid present. (Skiagraph by E. Ballard Lodge.)

When the retention of temporary molars and cuspids occurs, they are apt to occupy an occlusal level, lower than that of the permanent teeth (Fig. 149). They may not be in occlusion at all, as was the case with the eight molars just referred to. This proves the fact that the general occlusal level of the permanent teeth is farther from the margin of the alveolar process than in the case of the temporary teeth. The length of the permanent crowns accounts for this. In normal replacement, however, the occlusal level is nearly the same for the temporary molars and first permanent molar, at least until the change is made by the eruption of the bicuspid.

Fig. 155

Retained lower temporary molars, bicuspid absent. (Skiagraph by E. Ballard Lodge.)

Fig. 156



Delayed cuspid. (Skiagraph by E. Ballard Lodge.)

The correct placement of these first permanent molars seems to determine the correctness of molar occlusion, at least in the mesiodistal relation, though they may not occupy their correct buccolingual positions. Any slight forces disturbing the mesiodistal relation, causing the upper first molar to drift anterior to its correct

occlusion with the lower molar, will result in an abnormal relation of the teeth to those anterior to them and to their antagonists; either upper protrusion or upper irregularities will occur.

If the reverse occur, and the lower molar be placed anteriorly, and the upper be placed normally or posterior to its normal position, prognathism of the lower teeth ordinarily results. If placed too far posteriorly, retrusion of the lower teeth will occur.

FIG. 157

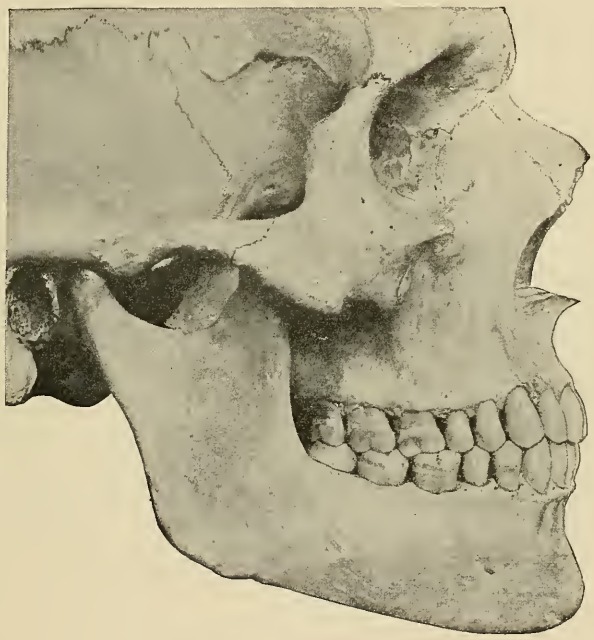

Typical occlusion. (Cryer.)

According to Angle, the misplacement of the permanent teeth erupting early causes their inclined planes to direct other teeth from normal occlusion, or by permitting contraction of the space normally occupied, particularly in the lower jaw, permits the other teeth to assume a position in a contracted arch, thus again causing their inclined planes to cause contraction in the opposite arch, with a consequent displacement, buccolingually, of teeth which would otherwise normally align themselves in the arch. Once established, the cheek and lip pressure maintains the inharmony (Fig. 162).

Angle divides all irregularities into three classes, with divisions and subdivisions:

Class I.—The first molars are correctly occluded mesiodistally, the teeth anterior being in malocclusion, though the biscuspids may be in correct mesiodistal relation.

The general characteristic of the class is that shown in Fig. 158.

Fig. 158

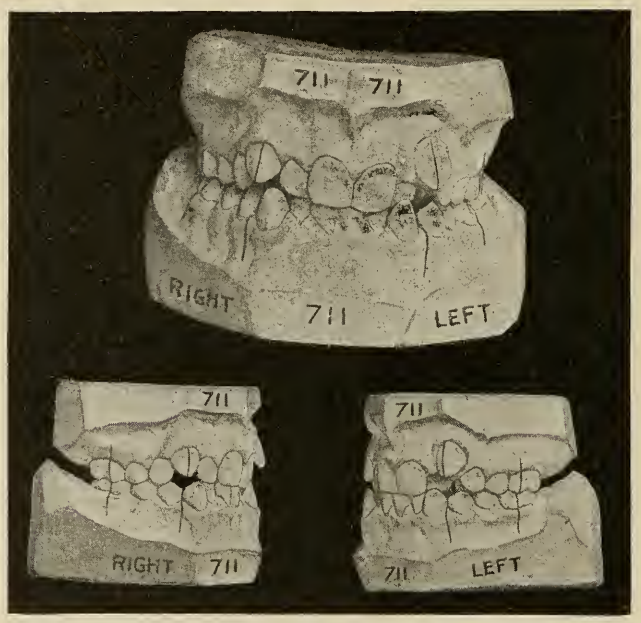

Malocclusion. Class I. (Angle.)

Class II.—The lower first molars occlude distally to the upper first molars, causing retrusion of the lower jaw. Division I is characterized by distal occlusion on both sides, the upper arch is narrowed, the upper incisors lengthened and protruded. The upper lip is short and functionless, while the lower lip is thickened and rests cushion-like between the upper and lower incisors, increasing the protrusion of the upper and the retrusion of the lower. There is usually mouth breathing, due to some form of nasal obstruction.

Division I.—The characteristic exists on one side only, the other being normal. Mouth breathing is usually associated (Fig. 159).

Division II.—There is distal occlusion on both sides, but the upper incisors are retruded instead of protruded, with crowding in the cuspid region. These are associated with normal breathing (Fig. 160).

Subdivision, Division II.—The characteristic is upon one side only, normal breathers.

Class III —Division I.—In this class, the lower first molars occlude mesially to the upper first molars on both sides, and the lower jaw progressively protrudes anteriorly (Fig. 161).

Fig. 159

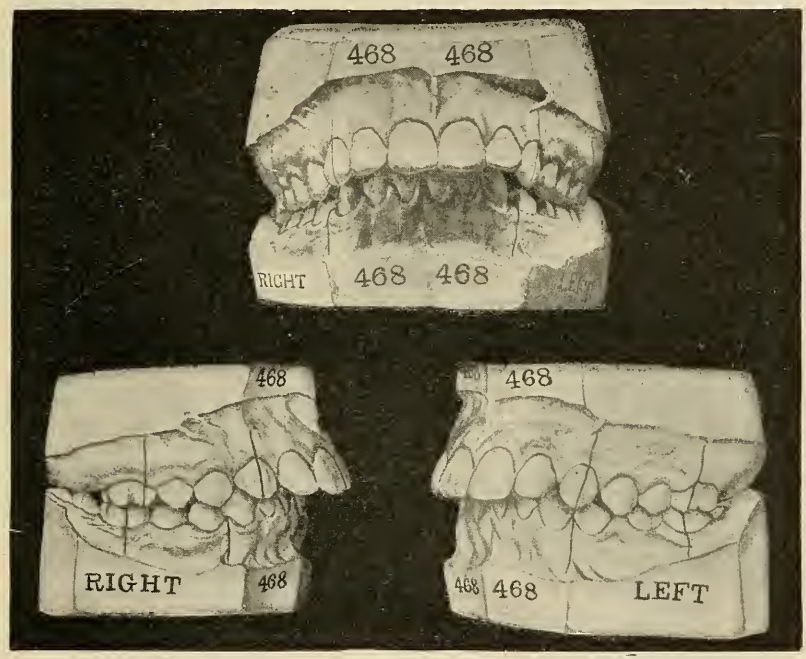

Malocclusion. Class II. (Angle.)

Subdivision, Class III.—The mesial occlusion is upon one side only, the other being normal, the arches crossing in the region of the incisors.

Angle has formulated the law "that the best balance, the best harmony, the best proportions of the mouth in its relations to the other features require that there shall be the full complement of teeth, and that each tooth shall be made to occupy its normal occlusional relations. He also states that the best development of the bones of the face and throat, the size and function of its cavities are dependent upon the position of the teeth.

The specific causes inducing malocclusion of the teeth as classified above are:

Fig. 160

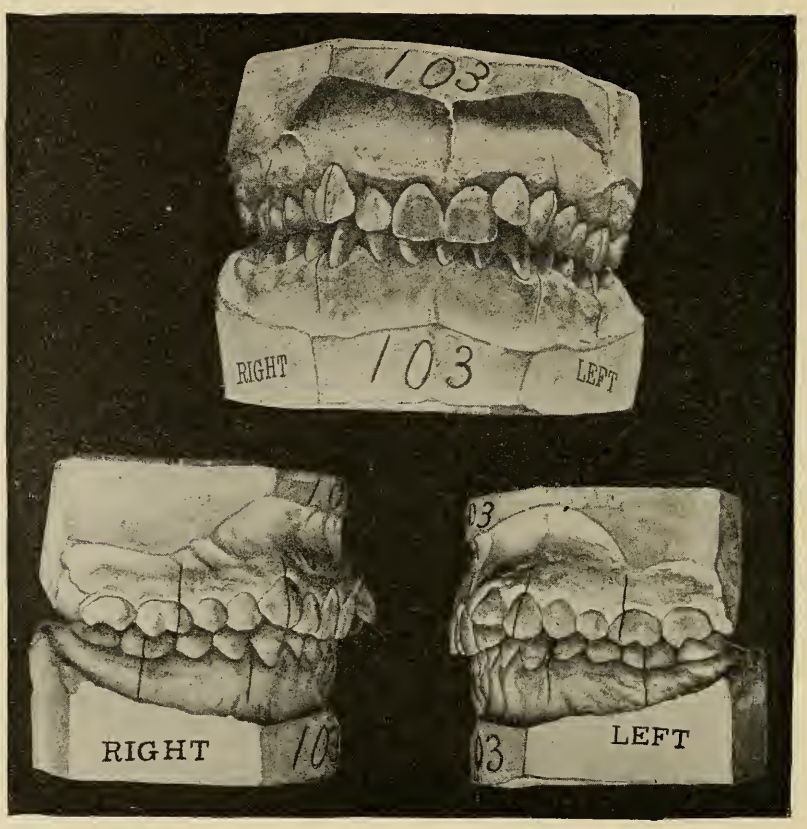

Malocclusion. Class II. Division II. (Angle.)

Fig. 161

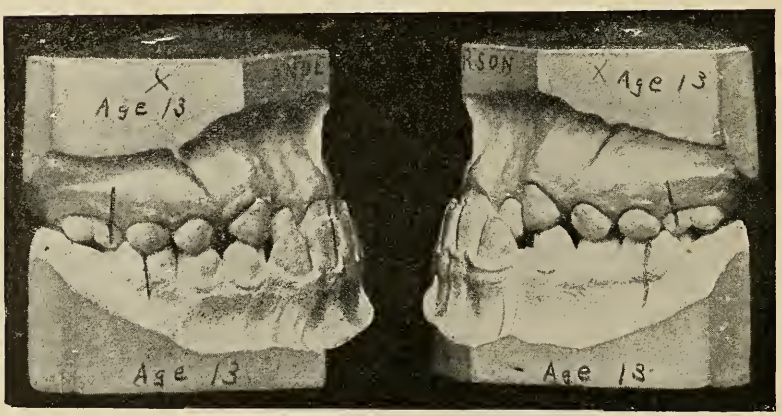

Malocclusion. Class III. (Angle.)

1. Premature loss of deciduous teeth prevents the pressure of the first molars upon the teeth anterior to them, which mechanically aids in the development of the jaws and thus of the space necessary for accommodation of the permanent teeth. It also allows the first molar to drift forward and come into malocclusion, and also to close the space occupied by the deciduous tooth, thus lessening space for its successor and forcing it into buccal or lingual displacement. The same is true of loss of approximal tooth contact as the result of caries (Fig. 162).

Fig. 162

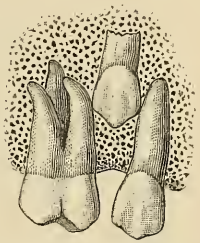

Effects of the premature loss of a deciduous second molar.

2. Prolonged retention of deciduous teeth may cause a deflection of the temporary successor or prevent its eruption.

3. Through loss of permanent teeth on that side upon which the tooth is extracted, the development of the jaw will be prevented and the tooth posterior to the space will tend to tip or drift forward into malocclusion.

Fig. 163

Fig. 164

Case of adenoids. Fig. 163, before operation; Fig. 164, after operation. (Faught.)

4. Tardy eruption of permanent teeth permits closure of the space altogether or in part, and the resistance offered causes a deflection of the tardy tooth (Fig. 162). The total absence of certain permanent teeth may be placed under this heading.

5. Supernumerary teeth, by occupying space, also compel the normal teeth to take an abnormal position, and, if erupting after them, may displace them by constant pressure (Figs. 220 and 250).

6. Habits such as thumb and lip sucking or lip biting will move the upper anterior teeth outward and the lower anterior teeth inward.

Fig. 165

Diagrammatic sagittal section, showing relation of anatomical landmarks. (Faught.)

Fig. 166

Adenoid vegetations. Compare Fig. 165. (Faught.)

Fig. 167

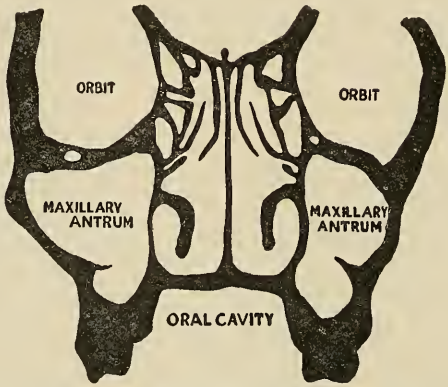

Diagrammatic coronal section through head in the region of the first molar, showing nasal septum, uncinate process, inferior meatus, inferior turbinals, middle ethmoidal cells, middle turbinates, and hiatus semilunaris. (Faught.)

Holding the tongue between the anterior teeth produces infra-occlusion of the anterior teeth, while the constantly open mouth permits supra-occlusion of the molars.

7. Nasal obstructions occurring in the developing child produce mouth breathing, and the opening of the mouth causes contraction of the muscles upon the teeth and bones, producing abnormalities of the bone of the jaw; the irregularity of Class II (Division I), an undeveloped nose and adjacent region of the face. Faught has ably

FIG. 168

Hypertrophy of right inferior turbinal, also deflected septum and spur. Compare Fig. 167. (Faught.)

FIG. 169

Cystic middle turbinal, hypertrophied inferior turbinals, enlarged middle ethmoidal cells, and hypertrophied middle turbinal. Compare Fig. 167. (Faught.)

illustrated these conditions in Figs. 163 to 171.[1] The consideration of malocclusion as a general subject is properly relegated to special works, and the reader is referred to Angle's *Malocclusion of the Teeth* and other works on the subject.

[1] Dental Cosmos, 1908, p. 7.

Disorders of the Second Dentition.—The devitalization of the pulp of a temporary tooth and proper canal filling delays, but does not absolutely prevent, resorption. Chronic abscesses upon such roots

Fig. 170

Hypertrophied posterior end of inferior turbinal. Compare Fig. 165. (Faught.)

Fig. 171

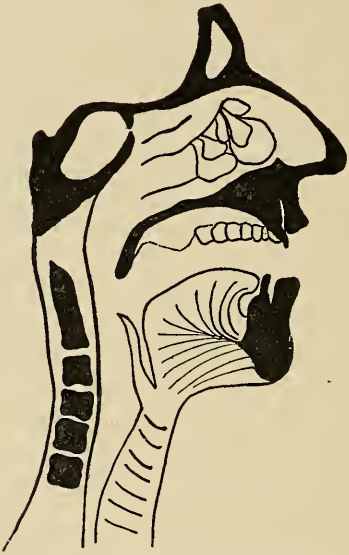

Nasal polypi. Compare Fig. 165. (Faught.)

Fig. 172

Right. Left.

Labial aspect of bilateral sequestra apparently due to typhoid fever alone. (Cowper.)

destroy the absorbent organ, but some pathological resorption may occur, as in case of permanent roots (which see). Pus has an alkaline reaction which may neutralize the acid solvent. As a rule, such roots are mechanical obstructions to the permanent crowns, which are

deflected to one side and caused to erupt irregularly; again, the temporary root may be bodily pushed aside, its apex pressed against the alveolar process and gum tissue, which are resorbed, and the necrotic root end is seen extruded through the gum. Extraction is indicated.

When temporary roots are not thus mechanically removed they are gradually extruded and decayed, or suppurative processes cause the resorption of the alveolar process about them.

Injudicious retention of temporary teeth may thus cause an irregularity. On the other hand, premature extraction by permitting the approximation of the previously erupted permanent teeth may have an equally bad effect upon an erupting tooth (Fig. 162).

In anticipation of physiological resorption of temporary roots, all temporary teeth should be carefully watched, cleansed, filled, and, if necessary, their roots treated so that a normal replacement by the permanent teeth may occur. If pronounced disease occur just previous to the time for normal replacement, extraction is indicated.

Early extraction has sometimes caused early eruption of the permanent teeth, *e. g.*, bicuspids at seven years of age.

It will be recalled that the teeth are an evolution of the dermoid system, which fact possesses pathological significance in certain acute, specific skin diseases. It is noted in some cases of the eruptive fevers of children, particularly when the child is much debilitated, that after the cessation of the acute disease, a necrotic affection of the jaw occurs, involving the alveolar bone and its contents. As many of these cases occur between the ages of three and seven years, the temporary teeth are still *in situ;* these, with the partially developed permanent teeth and the enclosing bone, may be exfoliated. The necrotic process may involve but one tooth, or may include all of the temporary teeth, their successors, and a large mass of bone.[1] The disease with which this necrosis is most frequently associated is scarlet fever;[2] it is also found as a sequel of measles and smallpox. "The cases prior to exfoliation of the bone, exhibit a stripping of the periosteum, apparently beginning about the necks of the teeth. A discharge of pus having a fetid odor is present, and the soft tissues may be raised from the bone for a variable extent;" that is, there is evidence of purulent periostitis. In the course of some weeks, six or eight, the necrotic bone and its contents exfoliate. Salter observes that the sequestra forming after severe scarlet fever are much more extensive than those which form as a sequel of measles.

An interesting case of bilateral sequestra of the aveolar process

[1] Salter, Dental Pathology. [2] Ibid.

due to typhoid fever alone is reported by Cowper.[1] Two sound teeth were involved in each sequestrum. (Fig. 172.)

The administration to children, of mercurials, has caused such a loss of teeth and process. I have seen a sequestrum containing three undecayed teeth attributed to this cause, and others have been reported. In these cases the parts should be kept as aseptic as possible by means of hydrogen dioxid and the compound tincture of capsicum and myrrh (enough to cloud a glass of water), used as a stimulant mouth wash.[2] When loose, the sequestrum should be removed. The parts heal by granulation, if due attention be paid to the general physical welfare of the child.

Eruption of the Molars.—The first permanent molars rarely produce more than slight rheumatic pains. The gum irritation may be relieved by an X-incision, or at times by the application of phenol-sodique and laudanum, equal parts, or phenol camphor, with the finger tip. A little alcohol or dilute tincture of iodin serves almost equally well.

As some time may elapse between eruption and occlusion, the first molars do not receive a proper friction. Associated frequently with carious temporary teeth, they are frequently decayed in their sulci and fissures; to prevent this it has been recommended that oxyphosphate of zinc be placed over these fissures without previous excavation.[3] The oxyphosphate of zinc or copper may also be thus used in third molars which are even more liable to dental caries.

The lower second molars may cause some irritation owing to an insufficient development of the jaw at the angle, leaving an inadequate accommodation for the crown. At about nine years of age the second molar occupies the angle of the jaw in much the same position as shown in Fig. 111 for the third molar. If held back, a pathological condition equivalent to that occurring in the temporary teeth may result; reflexes producing heavy pains about the jaw or reflex effects, such as chorea, may be produced.

Truman[4] has prevented a threatened second attack of this sort by deep incisions in the gum over the site of the crown. The presumption is that such treatment relieves the tension upon the pulp underlying the developing root.

Kirk[5] calls attention to the liability of chorea to be associated with reflexes from the dental region at from four to nine years of age, and cites a case from the practice of C. N. Peirce in which choreic manifestations were permanently relieved by the removal of a deciduous

[1] Dental Cosmos, 1909, p. 765.
[2] Garretson, A System of Oral Surgery.
[3] L. Ashley Faught.
[4] International Dental Journal, 1899.
[5] Dental Cosmos, 1905.

molar interfering with the eruption of its permanent successor, the bicuspid. He also cites a case of repeated hysterical manifestations, following nervous irritability due to each replacement of a deciduous tooth by its successor. Flagg cured a case of chorea in a boy, by the extraction of four teeth from a very crowded arch.[1]

The third molars frequently induce pathological conditions.

The upper third molar, meeting in its descent the roots of the second molar, may be united to it by hypercementosis—the condition of concrescence (which see); escaping this, it may meet a dense palato-alveolar plate of bone at the tuberosity and be deflected buccally through the thinner buccal plate of bone, so that its occlusal face presents cheekward (Fig. 173). Its occlusal face may present more posteriorly or more anteriorly. Here retained food collects about it and caries occurs, or a suppurative inflammation of the cheek or free gum margin may occur. For this condition sterilization, free

FIG. 173

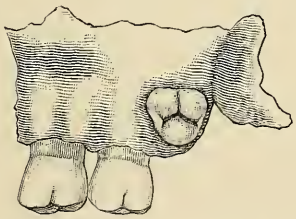

Abnormal eruption of the upper third molar.

FIG. 174



Partial eruption and impaction of third molar. (Skiagraph by Custer.)

incision of the gum margin, and subsequent asepsis maintained by antiseptic sprays will reduce the inflammation, which, however, is apt to recur at intervals. If the cheek be irritated or the position of the tooth permanently fixed, only traction of the tooth into a correct position, grinding away of the sharp cusps, or extraction will alleviate the condition. The extraction of such a tooth is little loss to the individual. A bit of cotton saturated with a mild antiseptic may be placed between the tooth and cheek for a time after grinding. The possibility of concrescence in such a case, as shown in Fig. 173, must be considered when extraction is intended. Individual motion is diagnostic of separate teeth, and is readily induced, when the crowns are together, by pressing a strong, thin, flat-bladed instrument between the teeth and turning it. The teeth are seen to move apart.

[1] Private communication.

The pressure of an erupting third molar upon the second molar may cause neuralgic pains, and at times the teeth in general, as far forward as the central incisor, may seem to loosen up and become tender to touch and again become comfortable and tight. These symptoms may be repeated apparently in consonance with the efforts at eruption. This pressure also causes irregularities of alignment or breaks up an orthodontia. Their extraction for this reason is sometimes indicated.

Owing to insufficient development at the angle of the jaw, it is almost the rule that the eruption of the lower third molar is attended with some degree of discomfort due to gum and bone irritation, and, possibly, to pressure on the formative pulp (Fig. 111).

For some months prior to eruption, heavy, gnawing, rheumatic pains may be indefinitely located about the jaw and ear of the affected side. The muscles of mastication become stiff and may contract spasmodically, simulating trismus. These symptoms, if severe, may be relieved by deep X-incisions in the gum; or, if mild, by the application of non-discoloring rubefacients or sedatives to the outside of the face, over the affected parts. The massage of the parts affords some relief. Flagg recommended the following:

℞—Tinct. opii,
Tinct. aconiti,
Chloroformi . . . . . p. æq.—M.
Sig.—To be rubbed on the outside of the face.

Or,

℞—Aconitinæ . . . . . gr. j
Cerati simplicis . . . . . ℥j—M.
Sig.—To be well spatulated. To be distended with oil of cloves or phenol camphor and gently rubbed on the outside of the face, the mouth and eyes to be particularly avoided.

Or, when the aconitine fails to produce relief:

℞—Veratrinæ . . . . . gr. xx
Cerati simplicis . . . . . ℥j—M.
Sig.—To be used in the same manner as the aconitine.

As the tooth advances, the symptoms may become progressively severe. The gum may become inflamed, swollen, and be masticated upon, the oral pyogenic organisms produce infection, presumably finding an entrance at the point proximating the second molar. The patient suffers from the pain and inability to masticate and swallow, and becomes nervous, irritable, and debilitated; the breath becomes fetid and the salivation excessive. The inflammation extends into the contiguous tissues, and pus may form, extending into them; swelling may occur in the adjacent glands, parotid, submaxillary, etc.

It may also extend to the tonsil or pharynx. All mastication is prevented, fever is present, and the patient prostrated; septicemia and death may follow.[1] Reflex pains may occur. Brown[2] relates a case of noma which developed from an infection in this location. The gangrenous condition extended to the lungs. Death ensued.

Results similar to these may occur when the crown is partly erupted, being covered at its distal portion by a curtain of gum which may be ulcerated upon its under surface. This curtain of gum may be thin and stretched, or project rather rigidly over the tooth without stretching, as though attached to it.

In these latter cases the pus, as a rule, finds egress, but occasionally it burrows into the pocket between the tooth and contiguous tissue, causing much inflammation or pus formation. When gum pockets remain about teeth, food may ferment in them and cause deep pus formations which may result in Ludwig's angina, a frequently fatal disease. (See Ludwig's Angina.)

Treatment.—The treatment depends upon the stage to which the inflammation has advanced.

If the patient be able to partly open the mouth, the part may be sterilized by spraying it with a germicide such as a 1 to 2000 solution of mercuric chloride in hydrogen dioxid [or hot carbolized water, followed by application of tincture of iodin. (Brown.)] Following this an injection of novocain solution is made into the flap of tissue, and the gum completely removed from over the face of the crown, or, if feasible, any pocket wall cut away.

To accomplish this, a deep linear cut is made with a sharp bistoury, extending from the distolingual to the mesolingual angle of the crown. A similar cut is made from the distobuccal to the mesobuccal angle. If not already free, the gum is divided at its mesial contact with the distal surface of the second molar. The block is now penetrated by a tenaculum, drawn tense, and the final cut made at the distal border with decidedly curved gum scissors. Less cutting is required in some cases. A special gum guillotine is obtainable, which practically bites out a piece of the gum flap. The electric cautery may be used to burn away the gum tissue (Fig. 175).

The hydrogen dioxid spray should be again applied to remove any possible pus germs present, and should be repeated at intervals of about two hours. Tincture of iodin, diluted about one-half with alcohol, may be applied every few hours, by means of cotton wound on an applicator or tooth pick, and exerts a germicidal effect. A neglect of this simple precaution gave the editor a week of personal

[1] Flagg, and occasional reports.

[2] Dental Cosmos, 1908, p. 5.

discomfort and inability to masticate, after the removal of a trifling and apparently non-inflamed flap of gum. A cold compress should be recommended for the angle of the jaw, if deemed advisable. Magnesium sulphate as a derivative may be used with advantage.

Fig. 175

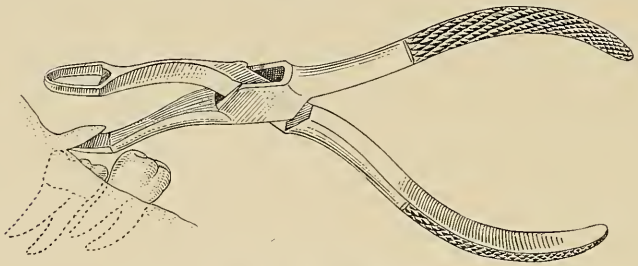

Ash's gum guillotine.

If the patient be confined to his bed and unable to open the jaws, a more difficult operation presents. The first object should be to reduce the intensity of the inflammatory symptoms. This is accomplished by the removal of the gum block as above, if the mouth can be opened sufficiently. Anesthesia may be resorted to, after oral sterilization, for the purpose. A jaw separator is introduced, and

Fig. 176

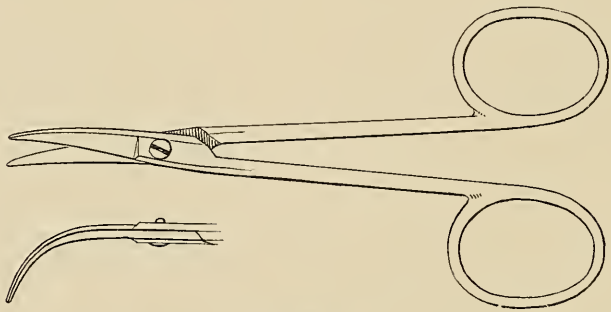

Gum scissors.

operated until sufficient space is gained and the cuts made. If no more be possible at the first visit, the lingual and buccal linear cuts should be made to insure free bloodletting, which may be increased by syringing forcibly with lukewarm water, the position of the patient being such that gravity favors its flowing out of the mouth.

Cold compresses are to be placed over the angle of the jaw and magnesium sulphate and the hot pediluvium administered as deriva-

tives. Cataplasma kaolini, a compound of kaolin (Chinese clay), boric acid, methyl salicylate, glycerin, and small quantities of thymol and oil of peppermint,[1] are useful, applied in quantity to the face, externally. The antiseptic sprays are to be used as before directed.

If, in addition, local massage or electric heat and massage over the angle of the jaw be practised, the swelling and muscular hardness usually disappear in a few days. It is well to then remove the entire block of gum to prevent reinfection. There can be no question that complete anesthesia and thorough gum block removal, at the first visit, is the most advisable surgery. (See Apical Abscess, third stage.)

If the third molar be correctly placed, its eruption, as a rule, proceeds uninterruptedly from this point, though it may never be entirely free from some degree of overlapping by the gum tissue, owing to arrest of eruption by the occlusion of the more advanced upper third molar. Pockets are thus formed which favor food retention, which, undergoing fermentation, may either cause ulceration of the soft parts, or caries of the distal and distobuccal surfaces of the tooth.

Grinding the occlusal face of the upper molar may assist eruption of the lower. The gum flap should be anesthetized and removed by the thermocautery; or if inflamed, be sprayed with hydrogen dioxid, and a pellet of cotton saturated with eugenol introduced for a short time.

More marked malposition may cause difficulty of eruption, necessitating the extraction of the third molar or even of the second molar. In some cases it may be better to also extract the upper third molar, as it will probably elongate in time and allow food to pack into the interspace mesial to it. A presentation of the occlusal face of the third molar to the distal surface of the second molar is a common form of malposition.

If very deep seated, the third molar may at times be diagnosticated in this position by passing an explorer or thin right-angled blade down the distal surface of the second molar, or by means of a deep incision with a bistoury or exploring needle. Failing this, or preferably, replacing it, the *x*-rays are a very valuable means of diagnosis.

In this situation, pathological resorption of the root of the second molar may result, and irritation of its pulp be added as a complication. In this case the second molar must be extracted. (See Malposition.)

A more common form of presentation exhibits the distal surface of the crown above the gum and the meso-occlusal angle locked

[1] Antiphlogistin is the proprietary equivalent.

beneath the cervix of the second molar (Fig. 174). Caries is not infrequently induced by the retention of food. The third molar may be removed by an operation involving the surgical removal of a portion of the base of the coronoid process, followed by extraction. The pulp of the third molar may be devitalized by arsenic applied and sealed in a pit, drilled in its distal surface. After death of a portion of the pulp, the pit may be made to perforate the crown from side to side, and then a dentate fissure bur mounted in the right-angle handpiece, or a disk, may be used to saw off the occlusal half of the crown. In the space thus gained, and between the second and third molars, a wedge of sea-tangle may be neatly fitted; its swelling causes mutual separation, which loosens the third molar somewhat, by the process of resorption. It should now be quite readily extracted by appropriate movements.

Cryer recommends the removal of the occlusal section of the crown of the third molar by means of a carborundum disk, and the removal of the tooth by means of forceps or elevators. Extraction in such a case must be carefully done. The use of the elevator is dangerous, unless laterally applied, as there is danger of fracture of the ramus, which has occurred. (Schamberg.)

The loss of a second molar may be for other reasons necessary, but such a loss in the last case described is equivalent to a loss of two teeth, as the third molar will be of little value.

CHAPTER VIII.

MALFORMATIONS AND MALPOSITIONS OF THE TEETH.

Abnormalities of the teeth are found associated with position, size, form, and structure. Aberrations in form, structure, and size are included under the head of malformations of the teeth; aberrations of position are discussed under the head of malpositions of the teeth. The particular section of dentistry relating to malpositions of the teeth is by general consent made a special department of operative dentistry, that of orthodontia; but many of the phases of the subject are of great pathological interest, although the therapeutic measures usually demanded are mechanical in character and clearly belong to the fields of operative and prosthetic dentistry.

Malformations of the teeth may be macroscopic or visible to the naked eye, or microscopic, requiring special preparation for observation under the microscope.

The causes of imperfectly formed enamel or teeth must be sought by study of the conditions preceding their development. That modifications of general nutrition must modify tooth development seems to be a safe proposition.

An ill-nourished child is apt to have at least poorly organized tooth material, while in one that has actually undergone an exanthematous disease the tooth form subsequently seen is frequently found to have been profoundly modified by the disease.

MICROSCOPIC MALFORMATIONS.

Microscopic or histological defects of the teeth may affect any of the dental tissues, enamel, dentin, cementum, pulp, or pericementum.

Enamel.—Defects in enamel structures range from any degree of orderliness in the even distribution of globular bodies and cementing substance in the tissue, to gross aberrations in formation. The finer variations of structure are not easily recognizable.

Theoretically perfect enamel should show in longitudinal section a series of squares of uniform size built into rods, the outlines of the squares and rods being marked by lines of cementing substance having a refractive index slightly different from that of the squares

(Fig. 118). While such a structure is perhaps never found, it is difficult to draw a line where aberrations from such a standard become pathological. An arbitrary standard might be assumed as follows: Regard any enamel as pathological, where areas of it differ from its general substance to such an extent as to have a decidedly different refractive index. A typical form of abnormality is noted in what are known as opaque spots in the enamel, areas in which an opaque surface exists instead of the normally translucent enamel.

Fig. 177



Portion of a white spot in enamel, showing lack of interprismatic cement substance. × 2000. Compare with Fig. 343. (Williams.)

Opaque Spots in Enamel.—White, brown, and corn-colored opaque areas of enamel are frequently seen, surrounded by apparently normal enamel.

Examined without the aid of the microscope they are seen to present a surface as smooth as any enamel, though sometimes slightly crenated, but upon this surface being broken up with a bur a chalky, granular, whitish material containing at times the yellowish pigment

is seen, sometimes occupying the entire thickness of the enamel. These spots, if slight, are sometimes without this granular character, while the pigment affects the entire thickness of the enamel.

Williams submitted the enamel at the borders of such spots to microscopic examination, and compared it with enamel in the first stages of decay, finding in both a similar appearance, characteristic of a lack of, or a loss of interprismatic cement substance (Fig. 177).

FIG. 178

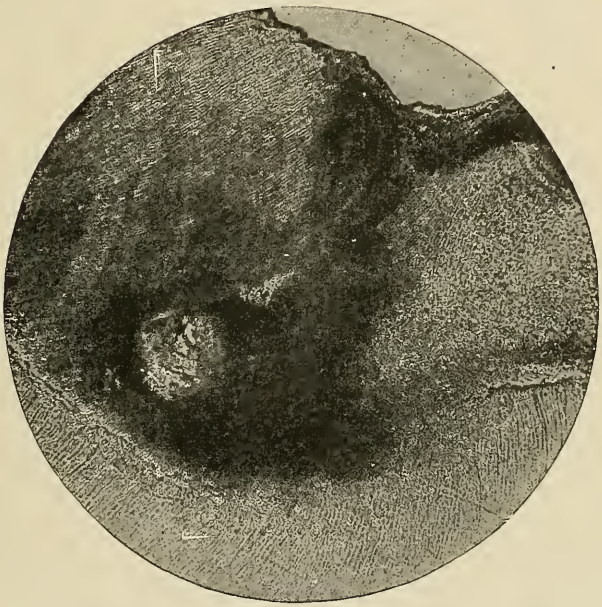

Section through human cuspid, showing sulcus and appearance of tissue in its vicinity. × 75. (Specimen by Choquet; photograph by Williams.)

Upon the data derived from his investigations with the development of the enamel, he concluded that these spots are due to a lack of such cement substance. This leaves, as the probable substance in the spot, unfused globules mingled with some pigment. H. A. Flynn concludes that "as about 87 per cent. of children born and raised in Colorado Springs have defects in enamel, while in other, close by localities these are moderately found, the cause must lie in the lack of lime in vegetable matters in that locality and hence in the milk of cows fed upon them. This lack together with the great demand of the developing osseous system for lime causes a deficiency for the relatively non-important teeth."[1] In one case of an adult lady, a

[1] Items of Interest, January, 1910.

broad, brown spot was seen on a lower left lateral. There was a history of the temporary lateral having been knocked out.

Enamel formation about the sulci of teeth is frequently faulty; owing to an imperfect union of the enamel segments forming the

FIG. 179

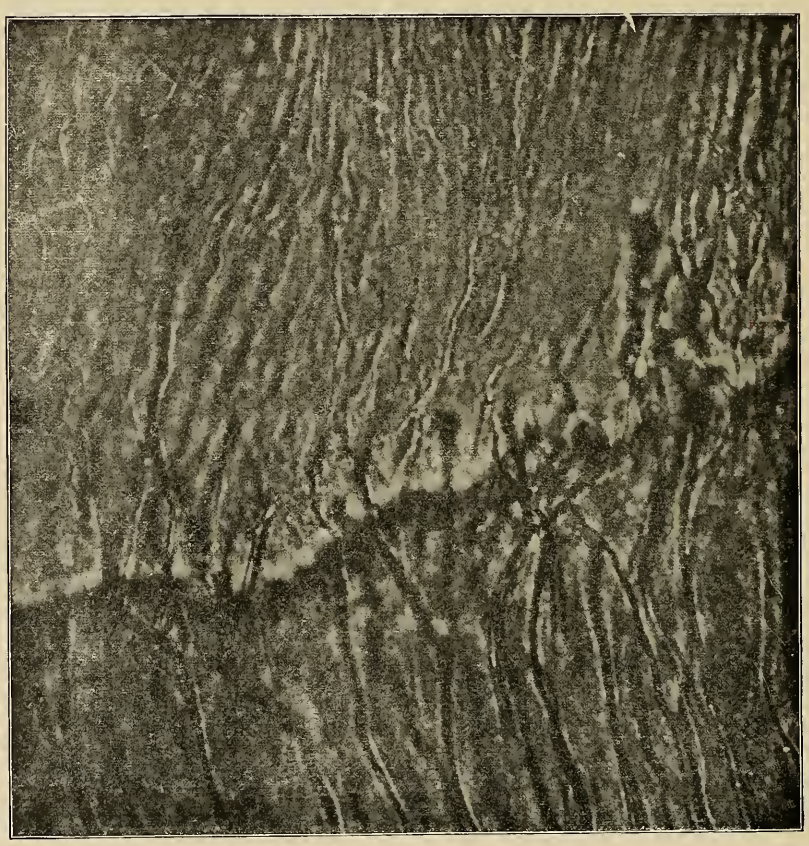

Section of human molar, showing dentinal fibrillæ penetrating enamel. × 600. (Williams.[1])

cusps of the teeth, minute fissures exist in the enamel; these are most marked in the fissures of molars, as shown in Fig. 178. The enamel bounding these fissures has an irregular structure.

The dentinal fibrillæ may penetrate the substance of the enamel (Figs. 179 and 184), occupying defined channels in its substance;

[1] For an interesting article illustrating this point see Boedecker, Dental Cosmos, 1911, p. 1000.

this was formerly regarded as a developmental accident. Caush[1] claims to have found this to be a normal condition of human enamel, and regards these as nutrient spaces. Still later Boedecker has found them to frequently occur in enamel (Fig. 184). Andrews[2] states that 'examination of sections at the junction of formed dentin and ameloblasts show fibres span any space formed between them.' Evidently there must have occurred a mixture of the elements of dentin and enamel, the record showing an interdigitation

FIG. 180

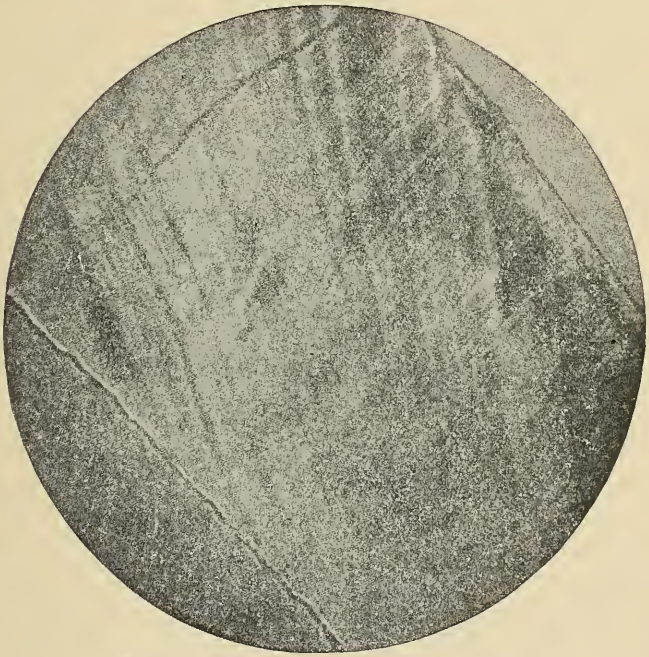

Section of human incisor, showing "bands of Retzius" and marked stratification of enamel. × 125. (Williams.)

of papilla (probably odontoblasts) and enamel organ (probably ameloblasts). After calcification these odontoblastic fibers are caught in the enamel. Von Beust also has experimentally shown this (Fig. 109). Such conditions are not to be confounded with fissures of enamel where large lines of faulty calcification or non-calcification extend through the thickness of enamel. A portion of the enamel may occupy an area within the dentin. This in itself

[1] International Dental Journal, June, 1904.
[2] Dental Cosmos, 1912, p. 49.

shows that the enamel and dentin organs can be heterogeneously arranged. An odontoma is another evidence.

Enamel, even normal enamel, is not of uniform composition; were it so, it would exhibit, in addition to an orderly arrangement of its histological elements, a uniformity in color. So common are differences in this direction that the presence of pigment bands must be regarded as normal. It is the rule to find enamel traversed by deeply pigmented parallel bands, which pass obliquely upward from the surface of the dentin to the surface of the enamel. These are termed the bands of Retzius; they appear to mark the size of the enamel cap at successive periods of its growth (Fig. 180).

Fig. 181

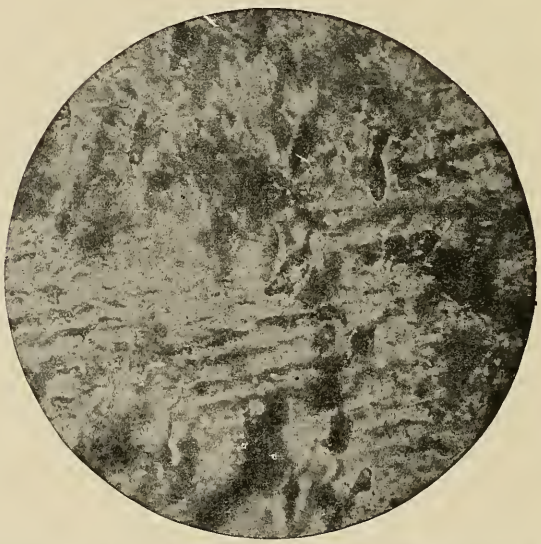

Section of enamel from syphilitic tooth, with appearances resembling the lacunæ of cementum. × 600. (Williams.)

Stratification and striation of the enamel, as shown by Williams, must be regarded as normal physiological records of the mode of enamel formation. Kirk has shown that normal enamel shows variations in density in the same teeth.

All of these histological defects represent variations of deposition, no doubt due to fluctuation of the nutritive processes of the child at the time of tooth formation. Histological records made in the enamel are not like those made in other tissues, for there is no certain provision through which such defects can be remedied at subsequent periods.

Profound nutritive disturbances, such as those attending hereditary syphilis in children, affect the structures of the teeth. One of the gross results of this disease is a common malformation of the general form of the incisors. The hard tissues of such teeth exhibit microscopic evidences of faulty histology; they are dull and opaque, and traversed by irregular bands. Viewed in section, the enamel of such teeth is seen to be almost structureless (Fig. 181). Williams found that the contents of the large, irregular spaces in this enamel did not respond to stains—*i. e.*, did not contain organic matter. Such teeth, when not presenting gross malformations, may have a distinct irregu-

Fig. 182

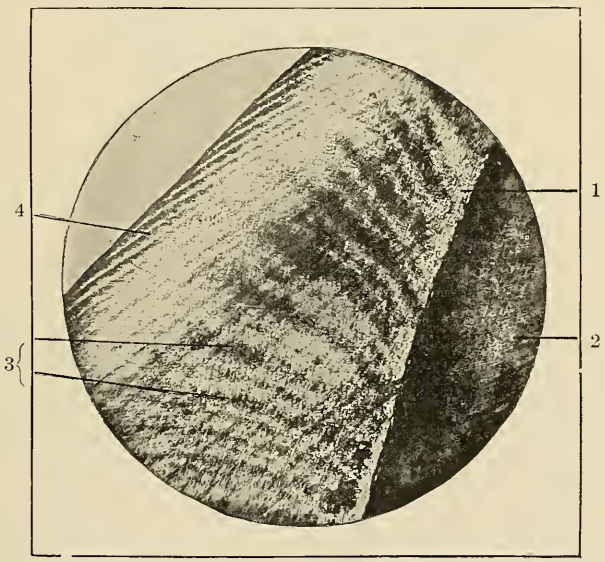

Enamel and dentin, human tooth: 1, enamel; 2, dentin; 1, lines of Schreger in enamel; 4, brown striæ of Retzius. (Probably aggregation of tubes, editor.) (Bromell, after Geise.)

larity of enamel surface. This may even be seen with the naked eye, or graphite may be rubbed over the teeth, bringing out the lines. Cloud-like markings are also seen in enamel, which are called the stripes of Schreger. They run from dentin toward the periphery, and are considered by Pickerill to be due to an optical effect produced by superimposed prisms[1] (Figs. 182 and 183).

There is evidence that other forms of specific dermatitis—scarlet fever and measles—which occur at an early age may affect the formation of enamel. The gross defects attributed to the exanthemata

[1] Pickerill, Dental Cosmos, October, 1913.

are irregular pits upon the crowns of, particularly, the incisors (Figs. 195, etc.), though the cuspids and first molars also suffer. In some

Fig. 183

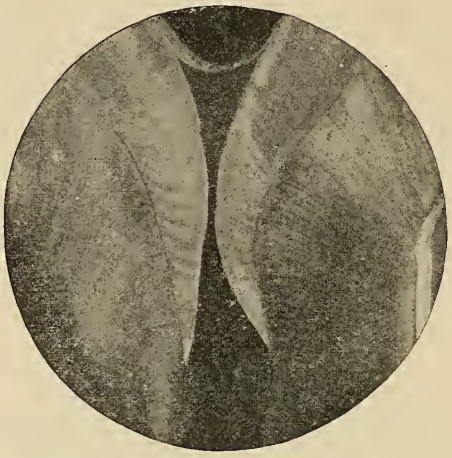

Lines of Schreger in the enamel of a permanent and deciduous tooth (human). Bulge of enamel at cervix of deciduous tooth is shown due to bulging of dentin, not to thickness of enamel. (Pickerill.)

Fig. 184



Specimen of decalcified adult enamel, showing enamel prism sheaths and lamella (*L*), cut longitudinally. × 500. (Boedecker.)

cases the crowns appear honeycombed. The condition is known as hypoplasia of the enamel, and is evidently due to an effect upon the enamel organs. The microscopic structure is also affected. There is evidence in some specimens (Fig. 194) that the dentin may be hypoplastic; the papilla being doubtless affected by the prevailing systemic malnutrition. The dentin being first developed, shows perhaps normal for a distance, then a row of interglobular spaces is found, which is evidence that the dentin organ is affected by the general disturbance at the same time as the enamel organ.

FIG. 185

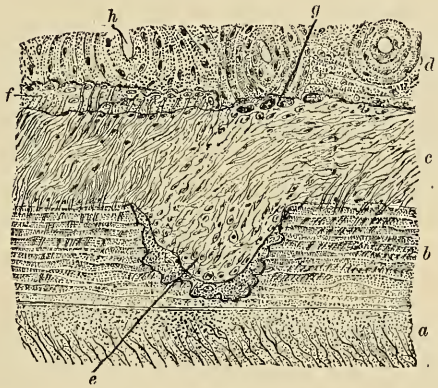

Section of a bicuspid with its alveolus, showing a pit-like absorption upon the side of the root in which the redeposit of the cementum has begun: *a*, dentin; *b*, cementum; *c*, peridental membrane; *d*, bone forming the wall of the alveolus; *e*, absorbed area of cementum. It will be noticed that a new deposit of cementum has begun the filling of the area, and that the soft tissue in the area of absorption is of a cellular type. The bone also shows the effects of absorption in the cutting away of portions of the ring of the Haversian systems at *f*, while at *g* the presence of osteoclasts shows that absorption is in progress at that point. (Black.)

Hopewell-Smith[1] describes the enamel developed during rickets as faulty, and, in so far as limited observation could determine, contained numerous spaces probably filled with soft tissue. These spaces were in the first-formed portions of the specimens observed.

Dentin.—Data regarding the finer phases of defective histological structure of the dentin are meagre. It has been observed that the dentinal tubuli of some teeth are much larger than in others of the same age, and, no doubt, future investigations with an improved technique directed toward a study of the exact mode of dentin formation will exhibit defects more certainly.

The chief histological defects noted in dentin are areas of faulty or non-calcification, called interglobular spaces (Fig. 186). These

[1] Loc. cit.

Fig. 186

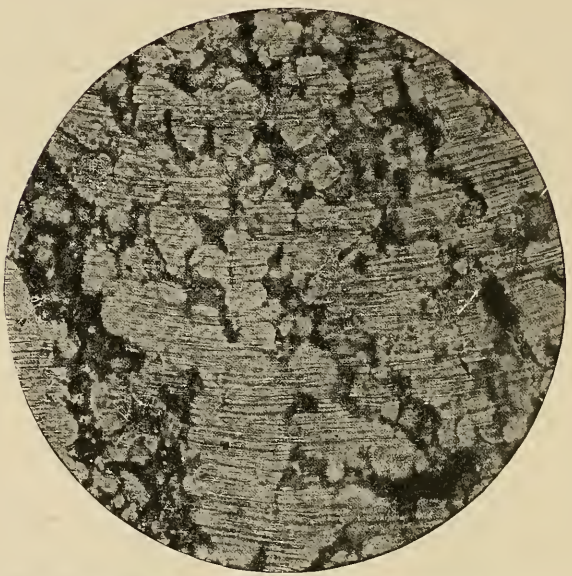

Section showing interglobular spaces in dentin of a syphilitic human tooth. (Williams.)

Fig. 187

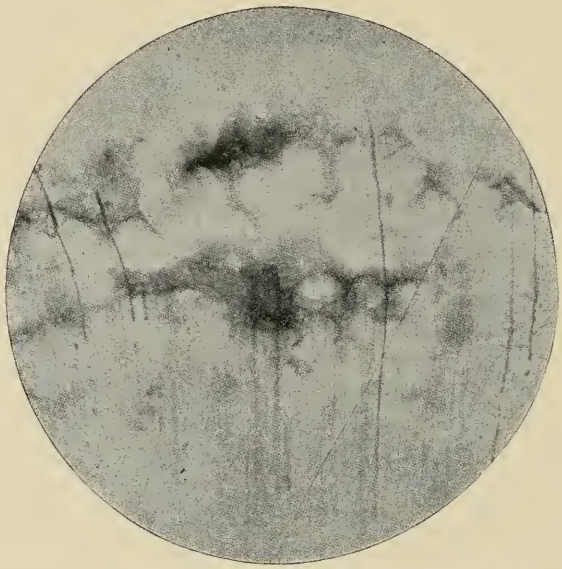

Interglobular spaces crossed by dentinal tubes. Prepared by Weil's process. Magnified 240 times. (Hopewell-Smith.)

are most common in the dentin immediately underlying its covering tissue; so common in the dentin under the cementum that this portion of dentin has been called the stratum granulosum, the granular layer of Tomes (Fig. 124). In the body of the dentin these spaces have a more irregular distribution.

In wet-ground sections (Röse) the dentinal filaments are seen to pursue an unbroken course through these areas. The contents of the interglobular spaces react to stains like the sheaths of Neumann; that is, they probably contain transitional tissue. These areas probably represent, as do defective spots of enamel, periods of depressed vitality, or of altered nutrition. In the light of present knowledge regarding the subject, they are to be viewed as areas in which the calcific process was faulty. The malformations noted in connection with the enamel of teeth have their analogues in the dentin (Fig. 187; also Fig. 195).

FIG. 188



Schreger's lines in dentin. From the ivory of the tusk of a walrus. Prepared by grinding. Unstained. × 45. (Hopewell-Smith.)

Interblobular spaces afford some evidence of the formation of dentin by a deposition of globular bodies in a matrix of protoplasmic material. The continuation of the tubules through the mass of uncalcified contents is evidence of their probable independent formation by the fibril cells (Fig. 187).

Occasionally lines appear in dentin at a common developmental level and having a degree of parallelism to the pulp surface. They are evidently records of a new period of increment and consist of short curves in the tubules. They are called contour lines of Owen, also lines of Schreger, in dentin (Figs. 188 and 189).

Fig. 189

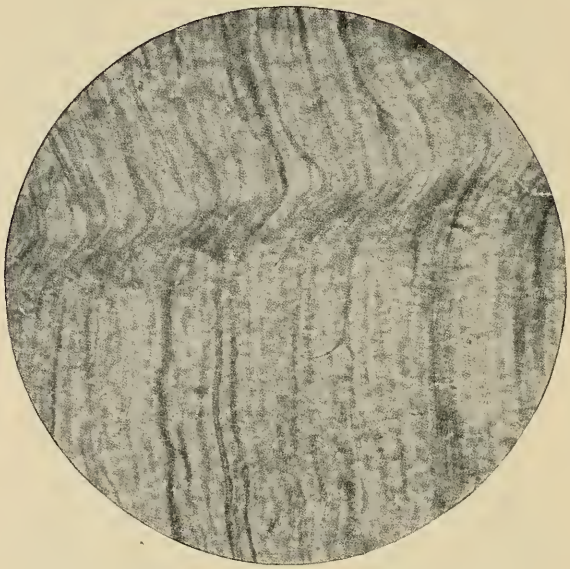

The same as Fig. 189. × 420. (Hopewell-Smith.)

Histological malformations of the pulp have not been recorded, the normal histology of the organ not being made out with sufficient certainty to determine what appearances are to be regarded as abnormal. Grosser aberrations, such as those shown in Fig. 137, are made out.

Cementum.—As stated in Chapter VI, the pericementum contains numbers of multinucleated cells—odontoclasts; and their presence is not to be regarded as abnormal. The cementum of the roots of teeth may exhibit evidences of former action of these cells in excavations of cementum, which, by a subsequent deposition of cementum, have become filled. This gives an irregular course to the cement laminæ (Fig. 185). These appearances are to be regarded as not necessarily pathological, for the following reason: for some time (years) subsequent to the eruption of the teeth, developmental changes occur in the alveolar bones; depositions (subperiosteal) increasing their volume are accompanied by resorption of other portions of the bone, such a balance being kept between their pro-

cesses that the teeth, although shifting their positions, are kept in normal occlusion.

The cementum may be thickened by additional deposits, as in hypercementosis, which is an excess of development classed as pathological.

MACROSCOPIC MALFORMATIONS.

The teeth may vary from the normal, either as regards size or external configuration.

Variations as to Size.—It is patent to the most casual observer that the teeth vary as to size. Comparisons in this direction are made by an examination of the upper central incisors. Fig. 191 shows nearly the extremes of observable sizes; Guilford[1] points out that excessively large, central incisor crowns are usually supported by abnormally small conical roots. Marked giantism of the central incisors usually occurs in pairs, the other teeth being of normal size. On the other hand, dental giantism of less degree may involve all of the teeth of a denture. The molar teeth are occasionally of enormous size, the bicuspids rarely so, and the cuspids next in frequency to the molars as to the occurrence of giantism. Guilford observes that giantism of the cuspid crowns, unlike that of the central incisors, is usually accompanied by an increased size of root. He mentions the case of a cuspid measuring an inch and one-half in length from tip to tip.

Fig. 190

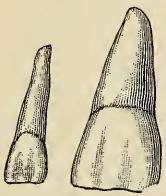

Fig. 191

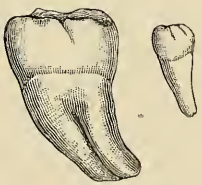

Dwarf Teeth.—Deficiency in size is of more common occurrence than excessive size. It appears to occur more frequently with the upper third molars and upper lateral incisors than with any other teeth. Fig. 192 shows the extremes in size between two perfectly formed lower third molars. The stunting of these and of other teeth is, however, usually associated with such an aberration of outward form that most dwarf teeth must be considered as abnormal in form as well as in size. The writer has seen a supernumerary with crown and root together measuring one-eighth inch.

[1] American System of Dentistry, vol. iii.

Fig. 192

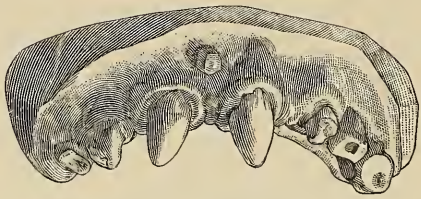

Tusk-like permanent central incisors; temporary teeth retained on either side. Female, aged twenty-five years.

Fig. 193



Conical lateral incisor transformed by porcelain crown.

Fig. 194

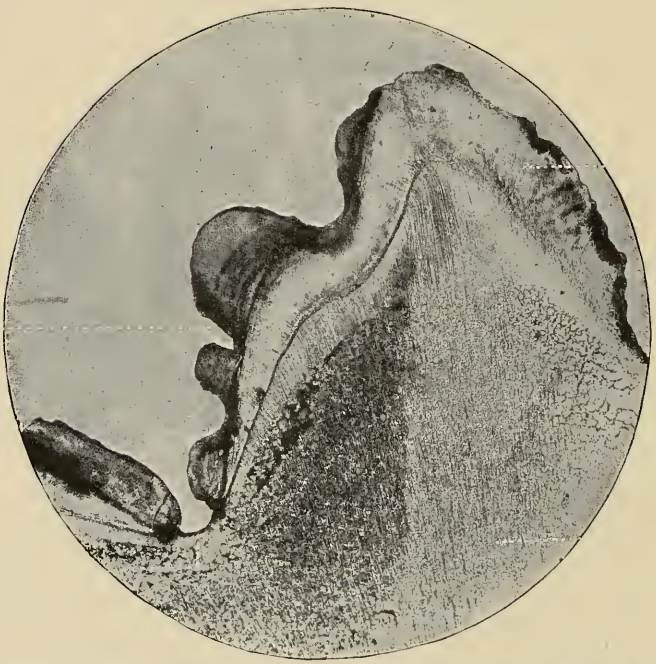

Hypoplasia of enamel, showing arrested stratification; dentine shows effects of hypoplasia at interglobular spaces (Hopewell-Smith.)

A central incisor, or more frequently a lateral incisor, may have a conical crown, as shown in Fig. 193. The condition may be double.

Upper third molars frequently consist of but a single cone, diminutive in size; at times a crater-like crown is formed by a series of small cones about a central pit.

Treatment.—The Land jacket crown is very useful in modifying the cone into a typical tooth form (Fig. 193).

Hypoplasia of the Dental Structures.—By hypoplasia in this connection is meant an arrested development of any portion of a tooth. Necessarily the tooth is deformed.

Fig. 195

Hypoplasia due to eruptive fevers.

Fig. 196

Hypoplasia of incisal portion of enamel.

The term atrophy has been used in this sense, but is better confined to a lessening in size after normal development of a part has occurred. (See p. 79.) Nutritional disturbances, the exanthemata, and syphilis all seem to have a profound influence upon the form of teeth developing during the period of active disease, by affecting the cells of the formative organs. With the passing of this period, the development of the tooth may proceed in an orderly manner. The following forms of hypoplasia are known:

Pitted and Grooved Teeth.—The hypoplasias described under this heading may consist of a series of irregular grooves or pittings, the crowns having approximately the normal outlines. Of these malformations Figs. 197 to 200 are fairly typical.

Black regards the formation of pits, the simultaneously developed zone of enamel being perfect, as due to aberration in development of enamel rods, leaving a hole (doubtless a localized effect upon the ameloblasts). Histologically the strata of the enamel partly fail of deposition at these points (Fig. 195).

With a history of a case, including the age of the child at the period of the disease, if examination be made of the positions of the defects, the age will serve as an indication as to whether there has been any connection between the eruptive fever and the dental malformation. For example, if enamel pits upon incisors have been caused by an eruptive fever between the ages of four and five, they should occupy

a part a little above the half-way area of the crown face of a central incisor. The lateral will be affected nearer the incisal edge and the cuspid still more so: it is evident that the enamel being already formed about the incisal edge of the tooth, alterations of nutrition could not affect the already formed tissue. (See Fig. 116.) The enamel formed after a period of attack may be perfect (Figs. 197 and 200).

Fig. 197

Fig. 198



Showing the front teeth grooved from the alternation of perfectly and imperfectly developed portions of enamel. Hypoplasia. (Tomes.)

Hutchinson's Teeth (Hypoplasia).—During the first few weeks after birth, skin eruptions characteristic of hereditary syphilis are apt to occur in the contaminated child. At this period the tips of the permanent incisors are undergoing development, the first permanent molar having started at the twenty-fifth week of gestation (see Fig. 116), and the effect of the syphilitic eruption, during which

Fig. 199

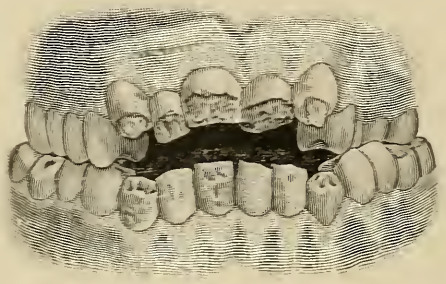

Malformations of incisal half of crowns, with cervical half perfect. Hypoplasia. (Model by W. A. Capon.)

the protozoon treponema pallidum may be in the enamel organ (or there is a severe disturbance of metabolism brought about by the infection, according to the preferred view of Stein[1]), is to cause a disturbance of the enamel organ and papilla, which produces a

[1] Dental Cosmos, July, 1913, p. 693.

defective development at this point. Instead of the normal angles and flattened curves of the labial surfaces, the incisors may have

FIG. 200

Pitted and fringed teeth, some of them carious at the incisal edges. Specimen in museum of Philadelphia Dental College.

FIG. 201

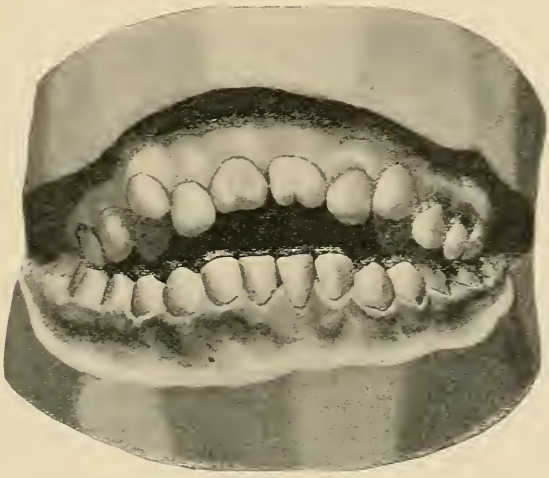

Hutchinson's teeth. Hypoplasia. Two upper centrals notched and contracted. Characteristically undeveloped upper jaw. From an hereditary syphilitic, aged twelve years.

a roughly rounded and stunted appearance. The incisal edge of the tooth is narrower than its neck. The enamel at this edge is irregularly and badly formed; but there is a semblance of the three

enamel tubercles found normally. The middle tubercle, being composed of defective enamel, is soon lost by abrasion, causing the tooth to have a notched appearance (Figs. 201, 202, and 203). Stein quotes an old authority as having seen one central notched and the other normal. The first permanent molars are often exceedingly corrugated and pitted, the pits extending into the dentin. These pits often decay, the points are broken or worn away, sometimes leaving a discolored, often black surface. (Fig. 204.)

In an exhaustive treatise upon this subject, Cavallaro[1] has shown that the pitted cuspal deformity of the first molars, the notched incisors of Hutchinson, and the dystrophic cusps of canines in the permanent set, as well as similar effects occurring in the temporary set, are the stigmata of hereditary syphilis, either direct or in the second generation. He found the treponema pallidum in the dental follicles of syphilitic fetuses.

Fig. 202

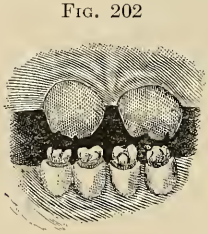

Syphilitic teeth in upper and lower jaws as they appear when recently erupted.

Fig. 203

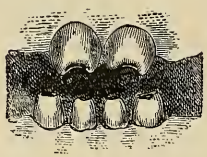

The teeth of hereditary syphilis at maturity.

He calls attention to the possible effect upon the first molar enamel (developing before birth) alone, as indicating the cessation of treponemal activity, though the incisor enamel (developing after birth) is usually affected. The cuspid (developing still later) may not be affected; which shows a cessation of germ activity between incisor and cuspid development. The dental stigmata may thus occur in the absence of the under-developed body and other physical characteristics of syphilis, though these may also be in evidence, as well as a history or evidence of more or less active manifestations of syphilis.[2]

[1] Dental Cosmos, 1908.

[2] No matter what conviction a dentist has that these dystrophies are of syphilitic origin, he must be cautious regarding the expression of his opinion. Even the thoughtless leaving of a copy of this volume upon the desk from which it was picked up and this chapter seen by a lady patient, produced questions of a very embarrassing character, regarding certain defects in her child's teeth. Unfortunately, Cavallaro's investigations do not take sufficient cognizance of the possible intervention of other exanthemata, either in the subject or mother; for example, in his Case XX, a girl, aged fourteen years, hereditary syphilitic showing transverse grooves in the teeth, the effects are attributed to syphilis. The child may easily have had other complications, such as measles. Stein excludes rachitis, variola, scarlatina, diphtheria, typhoid and rheumatism as very rare possible causes of the hypoplasia.

Stein[1] argues that as the stigmata are bilateral and symmetrical, they could not have been produced by causes acting locally, but that the general disturbance of metabolism affecting the developmental organs of the teeth causes interference with the functions of such of them as should be actively developing tooth structure.

Fig. 204

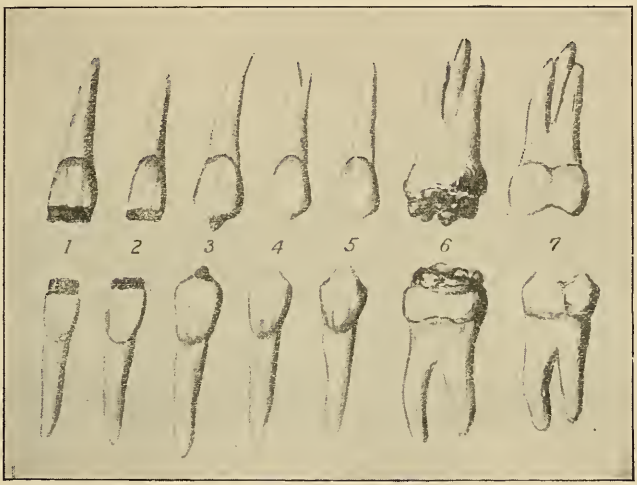

Semidiagrammatic representation of a systematized hypoplasia of several kinds of upper and lower teeth. The general systemic disturbance which must have caused these stigmata, commenced about the twenty-fifth week of intra-uterine life and continued up to about the fourth month after birth. (The third molars omitted.) (Stein.)

While to syphilis, may now be accredited much of the pittings upon teeth, the history of an attack of one of the exanthemata, such as scarlet fever or measles, at a certain age corresponding to the development of the particular part of the tooth which has undergone hyperplasia makes it rational to accredit the effect to such exanthema. Measles often causes characteristic eruptions in the mucous membrane of the mouth and pharynx, and could easily affect the dental follicle. If the disease and the effect do not correspond chronologically they should not be related. Syphilis is in a way, an exanthematous disease of chronic nature.

In hereditary syphilitics, Cavallaro found the following dental stigmata: Hypoplastic defects of systematic character with predilection for the central incisor forming the notched incisor or Hutchinson's tooth, and also cuspal defects, white sulci, white marks, delay

[1] Dental Cosmos, July, 1913, p. 695.

of development and eruption, dental infantilism, microdontism, amorphism, persistence of deciduous teeth, cuspal defects of deciduous teeth, especially the second molar, anomalies of structure, shape, number, direction, arrangement, and color, vulnerability of the dental system, ectopia, total or partial absence of teeth, wearing away, premature caries, premature loss of teeth, space between teeth, diastema. Also the following maxillary stigmata: malocclusion, defective articulation of the dental arches, prognathism, ogival palate and cleft palate.

FIG. 205

Hutchinson's teeth, cuspal atrophy of canines and molars. Multiple sulciform erosions. Diastema. (Cavallaro.)

Stein offers the following perhaps more clearly expressed classification:

"1. Multiple disseminated stigmata of the teeth, both in the maxilla and the mandible.

2. Symmetrical stigmata here and there upon homologous teeth.

3. Systematized stigmata at the same level on teeth of the same kind, but at a different level on different kinds of teeth.

The most characteristic stigmata of the teeth of heredosyphilis are:

1. Hypoplasia of the four first molars.

2. A systematized hypoplasia upon the several upper and lower teeth.

3. Hutchinson's teeth. Microdontism and non-replacement of deciduous teeth due to arrested development of the permanent successors are regarded by Stein as stigmata."

Black[1] states that any malnutrition, even a burn, typhoid fever, a spasm, etc., may mark teeth as a nail may be grooved. He claims to have seen Hutchinson's[2] teeth without history of taint.

[1] Dental Review, 1906.

[2] Dental Digest, 1904.

As it ordinarily causes embarrassment to question dental patients regarding syphillis, the Wassermann and luetin reactions may be resorted to if a diagnosis be needed.

Stein states that the Wassermann may be positive or negative in heredosyphilis.

The point at which the arrested development would occur, is that part under development at the time the nutritional or infective disturbance occurs. When several developing teeth are attacked, the centrals are marked nearer the neck than laterals, and these nearer than cuspids. The first molars are often occlusally defective, as well as incisors, and sometimes the incisors have only white or brown spots instead of the incisal notch; bicuspids are only rarely marked.

A lack of development of the anterior portion of the upper jaw has been noted in a number of cases clearly syphilitic (Fig. 201). It has been noted that not all syphilitic children present these dental appearances; and, again, appearances *said* to be identical with them are observed in children *said* not to be syphilitic; nevertheless, the presence of such teeth is usually regarded as a valuable diagnostic sign of hereditary syphilis. The existence of interstitial keratitis and of chronic catarrh of the middle ear, in connection with Hutchinson's teeth are held to be positively diagnostic signs of hereditary syphilis (Hare).

Oberwarth,[1] in a synopsis of associate symptoms, mentions central deafness, chronic hydrarthrosis of the knee, periostitis of the tibia, tumefaction of the spleen and liver, radiating cicatrices of the lips, adenopathies, ozena, and deformities of the bridge of the nose, cutaneous gummata, hemoglobinuria, and cerebral phenomena as possibilities deduced from a study of his known cases of hereditary syphilis.

In 605 hereditary syphilitics observed by Sidler, Huguenin, and the Fourniers, the stigmata averaged as follows: ocular, 50 per cent.; dental, 43 per cent.; aural, 16 per cent.[2]

Therapeutics based upon such a diagnosis are followed by better results, as a rule, than when the general indication is ignored. The boy from whose mouth a model (Fig. 201) was obtained, had interstitial keratitis in the left eye, chronic nasal catarrh, and a somewhat flat development of the nasal bones.

Tomes favors, and adduces evidence to support the contention of Hutchinson, that honeycombed incisal edges of incisors and cuspids and occlusal surfaces of first molars are indicative of mercurials administered in early childhood.

[1] Review by Dental Cosmos, 1908, p. 179. [2] Cavallaro: Dental Cosmos, 1909.

Pitted, grooved, or otherwise malformed teeth may decay sometimes so badly as to produce a black, slimy appearance almost loathsome to view. In other cases surprisingly little caries develops.

Agenesia of Enamel.—Cases are observed where there has been a formative crisis to the extent of having apparently no enamel whatever formed over the occlusal section of the crown, its deposit on the remainder of the crown being quite normal (Fig. 196).

Fig. 206



Dentinal tubuli terminating in the spaces of the granular layer. (Tomes.)

D. B. Freeman[1] records the case of an individual, aged twenty-six years, whose teeth anterior to the second molar were entirely devoid of enamel. The condition was hereditary; it appeared in both brothers and sisters, and could be traced back for three generations.

Hopewell-Smith[2] claims that teeth apparently devoid of enamel have, in all cases examined by him, had attenuated enamel upon them. This would also be classified as hypoplasia.

Black[3] has described the teeth of a man, aged twenty-seven years, as having enamel of an opaque, paper-white appearance, as readily cut as a slate pencil, and with dentin of ordinary consistence. The teeth presented little caries. He also described the temporary teeth of a child as all without trace of enamel, the dentin soft, bendable in any direction, with production of pain, and penetrable with a sharp explorer (agenesia of enamel).

Treatment.—If slightly pitted, gold or porcelain fillings may be introduced. Single pits collect stains which are not removed by the brush. It is well to concave these with a small finishing bur, and to furnish the patient a sharply pointed stick, for cleansing with tooth powder or pumice. In some cases, grinding off the rough incisal edge is sufficient; in other cases the teeth may require to be drawn down after this procedure, or porcelain inlays may be used to restore the incisal edges. In the extremely disagreeable cases above men-

[1] Guilford: American System of Dentistry, vol. iii.
[2] Histology and Patho. Histology of the Teeth.
[3] Dental Cosmos, June, 1908.

tioned, some form of crowning must be resorted to. Fig. 207 exhibits a restoration of the case shown in Fig. 199.

Hopewell Smith[1] has observed an entire absence of crowns, not due to wear or caries, both on upper and lower teeth, in four generations in one family. Therefore, they are cases of extreme hereditary agenesia of the crowns.

FIG. 207

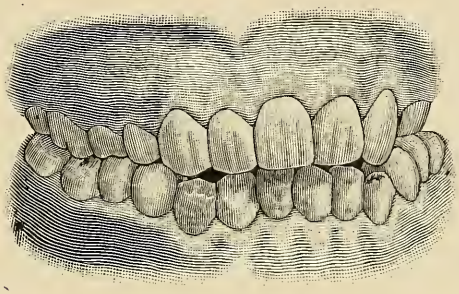

Same as Fig. 178, with Land jacket crowns placed over anterior teeth. (W. A. Capon.)

Fusion of Teeth.—Two or more teeth may be united during the process of development. The union may occur (1) by the crowns, (2) by the roots alone, and (3) by both crowns and roots.

1. Fused teeth united by the crowns alone have not been shown. The nearest approach to it is the case illustrated by Tomes, in which two central incisors have fused by union of the crown portions and one-fifth of the root portions of the two teeth (Fig. 208). Such teeth would have dentin common to both crowns at the point of union, the enamel being reflected over the outside of the common dentinal mass, according to the scheme shown in the diagram Fig. 213, *B*. The pulp may be common to the two teeth in the crown. Of course, the root pulps are separate.

The condition is a record of the fact that prior to dentification the papillæ and enamel organs of the two teeth have coalesced at some point. This must have occurred at an early period, perhaps even during the descent of the cords into the jaw. When it is considered that the two central incisors are contained in two separate intermaxillary bones, the rarity of such a union and in such a manner may be appreciated. I have seen such a union between a right lower central and lateral incisor, in the mouth. Recession of the gum permitted a view of the cervical conformation.

[1] Dental Cosmos, August, 1913, p. 781.

2. Those teeth united by fusion of the roots have a common dentin at the point of union, with cementum reflected over that. The pulp is common to the two teeth at the point of fusion.

Fig. 208

Lingual view.

Fig. 209

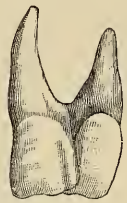

Labial view.

Fusion of two permanent upper central incisors by their crowns and a portion of the roots. (Tomes.)

In the specimen shown in Fig. 210 at *a* there is but one apical foramen. In that shown at *b* and *c* there is but one foramen for the two fused portions of pulp, though the other canals have their usual foramina. These cases evidence an accidental coalescence of pulps after much independent root formation.

Fig. 210

a *b* *c* *d* *e*

a, fusion of two molars at the roots—two pulp cavities, one foramen; *b*, *c*, fusion of supernumerary teeth roots to buccal roots of upper molars, pulp canal common where probes cross; *d*, view of resorbed root end of two fused temporary teeth; *e*, concrescence by hypercementosis.

3. Fusion throughout both crowns and roots have the same characteristics as the others, combined in the one specimen (Fig. 214). The diagram (Fig. 213) shows the scheme for the crown and root.

Fig. 216 shows specimens of fusion in both the upper and lower jaws. It occurs also with the temporary teeth (Fig. 217). Fig.

213, *A* shows a very rare condition, the fusion of the temporary central, lateral, and cuspid of one side (triple fusion).

Fig. 211

Attachment of temporary teeth by their pericementi.

Fig. 212

Fusion of a supernumerary tooth, with an upper third molar.

Fusion is evidently an abnormality of development, dependent upon coalescence of formative organs at some point, and is most likely to occur where the adjacent tooth follicles have least anatomical separation from their fellows. The roots of fused temporary teeth are resorbed as usual (Fig. 210, *d*).

No particular treatment is required unless the mass in some way causes interference with function, which is unusual. The teeth having a common pulp, no attempt should be made to divide them.

Fig. 213

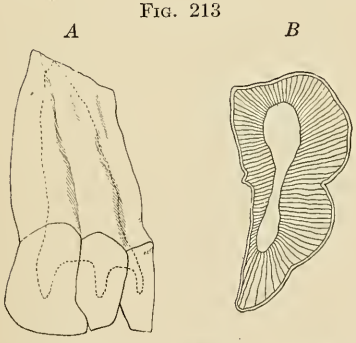

A, diagram of a case of triple fusion, showing crowns with independent incisal edges and pulps; but otherwise fused into one crown with one pulp; *B*, transverse section of same, showing common pulp cavity and common dentin overlaid by enamel (or cementum). From a perfect specimen in the editor's collection. (Enlarged.)

Fig. 214

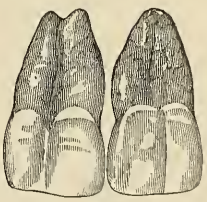

Permanent central and lateral incisors of the upper jaw, united throughout the whole length of the teeth. (Tomes.)

Fusions are most common between the anterior teeth of each set and between the second and third, or third and fourth (supernumerary), permanent molars. It has not been noted in bicuspids, presumably because these teeth lie in the bifurcations of the temporary molars.

Concrescence of Teeth.—Concrescence of teeth is their union after the tooth is formed; it is evident, therefore, that the union can only

be caused by fusion of cementum. This means that during the formative and eruptive period, or after eruption, the bony partition

Fig. 215



Geminous upper laterals with common pulp. Practice of Dr. Varney Barnes. (Skiagraph by E. Ballard Lodge.)

between the teeth disappears, and that their pericementi become united, receding from the line of compression as cementum is deposited between and joining the roots. The united teeth show evidences of hypercementosis at points other than the point of union

Fig. 216

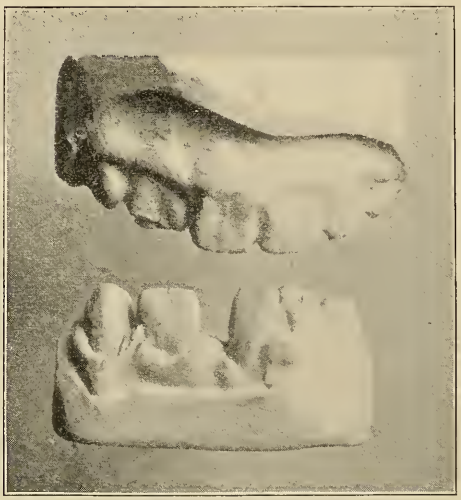

A, usion of upper geminous, permanent laterals; *B*, fusion of lower right permanent central and lateral incisions.

(Fig. 210, *e*, and Fig. 218). At times the roots of the same tooth undergo either fusion or concrescence.

During the eruption of the third molars, particularly the upper, temporary lack of space for the eruption of the crown may cause resorption of the bone covering the roots of the second molar, and fusion of the formative pericementum of the third molar with that of the second occurs; a deposition of cementum then binds the teeth together, preventing the eruption of the third molar. More than two teeth may be thus united. The lower third molar rarely presents its roots to those of the second molar; the contrary presentation is the rule.

FIG. 217

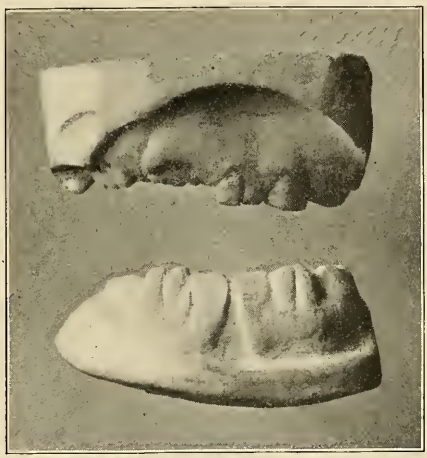

Fusion of upper temporary teeth. Double fusion of lower temporary lateral and cuspid.

In at least one case, the crown of the upper third molar was partly erupted when concrescence occurred. Retained in this situation, the crown decayed away, necessitating extraction; the second molar came away with it (see p. 266). The condition also occurs apart from the eruptive process. Excessive hypercementosis upon the roots of individual teeth may finally result in their union (Fig. 210, *e*).

The only treatment required for concrescence is that indicated for impaction or hypercementosis (which see).

The tough fibrous gum tissue or pericementum has caused two temporary teeth to be extracted together at times (Fig. 211).

Pont cites a case of attachment of a lower first molar distal root to the mesial root of the second molar by a strong fibrous ligament, 2 mm. in diameter, and causing fracture and removal with the first molar. There is also sometimes a firm fibrous pericemental attachment between a tooth and the alveolar process or bone. In one case a portion of the antral floor was torn out with the apical tissue.

Fig. 219 illustrates a remarkable case of combined fusion, concrescence, flexion, and hypercementosis. In this case two abnormal third molar crowns were first formed. The roots were fused during development, though individual single-pulp canals were formed, which joined to form one foramen. The lapped condition of the roots was due to pulp flexion previous to root deposition. The carious second molar roots all became hypercementosed and probably from non-occlusion. As the fused teeth erupted, they presented one root to one root of the second molar.

The junction of these occurred as the result of formations of cementum

Fig. 219

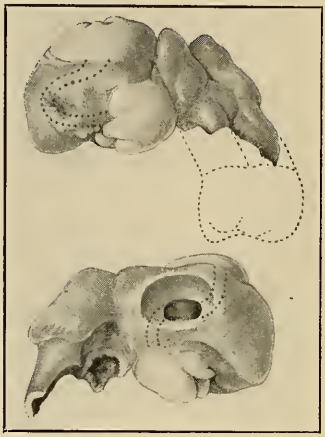

Case of fusion of two abnormal molars and concrescence with the root of a right upper second molar (restored for illustration.) Pulp canals shown in outline. Common apical foramen (enlarged.) (From author's collection.)

Fig. 218

Concrescence. Third upper molar imprisoned between the roots of the second molar.

(concrescence). The widely open crater-like pit in each crown shows the persistence of soft tissue (enamel organ) at that point, or a lack of enamel development there.

Mechanical Union of Teeth.—Teeth upon extraction are occasionally found united by alveolar bone which is locked between the roots of the two or more teeth and prefers to fracture elsewhere. Occasionally a sequestrum contains several teeth (Fig. 172).

Gemination of Teeth (Twin Teeth).—This term has been used by Tomes in the sense of union of teeth, but it is perhaps better used to designate supplemental teeth of the same class. In twin teeth, the enamel organ of a permanent or temporary tooth is duplicated, in all probability, two buds arising from the cord or band, as the case may be.

In gemination, one of the teeth formed is, of course, a supernumerary tooth, but in some cases both are typical teeth (Fig. 220). The second germ may develop an atypical tooth or one but slightly

abnormal in form. The geminous teeth may undergo fusion, as seen in Fig. 216, *A*.

Duplication of the Pulp Cavity.—Hopewell-Smith calls attention to a case of an upper permanent central incisor containing two pulp cavities in the coronal portion, probably an interrupted gemination.

Fig. 220

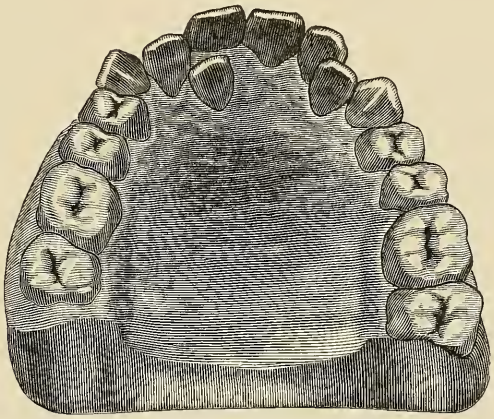

Double gemination of upper permanent lateral incisiors.

Dilaceration.—By dilaceration is meant a displacement of a formed portion of a tooth in such a manner as to change its relative position to the soft parts engaged in its development, the development then being continued in the new relation.[1] For example, an accident to a temporary tooth occurs and the force may displace the partially formed permanent crown, altering its relation to the enamel organ and papilla engaged in its formation. The balance of the crown may be formed in the new situation and be of fairly perfect or of imperfect structure (Fig. 221). This is most likely to occur with the anterior teeth, especially when a temporary tooth is driven into the alveolar process, its root in turn displacing the permanent tooth, thus twisting its relation to its formative organs.

Flexion.—Flexion means the movement of one of the formative organs of a tooth away from its normal relation to the hard part it is developing. The soft part has its position altered, the hard part remaining in correct position. Subsequent formations therefore have an abnormal relation to the previously formed portions of the tooth.

As an example of flexion, a portion of the enamel organ of a tooth may be displaced and in its new relations may form enamel in an

[1] Tomes.

unusual situation, as, for example, upon the side or neck of the root (see enamel nodule) or even in the bifurcation or on the apex of the root (Figs. 222 and 225). Again, it is probable that lack of space may cause deflection of a pulp engaged in root formation, a curved root being the result (Fig. 231). The pericementum (follicle wall) moves with the pulp in these cases.

Fig. 221

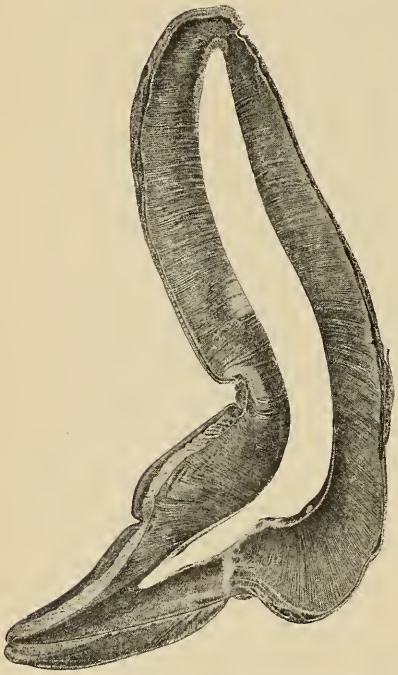

Dilaceration. Shows fold in the labial enamel and cervical dentin. (After von Wunschheim.[1])

Fig. 222

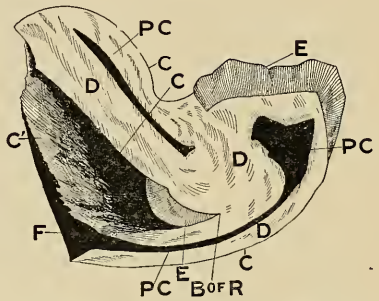

Pulp hernia and flexion, mesiodistal section: *E*, enamel, distal section in the bifurcation of the roots; *D*, dentin; *C*, *C'*, cementum; *PC*, pulp cavity; *F*, large apical foramen: *B of R*, bifurcation of the roots. (From a specimen, enlarged.)

Fig. 223

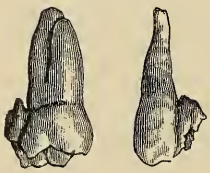

Enamel excrescences. (Salter.)

Unusual Locations of Enamel.—That during development, the enamel organ or portions of it, may assume an abnormal relation to the pulp, is evidenced by odontomes. Apart from these, there are evidences seen in teeth which show that portions of the enamel organ may become detached from the main organ, and develop enamel in unusual situations. Thus columns of enamel may penetrate the body of the dentin.

A small nodule or cap of enamel overlying dentin, and itself overlapped at the edges by cementum (Fig. 226), may be found upon the root of a molar, usually upon the side of an upper third molar at a

[1] G. von Wunschheim: Fracturen, Infraktionen und Knickungen der Zähne.

point about one-eighth inch from the cervical margin of the crown enamel; but one may be one-half inch distant from the enamel mar-

Fig. 224

Lower molar with enamel nodule connected to the enamel of crown by a ridge enamel.

Fig. 225

Five-rooted upper molar, cap of enamel on end of one root.

gin. A thin ridge of enamel sometimes, though not usually, seen connecting them, indicates the nodule to have been formed by a detached portion of the original enamel organ (Fig. 224). This forma-

Fig. 226

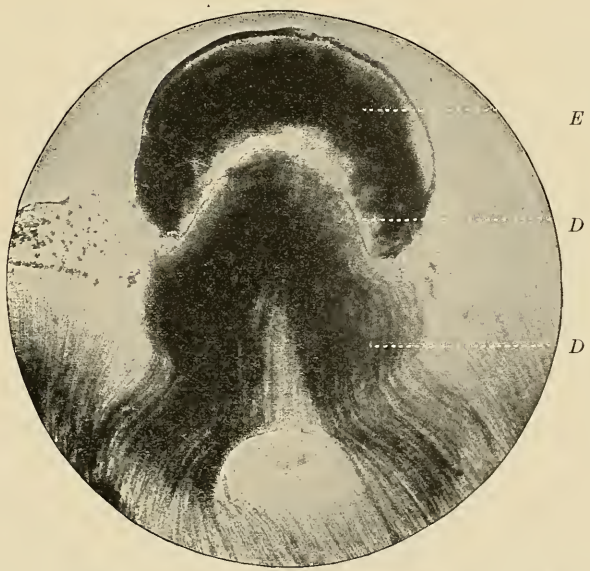

Structure of enamel nodule. *E*, enamel; *D*, *D*, dentin. (Hopewell-Smith.)

tion is known as an enamel nodule. It may occur upon a lower molar, though usually found upon the upper molars. Two may

exist on opposite sides of a molar, as in a specimen possessed by the editor. They may cause neuralgia. (Ottofy.)

A molar root may have a cap of enamel upon its apex, an evidence of extreme displacement, even more than shown in Fig. 225. Sometimes an enamel ridge runs down the side of a root; sometimes an excrescence may be found upon the enamel (Fig. 223). Fig. 222

Fig. 227

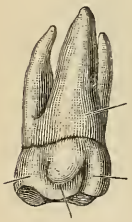

Upper molar with supplemental cusp on lingual side.

Fig. 228

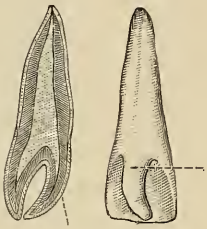

Showing talon-like unusual development of the cingule on an incisor. (From case reported by W. H. Mitchell, Dental Cosmos, vol. xxxiv.)

Fig. 229

Very large supplemental cusp on the buccal surface of upper molar. Probably a fused "paramolar."

shows enamel formed in the bifurcation of the roots of a lower molar. This enamel nodule has been explained upon the hypothesis that the remains of the epithelial root sheath of Hertwig have within them the inherent power of forming enamel, which may account for enamel on the side or end of a root. As this epithelial root-sheath

Fig. 230

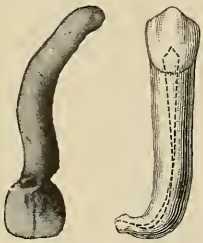

Cuspids with long roots.

Fig. 231

Curved roots.

Fig. 232

Upper cuspid with two roots.

is probably the trailing remains of the enamel organ left as the organ is carried up by the tooth, it is quite likely that larger portions of the organ may be detached as above explained. (See Fig. 98.)

Supplemental Cusps.—Occasionally a tooth has a greater number of cusps than usual. The most common form of this condition is a supplemental mass attached to the palatal side of the mesopalatine

cone of the upper first molars (Fig. 227). It is more rarely the case that a cingule of this sort is noted upon the lower molars. The palatal tubercle, the prominence upon the cingule of an upper incisor, may be of exaggerated size. In one case (Fig. 228) this develop-

Fig. 233

Short buccal root of a molar, otherwise properly developed.

Fig. 234

Central incisor with short root.

Fig. 235

Five-rooted upper third molar.

ment gave the appearance of a talon upon the tooth, a distinct cusp segment in itself. Fig. 229 illustrates a marked supplemental cusp upon the buccal surface of a molar. A fusion in this location is not impossible. (See Fourth Molar.)

Malformations of Roots.—Differences in regard to the size, arrangement, form, and number of the roots of teeth are the most common of the dental malformations. The roots of teeth may be abnormally long (Fig. 230) or abnormally short (Figs. 233 and 234).

The roots of cuspids may be bifurcated, particularly in the lower jaw (Fig. 232). A central may have a short supplemental root. (Guilford[1]), or sometimes two distinct roots as in Fig. 236.

Fig. 236

Two-rooted upper right central incisor. (Warren.[2])

The upper first bicuspids may have trifurcated roots, the extra root usually being on the buccal aspect. The upper second bicuspid may be bifurcated; upper molars may have more than three roots, the third molar often having four, five, or six, and in one case reported, eight roots (Figs. 225 and 235). In some cases upper third molars have but one root with a single, large canal, a case of true developmental fusion. In other cases the roots are fused so as to form apparently but one root, while the canal

[1] American System of Dentistry.
[2] Dental Brief, April, 1913.

divisions may exist. This may be fusion or concrescence of roots. Lower molars may have three or four distinct roots, but rarely only one.

Fig. 237

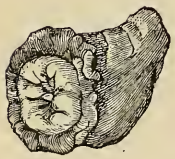

Fibrous odontome. (Garretson, after Pierce.)

Fig. 238

Two-rooted lower cuspid. Resorption of temporary roots. (Skiagraph by E. Ballard Lodge.)

Fig. 239

Results of hernia of a pulp. (Salter.)

Fig. 240

Fig. 239 magnified.

Abnormalities of root form are of extreme frequency, and are probably explained upon the hypothesis of flexion of the root pulp, previous to the deposition of the curved portion of root tissue.

It is impossible to diagnose the forms of roots from the appearance of the crowns, but a skiagraph will determine their form with certainty. It may be said, however, that narrow necks indicate a probable divergence of roots, and *vice versa*.

An excrescence upon the cementum is known as a cemental nodule.

Odontomata.—An odontoma is a growth composed of structures of which the teeth are composed, but the masses may be so arranged as to have no typical form or even resemblance to a tooth. They may appear in the arch or may remain embedded in the jaw, where they may lie quiescent or may excite cyst formation (Fig. 31), or give rise to various morbid reactions, such as tumor formation.

It has been held by Broca that any of the formative organs of the tooth—enamel organ, dentinal papilla, or follicle wall—may undergo aberrant development and may thereafter deposit calcific tissue or not, as the case may be. If not, soft tumors of the jaw, not distinctly dental, may form, though in its complete form such a tumor may become a seat of calcific deposition peculiar to the aberrant tissue.

FIG. 241

Radicular odontome. (Tomes.)

FIG. 242

Odontoma. (Garretson.)

Bland Sutton's classification is usually adopted, and is as follows:

1. Aberrations of the enamel organ: (*a*) Epithelial odontomes. (*b*) Calcified epithelial odontomes.

2. Aberrations of the follicle: (*a*) Follicular cysts. (*b*) Fibrous odontomes. (*c*) Cementomata. (*d*) Compound follicular odontomes.

3. Aberrations of the papilla: (*a*) Radicular odontomes. (*b*) Dentomata. (*c*) Osteodentomata. (*d*) Cementomata.

4. Aberrations of the whole tooth germ (or three formative organs), composite odontomes.

The Uncalcified Odontomata: 1. Epithelial odontomata which arise by aberrant development of the enamel organ, and remaining uncalcified resemble the adenomata.

2. Follicular odontomata: (*a*) The wall of the follicle is distended and the cavity is filled with a thick fluid (sometimes pus if infected), and contains a portion of imperfectly developed tooth. It is in this form really a cyst (Fig. 31). (*b*) The follicle wall or pericementum may thicken so as to form a fibrous capsule about the tooth, sufficiently resistant to prevent its eruption (Fig. 237). This is called a fibrous odontome.

3. Compound follicular odontomata: The follicle wall thickens into a fibrous capsule, and in this may appear fragments of cementum, dentin, or imperfectly formed teeth with their enamel, dentin, and cementum.

Fig. 243

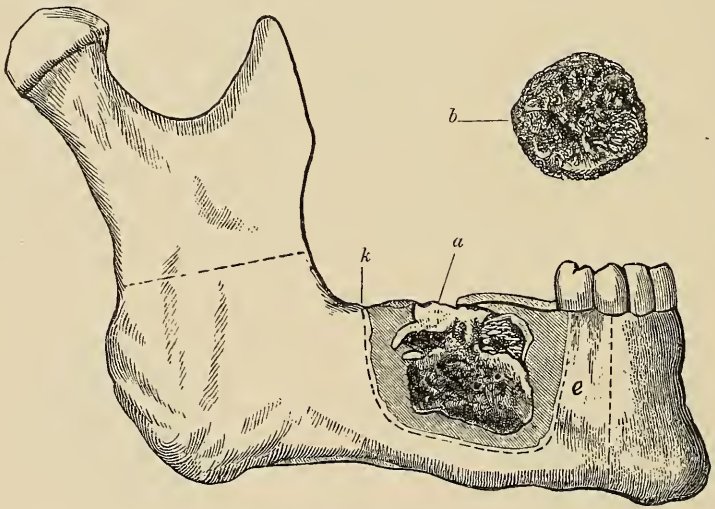

Composite odontome. (Garretson.)

It is a combination of an uncalcified and calcified form, and might easily lead to formation of a cyst containing many teeth or portions of teeth.

The Calcified Odontomata: 1. Epithelial. The enamel organ develops aberrantly into a large, possibly multilocular mass, and enamel deposition occurs.

2. The Cementomata: A fibrous odontome forms from the follicle wall, then calcifies into laminated ossific material. One from a horse, in the Royal Veterinary College, London, weighed seventy ounces. It may include one or more teeth.

3. Radicular Odontomata: The crown may form normally, but the dentinal papilla becomes aberrant and develops largely, conveying with it the follicle wall. Ceasing to enlarge, cementum and dentin

are deposited somewhat in the ordinary manner, but of somewhat aberrant deposition. Pulp hernia comes under this heading and acts similarly (Figs. 239, 240, and 241).

4. Composite Odontomata: The developmental organs, the enamel organ, the papilla, and follicle wall are aberrant, heterogeneously arranged, enlarged, and then deposit a composite mass, which may be somewhat orderly and tooth-like (Fig. 242), or be totally unlike a tooth as in Fig. 244.

The diagnosis of odontoma, if at all obscure may be made by skiagraphy (see Fig. 245).

FIG. 244

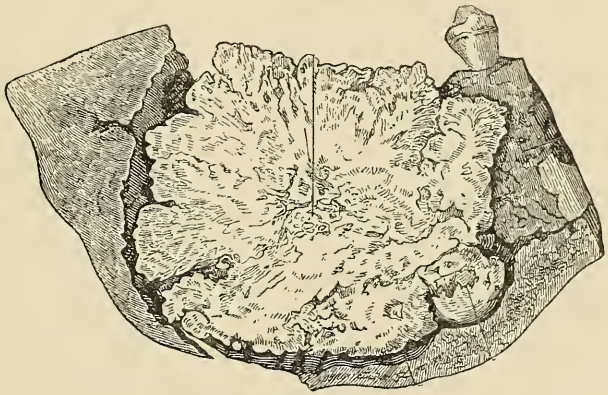

Composite odontome. (Garretson.)

Treatment.—The treatment of odontomata is usually that directed to their sequels, which consist of enlargements about the jaws with more or less inflammation or cyst formation, and, as a rule, involves their removal by surgical operation.

Anomalies of Number.—Although the dental series of man normally consists of thirty-two members, cases are frequently observed in which the number is less than, or in excess of that number, or there is an abnormal number in any particular group of teeth.

Deficiency.—It is observed with some frequency, that the upper lateral incisors never make their appearance, a condition traceable to the influence of heredity in some of the instances. In an interesting case of three sisters, who all were without upper laterals, a son of one of them had them. Unfortunately the history, as to the parents of the sisters, was not certain, as they wore artificial teeth.

When the laterals are absent, the permanent cuspid erupts and occupies the lateral incisor space, and thus sometimes fails to cause resorption of the root of the temporary cuspid, which persists in the

cuspid space (Fig. 153). The lower laterals sometimes, but more rarely, fail to appear; are probably never formed (Fig. 247). The third molar may never appear, or appear as a peg-like tooth.

The cuspid often is impacted but is seldom lacking in formation. Usually when missing it is to be found by skiagraphy.

Fig. 245

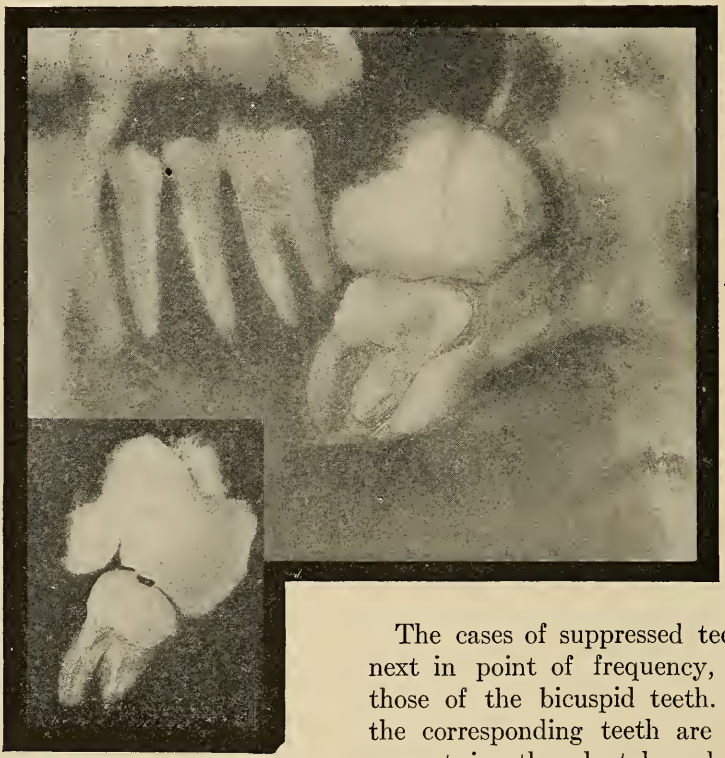

Surgical fracture of mandible, with photograph of odontoma and molar tooth after removal. (Graham.)

The cases of suppressed teeth, next in point of frequency, are those of the bicuspid teeth. If the corresponding teeth are all present in the dental arch, a well-founded suspicion of impaction of the missing tooth may be entertained.

An excessive growth of hair upon the face and body has also been associated, in some cases, with a deficiency in number and alteration in form of the teeth. In other cases no abnormality was noticeable.[1] In some cases the hair and other dermal structures may be normal and the teeth be quite deficient in number.

The extreme of suppressed formation is represented in a case described by Guilford.[2]

[1] Tomes: Dental Surgery.

[2] American System of Dentistry, vol. iii.

A patient over fifty years old had never erupted any teeth, temporary or permanent; the alveolar arches revealed no evidences of

FIG. 246

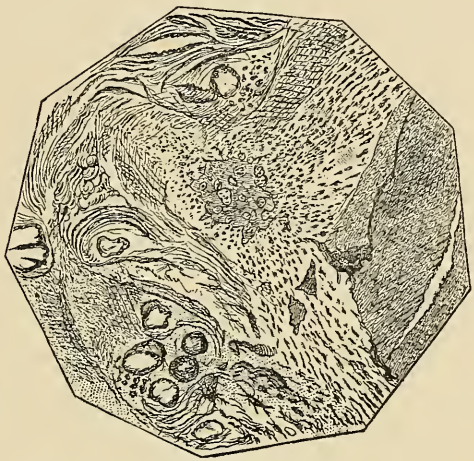

Structure of a composite odontome. (Garretson.)

FIG. 247

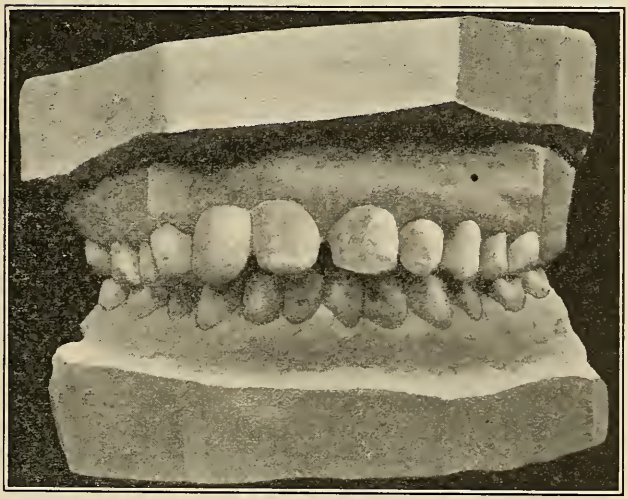

Absence of both upper and lower laterals in the same mouth. Temporary left upper cuspid.

enclosed teeth, but had the appearance of typical edentulous jaws; the alveolar bone itself was but primitive. The case appeared to be

sporadically hereditary, a grandparent and an uncle exhibiting a like condition. The cases are interesting also because of additional evidences of faulty evolution of dermoid structures. In the first case cited, no sudoriparous glands appear to have formed, and there was but a faint growth of hair on the cranium, and none on the face and body. The uncle was hairless and edentulous from birth. Guilford found, in other members of the family, an absence of the full complement of teeth.

In an interesting summary, Kjaer[1] quotes Trueswell as knowing of a man, aged fifty-four years, having had no permanent teeth, but all of his temporary ones, and Fricke as having 3 cases of retention of temporary teeth until sixteen, eighteen, and twenty years respec-

Fig. 248

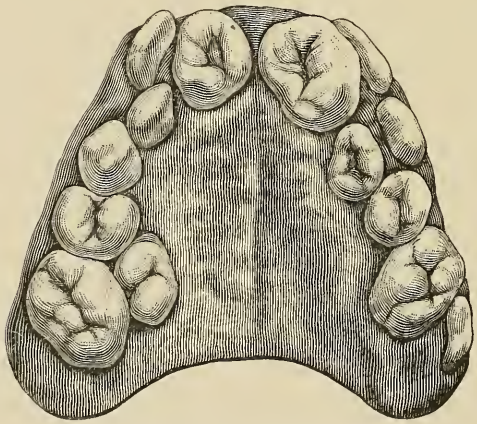

Malposition of molar teeth.

tively, when the permanent teeth appeared, and Linderer as having a case of a lady, aged sixty years, who never had any teeth, and a case of his own in which the temporary teeth were lost from time to time, but no permanent successors appeared, and none could be detected by skiagraphy. He attributed the lack to some disturbance during fetal life, as the family history did not include such a case.

Excess.—The possible occurrence of a condition in some respects the reverse of the preceding, has been much written of and discussed —*i. e.*, the occurrence of a complete third denture. There can be but one conclusion from an examination of all the evidence thus far presented, and that is that no clear and well-authenticated cases are

[1] Dental Cosmos, 1907.

made out. Isolated cases of the appearance of teeth subsequent to the loss of all of the second denture are not infrequent; and, so far as clear records can be obtained, are resolvable into cases of the eruption of supernumerary or impacted teeth, though sometimes a number of teeth are reported erupted. While these cases are, at least for the present, to be held as unproved in connection with elderly persons, a well-authenticated case of multiple dentition in a child is recorded by Catching.[1] Between the sixth and seventh month the eruption of one set of teeth was complete; within three months all of these had been lost. Between the eleventh and fifteenth months another period of dentition occurred, the teeth of this second denture being of such faulty structure as to crumble away quickly. At the age of two and one-half years a third dentition appeared, which caused the child such inconvenience that the teeth were extracted by the mother. At the age of eleven years a fourth series erupted, incomplete through the absence of six teeth. At the age of fifteen years these teeth were sound and firm.

The Fourth Molar.—Very rarely a fully developed fourth molar appears in the maxilla. In one case it was impossible to distinguish the normal. The third and fourth lay in lingual and buccal relation. Less rarely, a less typical molar appears posterior to the third molar. This must be very rare in lower molars. A third type of supernumerary appears in the maxilla. These are rudimentary, and appear upon the buccal side, opposite the approximation of the first and second molars or of the second and third molars, or to the distal or distolingual of the third molars. Bolk[2] calls the buccal supernumerary the "paramolars," and says they are small, two-cusped, single rooted, and, if fused, usually unite with the mesiobuccal portion of the tooth posterior to it during development. Here it forms a supplemental section, "paramolar tubercle" (Fig. 229), which may have a distinct "paramolar root" or root indication. Bolk accounts for the less frequent appearance of an anterior independent paramolar (opposite the approximation of the first and second molars) upon the supposition of a more frequent fusion with the second molar, and he has found twice as many "paramolar tubercles" in the second molar as in the third. The supernumerary posterior of the third molar he terms the "distomolar," and finds that when fused, it unites with the distolingual section of the third molar. He has noted a rare case having both a paramolar and distomolar. He also has not observed independent paramolars in the mandible, bnt the para-

[1] Southern Dental Journal, October, 1886.

[2] For the many beautiful illustrations enforcing this new conception the reader is referred to the article in Dental Cosmos, February, 1914.

molar tubercle may occur on the second or third molars, which may have a proper "paramolar root." The distomolar in the mandible fuses with the distolingual portion of the third lower molar. He calls attention to the fact that in the maxilla, the paramolar appears most often as a supernumerary tubercle, while in the mandible it is emphasized by a supernumerary root.

Supernumerary Teeth.—Any teeth in excess of the normal number of teeth belonging to any one class are included in the category of supernumerary teeth. The number of teeth may possibly not exceed thirty-two. Supernumerary teeth appear as simple unmodified cones, or as combinations of cones resembling the forms of teeth. The conical form is most common. Cases where these peg-like teeth appear around the third molars, singly or in number, are numerous. Their appearance in any situation is evidence that the normal number of dental cords has been exceeded.

Fig. 249

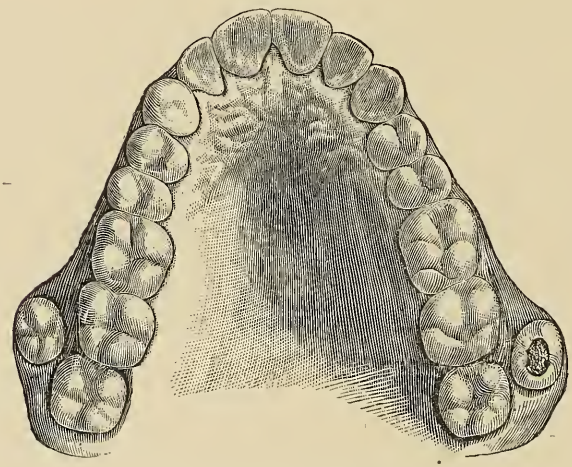

The fourth molar (Hartman.)

Guilford[1] divides supernumerary teeth into those having typical anatomical forms and those having atypical forms.

Supernumerary incisors having typical forms appear in either jaw. In the upper jaw, supernumerary centrals and laterals both appear, the latter more frequently (Fig. 220). Supernumerary teeth may occupy any position relative to the dental arch, but are more frequently seen at its lingual side. The compound cone occasionally

[1] American System of Dentistry, vol. iii.

appears (Fig. 251). In addition to molars and incisors, supernumerary bicuspids are occasionally found (Fig. 232); supernumerary

Fig. 250

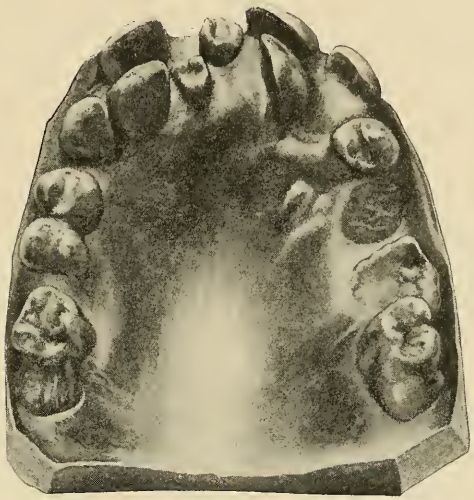

Two atypical upper supernumerary teeth displacing the incisors.

cuspids are very rare, but sometimes a brood of them exists, as many as seventeen fairly defined small teeth having been removed from a cyst in the location of the cuspid tooth.[1]

Unless supernumerary teeth are a source of offence, either through their position or appearance, they need not be disturbed. If they are found to be so, they should be extracted.

Fig. 251

The compound cone.

Malpositions of the Teeth.—A tooth is said to be in malposition when it is not in normal relation with the dental arch to which it belongs and to its antagonizing teeth of the opposing arch. Teeth are found in abnormal positions as the result of a variety of causes. Some of these operate prior to, during, or immediately after eruption; some long after the eruption of the teeth, and some because of non-eruption of teeth. (See p. 220, etc.)

Malpositions which are remediable through the application of mechanical force, applied by means of suitable apparatus, belong to operative dentistry, as has been stated. They are fully treated of in works upon operative dentistry[2] and orthodontia.[3]

[1] D. M. Clapp: International Dental Journal, 1900.
[2] American Test-book of Operative Dentistry. [3] Guilford, Angle, and others.

The extraction of teeth after they have been erupted, or of their predecessors, is one of the most frequent causes of acquired mal-

FIG. 252

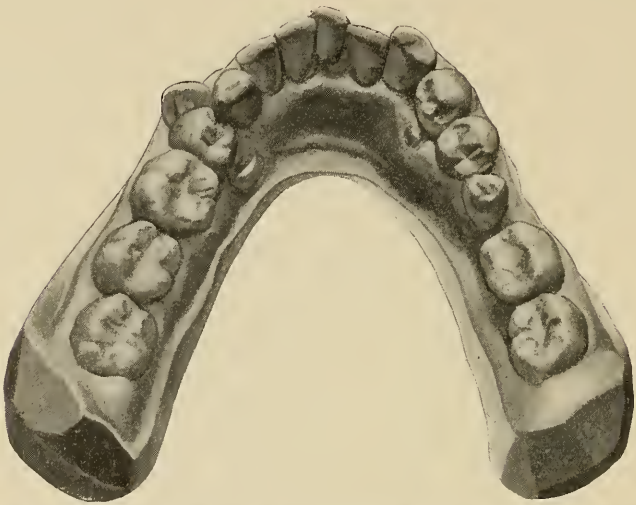

Case of seven lower bicuspids, two supernumeraries in place and one erupting. This patient has two supernumerary upper central incisors displacing the centrals proper, yet closely resembling them.

position of the remaining teeth. The teeth move from their original positions, the anterior teeth, incisors, laterals, cuspids, and occasionally the bicuspids, having a tendency to drift posteriorly, sometimes opening a space between the central incisors, sufficiently large to create a deformity. The molars have a decided natural tendency to drift forward, and when the bicuspids are removed they tip anteriorly, causing malocclusion upon their distal cusps and sometimes their distobuccal cusps alone, with a further tendency to tip forward and sometimes inward as well. Separation of the posterior teeth may occur, and in any event, the loss of mesial or distal support permits fibrous food to be packed between the teeth; as they spring slightly apart, it is held by their springing together again. The lack of occlusion brought about by extraction of antagonists permits elongation, and the loss of posterior support is apt to bring about labial protrusion or abrasion of upper anterior teeth. This effect is produced in youth

FIG. 253

Effects of premature loss of permanent first molars.

when the first molars are lost before the bicuspids are in place (Fig. 253). The first molars are the keystones of the arches, and determine the extent of the formative process which shall occur in the alveolar bone posterior to them. They are also the teeth which, correctly placed or out of position, determine largely the occlusion of the teeth.[1]

If a temporary tooth be long retained, it is sometimes raised to the occlusal level of the other teeth; again, it is sometimes left at its original level and occasionally imprisoned between other teeth. The *x*-rays should be used to determine the presence or absence of the permanent tooth germ or resorption of the temporary roots.

If teeth erupt in malposition, it is held to be wise to correct as early as possible, in order to prevent further malposition of other teeth.

Fig. 248 illustrates a case of malposition of molar germs which have developed in the incisal region, displacing the incisors.

Impacted and Encysted Teeth.—The extreme extent of dental malposition is reached when the permanent teeth do not erupt at all. Instead of presenting in the dental arch, they may be entirely embedded in the substance of the bone, either remaining there, with or without pathological manifestations, or erupting in some unusual situation. In other cases, a distinct cystic tumor forms about the enclosed tooth (Fig. 31). The cause of impaction probably lies either in a previous malposition of other teeth preventing advance, or in an originally malposed tooth germ, or to the development of the root while the crown advance is retarded, the expulsive force of root formation being lost. In many cases orthodontic procedures creating room may permit the descent of the tooth.

Impacted Lower Third Molars.—By far the most common dental impaction is that of the lower third molar. The extent of impaction varies from a partial eruption, or partial imprisonment of the tooth by its bony surroundings, to its entire imprisonment in any part of the ramus. Many of the more severe cases treated under the head of pathological dentition, if unrelieved, would be included in the category of impacted teeth.

In Fig. 254 is shown a lower third molar presenting the effects of a previous impaction. The irritation caused by the efforts of the tooth to disengage itself, or to overcome the resistance to its eruption, has caused an active formative reaction in the pericementum, resulting in an hypertrophy of the cementum. Likewise the pressure upon the bone causes a condensing osteitis, and the bone becomes dense, more obstructive, and less vascular (see p. 144).

[1] Angle.

If the distance between the posterior surface of the second molar and the columns of the coronoid process be very short, it is evident

FIG. 254

Right half of lower jaw, showing an impacted third molar. (Cryer.)

FIG. 255

Inner side of left half of same lower jaw. (Cryer.)

that upward eruption is impossible, so that the tooth may assume any direction of movement, the most common being forward, the

axis of the tooth changing its position until the tooth may lie in a horizontal position or even become inverted.

Fig. 256

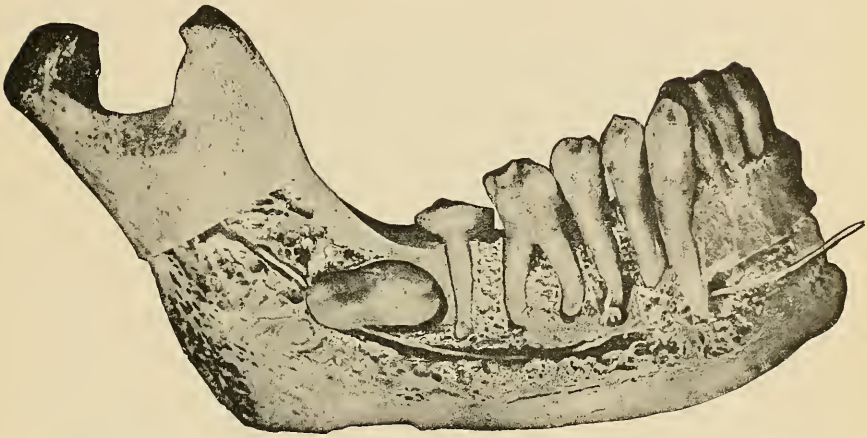

Impaction of lower third molar. Resportion of root of second molar and impingement of root upon inferior dental canal, which is deflected out of its course. (Cryer.)

Fig. 255 is taken from the same jaw as Fig. 254, but shows the opposite side; the impaction is pronounced. Fig. 256 shows another case with different anatomical surroundings. In the first case there were evidences, both in the tooth, in its bony surroundings, and in the external cortical bone, of the results of the irritation produced by the efforts at eruption. The cementum was thickened; the outer follicular wall, the tissue designed to form the alveolar periosteum,

Fig. 257

Impacted lower third molar beneath gum. Second molar tipped forward. (Skiagraph by E. Ballard Lodge.)

Fig. 258

Impacted cuspid. (Skiagraph by E. Ballard Lodge.)

had exercised its formative osteogenetic function, and a capsule of bone had formed about the tooth; it lay in a bony chamber. The

pressure exerted upon the distal wall of the second molar had resulted in a pressure resorption of its root until the pulp chamber was

FIG. 259

Impacted bicuspid. (Skiagraph by E. Ballard Lodge.)

encroached upon. These were both postmortem cases, and no records of their clinical histories were obtainable. The symptoms produced

FIG. 260

Same as shown in Fig. 234, with tooth removed. (Cryer.)

could only be surmised by the nature of the anatomical relations and the pathological evidences. There may have been a prolonged

but mild periostitis, probably a continued pulp irritation; and in the last, neuralgia of any grade of severity. The pressure upon nerves

Fig. 261

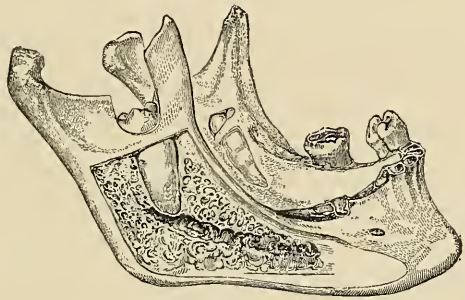

Wisdom teeth embedded in the rami of the lower jaw. (Tomes.)

of the inferior dental canal would account for neuralgia or mental or other disturbance.

Cryer calls attention to the fact that a third lower molar in its attempt to erupt, frequently causes a cellulitis, extending into the temporomandibular joint, causing acute ankylosis.[1]

Fig. 262

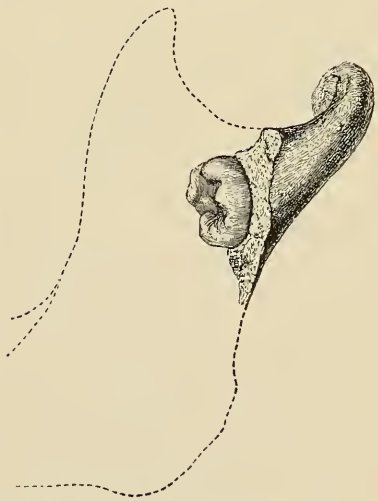

Wisdom tooth buried in the ramus. (Tomes, after Marshall.)

Judging from postmortem records and recent skiagraphy, cases of impacted third molars are more common than generally believed. Instead of remaining in the alveolar portion of the bone, the impacted tooth may come to occupy a cavity in some portion of the body or the ramus of the bone (Figs. 261 to 264). The positions of the teeth in such cases tend to confirm Tomes' theory of the development of the jaw. The jaw being lengthened, and the ramus developing through conjoined deposition and resorption of bone, the crown of the tooth appears to be either fixed in a bony nucleus and transported to some distant point in the developmental progress of the jaw, or to be irregularly shifted about during jaw growth. At later

[1] Dental Cosmos, October, 1911.

periods, the pressure exercised by root formation disturbs the relations of the tooth with its earlier surroundings. These efforts at eruption may, at late periods, cause the appearance of the tooth in odd situations. In the case shown in Fig. 263 the crown of the tooth made its way through the angle of the bone and through the muscles and skin. The opening in the skin healed upon extraction of the tooth.

Impacted Upper Third Molars.—Some phases of impaction of this tooth have been spoken of under the head of Pathological Dentition. The most common is imprisonment of the tooth and its subsequent partial eruption in a horizontal position, the crown pointing toward the cheek (Fig. 173). The crown of this tooth may, in rare cases, be directed inward or backward, in the latter case being arrested by the pterygoid plates of the sphenoid bone. It may present with an anterobuccal facing of the crown, as shown in Fig. 264, or with a posterobuccal facing.

FIG. 263

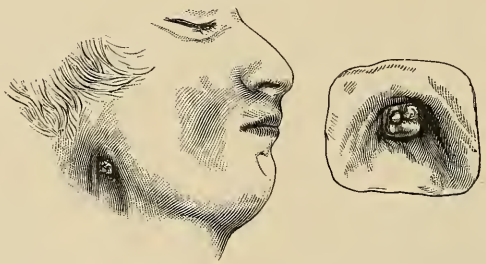

From a wax model in the museum of the London Odontological Society. (Tomes.)

In a case recorded by Tomes (Fig. 265) the extraction of the second molar revealed the third molar in a reversed position, its roots occupying the depression between the roots of the second molar. A case has been reported, of an upper molar with the roots partly embedded in the floor of the antrum, its neck carious,[1] and the antrum in a state of suppuration.

Impacted Cuspids.—In point of frequency of impaction the upper cuspids stand next to the lower third molars. The upper cuspids lie high up; the floors of their crypts, in which they lie *loosely*, are at a higher level than those of the adjoining teeth; their crowns, as with the other anterior teeth, lie lingual to the roots of their predecessors. All of these are elements which might cause displacement of the developing cuspids. Should the advance of eruption not keep pace with the development of the alveolar bone, imprisonment is likely;

[1] Possibly resorbed or decalcified instead of carious. (Editor.)

again, the dense bone immediately about the first bicuspid and lateral incisor may offer a deflecting resistance. Examining the texture of the bone about these parts, it is evident that the direction of least resistance to the advance of a much deflected crown is into the cancellated

Fig. 264

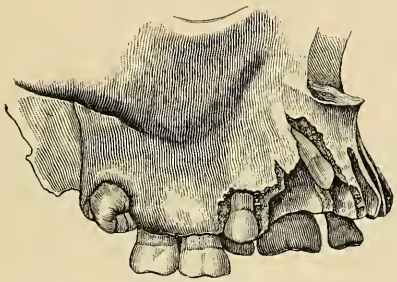

Upper jaw, with the third molar directed forward and impinging upon the second molar. The small tooth situated high up in the anterior part of the jaw was forced there by the spade of the grave-digger. The artist's accuracy in delineating all parts of the specimen has rendered this explanation necessary. (Tomes.)

Fig. 265

A second molar of the upper jaw, with the wisdom tooth inverted and embraced within the roots. (Tomes.)

bone of the incisor portion of the alveolar process; hence it is most usual to find the crowns of these teeth lying with their cusps pointing forward (Fig. 266). Several recorded cases have the posi-

Fig. 266

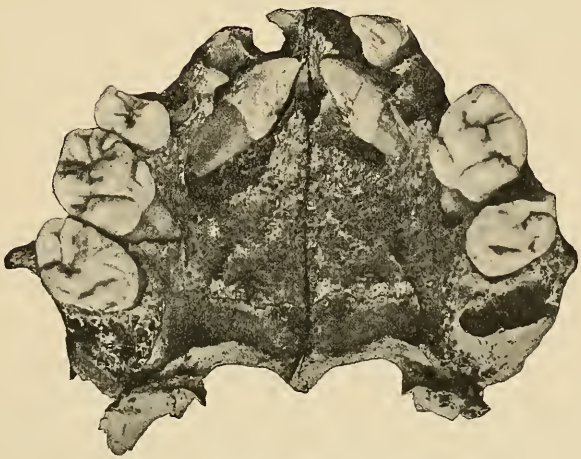

Abnormal jaw, showing impacted cuspids. (Cryer.)

tions shown; one or both of the teeth may be impacted. Cuspid teeth may erupt into the nasal cavity or appear in the canine fossa, and pre-

sent the crowns cheekwise, or lie horizontally and above the roots of the bicuspids.

Fig. 267

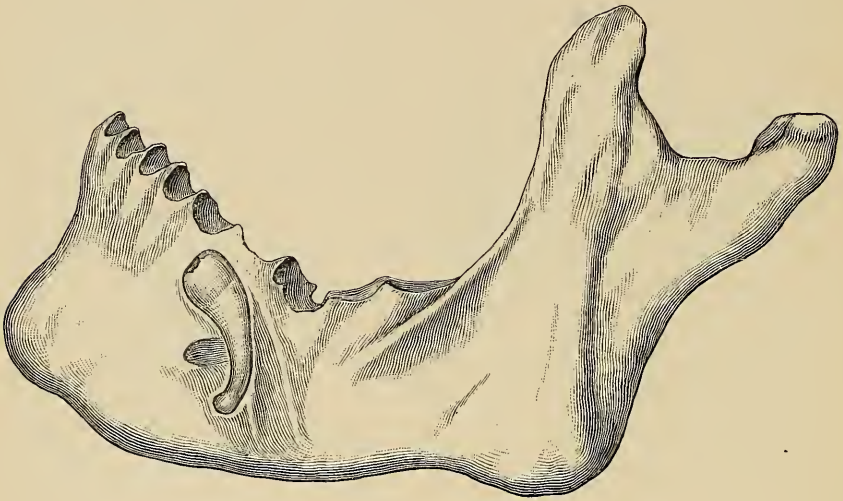

Impacted bicuspid. (Salter.)

Glas, of Vienna, discovered a cuspid in the nasal floor associated with calcic formations in its ulcerated surface (rhinolith). The patient, aged nineteen years, had frequent fetid eructations, with vomiting of green, foul-smelling masses. With the removal of the cuspid the vomiting, etc., ceased.

Fig. 268

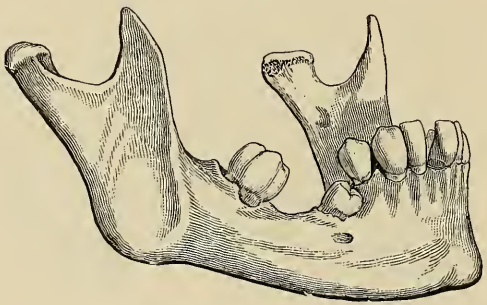

Lower maxilla, in which the right second bicuspid is placed obliquely, the root being directed backward. The crown, though exposed, does not rise above the level of the alveolar margin. (Tomes.)

Impaction of Other Teeth.—While impactions are most common in connection with the teeth named, any other teeth of a denture may

be imprisoned. Fig. 267 shows an impacted bicuspid whose root development has been normal as regards its length, but whose curve

Fig. 269

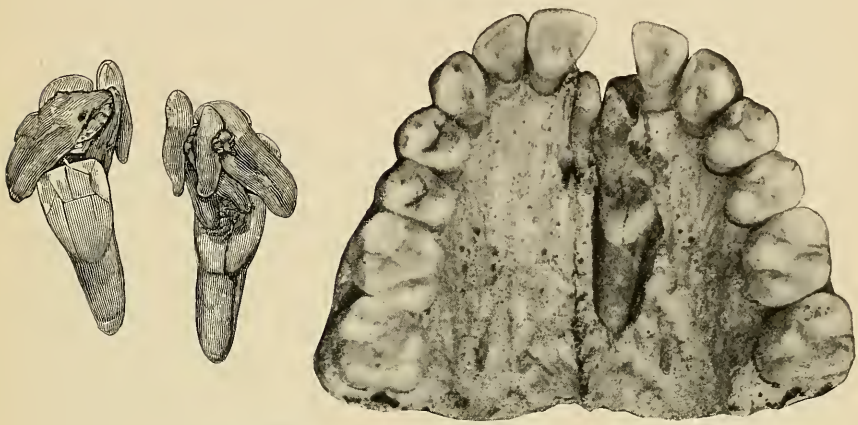

Imprisoned central incisor. (Kirk and Cryer.)

has been modified by the resistance of surrounding tissues. Fig. 269 exhibits an imprisoned central incisor, whose retention was, no doubt, determined and malposition caused by the development and presence of the brood of supernumerary teeth which surrounded its crown.

Fig. 270

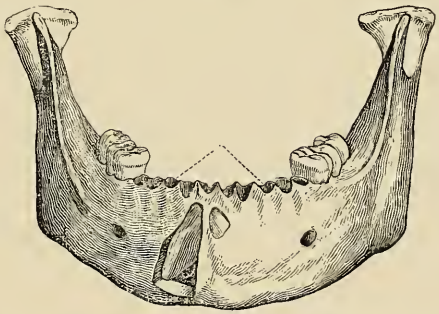

Maxilla, in which the temporary cuspids (the sockets of which are shown by the dotted lines) were retained, and the permanent canines developed within the substance of the jaw. The bone has been removed on the one side to show the direction taken by the tooth, which has been twisted on its axis to the extent of a quarter of a turn. (Tomes.)

Upper incisor teeth have been seen inverted and their crowns erupted into the nasal cavity, where they have produced inflammation,

which later became infective.[1] A supernumerary tooth has been found in the floor of the nasal cavity[2] so that presence of all normal teeth should not exclude extra teeth from consideration in making a diagnosis. Skiagraphy may demonstrate an unsuspected supernumerary.

Impacted teeth do not necessarily produce such pathological conditions as produce untoward symptoms. The malposition of the impacted teeth either in total or partial impaction may, however, lead to malposition of other teeth, or results such as caries. The relation of impacted teeth and any ulterior disease condition is settled by the facts, the probabilities of relation, or the results of their removal.

FIG. 271

Impacted teeth removed by surgical operation. (Cryer.)

Symptoms.—The most common symptom attendant upon impaction of teeth, judging from the obtainable records of cases, is trifacial neuralgia of any degree, caused by impingement of the malposed tooth upon nerve filaments or trunks. Cryer[3] records a case where a supramaxillary neuralgia was traced to the presence of a central and lateral incisor, and a cuspid tooth in the anterior wall of the antrum; they were only discovered by an exploratory operation. A cure of the neuralgia was effected by their removal.

Impacted third molars frequently give rise to heavy rheumatic pains about the side of the face and jaws, and no doubt in such cases as depicted in Fig. 256 would cause intractable and diffuse maxillary neuralgia. Salter[4] records a case of long standing and intractable neuralgia, exhibiting a constant painful area upon the scalp, and in which heat and tenderness were noticed over a swelling upon the hard palate. Immediate and permanent cessation of the neuralgia followed removal of the teeth.

Dr. N. T. Shields[5] describes a case of great pain in the region of the mental foramen, accompanied by a later appearance of fever, reaching 103.8°, with subsequent enlargement of the submaxillary gland, as cured by the surgical removal of the two impacted bicuspids and deciduous tooth shown in Fig. 272.

Symptoms of maxillary periostitis—heavy, gnawing, and dull, throbbing pain, with more or less heat and engorgement of tissues—are noted as an accompaniment of impacted teeth. Such symptoms

[1] Jameson: International Dental Journal, 1899.
[2] Boral: See Cosmos, December, 1911.
[3] Dental Cosmos, 1896.
[4] Dental Pathology and Surgery.
[5] Dental Cosmos, 1908.

may herald the appearance of the tip of the tooth through its bony covering and gum.

Cases of maxillary abscess, in the absence of their usual cause (gangrenous pulp), may run a prolonged and painful course,[1] involving neighboring structures, which may be vital, and after free venting be found to have arisen about an impacted tooth. The probable

FIG. 272

Skiagraph showing impacted teeth. (Shields.)

explanation for many cases is the partial absorption of the overlying tissues, permitting ingress of bacteria, but in some cases crown resorption may cause irritation, and bacteria in the blood may localize. A few cases of pulp exposure have been seen when a sinus allowed ingress of bacteria and the production of caries. In such

[1] See Garretson's Oral Surgery and Salter's Dental Pathology.

case a pulp may die, undergo putresence, and cause apical abscess with its symptoms.

Occasionally a circumscribed swelling is noted upon some aspect of a jaw, most frequently upon the palatal portion of the superior maxilla, which is attended by inflammatory symptoms, and an incision reveals an impacted tooth. If a plate has been worn, the tissue between, and even the bone may become necrotic.

Fig. 273



X-ray photograph, showing malposed cuspid entirely embedded in the bone and pressing upon the central.

Fig. 274

Impacted cuspid revealed by resorption of the overlying tissues. (Burchard.)

Quickly forming cysts of the jaw, upon receiving surgical treatment, may be found to contain the crown of an entire tooth, this evidently being the centre of irritation from which the cystic formation had its origin. Melancholia, mania, and dementia precox have been relieved by the extraction of impacted teeth diagnosticated by skiagraphy.[1] This shows a relation between cause and effect (Figs. 275, 276, 277). M. C. Smith[2] reports a case of lifelong attacks of prostrating sick headache due to impaction of a third lower molar and relieved by its extraction.

The pulps of other teeth have been devitalized by the strangulation due to the pressure of the crown of the impacted tooth upon the apical tissue, and the production of pulp nodules in other teeth through a reflex hyperemia has been noted. The resorption of roots of other teeth has been produced by the pressure of the impacted tooth.

Hypercementosis and concrescence have also been produced by the descent of the tooth and have produced impaction.

[1] Upson: Dental Cosmos, 1910, p. 527.
[2] Dental Brief, 1912.

Resorption of the roots of the impacted teeth, or resorption of the enamel and dentin of the crown may occur. In one case, a calculus in nowise associated with the oral cavity, and divided from it by an area of pericemental tissue was found. (See Resorption of Enamel, for illustration.)

In all these cases diagnostic features exist, though none are comparable to the *x*-rays.

Diagnosis.—The first point of observance in cases of suspected tooth impaction or of obscure supernumerary teeth is an examination of the dental arches. Are all of the permanent teeth in position? Given the absence of, for example, a lower third molar from the dental arch, with a history of no eruption, and a persistent neuralgia, particularly if occasionally accompanied by or alternated with heavy rheumatic, or what are known as bone pains, and finding no other evident cause of the neuralgia, an impacted tooth would be naturally inferred to be the source of the disturbance. Impacted teeth which lie horizontally, or nearly so, along the palatal vault frequently cause a swelling. This, taken in conjunction with the absence of a tooth from the dental arch, points to a diagnosis of impaction.

In very many cases of impaction, diagnosis has been a mere accident; discovery being made in the course of an exploratory surgical operation. In other cases dental disturbance has been simply an inference, until skiagraphy has determined an impacted tooth or some other lesion to be present. B. H. Catching[1] was the first to practically apply this diagnostic test in this connection. The left upper central incisor of a female, aged nineteen years, became loosened, and an exploration through its pulp chamber revealed a hard body occupying a position part way up the root, which had undergone resorption to that point. The cuspid of the left side was absent from the arch. A skiagraph of the parts (Fig. 273) revealed the missing cuspid, whose crown had impinged upon and caused resorption of the central incisor.

Impacted teeth may become uncovered at some aspect late in life, and the condition be discovered incidentally. Cases are recorded where the pressure of a plate has caused the resorption of tissues overlying an impacted tooth, thus revealing its presence. Fig. 274 illustrates a case where the presence of an impacted cuspid was revealed at the age of seventy years, through resorption of the alveolar bone and the gum tissue covering the tooth.

As the smooth feel of enamel is a diagnostic feature when instru-

[1] Catching's Compend, 1896.

mental examination is made, it is to be remembered that the enamel and dentin of an impacted tooth may undergo a true resorption with the characteristic Howship's lacunæ. When partly exposed to the oral fluid, caries may occur. Both these conditions produce rough surfaces, but enamel may usually be felt at some point.

Fig. 275



Impacted lower third molar; cause of neuralgia. (Skiagraph by Lodge.)

Fig. 276



Cuspid tooth, unsuspected by patient; demonstrated to have been responsible for severe neuralgias. Patient, a draughtsman, had not been able to work at his business for the six months previous. The tooth was not known to be present, until revealed by *x*-rays. It was removed from the lingual side. (Skiagraph by Lodge.)

Fig. 277

Impaction of upper third molar, without local pain, cause of profound delusions and melancholia. (Upson.[1])

Treatment.—The treatment of cases of impaction is the removal of the offending tooth. Whether or not this comes within the province of the dental operator depends upon the position of the tooth, and, incidentally, upon the usual range of practice of that particular practitioner. When the tooth is embedded deeply in the substance of the jaw, access to it involves the anesthetization of the patient,

[1] Insanity Caused by Painless Dental Disease, Dental Cosmos, 1910.

and the removal of the bone which obstructs the path of extraction; this may be an operation of some magnitude, and is usually done by a special surgical practitioner. When, however, it is evident that the obstructions to the removal of the tooth consist of the soft tissues and but a lamina of bone, the operation for removal is clearly within the province of the dental operator. For example, the presence of an impacted cuspid is determined, lying horizontally along the lateral aspect of the roof of the mouth. The parts may be injected with a local anesthetic solution, and a cut made with a sharp bistoury through the soft tissues from the outside of the swelling, to the bone. The flap thus outlined is raised from the bone, the flap including the periosteum. A large, sharp bur is then employed to remove the covering bone. When the tooth is freely exposed it may be dislodged with forceps or elevator. The parts are then washed with a hydrogen-dioxid solution, dried, the flap pressed back into place, and steresol[1] painted over the parts, or a stitch or two may be taken before application of the steresol. The mouth should of course be kept as aseptic as possible both before and after operation. A simple clot kept aseptic may be sufficient.

℞—Purified gum lac.	ʒix
Purified gum benzoin	ʒ ⅓
Balsam of tolu	ʒ ⅓
Oil of cinnamon (Chinese)	ʒ ⅕
Carbolic acid	ʒiij
Saccharin	ʒ ⅕
Alcohol	Oij—M.

[1] Dental Cosmos, 1895.

SECTION III.

AFFECTIONS OF THE ENAMEL AND DENTIN.

CHAPTER IX.

ABRASION, EROSION, AND MECHANICAL INJURY.

Formed by the ameloblasts, which are later changed into Nasmyth's membrane, and borne upward with the crown during the process of eruption, enamel has no posteruptive source of nutritive supply from without.

Its only conjectural source of nutrition is, therefore, from the pulp *via* the dentinal tubuli. This seems to have been proved by Caush, and later by others. (See p. 173.) Teeth do change in color with advancing age, generally becoming yellower; this is probably due to tubular calcification (which see), rendered possible by the tubes containing organic matter which are now supposed to permit a slow interchange of nutritive sap.[1] This coloration may be seen in cases of abrasion and in some cases extends even into the secondary dentin associated. The editor has a patient with a vital tooth of mahogany brown color, which she claims changes the depth of color. Changes in the color of the dentin may be transmitted through enamel, which is normally almost or even quite transparent. Such a transparency may be seen at the incisal edges of thin incisors before these edges are worn down. Another proof of transmission of color through enamel is seen in caries; a bluish-black or white appearance is caused by the decayed mass or decalcified inner surface of the enamel.

Again, amalgam or gold, oxyphosphate or oxychlorid, reflects its color through enamel, and, in excavating, the shadow of the excavator may be seen through thin walls. Enamel may be stained or whitened by decalcification due to causes acting externally. Extreme polishing

[1] C. Francis Boedecker: Dental Cosmos, September, 1911.

may also cause a new character of light reflection, simulating a change in color. Talbot claims a change in color of teeth during prolonged illness, such as pneumonia, typhoid fever, syphilis, tuberculosis, and in pregnancy.[1] With advancing age, the translucency of teeth verges more toward transparency—apparently a sclerotic change in the dentin. (See Transparency.)

After implantation, a tooth may somewhat change its color, but this evidently cannot be due to nutrition from the pulp, as this organ will have been removed before implantation. It would seem that it may take up coloring matter from the saliva.

Enamel may suffer mechanical and chemical injury, but whether it may undergo constructive changes or retrograde metamorphosis is at present only conjectural. There is, however, a possibility that a molecular change may occur as a result of slow interchange of fluid, environment, or impact of mastication.

The dentin and cementum contain about 28 and 30 per cent. of organic matter, respectively, and stain deeply and permanently with great readiness.

Possessed of living cells, they also undergo changes in their structure under the influence of various stimuli, their substance being added to or reduced according to circumstances. They are also acted upon by mechanical and chemical agencies, if exposed to their influence.

ABRASION.

Abrasion is the mechanical wearing away of tooth substance.

Occurrence.—It occurs most commonly upon the occlusal surfaces of teeth, but is also found upon the approximal and labial surfaces, the labial cervix, and more rarely upon the lingual surfaces. It is also seen in the temporary denture, especially in the molars, and is found in animals (Figs. 288 and 289).

Appearance.—Purely abraded surfaces present a smooth, flat, or concaved, highly polished appearance. The surface may become stained or otherwise altered in color, or subsequent caries may remove its smooth surface.

Occlusal Abrasion.—Occlusal wear is very common, and occurs largely with men who chew tobacco; the contained silex, being gritty, acts as an abrasive. Such wear, due to the use of hard food or gritty substances, is seen in skulls of aboriginal man. Ottofy describes a peculiar form of wasting due to chewing betel nut mixed with bay leaves and slaked lime. No doubt a gritty element is introduced.

[1] Dental Cosmos, 1905, p. 29.

Some degree of occlusal wear is accepted as normal to all teeth, the act of mastication producing marks or facets at the point of articulation of antagonizing teeth. A tip-to-tip variety of occlusion permits free lateral movement of the lower jaw, and a herbivorous type of articulation causing abrasion. It is also frequent in those cases presenting the first degree of prognathism. In some of these cases, the labial surfaces of the upper incisors and cuspids, and the linguo-incisal margins of the lower incisors are worn. A single overlapped lower tooth may abrade an upper tooth in this manner.

The gritting of teeth is also a cause. This gritting, termed "bruxomania," may occur only at night or for a few minutes each day; again it may appear for entire days, weeks, and months, not ceasing even during sleep. In such cases the teeth are worn down flat. Maria and Pietkiewicz[1] noted 12 cases of central nervous lesions, mostly dementia, developing bruxomania; also it has been noted in cases of epilepsy and chorea.

A clay pipestem may wear a hole of its own diameter in the incisal edges of anterior teeth; other stems wear less. Upholsterers and seamstresses have peculiar abrasions (tack holding, thread biting).

FIG. 278

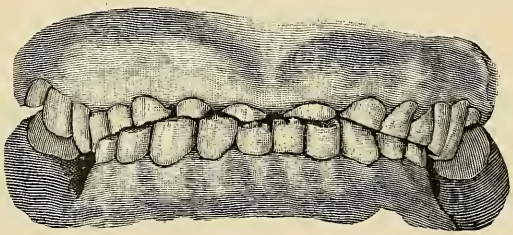

Abrasion of anterior teeth, with loss of posterior occlusion. (W. A. Capon.)

The undue loss of posterior occlusion and consequent overuse of the anterior teeth cause their abrasion after the manner shown in Fig. 278. A marked overbite, produced in any manner, may cause lingual abrasion of upper anterior teeth.

Where the abrasion occurs in a fairly regular manner, four degrees of abrasion are classified: (1) Abrasion removing the cusps; (2) abrasion removing the occlusal third of the crown; (3) abrasion removing the middle third of the crown; (4) abrasion extending to the gum line or beyond. (Broca.) (See Figs. 279 and 280.)

When there is a marked overbite occlusion, with a consequent lessening of the lateral movement of the mandible, the teeth do

[1] Dental Cosmos, 1907, p. 525.

not acquire flattened contact surfaces, but their cusps increase in sharpness and pointedness. This at times becomes exaggerated, and produces an interlocking of cusps or rather worn surfaces which have very sharp edges.

FIG. 279

The first and second degrees of abrasion. Specimens from museum of Philadelphia Dental College.

FIG. 280

The third and fourth degrees of abrasion. Secondary dentin plainly visible. Specimens from museum of Philadelphia Dental College.

In the first degree of abrasion, the dentin is often hollowed out in advance of the enamel of the cusps, forming concave places in which

berry seeds lodge and cause annoyance. These spots are at times hypersensitive. The plane surfaces also are often sensitive upon merely rubbing the teeth together.

Labial and Approximal Abrasions.—Some forms of abrasion have been attributed to too vigorous use of tooth-brushes, particularly when gritty powders are employed. There is no doubt that mechanical abrasion about the necks of teeth is produced in this manner, the gum line receding beyond the enamel border, exposing the cementum; and a careful examination will reveal the cementum and next the underlying dentin to be affected; the enamel, when abraded, shows first as a facet, then as a spot of bare dentin with thin edges of enamel around it (see the left lateral in Fig. 299), and later the area may be grooved. As a rule, however, the effect shown in Fig. 298, lower jaw, is the more common. These tooth-brush abrasions are quite

Fig. 281

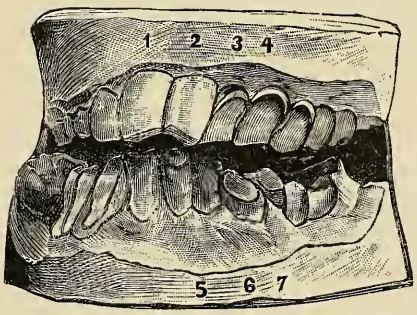

Abrasion due to employment for twenty years of a gritty English tooth paste. At 7, gold crown abraded. (Miller.)

characteristic. In well-kept dentures, the gums are seen to have receded from their normal line, but may exhibit little evidences of turgescence; the roots of the teeth, upper and lower, are exposed to a greater or less extent along their labial and buccal, but not usually along their lingual aspects; and they are excavated to variable depths, upon the bicuspids and first molars more than upon the other teeth, as here the greatest force of brushing is received. The depressions have a normal dentin color, sometimes deepened in the mouths of non-smokers, and which in smokers may be periodically blackened by deposits of carbon. If caries supervene, the abraded areas lose their normal color, and may be readily indented by sharp instruments, which they resist before the advent of caries. The bicuspids and molars, particularly, may be grooved in such manner as to require restoration by fillings.

FIG. 282

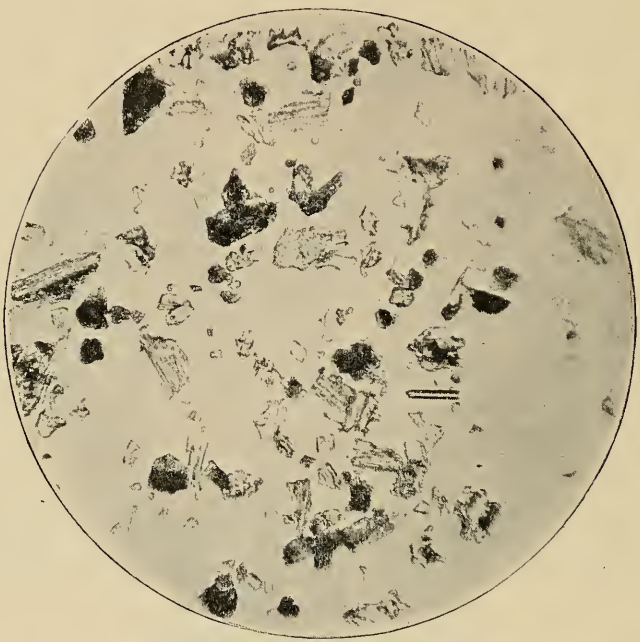

Photomicrograph of sediment obtained by washing tooth paste, which caused the abrasion shown in Fig. 281. (Miller.)

FIG. 283

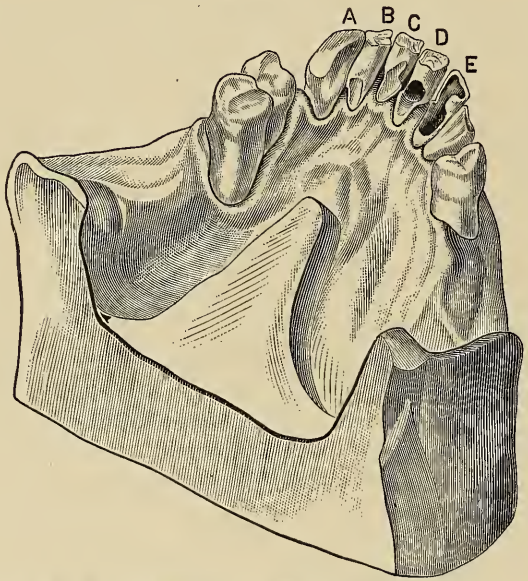

Abrasion of lingual surface by assiduous brushing with tooth powder. At *D* and *E* amalgam worn down. (Miller.)

Miller[1] investigated this subject very carefully, and found that the grit in many forms of tooth powder, vigorously used, was quite

Fig. 284

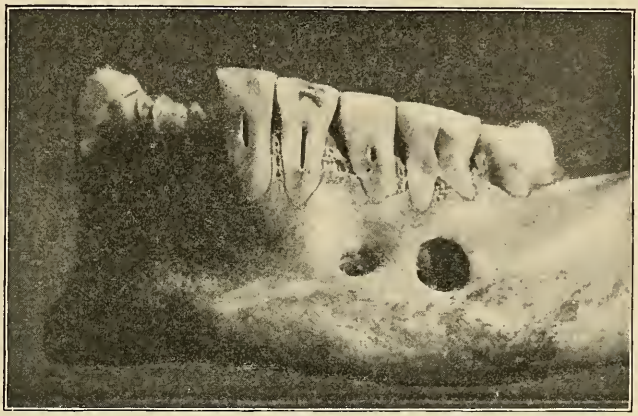

Artificial abrasion produced by brushing with a much-used English tooth paste with motor brush for eighteen hours. Remains of gold filling in first bicuspid. (Miller.)

Fig. 285

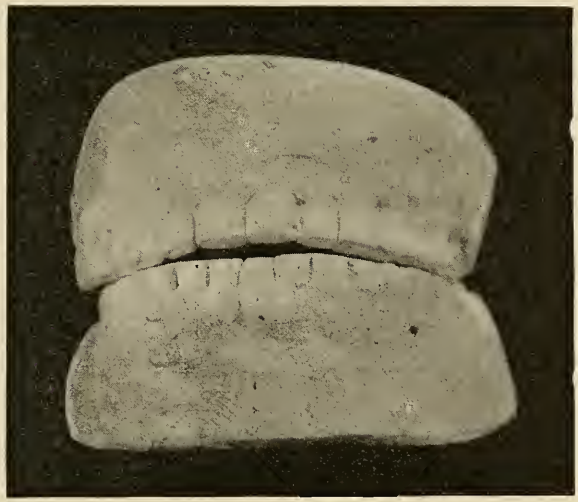

Gradual wear of both tooth substance and filling material, notwithstanding the open bite. (Miller.)

competent to wear away tooth structure, gold, and other fillings (Figs. 281 to 284). Figs. 283 and 286 show a lingual wasting,

[1] Dental Cosmos, 1907.

resembling graphic erosion. In both cases abrasion is proved by the wasting of metal, which acids could hardly accomplish. Miller experimentally proved abrasion competent to produce the grooves known as "wedge-shaped defect" (Figs. 284 and 298).

Calculus may be worn in like manner, either by the brush or by the festoon of a plate (Fig. 287).

Miller found that among clinic patients who never used a tooth-brush the labial abrasion was wanting, and he observed that a cessation of wear followed the abandonment of the use of gritty powder and the adoption of a soft brush and mild powder, which is the evident indication in such a case.

A clasp may abrade a tooth, and, if food debris be retained on its inner side, caries may follow in the abraded area. The purely abraded surface will be polished. Slight approximal abrasion may be normal as a facet, due to the rubbing of one tooth upon another at the contact point. A marked example of this was seen in the mandible of a skull of a Maori. (Museum of Philadelphia Dental College.)

The third lower molars are locked beneath the distal surface of the crowns of the second molars. Some form of bone loss occurred, producing looseness of the third molars. The individual motion of the teeth produced a deep abrasion of the enamel of the second molars upon the distal surface, and an occlusoproximal abrasion of the third molars. (Also see Fig. 338.)

Grit in powder may easily be detected by taking a small portion between the incisor teeth, or may be found by elutriating the powder, *i. e.*, place in water, stir, let settle for a few seconds, pour off the supernatant fluid, and examine the sediment as above, or microscopically (Fig. 282).

Miller found from experiments, as to the effects of various acids acting for a time and followed by brushing with abrasives, that it depends very materially upon the nature of the acid. Those acids which rapidly decalcify (soften) the dentin, of which we may take hydrochloric and lactic as types, most readily retard the wearing away by friction (unless the friction be so great as to wear in spite of the decalcification). While those which act slowly on the dentin (oxalic, tartaric, etc.), as well as those which have a macerating effect on decalcified dentin, may be wanting in this influence. He concluded that wear could not be produced by acid alone, but that any acid or acid salt which possesses the power of extracting the calcium salts from enamel, or of breaking up the connection between the enamel prisms, may accelerate the process of wasting, provided the necessary mechanical factor works together with it. Miller found food to be a negligible quantity as to wear upon labial surfaces.

The editor has a patient presenting the general characteristics of Fig. 300, who has been a brush enthusiast, and was taught in early life to use a toilet soap containing fine pumice (Bazin's poncine soap).

Extensive approximal abrasion may be due to extrusive elongation of a tooth in one or both jaws, causing a tooth to occlude with its antagonist with a glancing motion.

In this manner, specimens are produced abraded from the occluso-approximal angle to nearly the apex of the root.

The festoon of a metal plate may rapidly cause abrasion of the lingual cervix of a tooth. The condition is, however, rare; caries being more common. In the editor's practice a case was seen, in which several teeth were so affected in a few months, by an ill-fitting metal plate. The festoon of a vulcanite plate has also produced such an abrasion.

Abrasion sometimes follows caries, when the latter has become freely exposed to attrition. The softened surface wears away and the part assumes a polished appearance, but is discolored as the result of the stain due to the caries. (There is also eburnation, which see.)

It is probable that a hyperacid condition of the saliva in connection with mechanical forces may be a cause of rapid abrasion. (See Erosion.)

Effects of Abrasion.—These are external and internal, and most marked in the occlusal variety. The crown wears down until at times the gum is reached. In the process sharp edges of enamel are formed. These splinter off, leaving rough edges, or the enamel may fracture or split longitudinally, following the axis of the crown. Supported by dentin it does not further break away (Fig. 308).

Sharp enamel edges may irritate the tongue, producing ulcers of a sometimes chronic type, which acquire indurated edges and simulate syphilitic sores or epithelioma. The causal relationship between sharp edges of the teeth and lingual epithelioma appears to be quite clear in some cases. Brown[1] mentions a case of tetanic spasms of masticatory muscles due to this source.

Sores which have given evidence of malignancy and been diagnosticated as malignant growths, have been cured by rounding and polishing sharp and irritating enamel edges of teeth.

The continued stimulation of the ends of the dentinal fibrillæ, which are exposed in abrasion, causes them either to become hypersensitive or stimulates them to formative activity. Tubule material is built upon the inner walls of the tubule, obliterating their lumen. This

[1] Dental Cosmos, 1908, p. 4.

FIG. 286

a, abrasion of lingual surfaces; *b*, of amalgam filling produced by a plate. (Miller.)

FIG. 287

Abrasion of calculus. (Miller.)

FIG. 288

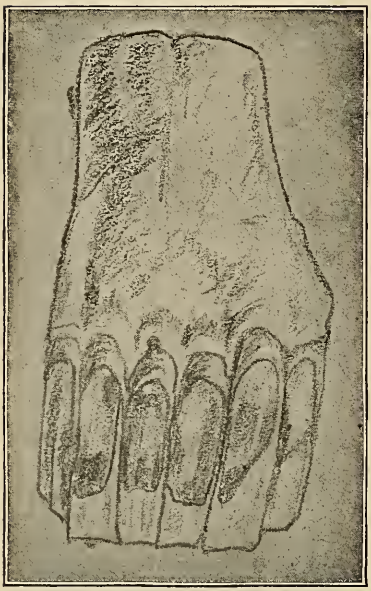

Abrasion of lower incisors of a horse produced by "cribbing." (Miller, after Kitt.)

FIG. 289

Defects resembling wasting in the teeth of a sea lion. (Miller, after Murie.)

is the so-called tubular consolidation or calcification (eburnation). Accompanying this, secondary dentin is often formed. As a result, most commonly the pulp chamber of the crown is filled up with secondary dentin as the abrasion proceeds, and the crown may often be worn off until the cervix is reached, while the pulp remains vital and covered (Fig. 280). In some cases the abrasion closely approaches the pulp, which has failed to protect itself, probably because of atrophy of odontoblasts, and the phenomena of hyperemia, or even exposure, and its results occur. A left upper bicuspid of the second skull in Fig. 280 was in this state.

The causes and phenomena of abrasion of the temporary teeth are practically the same as in the case of adults, except, perhaps, that children are more subject to the action of rectal parasites, as ascaris lumbricoides, tenia, etc., or suffer from irritable bladder due to hyperacidity of the urine. These conditions commonly produce a reflex stimulation of the muscles of mastication, resulting in nocturnal gritting of the teeth.

FIG. 290

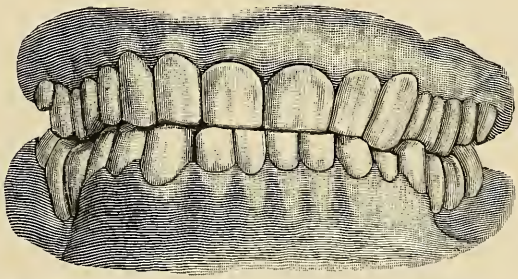

Same case as Fig. 278. Bite opened by bridge-work, posteriorly. Anterior teeth restored by means of Land jacket crowns. (W. A. Capon.)

Treatment of Abrasion.—In the cases of cupped occlusal dentin, hard fillings of platinum gold or platinized gold inlays are best. Whether the filling be built in or an inlay be set, it is advisable not to cut too closely to the enamel in making the cavity, for the structure of such a wall is often fractured after filling when this is done. If possible the form in Fig. 291, with retention made elsewhere than near the side enamel is preferable. Inlays requiring only pin anchorage are preferable when undercutting would weaken.

If nearly all teeth are present and the abrasion slight, bridge-work may be used to restore the full occlusion without attempt at restoration of the worn surfaces.

If the abrasion of the upper anterior teeth be deep, the bite may be raised by appropriate posterior crowns or bridges, and solid platinum-gold fillings may be built upon the anterior teeth, either

the uppers alone or upon both the upper and lower teeth. Anchorage may be obtained in the dentin, or screws may be planted in the dentin between the enamel and pulp and the fillings be built about them. Instead of malleted fillings, tips of the gold-inlay type may be made (Figs. 292 and 293). Casting the inlay is a simpler method. Usually it is better to use an alloy of iridioplatinum gold. This applies also to the lingual occlusal abrasion of incisors.

Fig. 291

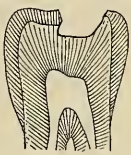

Manner of preparing the outer retaining wall of a cavity in case of cupped occlusal abrasion.

For those cases in the second degree, as a means of limiting the abrasion, Dr. J. C. Curry has introduced small truncated cones of unannealed iridioplatinum, which are to be cemented into holes drilled into the occlusal faces of the molars and bicuspids with an inlay drill of exactly corresponding size, mounted in the right-angle hand piece. As many are put in as the safety of the pulp and the enamel will permit. They act upon the same principle as steel nails in a shoe heel.

Fig. 292

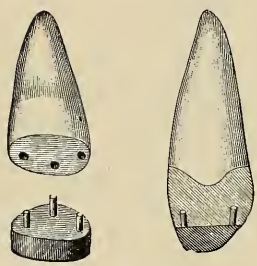

Gold tip for abraded teeth with living pulps. (Evans.) If cast the margins are to be beveled outwardly.

Fig. 293

Gold tip for abraded teeth with pulps removed. (Evans.)

Fig. 294

Porcelain-faced crowns for teeth with living pulps. (Evans.)

In other cases, after securing a proper opening of the bite and posterior occlusion with crowns or bridges, single porcelain-faced gold or platinum crowns may be made to cover each of the anterior teeth. For this purpose the crown is appropriately reduced to convenient form, but the pulps need not be destroyed. Fig. 294 represents the method outlined by Evans.[1] There can be no objection to pulp removal in any of these cases, if for any reason a dowelled crown seem preferable.

[1] Crown and Bridge Work.

Land jacket crowns, consisting of a wedge-shaped platinum jacket, with a porcelain facing attached by means of one of the numerous inlay bodies, may be used instead of the Evans crown. In some cases other forms of crowns may be indicated (Fig. 290).

There present at times cases of abrasion in which, aside from the wear, pyorrhetic conditions may be present, or where bridges cannot be properly inserted, especially when only a few teeth remain.

If this pertain to the upper jaw only, the lower denture may be restored to usefulness, the upper teeth extracted, and a full upper denture inserted; this permits the adjustment of the bite to any desired level. If the conservation of a few teeth is desirable, they may be crowned or bridged; the occlusion being raised if desirable, then a plate constructed. If the condition be transferred to the lower jaw and the anterior teeth be in good condition, a piece with the Roach[1] or Morgan type attachment may be fixed upon cuspid or bicuspid crowns.

It is to be remembered that in any case of opening of the bite, the occlusion is to be restored throughout.

The bite must not be raised by means of partial plates which strike before the natural or crowned teeth, as they tend to embed themselves in the soft tissues and create inflammation.

If the bite be only slightly raised by plates, this embedding will cause a return to the original condition. Neither must too great a strain be placed upon supporting teeth (see Overwork of Teeth).

In case of hypersensitivity, Robinson's remedy, silver nitrate, nitric acid, or the actual (hot burnisher) or the electrocautery may be effective; if not, the areas should be excavated and filled, or, if necessary, the pulp should be devitalized.

If the abrasion be caused by tobacco its use should be stopped.

A difficult class of cases to treat is found in those highly nervous individuals who grit their teeth during sleep. It is probable and reasonable that this cause alone may serve to explain abrasions traceable to no other source. The cure of such cases as these could only be possible through the wearing at night of some modified form of interdental splint. Arnone has described a simple vulcanite splint for the lower teeth, to open the molars about one-sixteenth of an inch and the incisors one-half inch. This he calls "the insulator," and is to be vulcanized at 160° C. It is to have the upper surface rounded (Fig. 295). He also describes "the paraglossus," a double vulcanite splint made in one piece to be inserted by bruxomaniacs during sleep, or by epileptics during the forewarning "aura," if

[1] Dental Cosmos, 1908, p. 17.

present, to prevent grinding or tongue biting.[1] The cases naturally indicate the medicinal use of a bromide before retiring, unless the causes can be discovered and removed.

If such gritting be present in children, the evidences of irritable bladder, due to hyperacidity of the urine, or of rectal parasites, should be sought and treated. The urine may be rendered alkaline by the use of potassium salts, and kept so by restriction to a largely vegetable diet. Belladonna may be used to reduce vesical irritability. Rectal parasites may be removed by the use of vermifuges, or, occasionally, by rectal injections.

Fig. 295

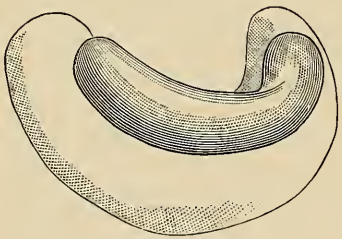

The "insulator." (Arnone.)

Fig. 296

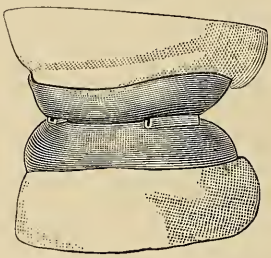

The "paraglossus." The meta groove shown relates to another method of construction.

RESORPTION OF ENAMEL.

Definition.—Resorption of enamel is the removal of enamel substance by soft tissue containing osteoclasts.

Fig. 297

Impacted cuspid with resorption of enamel and a hematogenic calculus. (Miller.)

Occurrence.—It occurs externally only in impacted teeth surrounded, at least in part, by irritated tissue, and internally very rarely after resorption of dentin by the pulp[2] (Fig. 297). (See Pulpitis.)

Such tissue may also be found in dermoid cysts, and causes the resorption of teeth. (See Fig. 32.)

Pathology and Morbid Anatomy.—Osteoclasts approximate the enamel as they do cementum, decalcify and resorb it. The dentin is next attacked. There result irregular excavations (Howship's lacunæ) and white or discolored areas of evident slight decalcification of the enamel. A deposition of bone into the area may

[1] Dental Cosmos, 1908, p. 924.
[2] Hopewell-Smith: Histology and Pathohistology of the Teeth.

occur.[1] The process is probably the result of a non-septic inflammation, as in the case of root resorption. (See Interstitial Gingivitis and Resorption.)

The enamel may be resorbed from its internal surface after the resorption of dentin by the pulp (see Chapter XVI), and, as shown by Woods, may be filled in with adventitious material of a structure resembling cementum.

Treatment.—Should the disease by chance occur upon a tooth which later has been drawn into place, the area may be filled; otherwise it has only a pathological interest.

Fig. 298

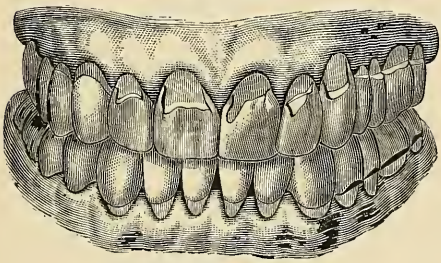

Case described as erosion. (Darby.)

Fig. 299

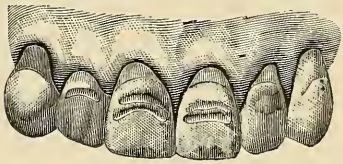

Case described as erosion. (Darby.)

Fig. 300

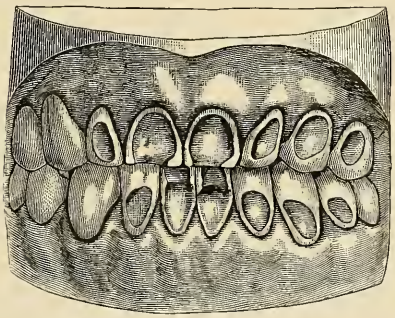

A case of erosion (drawn from the cast): *B*, silhouette from a perpendicular line through the left centrals, upper and lower, showing the loss of substance. (Black.)

EROSION.

Definition.—Erosion of the teeth is a term applied to the chemical or chemicomechanical destruction of the hard tissues of the teeth in such a manner that broad, shallow, smooth excavations are made in the enamel and dentin in situations free from attrition by mastication.

[1] Hopewell-Smith: Histology and Pathohistology of the Teeth.

Figs. 298, 299, and 300 illustrate the characteristic appearance of areas until recently supposed to be due to the chemical or chemico-mechanical solution which has been termed erosion.

The demonstrations of Miller with reference to abrasion of labial and lingual surfaces of teeth by means of the tooth-brush and gritty powders, and the abrasion of approximal surfaces into grooves in animals by the drawing of gritty grasses, etc., through or along the teeth, or the gnawing of bones by carnivora, etc., have cast a heavy cloud of doubt upon the chemical etiology of what have been usually considered as erosions due to the action of acid sodium phosphate excreted by the mucous glands of the lips or cheek.

The appearance illustrated in Fig. 298, lower jaw, and in Figs. 299 and 300 might readily, in the light of Miller's demonstrations, be regarded as abrasion, if the causes (brush and abrasive powders) he suggests be found; but the graphic outlines shown in Fig. 298, upper anterior teeth, seem difficult to harmonize with the abrasion theory. The cases of this sort are rare as compared with the others, the editor recalling but two having the peculiar undercut mesial and distal erosion borders. The spreading of brush bristles, as the brush is brought from the gum down, might account in part for this, but in one of the cases mentioned there was also an undercut at the incisal border, which would render the theory difficult of application.

One case was in a man aged forty-five years, a German Jew, fond of wines, beer, etc., at meals; the other a middle-aged maiden lady of nervous temperament, with whitening hair, slightly wrinkled skin, and some evidences of goutiness.

According to Miller, acids or acid salts, which can extract calcium salts, may accelerate the wasting process provided the necessary mechanical factor works with it and wears off the decalcified tissue before it becomes leathery, when wear is retarded. Kirk burnt asbestos cloth, treated it with hydrochloric acid, neutralized this with ammonia, washed it with distilled water, and again subjected it to high muffle heat. This absorbent, inorganic cloth he applied to buccal glands for twenty or thirty minutes in cases of erosion, dissolved the mucus obtained in distilled water, dialyzed the salts out, and examined the evaporated residue under the microscope and by reagents. He found acid sodium phosphate to be the decalcifying agent in what he called graphic (hydroglyphic) erosions (Figs. 298 and 299).

Head[1] found by experiment with a 1 to 20,000 solution of acid sodium phosphate in water, acting in the incubator at body temper-

[1] Dental Cosmos, 1907.

ature, that superficial decalcification of enamel occurred after fourteen hours, and when polished off it again decalcified in eight hours, and was quite superficially decalcified in two days; that a 5 per cent., 2 per cent., 1 per cent., and 1 to 500 solution acted under similar conditions in seventeen hours, and points out that a solution of 1 to 10,000 and 1 to 20,000 acid sodium phosphate in alkaline saliva acted after eight and five days only. He also has shown that enamel which was experimentally slightly decalcified, again hardened when placed in saliva for a time. He was, however, unable to explain the result.[1]

Miller found the slowly acting acids do not produce such decalcification as to retard the abrasive action of brushing with a 10 per cent. pumice. Given, then, a decided production of acid sodium phosphate by the buccal glands in contact with the labial surfaces of teeth (Kirk) for eight hours (the period of sleeping, and Head's period of one experiment, see above), it is quite reasonable to suppose that an undetermined percentage of acid sodium phosphate dissolved in buccal mucus, which in total has an acid reaction to litmus (Truman, Kirk, and others), is competent to produce a superficial decalcification, which the morning brushing will remove. This repeated for months or years may produce the effect seen. Brubaker, in 1894, immersed a tooth for a week in a solution of acid sodium phosphate, subjecting it daily to tooth-brush friction, and at the end of that time spots and grooves resembling erosion made their appearance.

According to Head and Kirk, the acid phosphate does not attack the enamel so as to roughen it, but leaves it translucently smooth and white, and this mildness of the action of the acid sodium phosphate is just the action that would make smooth erosion with a minimum of abrasion. (See Miller's experiments, p. 306.)

Head points out "that 1 to 500 lactic acid in water will decalcify enamel in thirty minutes, while the same percentage in saliva does not do so in fifteen days, but that the inhibitory effect of saliva is overcome when the lactic acid has a strength of 1 per cent." The inhibitory effect, therefore, seems to lie in the relative relations of the acid and alkaline element, though Head has shown that a mixture of 1 per cent. solution of acid sodium phosphate with a 1 per cent. solution of tribasic sodium phosphate, which is capable of turning blue litmus red, but not of turning red litmus blue, placed the acid under control so that the mixed solution did not corrode the tooth placed in it, which a 1 per cent. solution of acid sodium phosphate in water would do.

[1] Dental Cosmos, 1910.

Regarding the production of the abnormal exudate from the labial glands, Kirk argues that in diseases of suboxidation (resulting in hyperacid conditions such as gout and rheumatism) the blood is loaded with carbonic acid as a result of faulty metabolism. In the epithelium of the kidneys, the mass action of the carbonic acid upon the sodium phosphate of the blood, normally produces acid sodium phosphate, which is eliminated in the urine, and sodium bicarbonate, which is returned to the blood and maintains its alkalinity (see p. 96), according to the following reaction: $HNa_2PO_4+H_2CO_3=H_2NaPO_4+HNaCO_3$. If the amount of carbonic acid be of only normal production, this action will result in only a normal amount of acid sodium phosphate in the urine and perspiration; but if in excess and not cared for by the lungs, skin, and kidneys, the buccal glands may also take up the action and excrete acid sodium phosphate in an identically similar manner. The acid calcium phosphate is also found in the saliva at times, and can be formed in a similar way, the calcium phosphate being substituted for sodium phosphate as the basic salt.

Kirk states that in the saliva of arthritics there are frequently found acid salts, such as acid sodium phosphate and acid calcium phosphate. The excessive amount of carbonic acid accounts for the excessive loss of phosphate in the kidneys seen in arthritics, as the acid sodium phosphate and acid calcium phosphate require for their production the basic phosphates, and the elimination of those, continuously, produces a phosphaturia until depletion of phosphates occur, when their amount lessens and other salts appear. (See p. 96.)

In a paper published in 1902, Kirk[1] describes polariscopic observations made upon saliva from a patient afflicted with a general erosive wasting of the teeth. The patient had had attacks of inflammatory rheumatism, and suffered from obstinate constipation, periodic attacks of migraine, headaches, and neuralgia, and his saliva was most acid at night. The saliva was dialyzed, the dialysate concentrated, and found to contain lactic acid salts, calcium lactophosphate, calcium lactate, and magnesium lactophosphate (Fig. 301).

In view of these two classes of cases, Kirk has suggested that erosion cases may be of two kinds: (1) A general erosion, in which all of the surfaces are uniformly involved, and in which lactic acid is the solvent agent; and (2) cases distinctly due to an exudate from abnormal buccal glands or gland, the acidity of which is due to either acid sodium phosphate or acid calcium phosphate. Talbot[2] claims

[1] Items of Interest. [2] Dental Cosmos, December, 1907.

that the systemic acidosis produced by various diseases and by fruit eating in excess is responsible for the acidity of the buccal mucus and saliva, and for pulp and gingival degeneration and resorption through a process of artery and nerve-end degeneration. A decrease in the normal acidity of the urine (below 30) indicates renal insufficiency, and the difference indicates the amount retained in the system. An excessive acidity of the urine indicates excessively imperfect oxidation. This expression of the cause is quite compatible with the view of Kirk, and both are views of general malnutrition. (See p. 93, etc.)

FIG. 301



Crystallization of salts from dialysate of saliva from erosion case, showing two typical forms. Large crystal is calcium lactate. (Kirk.)

The disease appears to affect females more than males; appears usually after thirty years of age, and often some history of goutiness, arthritis, or rheumatism can be obtained. Miller denied the presence of this disease in the gouty, but since his observation the editor has had several patients hold up gouty fingers when questioned as to a possible gout as a cause of the erosions present.

Erosion Due to Extraneous Acids.—Miller[1] describes a case reported by Davenport,[2] of Paris, of a healthy man whose teeth were eroded and worn away by acid vapors, within six months of entering a factory devoted to the manufacture of nitric and sulphuric acids. This effect was observed upon the other workmen also, and also in workmen in a dynamite factory in which these acids are used. The teeth were first set on edge. Miller suspended a tooth in a flask con-

[1] Dental Cosmos, 1907. [2] Transactions American Dental Association, 1881.

taining equal parts of nitric and sulphuric acid, and found that the vapors attacked not only the inorganic but the organic portion as

FIG. 302



Another field from the same specimen as Fig. 301, also showing two typal forms. Large crystal is calcium lactate. (Kirk.)

FIG. 303



Crystallization from solution of a tooth in 1 per cent. lactic acid. Large crystal is calcium lactate. (Kirk.)

well, so that upon slight rubbing with a soft tooth-brush the tissue was worn away, leaving a hard, polished surface. Miller states that

the vapor is nitrogen peroxid, N_2O_4. Lemon juice, even in lemonade, and vinegar will produce this effect of setting on edge, which undoubtedly is due to the chemical solution of a small portion of the enamel, probably the interprismatic cement substance, leaving the enamel globules a trifle higher, this soon being worn off to a general level again.

Guilford[1] mentions a case of erosion caused by shaddock (grape fruit) eating. Tomes cites cases of erosion caused by lemon and grape sucking. The pitting of grapes has produced cases of peculiar erosion of the labial and lingual surfaces and incisal edges of anterior teeth. In one case, the incisal anchorage of an approximal gold filling was almost worn away upon the tooth most used to pit the grape. Unquestionably, other fruit juices might act in a similar manner if the acid has an affinity for tooth structure, and the exposure to its action is sufficiently lengthy and often enough repeated to produce effects.

The Effects of Erosion.—Tubular calcification and secondary dentin are produced together with atrophic changes in the pulp, due to secondary dentin formation. Gold and amalgam fillings are left as raised islands by the wasting of the tooth around them, though Miller has shown that associated abrasions may cause their wear, which acids evidently can hardly be expected to do.

Scratches shown as lines and Baume's clefts are explainable upon the theory of abrasion by brush and powders; though usually transverse, there are sometimes vertical lines. The stimulation of the dentinal fibrillæ by acid or mechanical stimuli may cause great hypersensitivity; as a rule, however, this is not pronounced (Fig. 304).

The anterior teeth are sometimes shortened so that their occlusion is lost. Kirk's lactic acid case was of this order. The carious process may become implanted upon an eroded area, or at some part of it, usually the cervical portion. Whether this is initiated by a decalcifying process due to the acid sodium phosphate, or uncleanliness due to a cessation in the intensity of the brushing, is not so clear as it formerly seemed, when it was thought due to a temporary cessation in production of acid sodium phosphate, which was regarded as immunizing the part to caries. In any event the stain of iodin is taken, showing the presence of bacterial films at the point showing caries.

Diagnosis.—The presence of the peculiar excavations, the hypersensitivity of dentin if any, and the acid character of the mucus from the follicles, as shown upon test with litmus paper made just

[1] Lectures.

after rising,[1] are diagnostic signs. Kirk's method of obtaining the acid may be used. (See p. 314.) The acid reaction is not marked

FIG. 304

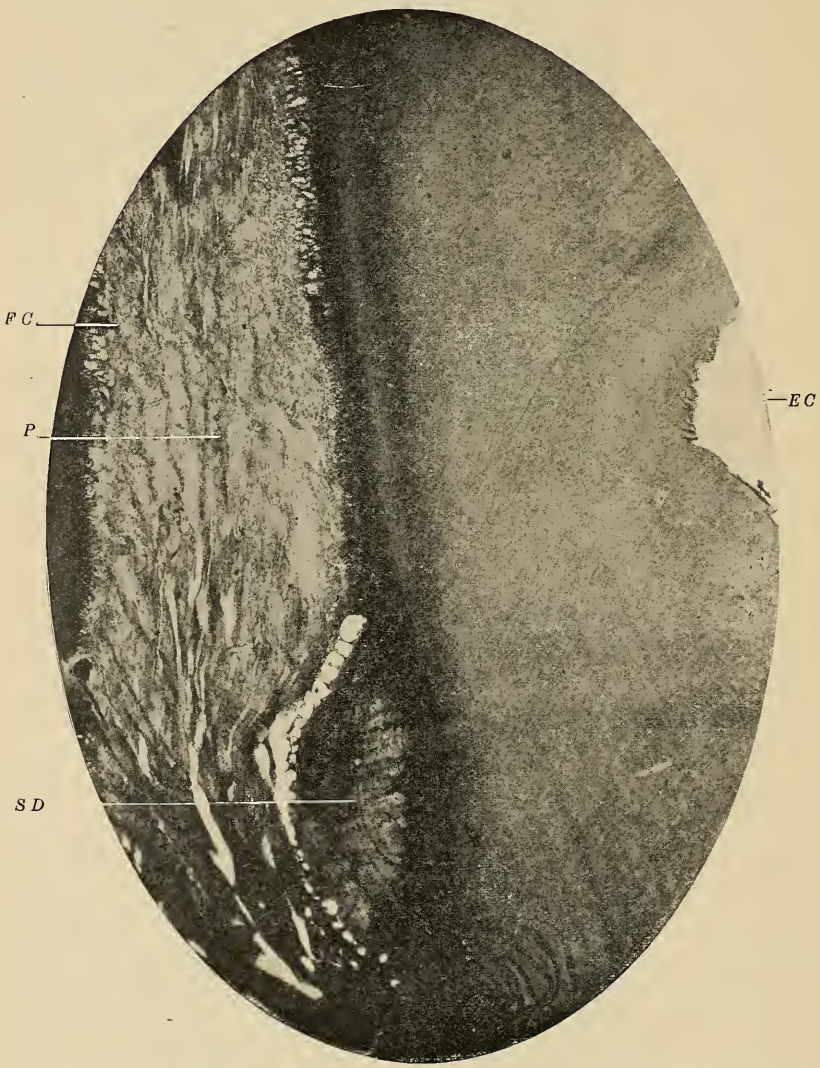

Sagittal action of human incisor prepared by Hopewell-Smith's process, and stained with hematoxylin: *E C*, erosion cavity, on surface of which can be seen Baume's clefts; *P*, pulp tissue undergoing degenerative changes; *F C*, atrophic odontoblasts: *S D*, secondary dentin. × 45. (Hopewell-Smith.)

[1] Truman.

during the day. The existence of erosion has become a valuable diagnostic sign for the general practitioner in his search for the nature of masked maladies from which patients frequently suffer.

Obscure gout has been pointed out through dental indications alone, where the practitioner had before been baffled in his diagnosis.

Treatment.—The treatment of erosion divides itself under two heads: Prophylactic and restorative; the prophylactic is again divided into local and general treatment. The problem of eradicating the cause of the disorder lies in a correction of the morbid glandular secretion. It is evident that if the irritation and altered secretion of these glands be due to some systemic cause, a disease of suboxidation, notably an affection of the gout order, a cure of the local disturbance involves the cure of the underlying systemic cause. Talbot[1] reduces the acidity to normal with sodium bicarbonate (10 to 30 grains), or sodium chlorid (45 grains), after meals; or sodium phosphate morning and evening. One-tenth grain of calomel is given each two hours, for a time, to cleanse the bowel and stimulate the liver. Eight to ten glasses of water should be taken daily. A practically antigout diet and hygiene are suggested, to increase oxidation and elimination. Local treatment of the gums is necessary. (See pages 97–105.)

Kirk,[2] working to the end of reducing acid buccal secretion, uses, three times a day, $\frac{1}{100}$ grain pure phosphorus in olive oil, in gelatin capsules, along with a very mild laxative, and when the urine shows a deficiency of phosphates, 25 to 30 grains per diem of glycerophosphate of lime and soda are given.

Next in importance to the prevention of acid formation is its neutralization. This implies the application of alkalies or the use of alkaline mouth washes. The greatest production of acid occurring during the night, applications of adhesive masses of alkaline substances are made to the teeth at night. The principal of these is prepared chalk, calcium carbonate; it is rubbed over the labial faces of the teeth and between them, before retiring. It remains in sufficient amount to neutralize any acid substances coming in contact with it.

Excellent results, as to the checking of the progress of the decalcification, are obtained from the use of magnesium hydrate held in suspension in water, or milk of magnesia. Kirk found that three hours after the use of a teaspoonful of the milk of magnesia, the saliva maintained an alkaline reaction. It should be used at night as a wash, after cleansing the teeth, the residue to be left as an alkaline coating upon the teeth. The chalk and milk of magnesia

[1] Dental Cosmos, December, 1907.

[2] Dental Cosmos, 1908, p. 811.

may be mixed into a paste. If the preparation be disagreeable, a few drops of essential oil may be added. (See Caries.) The abrasive factor and its possibilities as causes of apparent erosions suggest the avoidance of any strongly abrasive powders, or, perhaps, a confinement to the use of castile soap and a soft brush.

It has been suggested by Ottolengui[1] that in the earlier stages an impression and plaster model of the teeth be made for comparison at future dates, so that the progress of the erosion may be noted.

Restorative Treatment.—If the eroded areas be excavated and filled, the erosion may proceed about the edges of the fillings. It may, however, take some time for the erosion to become as deep as the original area.

If metal be used, the margins must be extended to avoid this, if possible. Metal is very unsightly in the locations peculiar to erosion, so that porcelain inlays, which the locations favor, are indicated. In their place silicate cement fillings may be used, but must be constantly kept in a good condition of surface or they become unsightly.

The generally distributed erosions are only amenable to the prophylactic treatment (except by crowning, when teeth are largely wasted away), and slight erosions are best treated in the same manner. If a sharp edge be produced it is well to remove it, as lip irritation may possibly be a factor in the acid production.

MECHANICAL INJURY OF THE TEETH.

The enamel is a material much more brittle and inelastic than the dentin, and, therefore, less capable of resisting a parting strain. Under ordinary circumstances, however, well-formed enamel distributed over sound dentin resists all the ordinary forces brought to bear upon it.

Under abnormal conditions, however, enamel appears to fracture readily in two directions: (1) Along the line of the interprismatic cement substance between the prisms themselves, and (2) along the line of cement substance between the globules. The possibility of reference of all cases into one or other class indicates that the cement substance is naturally a tissue relatively weak.

Dentin may apparently fracture in any plane.

Causes.—The teeth may be mechanically injured by (1) the action of abrasion, which mechanically wears away the teeth; (2) by the application of undue force during mastication or by the improper use of cutting, filling, or extracting implements; (3) by blows of

[1] Methods of Filling Teeth.

some sort, delivered either directly upon the teeth or through forcible closure of the jaws, as the result of a shock or blow delivered upon the rim of the jaw.

Aside from blows or bites of sufficient force to break sound teeth, it is rare to find teeth fractured without a previously acquired weakness in the tooth itself. The causes of weakness are several.

During the course of abrasion the enamel is worn to a sharp edge, which is readily fractured. Oblique splintering occurs in the line of cement substance between the globules. The enamel edges become ragged and further fracture is imminent. Thread biting produces a similar but localized condition (Fig. 308).

Caries, by removing the natural support of the enamel, renders this brittle material subject to fracture in ordinary use. The removal of dentin from both the mesial and distal sides of a crown by caries —*e. g.*, a bicuspid—renders the buccal or lingual section liable to fracture, as the result of a strain delivered between the cusps and tending to wedge them apart. This accident is liable to occur in proportion to the lessening of the healthy dentin between the cavities or beneath the occlusal fissure. An upper incisor so decayed would naturally have its labial section fractured away, particularly its incisal half.

The exposure of the dentin of a devitalized tooth to the saliva seems to weaken it.

While these principles are correct, it is surprising to what extent enamel undermined by caries may retain its integrity if properly supported by an adhesive oxyphosphate of zinc.

The packing of cohesive gold against frail enamel walls renders them liable to direct fracture, or if packed so as to permit leakage the wall is further weakened by lactic acid produced upon its under surface. Again, the improperly prepared cavity margin may be comminuted, a condition favoring the recurrence of caries.

Gold does not support enamel walls so well as oxyphosphate. If built over comparatively frail walls in such a manner as to protect them from direct impact, they stand fairly well. Inlays of gold serve a useful purpose in this connection.

Amalgam by its attendant leakage permits gradual weakening of frail enamel walls. The use of a cement lining, as in combination fillings, is distinctly useful both as a support and prevention of leakage.

Johnson[1] explains fracture after filling, where the enamel walls were previously undermined but not fractured, upon the theory that

[1] Principles and Practice of Filling Teeth.

previous to filling, the pain attendant upon mastication brings about a temporary disuse of the diseased tooth. After filling, comfort ensues, the patient again uses the tooth, and fracture occurs.

The fractures caused by blows present features of interest. An actual splitting off of one of the angular portions of a crown may occur, or a fracture may be seen resembling one sometimes seen in a pane of glass, the result of a light blow from a stone.

In the latter case, the cracks radiate from a central crushed spot, and may involve only the enamel. A large section of an incisor may be fractured away and include the labio-incisal third and all the lingual section of the crown and a small, obliquely fractured portion of the root. This results from a blow—the exact opposite usually results from occlusal strain.

FIG. 305

Fracture of two years' standing with pulp vital and a lateral tissue growth resembling granulation tissue covering the root face, would explain how the case, Fig. 309, occurred. (Macdonald.)

Biting upon hard objects has caused the fracture of sound bicuspids and molars, the line extending mesodistally between the cusps, the fracture being oblique or through the crown and between the roots. Thus a molar or first bicuspid may be divided into two sections, each supported by a root or roots (Figs. 306 and 307).

Fracture and repair of enamel after eruption is not, so far as I am aware, known. Cases of fracture and repair of dentin have occurred.

A case of such repair by adventitious (secondary) dentin has been recorded by Tomes,[1] and Fig. 309 illustrates a fracture of the root well below the gum line. The root is girdled by the line of fracture, but the dentin has been repaired, and the attachment is firm. The line evidently indicates a repair from the pulp side. A case analogous to healing of a comminuted fracture of a central has been reported.[2] Fig. 310 illustrates a peculiar fracture due to an unknown cause. (See p. 326.)

In a case reported by Val. Macdonald,[3] of a similar fracture, the pulp maintained its vitality in both crown and root for two years, and until the tooth was extracted. There was between crown and root, a growth of soft tissue connected with both the pulp and the

[1] A System of Dental Surgery. (See Secondary Dentin.)
[2] Watson: Dental Record, May, 1906.
[3] Dental Cosmos, January, 1908.

pericementum, and considered by Macdonald to be pulpal in origin (Fig. 305). Macdonald's case would explain that in Fig. 309.

In an experimental implantation of a dried tooth, filed to fit the socket of a previously extracted tooth, union of osseous nature took place, and a slight fracture of the root was reunited by osseous deposition.[1]

FIG. 306

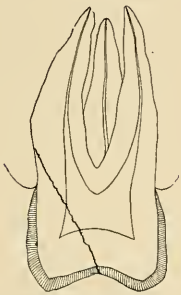

Oblique fracture.

FIG. 307

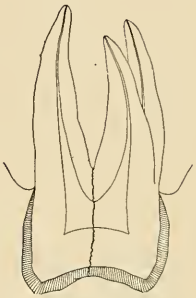

Fracture involving the bifurcation of the roots.

Longitudinal cracks in the enamel of otherwise fairly sound teeth occur, the line running from the labial edge of the gum to the incisal edge of an incisor (Fig. 308), or from the fissure of a bicuspid along the enamel to the summit of a cusp, or from the cervical margin of an approximal cavity to the gum margin.

FIG. 308

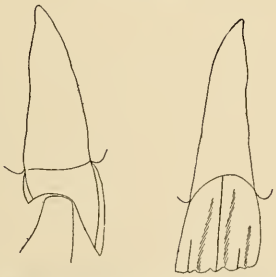

Abrasion associated with fracture of the enamel.

FIG 309

Root fracture and reattachment by adventitious dentin. (From a specimen.)

These lines probably indicate that force has been applied, sufficient to cause a parting of the enamel cap without loss of continuity in the more elastic dentin. Dryness from mouth breathing may be a possible cause of cracks, and the contact of excessively hot or cold

[1] Mendel Joseph and Dessonville: L'Odontologie. (See Cosmos, 1904, p. 1060.)

substances has been advanced as an hypothesis, but mostly they are found in cases of overworked teeth. In some cases the enamel cracks may be very numerous. These cracks take up stains, and at times in the preparation of cavities, cause annoyance by centring the chisel and perpetuating a defect, necessitating the removal of much tooth tissue or the risking of future caries. In one case typical of a class of accidents, the root of a second bicuspid was found loose and fractured longitudinally (Fig. 310). As its occlusal end was firmly embedded in an encircling crown band, and no pins had been used, the only explanation seems to be, fracture in preparation, the swelling of the guttapercha root canal filling or the expansion of gas. Such an explanation could not apply to the fracture in Fig. 311.

Fig. 310

Case of root fracture. (See Text.)

Treatment.—The treatment of fractures involves considerations purely operative, and depends upon the nature of the case. Roughened, abraded enamel margins are best rounded with carborundum stones or coarse sand-paper disks, and should be polished. Sometimes a deep serration must be filled; corners are to be nearly rounded or restored to contour by fillings or inlays, or at times the entire incisal edge is to be ground away and the tooth drawn down and retained until firm.

In case of an uncompleted tooth root, and the pulp not quite exposed, a pure gold, all-metal crown is to be adapted with or without grinding, according to the future requirements, and the root completion awaited. If necessary, the capping of the pulp may be attempted as well, for the same purpose.

After root formation the pulp may be destroyed if desired. If conservation of the pulp be not possible, the pulp may be prepared for removal by pressure anesthesia or conductive anesthesia, and the root filled. (See Root Fillings.)

Fractures involving the cementum demand either the removal of

the loosened piece and the construction of a special crown retaining a portion of the natural crown as a base, or the removal of all of the natural crown and the mounting of a substitute upon the root, or the parts may be banded, or in case of molars an all-metal crown may be mounted. In some cases screws or a staple must be placed in the roots and the parts restored with amalgam (Figs. 313 to 315). If the loosened portion be retained, thin oxychlorid of zinc is to be introduced into the joint after appropriate sterilization, and before the gold crown or holding device is set. It distributes itself by capillarity, if the joint is slightly opened once or twice. The split piece, if of the oblique type, is apt to irritate, and in most cases in time cause lateral abscess. It should ordinarily be removed and the part prepared as in Fig. 313. Should the pulp be vital at the time of

FIG. 311

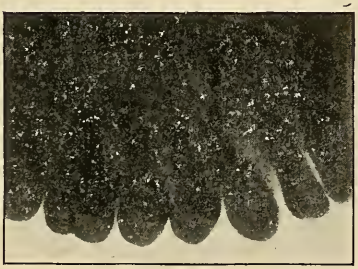

Fracture of portion of upper cuspid, cause unknown. (Skiagraph by E. Ballard Lodge.)

FIG. 312

Fracture with dovetails for amalgam. (Evans.)

FIG. 313

Oblique fracture of root, with pin and amalgam for restoration, ready for crowning. (Evans.)

fracture, it will become inflamed, and should be removed by the pressure method if possible. To accomplish this, the parts must be lashed together and an occlusal opening made. After devitalization, the parts may be given a dove-tailed form, and be temporarily held together, internally, by amalgam, or a circular band may be inlaid in a trephined groove by Cigrand's method (Fig. 316[1]). The cuspid root shown in Fig. 314 had an amalgam filling in its mesial side until after the cap and band were constructed. A temporary crown caused the wall to fracture out, so the plan was devised of drilling holes in the root side, tapping them with the How tap and

[1] For certain crowning devices in cases of fracture, see Evans' Crown and Bridgework, and Goslee's Principles and Practice of Crowning Teeth.

placing iridioplatinum screws on both sides of the pulp canal groove. The pin and cap were then waxed slightly, placed in position, amalgam built in and when hard, the wax was melted by heating the

Fig. 314

Screws placed into a fractured root to enable the building up of amalagam around a waxed pin attached to a gold cap. This root is one of four piers of a nine-tooth bridge.

Fig. 315

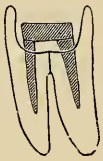

Staple used to unite portions of a fractured root. (Evans.)

Fig. 316

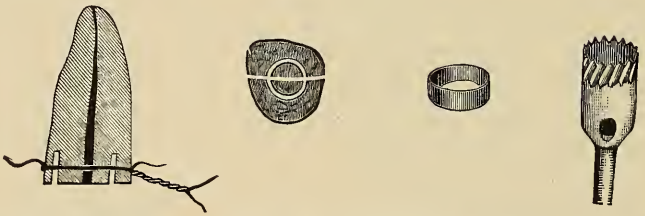

Cigrand's method of trephining a root face and inlaying a metal ring; also useful to prevent fracture when plain dowel crowns are used.

cap and pin, which were withdrawn. After thorough hardening, the bridge-work was proceeded with. Fortunately the root received its strain from the lingual side, which was largely intact. The requirements vary, and must have due consideration.

CHAPTER X.

STAINS OF THE ENAMEL AND DENTIN.

CERTAIN stains are found upon the surface of the enamel and sometimes penetrating its substance. The calculus sometimes located upon the enamel is not included in this consideration, though the calculus itself sometimes becomes stained. So far as they have been observed, stains may be divided into those of metallic and non-metallic origin.

METALLIC STAINS.

Metallic stains are those which are caused by the direct deposition of minute particles of metal, inhaled by workers in the metals, in the organic collections upon the surfaces of the teeth, or taken into the mouth in various solutions of drugs.

Copper.—Miller found that "workers in copper, brass, or bronze all presented a green stain upon the upper teeth, showing every shade of green and bluish-green up to bluish-purple. The latter color predominated in rooms where phosphor-bronze was worked." Attention is called to the fact that "trumpeters very often show a discoloration of the teeth." Similar discolorations are sometimes noted in proximity to copper amalgam fillings. The presence of copper was demonstrated in scrapings from some of the stained teeth, imparting a characteristic green color to a Bunsen flame. McGeehee[1] notes a case of a metal worker whose enamel was stained and the dentin as well, the tooth being vital. The presence of defects or spaces containing organic matter is evidenced (see p. 352). Bands or wires containing base metals, generally containing copper, sometimes stain enamel.

Iron.—"Workers in iron presented stains of a brownish color." As pointed out, "the green salts of iron under the conditions found in the mouth would become oxidized and brownish in color." The administration of iron salts, medicinally, is believed to produce black discolorations, iron sulphid being formed. "Iron deposits are usual in the border-line between carious and normal dentin." It is believed that the brownish spots frequently seen in connection with

[1] Dental Cosmos, March, 1912.

incipient or arrested caries of the enamel are due to the formation of iron salts. Iron or steel in dentin stains black with iron sulphid.

Manganese.—Manganese was found in the dark colored deposits upon the teeth of herbivorous animals, but as yet not upon those of man. The investigator stated "that alkaline saliva may be necessary to the production of these deposits." Manganese stains may occur from the use of potassium permanganate, manganic oxid being formed.

Mercury.—In cases of prolonged mercurial administration the deposits (black) upon the teeth may give the reaction for mercury. "If mercury and potassium iodid are given together, the green iodid of mercury might be present upon the teeth." It is probable in these cases that another discoloring substance may form. There is in mercurialism more or less gingivitis; the gums are swollen and spongy, bleeding readily. "More or less putrefactive decomposition of the albuminous matter present upon the teeth occurs, and hydrogen sulphid is formed. Reacting upon the oxyhemoglobin of the blood, sulphomethmoglobin is formed—greenish red in concentrated, green in dilute solutions." Miller ascribes the discoloration found in conditions of gingivitis from various causes, with lack of hygienic care, to a probable reaction between hydrogen sulphid and oxyhemoglobin.

Lead.—Hirt (quoted by Miller) found in cases of lead poisoning, discolorations upon the teeth: dark brown at the necks, light brown on the crowns, with sometimes a trace of yellowish green. Miller's tests (limited in number) showed no lead reaction from the dental deposits in lead poisoning.

Nickel.—Some of the salts of nickel are green. Metallic nickel attacked by fluids of the mouth and mixtures of bread and saliva produces greenish salts. The entire root of a tooth containing a nickel retaining screw has been stained a uniform apple green.

Silver.—The dentin of pulpless teeth containing amalgam fillings is sometimes stained black, owing to the formation of silver sulphid.

The use of silver nitrate as a wash may cause the albuminate of silver to precipitate salts of silver upon the teeth. If a cavity be touched with silver nitrate and an amalgam filling be introduced, the salts of silver will be instantly formed at any point where the silver nitrate and amalgam combine. If this be upon the enamel, the latter will receive a somewhat lasting black stain.

The nitrate of silver applied to dentin causes the dentin to assume a light yellowish green tinge, and the albuminate of silver is formed; later metallic silver is precipitated, the tissue becoming black.

Gold.—Gold chlorid stains may be formed during the bleaching of teeth containing gold fillings by the chlorin methods. The dentin becomes first pink, then violet or purple, then black.[1]

NON-METALLIC STAINS.

Green Stain.—The most common of green deposits upon enamel occurs upon both the temporary and the permanent teeth, particularly of young persons. The deposits usually have a crescentic form, are mainly upon the labial faces of the anterior teeth, and may be but a narrow line or may cover one-half the labial face. It is unusual for the deposit to extend far into the interproximal spaces, their tendency being to follow the edges of the approximal surfaces. While green stain undoubtedly does form upon adult teeth (Figs. 317 and 318), where clearly the enamel cuticle has long been absent, it is only very common upon young teeth where remnants of Nasmyth's membrane persist about their necks. The color of these deposits varies from light green to greenish black.

FIG. 317

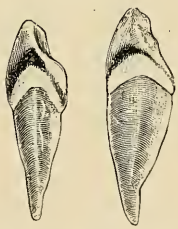

Extension of green stain on the approximal surface of the incisors. (Miller.)

FIG. 318

Extension of green stain on the lingual surface of the incisors. (Miller.)

If an instrument be passed over the portion of enamel affected, more or less roughness of the surface is evident. If the deposits are subjected to friction with abrasives, they disappear slowly and the enamel beneath may be found roughened. This has led to the belief that these deposits cause decalcification of the enamel. It is found upon adult teeth that when an area of cervicolabial enamel has become roughened through slight decalcification, a green stain is likely to form upon the rough surface, if proper hygienic care be not exercised. It is also found that if the stain be removed by means of abrasives, the roughened enamel may be readily polished—*i. e.*, the decalcification is very superficial.

[1] Kirk: American Text-book of Operative Dentistry.

If cases be observed early enough in childhood, it will be noted that green stain is usually preceded by a lack of oral hygiene; collections of food debris are not removed from about the necks of the teeth, which implies that prior to the formation of green stain the affected enamel surfaces have been subjected to the action of fermenting food debris—that is, to acids. These facts have led to an acceptance of the view that the roughness or decalcification has preceded the green deposits. "If teeth be placed in a 10 per cent. solution of hydrochloric acid, in from two to four minutes the enamel cuticle begins to loosen, and in from five to ten minutes is isolated. It is found that the entire stain comes away with the cuticle."

In even the mouths of children, the removal of green stain with pumice may be difficult, showing that some penetration of enamel substance has occurred.

Nature of the Coloring Matter.—The coloring matter is found to be insoluble in water, glycerin, alcohol, ether, chloroform, or oil of turpentine. Mineral acids, hydrochloric, nitric, and nitrohydrochloric act but slowly upon the coloring matter; even hydrochloric acid requires some hours to completely destroy it. Tincture of iodin, commonly believed to act as a solvent of green stain, was found to affect it but slightly. Both chlorin and nascent oxygen destroy the coloring matter rapidly, the cuticle being bleached in a few minutes by a 10 per cent. solution of hydrogen dioxid. Thick, dark green deposits were incompletely bleached after eight hours' immersion in the 10 per cent. H_2O_2 solution, pointing to a lack of uniformity in the composition of the stain.

The belief that the green coloring matter is chlorophyl is contradicted by the fact that it is not soluble in ether.

Miller[1] regarded the association of the green discoloration with sulphomethemoglobin, or some allied substance, as the most probable explanation, though he found a micrococcus in a deposit of green stain which produced a grayish-green color in glycerin agar.

Miller did not find any definite connection between a milk diet and green stain.

Goadby[2] has found Bacillus liquefaciens fluorescens motilis present in several cases of green stain. It deposits in its culture medium a fluorescent blue-green pigment. Other mouth bacteria produce a greenish pigment—*e. g.*, Bacillus pyocyaneus and Bacillus fluorescens non-liquefaciens.[3] The deposits of green stain are considered to be secondary to enamel decalcification rather than the cause of it, when found in connection with it.

[1] Dental Cosmos, 1894.
[2] Mycology of the Mouth.
[3] Ibid.

In case of roughened enamel, green stain appears at times to have been taken into its substance, rendering removal without bleaching difficult.

Black Stain.—A peculiar black stain occurs in the mouths of apparently healthy individuals, both men and women, and smokers and non-smokers, and even with those also who drink neither tea nor coffee. It occupies the general position described for green stain, but may cover much of the surface of the teeth. It occurs in somewhat unclean mouths, though the teeth may have been regularly brushed. As a rule, those teeth having the deposit are comparatively free from caries. Its etiology is not worked out, but it may be due to a formation of iron sulphid in place of sulphomethemoglobin. It is very readily removed, and does not, as a rule, affect the enamel. At times a superficial caries is found associated with it, and at some minute spot the enamel may be penetrated. Whether this cavity is a result of the action of the film is not certain. In a case of a woman a black stain was prevalent for years—recently it has entirely disappeared. The only available explanation other than some possible unknown systemic change, is the use of a well-known tooth paste which contains a large percentage of potassium chlorate.

Tobacco Stains.—Smokers have characteristic black deposits upon both the teeth and calculus deposited upon them. The stain is most marked upon the lingual surfaces of the teeth, and a pipestem held well back in the mouth may cause a thick deposit upon some of the posterior teeth.

Tobacco juice itself stains exposed dentin and cementum, and enters cracks in the enamel, producing brown discolorations very difficult or impossible to remove. McGeehee found tobacco stain to have deeply penetrated the enamel tissue.

Stains Due to Dyes.—McGeehee[1] has shown that colored mouth washes containing vegetable or analine coloring matter may stain enamel and other tooth structure. The chewing of betel nut or other material containing vegetable coloring matter also produces a stain characteristic of the coloring element. Dyed cotton also stains.

Red Stain.—A peculiar red stain occurs upon the necks of some teeth, but is not generally distributed. It is probably due to chromogenic bacteria, as it is only found on unclean surfaces.

According to Goadby,[2] Bacillus prodigiosus, Bacillus rouge de Kiel, Bacillus mesentericus ruber, Bacillus roseus, Sarcina roseus, Micrococcus roseus, and other micrococci produce a red pigment in at least some of their media.

[1] Dental Cosmos, March 1912.

[2] Mycology of the Mouth.

Sarcina lutea and Sarcina aurantiaca produce yellow and orange-colored pigment respectively.[1] The exact relation of chromogenic bacteria to stains is not worked out.

DENTIN STAINS.

Exposed dentin may be stained as enamel is. In addition it may take up certain stains like tobacco.

Metallic fillings, such as amalgam, containing mercury, silver, copper or cadmium metals which combine with sulphuretted hydrogen to form sulphids, may cause staining of dentin.

Metallic posts containing silver, copper, or nickel, or made of steel or iron wire, may produce sulphids in the same manner. The dentin may also be stained pink by hemoglobin entering the tubules during the progress of venous hyperemia. This finally develops iron sulphid.

The dentin may also be stained by iron sulphid formed during putrefaction of the pulp, by the action of ammonium sulphid upon the iron contained in the hemoglobin of the blood undergoing decomposition.

TREATMENT OF STAINS.

Enamel stains are best removed by mechanical means, after the removal of calculus from the teeth. (See Salivary Calculus.) For this purpose, brush wheels and rubber cups charged with pumice and revolved in the dental engine are used to remove the accessible portions of the stains. Next a wood point, made by sharpening an orange-wood stick or hickory shoe-peg to a wedge-shape, is charged with the pumice and rubbed by hand over all the surfaces not reached by the brushes and cups. For the more inaccessible situations, the point is to be mounted in a Jack or other porte polisher. A very fine linen tape, a German silver strip, or flat floss silk charged with pumice will remove the stains at the contact points. A very small finishing bur or dull ordinary No. 1 or No. $\frac{1}{2}$ bur is useful upon lingual surfaces or in grooves.

The powdered pumice used is best mixed with glycerin, to prevent the flying of the pumice during the rapid revolution of the wheels. Saturation of the stains with tincture of iodin followed by a douche of water renders them more visible, and also brings to view the associated bacterial films upon the teeth.

[1] Mycology of the Mouth.

Register recommends the use of 1 per cent. hydrogen dioxid, to be forcibly sprayed upon the gums and deposits both before and after the use of tincture of iodin. The brush and pumice will then rapidly remove the stains and bacterial films upon the accessible portions of the teeth.

Tobacco stains in cementum need not be removed to their full depth.

Head[1] has suggested the removal of deep enamel stains and the deposits in irregular depressions and joints of inlays, inaccessible to the stick, by the use of nascent oxygen derived from 25 per cent. ethereal pyrozone, or a paste of sodium dioxid and water, made by dissolving the latter in distilled water at about 32° F. These are applied to the part on cotton, and nascent oxygen liberated with a hot burnisher. The face and gums are protected by the securely placed rubber dam and by oiling the face.

The method is also applicable to the bleaching of obstinate stains of the dentin, especially near the cutting edges.

In the joints of inlays, fresh cement is to be rubbed—preferably the silicates—in order to prevent a rediscoloration.

If beneath green stains decalcification be discovered, the decalcified area should be polished as well as possible, but not cut away unless carious and the patient urged to careful prophylaxis.

After the removal of calculus and stains from the teeth, the mouth and teeth should be kept in as cleanly and aseptic a state as possible, by the employment of correct prophylactic measures. Dental caries and pyorrhea alveolaris are thus also largely prevented. (See Prophylaxis of Dental Caries and Pyorrhea Alveolaris.)

The stains found in the dentin are also divisible into metallic and non-metallic. The former are best removed by transforming the insoluble metallic salt into a soluble one.

The most frequent and practicable course is to form soluble chlorids through the action of nascent chlorin. Copper, nickel, gold, and iron stains should be subjected to the chlorin method of bleaching, followed by repeated washings with chlorin water, 50 per cent., and hot distilled water to remove the chlorid formed.[2]

Silver stains are converted into silver chlorid by the chlorin method, or iodid by the use of tincture of iodin, and dissolved out by the use of sodium hyposulphite, followed by hot distilled water.[3]

For mercurial stains Kirk recommends the use of aqueous, ammoniacal solution of hydrogen dioxid after the chlorin method, and a saturated solution of potassium iodid after the iodin method, in either case followed by washing with hot distilled water.

[1] Items of Interest, 1902. [2] Kirk. [3] Ibid.

Manganese stain is removable by the use of 25 per cent. aqueous solution of hydrogen dioxid, saturated with oxalic acid crystals and followed by washing with hot water.

The non-metallic dentin stains are removable by the use of chlorin evolved from chlorinated lime by the reaction with dilute acetic acid, or of nascent oxygen evolved from hydrogen dioxid or sodium dioxid.

In either case the color molecule is destroyed by the indirect or direct oxidizing effect.

The hydrogen dioxid may be used in the form of the 25 per cent. ethereal solution (25 per cent. pyrozone) applied for a time, or sealed within the tooth for twenty-four hours, or the 25 per cent. aqueous solution may be driven into the tubuli by the aid of the cataphoric current.

Sodium dioxid should be employed in saturated solution in distilled water (made at about 32° F.). The dentin is first desiccated and then saturated with the solution. Weak sulphuric acid (10 per cent.) is used to liberate the nascent oxygen. Kirk recommends a second application, omitting the use of the acid.

As with metallic stains, all the by-products should be washed out with hot distilled water.[1]

A further description will be given under the caption of Moist Gangrene of the Pulp.

[1] For a complete description of the bleaching process, see Kirk's article in American Text-book of Operative Dentistry.

CHAPTER XI.

DENTAL CARIES: HISTORY; EXCITING AND PREDISPOSING CAUSES.

Definition.—Dental caries may be defined as a disease of a tooth characterized chiefly by the production of a localized cavity, concavity, or area containing decalcified tooth structure and due to a combined acid fermentation and liquefaction.

History.—Examinations of crania show the disease to be certainly as old as semicivilization, and when more data are obtainable it will, no doubt, be found even older. The skull of a mummy in the British Museum, dating 2800 B.C., exhibits well-marked caries and other dental diseases. Caries appears in the teeth of the skulls of all peoples, no matter what their degree of civilization, provided their dietary included cooked, starchy foods.

Causes.—These may be divided into exciting and predisposing.

Prior to the investigations of Miller,[1] published in 1882, a vast amount of labor was expended in the effort to determine the cause of dental caries. The deductions made were partly speculative and partly based upon scientific investigations.

From 1754 to 1835 caries was regarded as an inflammation or gangrene of tooth structure; Boudett, Jourdain, Hunter, Fox, Bell, Fitch, and Koecker advancing one or the other theory.[2]

In 1835 Robertson,[3] of Birmingham, England, advanced the opinion, based upon his observations, that it "is to chemical and not to inflammatory action that the destruction of the teeth must be attributed." The author pointed out forcibly the errors and fallacies of previous writers. He stated that "Particles of food retained in fissures and imperfections of the teeth and in the spaces between the teeth undergo a process of decomposition and acquire the property of corroding, disuniting, and therefore destroying the earthy and animal substances of which the teeth are composed."

John Tomes, a little later, was the first to record microscopic examinations of carious dentin. He described the transparent zone

[1] International Dental Journal, 1884.

[2] For an interesting and exhaustive exposition of their views, see American System of Dentistry, Section on Dental Pathology, by Black.

[3] A Practical Treatise on the Human Teeth, second edition, Philadelphia, 1839.

lying between the carious and non-carious dentin, and observed and pointed out also the dentinal fibrillæ. He announced the very significant fact in relation to caries, that if blue litmus paper be applied to a carious cavity it is at once reddened, which furnishes evidence of the presence of an agent capable, if unresisted by the vitality of the dentin, of depriving the tissue of its earthy constituents, leaving the "gelatin to undergo a gradual decomposition favored by the heat and moisture of the mouth.

Tomes first established the essentially chemical character of some features of caries. The character of the acid and its localization were, however, not ascertained.

In 1867 Bridgman promulgated the theory that the crown of the tooth and the gum were of different electrical potential, and that being bathed in the oral fluids, the conditions of a battery were set up.

Acid substances were said to be set free at the positive pole (the crown), causing decalcification.

S. B. Palmer, in 1874, claimed that after filling, recurrent caries was caused by the conditions of a battery being set up—*i. e.*, the difference of electrical potential between the filling and dentin in the presence of saliva or of the fluid of the dentin, as an electrolyte caused liberation of acids, producing decalcification of the tooth or disintegration of the filling—*e. g.*, oxyphosphate.

Miller, in 1881 and 1900,[1] experimentally examined these assumptions. He ground the enamel away from the crowns of freshly extracted teeth and filled cavities made in them with gold and gutta-percha. These he placed in separate flasks containing a physiological salt solution (0.75 per cent. sodium chlorid). This, in the presence of electric currents, should produce hydrochloric acid by liberation of hydrogen and chlorin, and decalcification should occur. After four years there was no decalcification.

Similarly filled teeth were suspended in dilute lactic acid. The decalcification was exactly similar to that in the unfilled pieces used as a control. Had electrolytic currents been generated between the metals and dentin, the latter would have been acted upon more vigorously than in the unfilled pieces.

In 1868 Watt[2] advanced the theory that free sulphuric, nitric, and hydrochloric acids were generated in the mouth during putrefactive processes and caused the different varieties of caries.

Magitot[3] pointed out that the essential phenomena of caries, as they were then understood, were the same in natural teeth mounted upon plates as in the natural organs *in situ;* proving that caries is

[1] Dental Cosmos, April, 1901.
[2] Chemical Essays, 1868.
[3] Treatise on Dental Caries, Experimental and Therapeutical Investigations.

intrinsically independent of existence of vitality. By immersing teeth in solutions of sugar undergoing fermentative changes, he found that decalcification occurred. Teeth immersed in solutions of sugar, in which fermentation had been prevented by boiling the solution and sealing, or by additions of sufficient carbolic acid, remained unaffected.

Leber and Rottenstein, in 1867, first called attention to the probable causative association of bacteria with some phases of dental caries. By staining carious dentin with iodin, the dilated dentinal tubules were shown to be filled with granular bodies, which they recognized as bacteria, identifying but one of the many forms of oral bacteria—the leptothrix. They deemed an initial exposure of dentin a necessary preliminary to the invasion and growth of the leptothrix, which in conditions of lessened resistance gained access to the tubules and in some undescribed manner caused their dilatation.

The question of the recognition of the presence of bacteria directly resolves itself into the subject of special staining. Prior to the work of Koch, presented in 1881, no means of isolating specific bacteria by special cultures and staining were known, and it is remarkable that in the same year, the essential features of dental caries were first made out with some degree of clearness.

Miles and Underwood (World's Medical Congress, 1881) pointed out clearly and at length, the different appearances produced by simple decalcification of dentin and those by dental caries. Speaking of Magitot's experiments, they say: "We assume that two factors have always been in operation: (1) The action of acids and (2) the action of germs. When caries occurs in mouths it is always under circumstances more favorable to the action of germs than to the action of acids." They believed that the acids necessary for the decalcification were excreted by the germs, which utilized the dentinal fibrillæ as a food supply.

It will be seen that the invasion and multiplication of organisms in the tubuli were held as the antecedent of the process of decalcification. The deductions of these observers were drawn from data not derived from the methods of modern bacteriology—*i. e.*, special stains and special cultures. Moreover, they were made before the physiological chemistry of bacteria was even partially understood.

In 1882 W. D. Miller, of Berlin, announced, as the results of experiments conducted by him, that he believed the first stage of dental caries to consist of a decalcification of the tissues of the teeth by acids which are for the greater part generated in the mouth through fermentation of carbohydrate food by bacteria. This, it will be seen, is a position in agreement with that of Robertson.

The observations of Miller were supplemented by J. Leon

Williams, who demonstrated a microbic collection upon the surface of superficially decayed enamel, and having sufficient attachment to permit grinding *in situ*. Williams claimed that these plaques are the primary agents which manufacture acid from carbohydrate material in association with them.

These, and other observers whose names will be mentioned in place, have thrown side-lights upon the formation and nature of the plaque and upon the pabulum which they require and out of which they form acid as one of their by-products.

The reader will be assisted in considering the somewhat disconnected facts hereafter given by bearing in mind the generally accepted theory of the modus operandi of caries deduced from the facts brought out and which is now briefly stated. The *primary* cause of dental caries is a collection of bacteria upon the surface of the tooth. This probably begins with a coating of the tooth by saliva in which a certain proportion of solid organic matter exists—mucin, globulin, leukocytes, epithelial scales, etc.

This is immediately infected by ever-present bacteria, which form colonies in it. This mass of organic basis and bacterial colonies when firmly established can be ground *in situ* and constitute a "microbic plaque." By itself this cannot produce dental caries. To this microbic plaque comes the carbohydrate food which is the *second* essential factor in caries.

This carbohydrate is changed by the bacteria to acid, mainly lactic acid. This decalcifies the tooth substance, leaving the organic matrix. The organic matrix is next destroyed by bacteria having the power of its liquefaction, probably due to their enzymes. Both the inorganic and organic bases of tooth structure being destroyed, a cavity is left. This being a relatively slow process, the intermediate stages are found.

There was exception taken to this theory by Miller, who claimed that plaque formation was not essential, but that the infected food mass could form the acid and act directly. This is simply a question of whether bacteria act in the mass or under the mass, and is only a question of modus operandi, not of essential fact. Pickerill[1] endorses Miller's viewpoint, but so far as the writer is aware neither Miller nor Pickerill have offered any satisfactory proof that the plaque which von Beüst has shown to form in a few hours is not the localizing factor. There is, indeed, no reason why an infected food mass should not form its own underlying plaque out of there existing mucin and bacteria. The theory of self solution of base of attachment of the plaque (reason 2[2]) seems weak in view of the rapidity of bacterial reproduction.

[1] The Prevention of Dental Caries and Oral Sepsis, 2d Ed., p. 24. [2] Ibid.

Miller's observations and experiments established the following basal facts in connection with dental caries:

1. That in all cases of dental caries microörganisms may be seen under the microscope in the tubules of the carious dentin, and that bacteria exist in great numbers in the mouth.

2. That the invasion of the tubules is always preceded by decalcification of the dentin—*i. e.*, an area, sometimes relatively large, of decalcified dentin may be seen in advance of the organisms.

3. Analysis of the softened dentin proved that a large part of its lime salts were removed—*i. e.*, decalcification had occurred.

4. Test with litmus paper gave the acid reaction in nearly every case, so that the inference that decalcification was due to an acid was warrantable.

5. The food substances taken into the mouth are of all classes. Carbohydrates (sugars and starches), hydrocarbons (fats), and nitrogenous (albuminous) materials.

The carbohydrates are fermented with acid reaction by many mouth bacteria, commonly producing lactic acid; the albumins ferment with an alkaline reaction.

It was inferred from this and other experiments that caries was due to the acid fermentation of carbohydrates and not directly to the fermentation of albuminous substances.

6. That oral fermentation is the result of bacterial action, his following fundamental experiments show:

(*a*) A small tube was filled with a solution of starch and fastened to a molar tooth on retiring. The next morning the contents of the tube had a strong acid reaction. A tube of the starch solution with saliva added was incubated at blood temperature. After four or five hours the mixture became acid.

(*b*) The mixture of starch and saliva was kept at 100° C. for a half-hour, and incubated. It did not become acid—*i. e.*, the exposure to this temperature killed the ferment.

(*c*) The saliva was boiled for a half hour and then added to the starch solution and the mixture incubated. No acid was produced—*i. e.*, the ferment existed in the saliva, not in the starch.

(*d*) The ptyalin of the saliva was destroyed by heating the mixture for twenty minutes at 67° C.; the incubated mixture still became acid—*i. e.*, ptyalin did not act as the acid-forming ferment, but the fermentation must have been caused by some other ferment not destroyed by exposure to this temperature.

(*e*) To the mixture of saliva and starch, carbolic acid was added as an antiseptic. No acid was formed, but the ptyalin changed the starch to sugar—*i. e.*, the acid-forming bacteria were inhibited, the ptyalin not.

(*f*) A number of tubes were each supplied with a small quantity of the saliva-starch solution and sterilized; a third of them were infected from the mouth, a third by carious dentin, and a third were left uninfected as controls. The infected tubes became acid; the controls did not.

(*g*) The first of a series of tubes containing sterilized saliva and starch solution was infected with carious dentin; when this became acid a fraction of a drop was carried from it to a second tube. After that became acid a third was infected from it, and so on indefinitely.

Conclusion.—Carious dentin contains a ferment or ferments capable of reproduction—*i. e.*, living organisms are present in it.

7. The nature of this living ferment was determined by infecting a culture medium with carious dentin taken from the deeper layers. The bacteria cultivated were distended into pure cultures by carrying through a series of cultures and examining microscopically during the process. The same morphological characteristics were exhibited in the last tube, as shown by the germs in the deeper layers of carious dentin itself, and were identical with that of Bacterium acidi lactici. These germs may be found in the sediment of a culture tube, and consist of cocci and micrococci, either single or in chains. These cocci possess the power of forming lactic acid from glucose. The organism is a faculatative anaërobe (Fig. 319).

8. A sound bicuspid was sawed into sections, and an equal number of these sections placed in each of two test-tubes. Upon these was poured a 2 per cent. aqueous extract of beef (albuminous). To one tube a minute portion (0.2 per cent.) of cane-sugar was added. Both tubes were sterilized, and after cooling infected with a pure culture of the germ, obtained from the deeper layer of carious dentin. The sugar-containing solution became acid in a few hours; in a week the dentin was softened; in two weeks thin sections were completely decalcified; in three weeks cavities were found in the dentin, exactly similar to cavities formed in teeth in the mouth and presenting under the microscope other phenomena of caries to be described later.

A more prolonged fermentation resulted in the complete disintegration of the slabs of dentin, a proof of the fact that *one organism may completely destroy dentin.*

In the tube containing only the extract of beef, no acid was produced, and no decalcification of the dentin occurred.

From these facts, Miller argued that putrefaction does not initiate the process of dental caries, and may not be essential to the destruction of either the inorganic or organic dental elements.

9. That the acid produced was lactic acid, Miller demonstrated as follows:

Starch and saliva were mixed and fermentation induced. This was then checked by sterilization with heat. A quantity of material being collected in this manner, the whole was concentrated by evaporation, and tested with a solution of methyl violet, which would turn first blue and then green with an inorganic acid. Not so reacting, and not distilling off during the concentration, the acid present was pronounced a non-volatile organic acid. The concentrate was shaken with a quantity of ether, which dissolved the organic acid present. When the solution was clear, it was filtered and the ether partially distilled off, when the partially concentrated solution was further concentrated over a water bath and then mixed with an excess of freshly prepared zinc oxid. The whole was boiled, water being added as needed, until the solution became neutral, when it was set aside to crystallize. A drop placed upon a slide under the microscope showed the forms of crystals of zinc lactate (Fig. 320).

FIG. 319

FIG. 320

By testing the molecular weight of the washed and dried crystals, it was determined clearly that the substance was zinc lactate.

In practically a similar manner, lactic acid was obtained directly from carious dentin.

While Miller demonstrated the ability of one organism to produce all the essential phenomena of caries, including liquefaction of the dentin, he did not claim that only one or two organisms are involved in the process, but that "any germs possessing the power of producing acid fermentation of food may and do take part in the first stage of caries, and that all those possessing a peptonizing or digestive action upon albuminous substances may take part in the second stage; and that those possessing both properties may take part in both stages."[1]

[1] Microörganisms of the Human Mouth.

He was of the opinion that it is not the presence of this or that kind of bacterium, but rather the joint activity of the total flora, as expressed in intensity of fermentation in food particles, which determines the extent of caries.

Out of eighteen mouth bacteria examined, Miller found ten that produced lactic acid in sugar-containing solutions.[1] He also found acetic and butyric acid to be by-products. Miller and others have found lactic-acid-producing bacteria plentiful in the mouths of immune.

Hinkins and Acree,[2] in experiments upon pure cultures of a number of oral bacteria in various artificial media, found lactic, butyric, valerianic, formic, carbonic, and hydrosulphuric acids as either principal or by-products of the fermentation.

It is quite clear from Miller's demonstrations that bacteria, or at least one bacterium, are the exciting causes of dental caries; and that for their function as such they require carbohydrate material as food. It is probably true that in order to act, the acid-producing bacteria must be attached to the teeth in the form of plaques (to be later described), or the food and bacteria as a mass must be attached at some undisturbed location.

The action of bacteria upon these substances has been studied. The carbohydrates introduced into the mouth as food are monosaccharids, disaccharids, and polysaccharids. (1) The monosaccharids or glucoses have the general formula $C_6H_{12}O_6$, and are represented by dextrose and levulose, found in seeds, fruits, roots, honey, and in many forms of candy, such as peanut brittle and glacés, and galactose formed from lactose or milk sugar by hydrolysis. These ferment directly into lactic acid without formation of gas.

$$C_6H_{12}O_6 + \text{bacterial enzyme} = 2C_3H_6O_3.$$

A certain proportion of the glucose, etc., is appropriated by the bacteria as food. (2) Disaccharids or saccharoses have the general formula $C_{12}H_{22}O_{11}$. The principal one is saccharose, found in sugar-cane, the sugar-beet, sugar-maple, and maize. This is inverted by the ferment of the bacteria into glucose and levulose through a process of hydration:

$$C_{12}H_{22}O_{11} + H_2O + \text{bacterial enzyme} = C_6H_{12}O_6 = C_6H_{12}O_6.$$

Two other disaccharids enter the mouth or are formed therein: lactose and maltose, both $C_{12}H_{22}O_{11}$ (H_2O). Lactose exists in milk, and by hydrolysis is changed by bacteria to galactose, $2C_6H_{12}O_6$, and then ferments like other monosaccharids. Maltose is an intermediate product in the formation of glucose from starch, and is produced by the action of ptyalin. It is readily fermentable by yeast and by

[1] Microörganisms of the Human Mouth. [2] Dental Cosmos, 1901.

some mouth bacteria (Goadby). (3) Polysaccharids or amyloses with the general formula $(C_6H_{10}O_5)n$. Starch, cellulose, glycogen, and gum.

Starch was found by Miller not to undergo direct fermentation by mouth bacteria—*i. e.*, culture media containing starch, but not sugar, when infected by bacteria did not ferment into lactic acid unless ptyalin was present.[1] When saliva was used, however, the acid reaction occurred, owing to the formation of glucose through the action of ptyalin.

In oral fermentation starch is first changed by ptyalin to maltose by hydration, and the maltose to glucose. Then the bacteria change this to lactic acid.

$$\underset{\text{Starch.}}{2C_6H_{10}O_5} + \underset{\text{Water.}}{2H_2O} + \text{ptyalin} = \underset{\text{Maltose.}}{C_{12}H_{22}O_{11}(H_2O)}.$$

Erythrodextrin and achrodextrin are said to be associate products.

$$\underset{\text{Maltose.}}{C_{12}H_{22}O_{11}(H_2O)} + \text{ptyalin} = 2C_6H_{12}O_6.$$

or Bacterial Enzyme.

$$2C_6H_{12}O_6 + \text{bacterial enzyme} = 4C_3H_6O_3.$$

In a serial of seven papers in the American Dental Journal, beginning November, 1910, J. Oxford Keller, D.D.S., endeavors to establish the claim that dental caries is produced by causes existing in the saliva apart from organic acids produced by microorganisms. The causes ascribed are:

1. Neutral salts—a chemical combination of acid and base, as potassium phosphate.
2. Neutral salt acid or neutral salts with excess acidity.
3. Neutral salt alkaline or neutral salts with excess alkalinity.

These by chemism are supposed to extract the salts from tooth structure.

After making the assertion that lactic acid has never been discovered, even in trace, in human saliva, he states that such acids as lactic, sulphuric, muriatic, acetic, oxalic, phosphoric, malic, and carbonic may be contained in saliva in combination or association. (Compare with Miller's determination of lactic acid in carious dentin.—Editor.)

He states that lactic acid does not develop in the mouth in sufficient strength to cause caries; that full digestive fermentation necessary to produce lactic acid requires from three to six days, and any found would be neutralized by the alkaline saliva. (Compare with Miller's Experiment, No. 6, *a*.—Editor.)

The editor has carefully read these papers, but can see no reason to disturb the text of this work on their account, for the reasons that:

1. The microbic plaques are always present in enamel in incipient decay, and should protect against the access of saliva to enamel. Certainly it would have to contend with them, but when the carbohydrate element in it is considered, it is probable it furnishes them their pabulum.

2. That acid may exist in a cavity while the saliva is alkaline, and can be often noted in food masses collected on teeth, and can be demonstrated to patients by the aid of litmus paper.

3. That caries is clinically noted in the exact locations in which plaques are found is demonstrable with tincture of iodin, whereas if salivary salts are alone responsible there is no reason why clean spots should not be affected.

4. That where saliva is most abundant, decay occurs least, as a rule.

5. Because the author has by no means shown how the salts of saliva produce decay, as his experiments with concentrated saliva, which disintegrated teeth after two or three years may have contained concentrated acid, and as compared with Miller's experiment No. 8, seems unconvincing.

6. Black has shown that the plaques formed by saliva in formation of calculus are the habitat of bacteria after twenty-four hours, hence their agency is hard to exclude.

(See p. 349.)

---

[1] American System of Dentistry, vol. i, p. 805.

According to Goadby[1] a few bacteria found in the mouth can produce the change direct from starch to maltose and thence to acid. This is of no practical consequence, however, as ptyalin is always present in the mouth. (See Miller above.)

Glycogen, $C_6H_{10}O_5$, or animal starch, is fermented to glucose by liver cell ferment, and probably exists in the oral epithelium, in certain states as well as in the saliva in others, hence a systemic state may introduce glucose (in diabetes). (See Glycogenic Infiltration and pages 355, 358, and 359.)

Miller has demonstrated that bacteria produce acid from starches and sugars in about equal proportions, provided the starches are cooked. The cooking of starchy foods bursts the starch granules and renders them more adhesive to the teeth, as well as more fermentable. The following synopsis of experiments[2] made with food mixed with saliva in definite quantities speaks for itself:

Material.	Duration of experiment.	Acids formed in units.[3]
Bread, starch, potato, macaroni, rice, corn, and other cooked starches	12 and 30 hours.	20 to 25 and 42 to 110
Raw starches, potato, spinach, etc.	12 and 30 hours.	0 0
Cane-sugar and grape-sugar .	12 and 30 hours.	17 to 20 and 37 to 41
Meats, fish, eggs, etc. . . .	12 and 30 hours.	0 or alkaline.

The table shows that albuminous materials and raw starches produce no acid and are not concerned in caries except in so far as meats, etc., act as culture media perpetuating bacteria, which later may produce an acid reaction in carbohydrate materials.

Milk contains a carbohydrate (lactose) and often lactic acid bacilli. It therefore may supply both the bacilli and their food. This, however, has relation to caries only after plaque formation, or by retention of acid milk against the teeth. That such a result may occur has been shown by Bennett.

Pickerill[4] tested the acid-forming powers of foodstuffs, chewed, and incubated for four days. The following table resulted:

[1] Mycology of the Mouth.

[2] Microörganisms of the Human Mouth.

[3] An acid unit equals the amount of acid necessary to neutralize 0.1 c.c. of a 0.5 per cent. solution of potassium hydrate—*e. g.*, if in a quantity of acid material containing an unknown amount of acid, 25 of such alkaline units are necessary to neutralize the reaction, there were 25 acid units present in it. For purpose of comparison the quantities of material used were 4.0 c.c. of saliva and 0.5 grams of the food.

[4] The Prevention of Dental Caries and Oral Sepsis.

Food material.	Acid units each neutralizing c.c. of N/5 NaOH.
Pastry	5.2
White bread	4.4
Toast	4.4
Brown bread	3.6
Chocolate	3.6
Biscuit	3.5
Apple	2.6
Potato	2.5
Bread and butter with jam	2.5
Crust of bread	2.0
Parsnip	1.7
Orange	1.2
Salad	1.1
Cane-sugar	0.9
Rice	0.9
Meat (alkaline to acid unit $N/5H_2SO_4$)	4.8 alkaline

He calls attention to the various factors of viscosity of saliva, natural adhesiveness of food to teeth, etc., as modifying factors in inception of caries.

Dr. Harold Clark[1] has called attention to the fact that the English, whose teeth are much subject to caries, consume chocolate in large quantities. The observation of Dr. Albert King (p. 348) regarding white bread seems partly confirmed.

The fats may be fermented with production of fatty acids. Goadby has found these of no importance in relation to caries, but Miller has shown that the acids found in dermoid cysts, among which are fatty acids, can produce decalcification; as other acids were present, the relation of fatty acids is not quite clear. Miller asserts that fats deposited upon the teeth, as well as calculus retard decay, and that fat mixed with saliva will give an alkaline reaction.[2]

That alkalies do not produce tooth disintegration in the mouth is shown by the fact that a tooth is not affected by alkaline solutions, which are not strong enough to injure the soft parts.

The influence of carbohydrate diet in the production of caries is well shown by tables compiled by Mummery and quoted by Miller.[3] The races consuming a fish and meat diet almost exclusively—*e. g.*, the Esquimaux—are recorded as having about 3 per cent. of caries in skulls examined, while those using a mixed or vegetable diet have from 10 to 40 per cent. of caries. A most convincing example is that given by Miller of two related tribes living on either side of the Andes, in the Argentine Republic, and Chili respectively. The former, a cattle breeding and meat eating tribe, were practically free from caries, while the latter, living on mixed foods, and consuming sugar, had 19 per cent. of caries. Miller and others have shown that

[1] Private communication.

[2] Dental Cosmos, 1904.

[3] Microörganisms of the Human Mouth.

millers and confectioners rapidly develop caries after engaging in the occupation, probably owing to the inhalation of flour and sugar dust. Albert B. King[1] has recorded observations upon 132 cases of bread eaters, finding that 87 who used bakers' bread exclusively had much caries, 31 who used alternately bakers' and home-made bread had a less prevalence, while the 14 using home-made bread exclusively had only six cavities in three years. The results are certainly worthy of attention and of further observations.

While the fermentation of carbohydrate food debris into acid is conceded to be the active exciting cause of dental caries, the modus operandi of the inception has not been satisfactorily settled. Miller held that as he was able to find bacterial plaques upon many surfaces of teeth, even in the mouths of immunes, without caries beneath, the plaques had no relation to the inception of caries of enamel, but that the carbohydrate food collecting at favoring spots undergoes acid fermentation, with production of enamel decalcification, after which the bacteria enter. By experiments, he determined that the plaques rather hindered the action of acids experimentally used as a decalcifying agent. Black, on the other hand, claims that the bacteria produce a gelatinoid material and are left upon the teeth in the form of a plaque or zoöglea mass, and that the plaque is a thin, transparent, slightly yellowish film, not seen without close inspection. (It can be stained by iodin.—Editor.) Williams found a film of bacteria over the decalcified area in almost all cases of superficial caries of enamel, and that it has sufficient resistance to permit grinding *in situ* (Figs. 336 and 337).

Goadby frequently found on the opaque white patches of softened enamel, a coccus to which Williams called attention, which would cause a plaque deposition upon teeth suspended in its culture, and that when acid-producing bacteria were mixed with the coccus and a carbohydrate medium used, superficial decalcification of the enamel under the plaques was produced in from a week to ten days.

Miller also showed that in the immune with unclean teeth, the putrefactive reaction was the dominant one, and that the collection, if persistent, could act as a protective against the access of acid-producing material.

In the above data we find that the plaques are almost universal, even on immune surfaces (Miller), so that their presence on a decalcifying surface is probably true, as claimed by Williams. If, then, they are a protection against the acids produced from carbohydrate they should protect, but they do not. Secondly, experiments with formed acids are not conclusive, as they may be germicidal and

[1] Dental Cosmos, 1905.

the dead film might be a relative protection against decalcification by the acids. Thirdly, the bacterial films, if containing acid-producing bacteria, can easily take up any carbohydrate food collected against them, form acid from it, which they then pass to the enamel in a nascent state, hold it against it, and permit it to abstract the calcium salts, which they then pass out as lactates, etc., or allow to remain *in situ*. This latter conclusion in the main is the theory of Black, and while the decalcifying ability of infected carbohydrate food without the intervention of a definite previously formed plaque (but possibly by a self-formed one) is a possibility, it seems a reasonable conclusion to admit the activity of the plaques. Kirk has shown that the precipitation of mucin from saliva rich in mucin content, by lactic acid produced by lactic acid bacilli, plays a part in the development of the plaques, or by binding the bacteria together creates a bacterial plaque. Von Beüst[1] has shown that within three hours, a mucinous deposit containing many colonies of bacteria which rapidly increase in size, may be formed. He attributes to bacteria, a large share in the formation of calculus which is the theme of his paper, but it also throws light on caries plaques.

The frequent disturbance of the plaques by monthly cleansings (prophylaxis), also prevents dental caries in large degree, so that they must have some relation to the inception, though it is only fair to state that a constant warfare against any species of bacteria doubtless vastly reduces their number in the mouth.

Noyes[2] claims that in well-cared-for mouths the confinement of acid under the plaques is great, while in uncared-for mouths, though much acid is formed, it may be dissipated in the saliva and the teeth not be much attacked. This argument, however, does not take into consideration the idea of Miller, that stagnant materials take on a putrefactive reaction after the acid production is exhausted (see p. 361).

The Predisposing Causes of Caries.—The causes of the predisposition to caries are local and general.

Local Predisposing Causes.—So invariably does caries begin in sulci or pits upon approximal surfaces, about defective fillings, and upon unclean surfaces, that faults of form or retentive nature of approximation, defects, and faulty position of the teeth must bear a relation to the difficulty of keeping the parts free from accumulations of bacteria and carbohydrates.

These local predisposing causes, as they are called, are simply conditions favoring the formation of the bacterial plaques upon the teeth and the retention of carbohydrate food.

[1] Items of Interest June, 1912.

[2] Ibid., 1909, p. 750.

Lack of Oral Hygiene.—This is perhaps the most frequent local predisponent of caries. It is, in fact, a factor in the exciting cause and its reverse is prophylaxis. Most people either can not or will not cleanse the teeth thoroughly, hence their lack of care predisposes them to caries. It may not occur, but is liable to do so. Otherwise lack of hygiene means the presence of microbic plaques and carbohydrate food, and these are exciting causes of caries.

Faults of Form.—Deep pits or sulci in the occlusal surfaces of bicuspids or the occlusal or buccal surfaces of molars, or in the lingual surfaces of incisors, and occasionally cuspids, or pits upon the cusps of bicuspids or molars, or in other unusual situations, are not subjected to a cleansing friction, and so permit bacteria to form plaques in these locations (Figs. 322 to 335).

The nature of the approximal contact has to do with the inception of caries. Teeth are seen in which the approximal surfaces are well rounded and their buccal and lingual angles free from approximation. Such teeth are usually relatively narrow at their cervices, so that these also recede well from the line of contact. A V-shaped space is formed, which the gum festoon normally nearly fills. Such perfection of contour is also, as a rule, associated with a perfect organization of the enamel structure, in virtue of which the surface is smooth. While such teeth may decay approximally, there is much less tendency to caries (Fig. 338).

Opposed to this, approximations exist of a broad nature. Broad approximations are very common, and not infrequently are associated with a certain degree of enamel opacity and an unevenness of enamel surface plainly visible to the naked eye (see p. 352).

The fluid exuded by the gum is normally alkaline in character, and probably neutralizes the products of acid fermentation. In view of this fact, the first-mentioned form of contact evidently affords more of this immunizing principle. The extension of cavity margins beneath the gum has been strongly indicated by experience as good practice, and probably is explainable upon the same ground. There is also some evidence that the gum has some cleansing action (probably phagocytic) upon metal placed beneath it, as it is noted that when unclean gold crowns are removed the portion extending beneath the gum is usually quite clean.

With the narrow approximations, saliva is readily forced between the teeth and neutralizes the acids formed, or washes away soluble carbohydrates, the food for the bacteria. With the broad approximations such a result is less likely to occur.

Stagnant saliva retaining carbohydrates, probably will develop an acid reaction. (Miller.)

A depressed approximal surface may decay, but frequently does not. An acquired fault of form requires notice.

Anatomically, the gum covers the cementum and the enamel margin. When recession of the gum occurs, the cementum is left exposed and food debris accumulates at the angle formed by it with the gum. Owing to the cementum being less smooth than enamel, microbic plaques readily collect, hence decay of the cementum frequently occurs, and is apt to progress rapidly, owing to the natural low percentage of inorganic matter (Figs. 321, 332, and 364).

Arrangement and Position of the Teeth.—The overlapping of one tooth upon another creates a form of contact, producing a tendency to decay at that point. Angle[1] claims to have observed a comparative freedom from caries of very irregular teeth (Fig. 335).

The presence of a supernumerary third molar, lying at the buccal side of the interdental space, between the second and third upper molar, or an inlocked bicuspid, very frequently causes approximal caries at the contact points. The upper third and lower third molars frequently stand in bad relation to the cheek or the gum.

Food collects upon their buccal surfaces, or they are not subjected to the friction of the tooth-brush, and decalcification of a broad area of a buccal surface frequently results.

Defects about Fillings.—Under the caption of Recurrence of Caries, will be found a list of the causes which perpetuate caries about fillings. Defectively cemented bands are also a cause. I believe the abundance of these and a lack of oral hygiene to be, in a large degree, the measure of a tendency to persistent caries. A patient has a large number of cavities due to a period of negligence, with consequent intensity of oral fermentation. If these are obliterated in the best manner with physically perfect fillings, and oral hygiene be exact, the tendency to caries is largely obliterated. If, on the other hand, a large number of even slightly defective fillings are made, not only is recurrent caries induced, but the caries ferment is continuously active, and exact oral hygiene is an impossibility. The number of cleansings a day is no guarantee of perfect hygiene, even with perfect teeth, as nothing is more common than to see unclean embrasures easily taking the stain of tincture of iodin even in the anterior part of the mouth (in less degree than shown in Fig. 321). Unquestionably, food debris may even be swept into the interdental spaces by brushing alone. Miller[2] has shown that a mixture of bread and saliva may become decidedly acid in one hour, and superficially decalcify sections of dentin in five hours. With this going on, day

[1] Dental Cosmos, 1903.

[2] Ibid., 1905.

after day, in cases of soluble teeth and without other aid than brushing, and often this not thoroughly done, the persistence of decay is not surprising. This, however, does not prove the absence of systemic susceptibility or immunity, as an added cause of caries or its absence. A condition similar to a defect about a filling, is that of the presence of an orthodontic appliance which may afford convenient nooks for caries, fungi, and food. In the use of base metal wires about teeth for pyorrhea, the wire either has some antiseptic, action probably due to the contained copper, or the pyorrhetic condition itself furnishes an alkaline element. In such case caries frequently does not occur.

Fig. 321

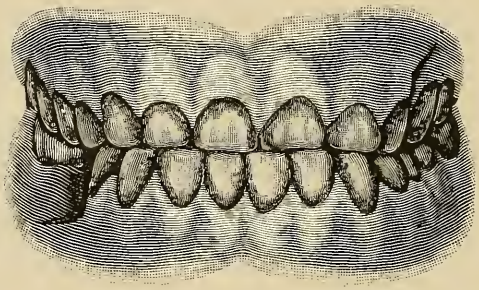

Caries of enamel about the cervices of many teeth, due to tenacious films collected upon them: at first probably neglected, later impossible to cleanse with brush alone. (Model by W. A. Capon.) Fairly clean teeth stained with iodin present such an appearance. (See prophylaxis.)

Structure.—While the structure of the enamel has no relation to the inception of caries, that is, teeth of poor structure may not decay, a roughness of the enamel surface, which often accompanies teeth of opaque appearance, may act as a favoring condition, and after inception of caries, inferior structure and possibly the presence of Caush's tubes may permit more rapid disintegration. (See p. 243.)[1] An interesting examination of 16,000 mouths, made in Sweden by Forberg (Stockholm), and others by Röse in Baden and Thuringia seems to show that there is a relation between the color (structure) of teeth and the presence of caries, the following averages

[1] This statement now made in two editions has been further experimentally confirmed by Pickerill (The Prevention of Dental Caries and Oral Sepsis, 2nd Ed.), who has shown by rubbing graphite upon the surface, what he terms "imbrication lines," which are associated with "calcarine" fissures in some teeth. Those teeth which contain many of the lines and fissures are termed "malacotic," while those but slightly imbricated are termed "sclerotic." By test, "malacotic" teeth were found more soluble in lactic acid solutions than the sclerotic (Ibid., p. 129). A similar result was obtained with hydrochloric acid. Malacotic and sclerotic teeth were both but little affected after insertion into an orange for a week but the malacotic were more affected (Ibid., p. 130). This fact is of importance in prophylaxis (which see). Carbon dioxid in strong solution was found to have no effect upon teeth (Ibid, p. 133).

of all ages being observed: White teeth, 14.3 per cent. of caries; yellowish-white, 16.4 per cent.; yellow, 20 per cent.; grayish blue, 24.3 per cent.

According to these observers,[1] in the regions in which the water was rich in calcium salts the individuals examined had the yellowish-white teeth. Miller's observations confirm this.

Gautier[2] has found that in young pigs, deficient osseous development corresponded exactly to the lack of calcium salts in their drinking water.

Black[3] made analyses of so-called hard and soft teeth, and deduced from them the opinion that the hardness and softness of teeth have nothing to do with the inception of caries.

Touching this point, Black[4] instances the case of a man whose enamel had always been chalky and as easily cut as a slate-pencil, yet who had little caries of the teeth. That some teeth of apparently poor structure and defective form do not decay is also a fact of common observation, but, as a rule, they go together.

These observations, together with the foregoing data, regarding the inception of caries, point to the now conceded conclusion that the caries of teeth is entirely due to the environment of the teeth, and in no sense does it arise from within the tooth, and that in so far as the cause is active, it is a question of the localization of the exciting cause or its factors on the one hand, and the solubility of the teeth on the other; and that no amount of cause is sufficient to produce it, unless permitted to exert its effect upon special points upon the teeth; in other words, it requires localization and time to act, though it may in some cases be broadly localized.

Other Local Predisposing Causes.—Acids taken in excess into the mouth may act as predisponents by causing a roughness of the enamel, which invites the formation of the bacterial plaques. A course of tincture of ferric chlorid has a bad reputation in this connection. In the cases observed by the editor, the hydrochloric acid in the tincture seemed to have formed roughnesses between the teeth, and many large cavities of not unusual form were later produced and evidently due to the carious process. Weld,[5] in a series of experiments to determine the action of ferric chlorid, found that the pure tincture had little effect, while in the dilution of 1:5 in water it had much; destroying the entire enamel in twenty-four hours. Head's observations on the effect of dilute acids are in general accord with this principle (see p. 314). This fact indicates the prompt

[1] Dental Cosmos, 1911. [2] L'Odontologie, October, 1910. See Cosmos, 1911, p. 242.
[3] Ibid., 1898. [4] Ibid.
[5] Quoted by Prentiss, Dental Cosmos, September, 1912, p. 1006.

local use of an alkali after a dose. (See Prophylaxis of Caries.) Howe[1] claims that iron, whether as chlorid or carbonate, taken in capsules, returns to the salivary gland for excretion as ferric chlorid and may exert injurious effects.

Morjenstern[2] describes experiments that show that acid iron waters or tinctures have a decalcifying action, ferrous iodid and ferric chlorid being particularly injurious, while reduced iron, saccharated solution of iron, and albuminate of iron produced no ill effects either local or through systemic action.

The acid vomitus of pregnancy and seasickness have an analogous effect. It is not likely, however, that during a transatlantic voyage large cavities can develop. The probable explanation of the presence of such cavities directly after the voyage is that they existed before the voyage was begun. Cavities are frequently left or overlooked. (See Prophylaxis of Caries.) Since the advent of medication by lactic acid preparations and those containing lactic acid bacilli, such as sour milk, analogous effects have been observed, and therefore the mouth should be washed out with alkaline antiseptics after such remedies are taken.[3]

Miller found that the saliva has no antiseptic quality as a whole and contains no antiseptic substance, and though he found the saliva of immunes to develop a little less acid than that of highly susceptible individuals, the difference was not constant and not sufficient to account for the marked difference in susceptibility. Miller found that carbohydrate foodstuffs mixed with an alkaline saliva became even more acid than when the reaction of the saliva was intensely acid and the chance for caries was about the same with either reaction at the start. Goadby[4] calls attention to the demonstration of Savarelli that saliva is germicidal for small quantities of bacteria but loses its property with large quantities. This may have some bearing on caries.

Under conditions of oral irritation, such as catarrhal stomatitis, or even the presence of many cavities of decay, a stringy, mucinous condition of the saliva may result. This may be due to a partial coagulation of the mucin by the acid present in the mouth, and the coagulum may entangle food masses and cause their adherence to the teeth.

Lack of Saliva of Alkaline Potential.—Pickerill,[5] in exhaustive experiments, shows that a continuous flow of saliva may be reflexly

[1] Dental Cosmos, January, 1913, p. 39.
[2] Therapeutische Monatshefte, 1908.
[3] Vanel, Dental Cosmos, 1904, p. 694.
[4] Mycology of the Mouth.
[5] The Prevention of Caries and Oral Sepsis, 2d Ed.

excited by foodstuffs having taste and flavor, and especially by organic acids of fruit, and argues that such alkaline saliva by flowing over teeth neutralizes any acid formed by fermentation. *Per contra*, its absence may be a cause of caries. The argument looks rational, but Pickerill has not given any experiments upon susceptible individuals to prove his case.

Very dry mouths have a viscid, tenacious saliva, and usually cervical caries is present. Some individuals are greatly inconvenienced and may have to frequently moisten the mouth to obtain comfort.

The contention of Lohmann that the carbohydrate element in mucin was the cause of caries, Miller examined experimentally and found it untenable, but that the explanation here given of its entangling action is the probable one. He states that very small amounts of lactic acid precipitate the mucin and thus enable the bacteria to become fixed to the teeth as plaques.

Miller has noted that some immunes have had exceedingly ropy saliva which could be drawn out into long threads, while much caries was noted in the mouths of some almost absolutely free from mucus.

Miller could find no antiseptic quality in the saliva, nor any principle corresponding to alexin, and found that bacteria developed in the saliva of immunes almost as readily as in that of those susceptible to caries.

He also pointed out that the mucus may readily undergo putrefactive fermentation with alkaline reaction, and, again, the carbohydrates entangled in it will ferment with acid reaction, causing any caries which might be attributable to mucin fermentation. Gies[1] has shown that salivary mucin forms viscid films on the teeth, which tend to thicken by accretion and in which millions of bacteria multiply, particularly at night, when the secretions are strongest.

It is possible that the secretion from the gum may in some cases be acid and favor the production of caries by decalcifying the enamel about the cervix (Fig. 321).

Cook has shown that glycogenic infiltration of the oral mucous membrane may be produced by the use of irritant or astringent washes, which may possibly permit a change of this substance by bacteria into acid about the necks of teeth, accounting for a certain form of cervical decay long thought to be due to an acid mucus. (See Glycogenic Infiltration.)

[1] Journal of the Allied Societies, June, 1912.

Systemic Predisposing Causes.—Some individuals seem to suffer much from caries; others in less degree. In either case, periods of immunity or comparative immunity may be established, and may be again followed by a period of susceptibility and a succeeding immunity.

These facts point to the conclusion that a period of caries is due either (1) to a temporary lack of oral hygiene with a corresponding intensity in oral fermentation—*i. e.*, the exciting cause is active—or (2) that it is due to some systemic condition which changes the constitution of the oral fluids, permitting the formation of the microbic plaques upon the teeth, or (3) increases the fermentation by supplying some element nutritive to bacteria or (4) depriving it of some element inhibiting the growth of bacteria.

Black has shown that caries fungi are always present in the mouth, but do not always form the plaques. Cases also exist in which caries has begun during some period of susceptibility and a number of new cavities have been started. Later a period of immunity has followed and the cavities have not progressed.

So far as classed, systemic conditions influencing susceptibility and immunity may be placed under the four headings: Heredity, Prenatal and Postnatal Influences, Age, and Bodily Condition.

Heredity.—Black[1] records observations on certain families as showing a tendency to caries of certain teeth at a given age, or in certain positions upon the teeth, *e. g.*, occlusal pits. In certain cases the hereditary tendency persists. This tendency must be due either to an inherited cell physiology, or diet tendency influencing the oral fluid, or to transmitted faults of form or, possibly, of structure of the teeth.

Prenatal and Postnatal Influences.—It is quite probable that the systemic condition of the mother during gestation may profoundly modify the anatomicophysiological condition of the body cells of the child; nutritional processes may suffer and the postnatal tooth development proceed irregularly, structure being affected; moreover, the altered biochemical function of the cells may stand in close relation to the constitution of the oral fluids, and these in turn may favor the development of caries fungi. If, therefore, the mother is not properly nourished, the teeth may not be well constructed, especially if lime be lacking in her food. The same line of argument may be applied to bottle feeding of recently born infants, or to other conditions profoundly affecting general nutrition. In this connection, the absence of the influence of the internal secretion

[1] Dental Cosmos, 1904.

which should be transmitted from mother to child by way of the milk, may in the future be shown to have a bearing upon cell development and consequently upon the product (as the enamel).

In an examination of school children, Th. Frick[1] (Zurich) found a much greater percentage of decay in children that had been bottle-fed at between three and six months of age. He performed an experiment on a litter of six dogs, feeding three on cows' milk and bouillon; one of them died, and the others had poorly developed teeth. The controls were normal.

Forberg and Röse[2] have shown that the individuals who drink water rich in calcium salts have a smaller percentage of caries than those drinking soft waters. Ferrier has observed a coincidence of caries and the drinking of boiled water which had been deprived of calcium carbonate. Whether this effect is due to a better development of tooth structure or is a post-developmental effect is not stated in either case. The point brought up by Head,[3] who has shown the apparent rehardening of teeth in saliva after partial decalcification by a weak acid, opens up the question here as to whether the use of calcareous waters after tooth eruption can increase the density of enamel. Enamel can be dried, why then not infiltrated by calcareous solutions? The question cannot now be answered. Another view might be that some of the calcium salts in drinking water come back to the saliva eventually, and if abundant may neutralize the acidity in plaques, through their alkalinity, by combining with the acids formed.

Age.—That the age has an influence upon caries was noted by Flagg. He recorded the ages from five to eight, twelve to twenty, thirty to thirty-five, forty-five to fifty, sixty to sixty-five years, and senility as periods of decay, while the intervening periods were intervals of comparative exemption.

Black has noted that caries is a disease of youth, most intense before adult age, at which time immunity is established, provided the teeth have been well and promptly filled and the mouth otherwise cared for. In view of this fact, he aims at establishing this immunity by close attention to the teeth during youth.

He records fluctuations in susceptibility not unlike those recorded by Flagg, and also points out that some persons pass through the ordinary periods of susceptibility and first develop caries in middle age. In old age, general recession of the gum is common, and in the conditions of debility associated with old age, much caries of cementum occurs. The patients are often either unwilling or unable to keep the cementum cleansed.

[1] Dental Cosmos, 1901. [2] Ibid., 1899. [3] See p. 315.

Repeated examinations of the mouths of school-children show a deplorable amount of caries which may, perhaps, be attributable to several causes, such as the induction of a lessened systemic resistance due to confinement, study, etc., and also to the inhalation of vitiated air, which presumably also contains acid-producing bacteria. Moreover, bacteria of caries may be directly transmitted by kissing, common use of drinking cups, pencils, etc.

Michaels,[1] of Paris, has observed that "the saliva of adolescence contains a dextrinic principle (glycogen) susceptible of fermentation under the influence of ptyalin in the presence of earthy salts. Lactic acid is formed." (See p. 98.)

Bodily Condition.—It is a matter of observation that such conditions as pregnancy, typhoid fever, anemia, leukemia, diabetes, dyspepsia, nervous exhaustion, and debility are frequently accompanied by or followed by a development of cavities of decay, but whether the diseases themselves or a coincident lack of oral hygiene act to permit the formation of the microbic plaques has not clearly been made out. If oral and dental prophylaxis be practised during typhoid fever and convalescence therefrom, the production of cavities is much limited, but this does not prove anything.[2] The same is true of pregnancy, which introduces an exciting cause (the vomitus), and of glycosuria, which may introduce glucose, or a fermentable substance as claimed by Michael,[3] according to whom it takes a red coloration with Nessler's reagent, which passes into a grayish blue. Black contends that periods of susceptibility are noted both in apparent good and ill health. That apparent health may really not be true health is a matter that must be considered.

This bodily condition is seemingly the key to any change which can occur in saliva, or mucus, or oral phagocytosis, to one of which must be attributed any possible systemic effect upon caries bacteria, which can aid or inhibit their growth or localization. It matters very little whether the bodily condition is due to heredity as a general modification of cell physiology, to age, or some period of stress, as the "change" of the teeth, puberty, growth during adolescence, diet, business or family anxieties, the degenerative tendencies of advancing age, or to some more acute systemic condition, as typhoid fever, diabetes, etc., except in so far as these conditions may introduce into the oral fluid a substance which may act either (1) as a

[1] Sialosemeiology. See Dental Cosmos, 1900.

[2] A caries susceptible was treated before pregnancy and during lactation for many cavities. The value of prophylaxis was finally so impressed upon her that she practised it properly. Since then she has had typhoid fever, but no increase in caries; which amounts only to about one small cavity a year.

[3] Quoted by Kirk, see Dental Cosmos, January, 1914, p. 5.

direct decalcifying agent (an acid) or (2) as an indirect decalcifying agent, by furnishing a food material for the bacteria from which they may manufacture acid (a carbohydrate), or (3) furnish a substance in the saliva which may glue the germs to the teeth, or (4) take from the saliva some substance which normally inhibits plaque formation.

It was shown under the caption of Erosion, that a very weak acid may decalcify more rapidly than a stronger solution, and it has been noted that in systemic conditions inducing general acidosis (as chronic nephritis or diabetes) there is a tendency to deep decalcification of cervices of teeth, beginning particularly upon the cementum. While by no means proved not due largely to fermentation of carbohydrate food by bacterial plaques, as a result of defective hygiene, there is, nevertheless, a strong suspicion that the acidosis expressed as acidity of saliva has produced the decalcification. There is also a probable reduction in the amount of normal sodium phosphates as the result of the general acidosis, and this also found in the saliva reduces the controlling quality, which Head has shown to exist when a certain percentage of basic sodium phosphate is present in solutions having an acid reaction. (See p. 315.) On the other hand, in such a condition as diabetes there is not only a general acidosis, but also the possible transudation of a glycogenic principle into the saliva, which can undergo acid fermentation by oral bacteria.

Michaels[1] states that the constitution of the saliva changes with the establishment of various diatheses, and that a physiological saliva with the biochemical principles in a state of equilibrium is probably very rare. He states that the most active dental caries is found in the mouths of hypo-acid individuals, in whom saline chlorids predominate over the acid elements of metabolic waste, reducing the acidity of body fluids below normal, and inducing a lessened resistance to development of infective causes, and that caries is least active in the hyperacid individuals, in whom sulphocyanid of potassium is more abundant in the saliva. He has also claimed to have found glycogen in the saliva of adolescents. (See pp. 98 and 358.)

Kirk[2] claims that in the caries susceptible, the saliva is alkaline to litmus, though it may be acid to other reagents (may be amphoteric). That the alkalinity keeps the mucinous elements in solution, and at the same time a substance analogous to glycogen and fermentable by caries bacteria is transuded by the salivary glands, which furnishes the bacteria their pabulum after their fixation in plaques upon the teeth. He regards this glycogenic principle in the

[1] Dental Cosmos, December, 1900.
[2] Items of Interest, July, 1902, p. 546.

saliva as due to carbohydrate diet in excess of the body's needs and its capability of storage as fat; that it enters the blood after the glycogenic function of the liver has been exerted and is excreted in the saliva. He regards the variations in susceptibility as due to variations in carbohydrate diet.

In a recent article,[1] the possible influence of the hypophysis cerebri upon the presence of an excess of sugar in the blood and of this as a possible explanation of caries susceptibility, is treated of by Kirk, who, however, disclaims any definite finality at present.

Pickerill argues that as glycogen is rapidly converted into maltose and iso-maltose by ptyalin, glycogen and ptyalin should be chemically incompatible. He states that in his examination of the saliva of diabetics and those suffering from other disease, no sign of glucose has been present. The question therefore calls for investigation of saliva from the glands direct, to avoid mouth glucose.

Gies,[2] conducting elaborate experiments concerning the inhibitory effect of potassium sulphocyanate upon plaque formation, concludes that it is an excretion having no determined bearing upon caries. Both he and Howe[3] found experimentally that it did not inhibit bacterial growth in cultures. Howe considers it increases the growth. Pickerill[4] seems to have found a different conclusion. The Committee on Scientific Research of the New York State Dental Society furnish the following tests for it:

Take 2 c.c. of saliva, to which add 2 c.c. of distilled water, and shake thoroughly together. Add 5 drops of iron perchlorid, and shake again.

The presence of sulphocyanate naturally in the saliva is determined by the color.

A straw color indicates little or none. A brick color indicates a sufficiency. A wine color indicates abundance.

The Committee on Scientific Research, of the National Dental Association,[5] have devised a colorimetric scale which consists of two tubes. In tube A, 1 c.c. of saliva is placed. In tube B, 1 c.c. of a 1 to 2000 solution of sulphocyanate of ammonia. To each, add 2 drops of a 5 per cent. ferric chlorid solution from the same pipette. Add distilled water; to be in definite quantities until the color matches that of the saliva. Calculation of the dilution of the standard solution will give the amount of sulphocyanate in the saliva. The observations are introduced, that others may continue the line of thought.

[1] Dental Cosmos, January, 1914.
[2] Ibid., 1913.
[3] The Journal of The Allied Societies, June, 1912.
[4] The Prevention of Dental Caries and Oral Sepsis.
[5] Dental Cosmos, 1908, p. 1365.

The use of potassium or sodium sulphocyanate internally in $\frac{1}{4}$ to 1 grain doses, in tablet form, has been recommended as a prophylactic, but while some claim value it is quite likely that other means, such as oral prophylaxis conjoined with it, have had much to do with lessened caries and hypersensitivity of dentin, as claimed.

Potassium sulphocyanate is described as a nerve tonic, safe in even 10 grain doses. *It must not be confused with potassium cyanate, which is a virulent poison.*

Kirk has succeeded in altering viscid saliva to a more limpid condition, by reducing the ratio of carbohydrate to proteid diet, first cutting out carbohydrates almost altogether, then adding them gradually to the diet. He cites observations upon asylum children kept upon well-balanced rations, as having large numbers of arrested caries.[1] (See p. 359.)

Black[2] believes that the condition of the system alters the oral fluid, so as to permit the bacteria in it to produce a gelatinoid material as a by-product, in one case and not to produce it in another, and that when produced, plaques adhere to the teeth in sheltered spots, while when not produced no plaques adhere, though a general acidity of the oral fluids may be produced.

Miller,[3] some years ago, pointed out that filthy mouths often do not contain carious teeth. He offered the rational explanation that the unchanged adhering collections, once their acid-producing capacity is destroyed, can even act as a protection in so far as caries is concerned. In experiments on artificial production of caries, Miller found that the pabulum of the bacteria needed constant change, otherwise putrefaction resulted and decay ceased. The fact that fairly cared-for mouths often contain carious teeth is rather an argument in favor of the local etiology of caries, as teeth unbrushed after a meal, or, rather, not thoroughly cleansed, as is the rule in a vast majority of mouths, contain every necessary factor of caries, including a renewal of fresh carbohydrate food for the bacteria. As prophylaxis becomes more accurate, mouths usually pass into a condition suggesting a condition of immunity. It would seem, therefore, that unless some other factor of prophylaxis can be introduced, the mouth should either be thoroughly cleansed or not at all, so far as caries is concerned.

The whole subject of susceptibility and immunity to caries is yet obscure and requires accurate experimental study.

[1] Dental Brief, 1907.
[2] Dental Digest, 1907.
[3] Lecture at the University of Pennsylvania.

CHAPTER XII.

DENTAL CARIES: PATHOLOGY, MORBID ANATOMY, AND CLINICAL HISTORY.

PATHOLOGY AND MORBID ANATOMY.

It is a fact of common observation that caries begins only at spots protected from friction or uncleansed. These are in order of frequency: (1) Pits, grooves, and fissures in the enamel; (2) approximal surfaces just above the contact point; (3) smooth surfaces which

Fig. 322

Fig. 323

Fig. 324

Fig. 325

Fig. 326

Fig. 327

Fig. 328

Fig. 329

Fig. 330

Fig. 331

Fig. 332

Fig. 333

Fig. 334

Fig. 335

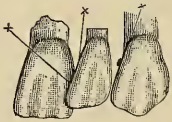

from any cause are habitually unclean; (4) necks of the teeth at or near the junction of the cementum and enamel (Black) (Figs. 322 to 335).

In these situations Williams has demonstrated the fact that the oral bacteria, protected from friction, attach themselves to the

enamel, forming microbic plaques which are sufficiently adherent to permit their retention during the grinding of the specimen for microscopic examination. (See Figs. 336, 337, and 338.) Carbohydrate food debris lodges at the points at which retention is favored, and either ferments directly against the enamel, or through the medium of the microbic plaque.

The bacteria in the plaque require food and obtain it from the carbohydrate and albuminous materials which come in contact with them. From the carbohydrates lactic acid is produced as a waste

FIG. 336



Section of normal human enamel, showing thick, felt-like mass of microörganisms slightly raised from the surface of the tissue, by pressure of the cover-glass in mounting. × 250. (Williams.)

product. (See Chapter XI.) Williams states that it is "highly improbable that the enamel is affected, except in rare and special instances by any other acid than that which is being excreted by the bacteria at the very point at which they are attached to the enamel."

This thick mass of fungi also prevents the excreted acid from being washed away, so that it exerts its full chemical power upon calcific tissue.

The lactic acid produced attacks the inorganic matter of the

enamel, following first the interprismatic cement substance between the prisms, later dissolving the transverse cement substance between the globules. The effect is to produce an irregular, roughened surface of the enamel and to bring into view the structure of the rods (Figs. 337 and 343).

Fig. 337

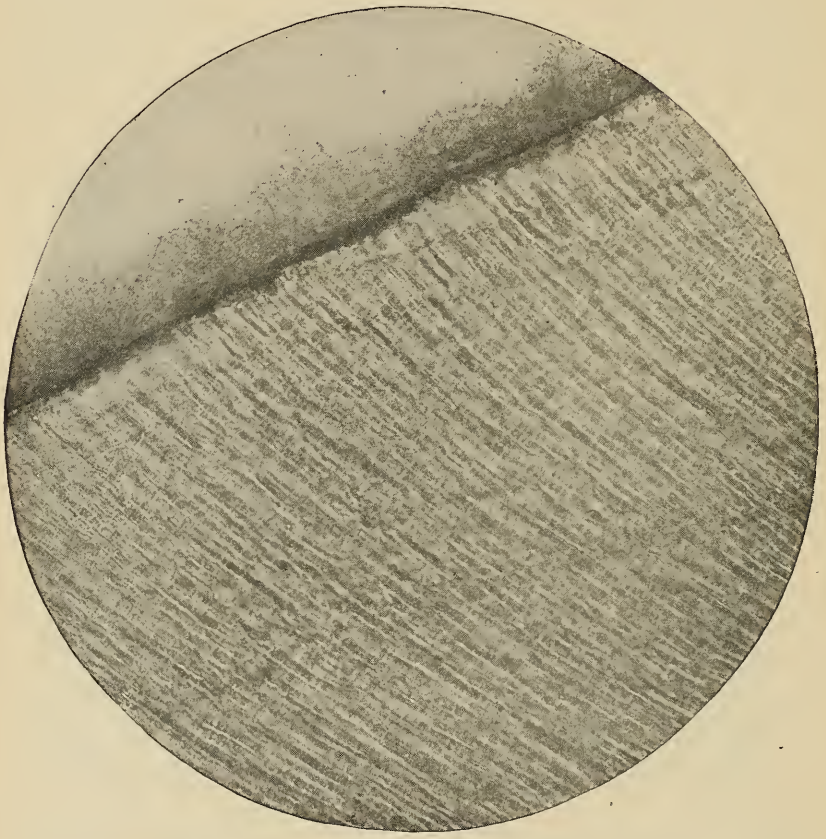

Microörganisms of caries attached to enamel on approximal surface of tooth. (Williams.)

The gradual loss of cement substance unbinds the enamel globules, which are in turn dissolved and washed away, leaving a depression or cavity.

In the process of enamel dissolution, the bacteria may enter the crevices formed by solution of the interprismatic cement substance, and by repetition of the process gain access to the dentin (Fig. 346).

The form of the enamel may be retained until and even after decalcification has reached the dentin. Clinically, this is seen as an

FIG. 338

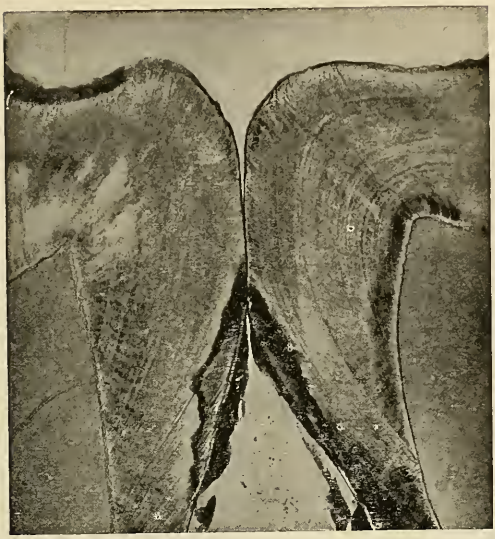

Superficial approximal caries of enamel with films; also shows slight approximal abrasion. (Miller.)

FIG. 339

Budding of spores on the stems of Leptothrix racemosa. (Williams.)

opaque white or discolored spot, resisting the instrument until some force is used, when it rapidly breaks down (Figs. 338 and 347).

A central cavity, or several minute openings, leading to or almost to the dentin, is sometimes seen in the general decalcified area. It signifies the loss of the organic matter of the enamel, by unbinding or

Fig. 340

Thick growth of Leptothrix racemosa fructification heads from approximal surface of tooth, under high magnifying power. (Williams.)

peptonizing actions. The extraction of an approximating tooth permits the film to be rubbed off, or prevents the retention of carbohydrate media, so that the bacteria cease to be active, and this spot may remain indefinitely at this point—*e. g.*, the disease is arrested. It may cease spontaneously to develop further, owing to the establishment of an immunizing systemic change, even though the teeth

FIG. 341

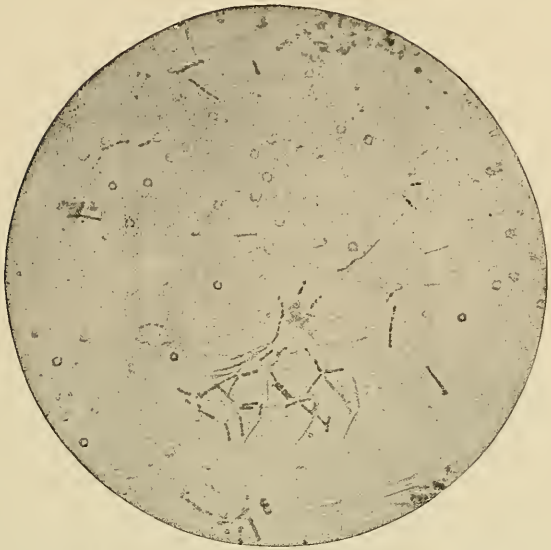

A form of streptococcus found abundantly in mouths where very rapid decay of teeth is in progress. × 750. (Williams.)

FIG. 342

Scrapings of microörganisms from the approximal surface of a decaying tooth: shows the Leptothrix buccalis maxima and the Bacillus bucallis maximus of Miller. × 1500. (Williams.)

remain in approximation, and strict prophylaxis will usually arrest the advance of the process.

It is also noted clinically and microscopically that the decalcification is deepest at a spot just above the point of contact, and less deep at points buccal or lingual, occlusal or cervical, to this spot, and still less at points more buccal or lingual—*i. e.*, it shades off to zero lingually, buccally, occlusally, and cervically (Fig. 347). The dentin may in such cases be deeply affected. Bacteria growing in the spaces from which the interprismatic cement substance has disappeared, causes detachment of masses of partially decalcified rods (Figs. 346 and 348).

Fig. 343



Section through human enamel, showing first stages of caries, *i. e.*, solution of interprismatic cement substance. To be compared with Fig. 177. (Williams.)

When the entire thickness of the enamel is penetrated and the dentin attacked, there is a change in the mode of progress of the decalcification, which proceeds along the line of union between the enamel and dentin, as well as directly into the dentin (Fig. 347); in this way the enamel is attacked from its dentinal side (backward caries) (Fig. 345).

In the ultimate breaking down of the enamel the rods first separate; the outlines of the several globules of which the rods are composed are brought into plain view; next, the calcified plasmic strings noted in enamel formation become evident; and finally, the bead-like masses upon these strings are left as the ultimate granular detritus of the enamel.

In cases of rapid enamel dissolution, Williams found streptococci almost invariably present; and suggests tentatively that the variety of organism may be the factor governing the rapidity of dissolution (Fig. 341). (See Miller, p. 344.)

FIG. 344

Section of human bicuspid, showing commencement of caries: *a* and a^1, appearances caused in enamel and dentin by the acid of decay; *b* and b^2, shreds of a felt-like mass of bacteria raised from the surface of the enamel; *c*, a cavity. × 12. (Williams.)

These are probably the Streptotoccus brevis, of Goadby (Micrococcus nexifer, of Miller).

Williams found Streptococcus pyogenes albus and aureus and Sarcinea lutea to be acid producers.

The large cocci and diplococci shown in Fig. 349 were always found in the secondary decay of enamel.

"In the direct caries of enamel, the cavities are lined with leptothrix and thread-like forms."

"The Leptothrix buccalis maxima and the Bacillus buccalis maximus, of Miller, are nearly always found, the latter more sparingly" (Fig. 342).

Fig. 345



Section of carious tooth, showing appearances of decay in enamel and dentin at the line of union of these tissues; the dark spots shown in the enamel and dentin are masses of microörganisms. × 250. (Williams.)

Fig. 346

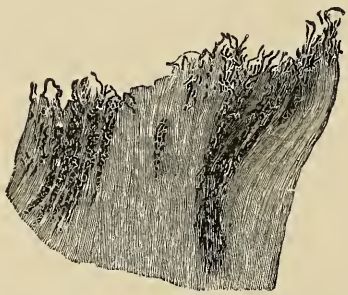

Penetration of bacilli between enamel prisms after solution of interprismatic cement substance. (Miller.)

Some of these bacteria are not acid producers, and it may be that if a film is composed entirely of these, they may occupy a field and really protect it by excluding acid-forming bacteria.

"Beneath the felt-like masses of thread forms, and lying in contact with the decomposing enamel in direct decay, and also in deep cracks and fissures in secondary decay, there is invariably found a short, thick bacillus, usually constricted in the centre." (Williams, also Goadby.)

FIG. 347



Decalcification of enamel without loss of form; *a*, film. × 35. (Miller.)

Caries of Nasmyth's Membrane.—Miller[1] demonstrated that the enamel cuticle may act as a breeding ground for many forms of bacteria which occupy it, forming a matrix which may retain minute particles of food, which in turn aid in acceleration of the progress of decay (Fig. 351).

Caries of Dentin.—The bacteria, after penetrating the substance of the enamel, attack the dentin. This presents a different anatomical and chemical structure to be acted upon. Beneath the enamel, the first layer of dentin is of a composition which permits the bacteria to rapidly spread laterally along this zone. They also enter the

[1] Microörganisms of the Human Mouth, 1890, and Dental Cosmos, 1900.

tubules of the dentin, and penetrate by multiplication, toward the pulp. A wedge-shaped area of decay is produced (Figs. 347 and 353).

In all cases decalcification precedes these invasions. At the periphery, the tubules communicate freely by their lateral branches (Fig. 352), and the lateral spreading of the bacteria by multiplication is readily explained.

FIG. 348

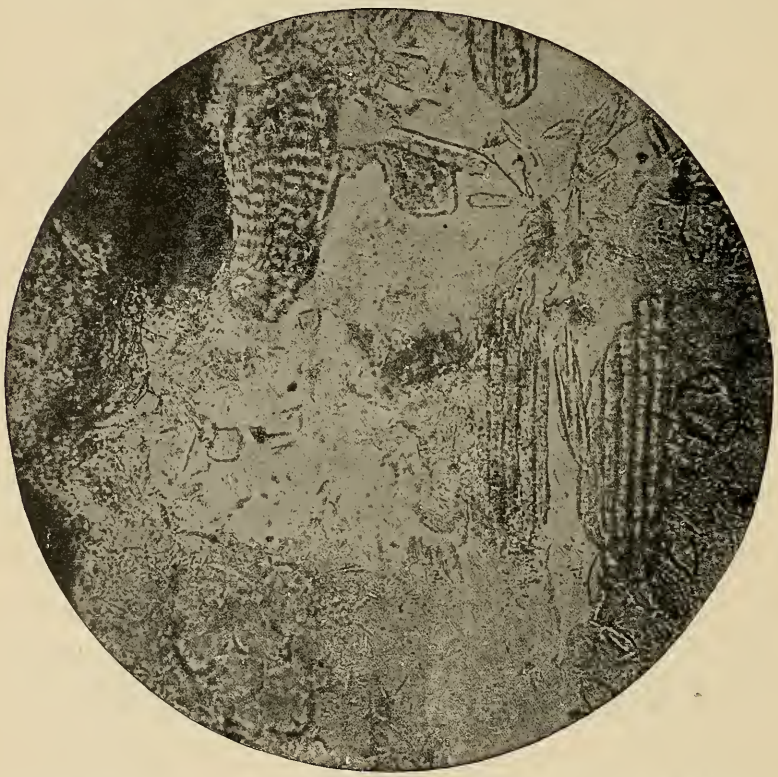

Cover-glass preparation from scrapings of white, opaque, decaying enamel; the cement substance between the rods is seen to be dissolved away, and the crevices thus formed are filled with round and oval forms of micrococci and bacteria. Stained by the Gram method. × 450. (Williams.)

It is seen clinically in caries, that a portion of the dentin is absolutely destroyed and removed, leaving within the tooth a "cavity of decay," bounded by dentin and enamel undergoing disintegration; beneath this lies dentin less affected, and beneath this, sound dentin (Fig. 353). These phenomena require explanation.

The tubules of the decalcified dentin become packed for a distance, with bacteria (Fig. 354). These act upon the organic matrix of the decalcified tubule walls. The internal pressure due to multiplication

FIG. 349

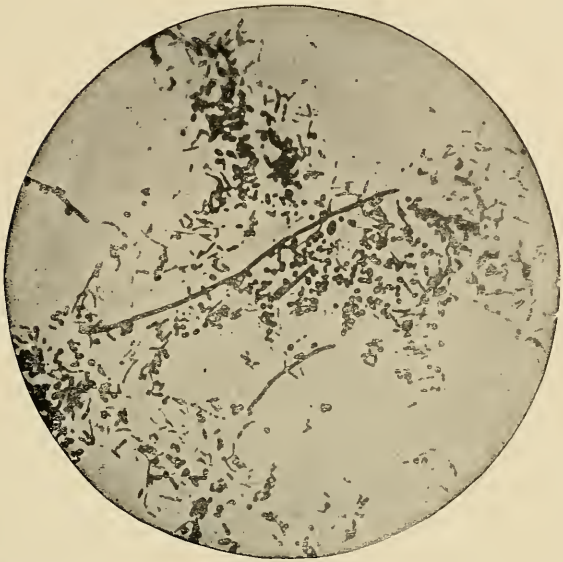

Various forms of micrococci and bacteria from decaying enamel. Photographed by Mr. Andrew Pringle from Williams' cover-glass preparation. × 1000. (Williams.)

FIG. 350

Cover-glass preparations of scrapings from decay of enamel; shows Leptothrix bucallis maxima and Bacillus bucallis maximus, of Miller. Stained by Gram method × 830. (Williams.)

distends them so that the lumen is enlarged. At the same time, the bacteria excrete a ferment or ferments which cause the wall at first to thicken. The dilatation and thickening together cause the com-

Fig. 351

Enamel cuticle permeated by bacteria. (1100 to 1.) (Miller.)

Fig. 352

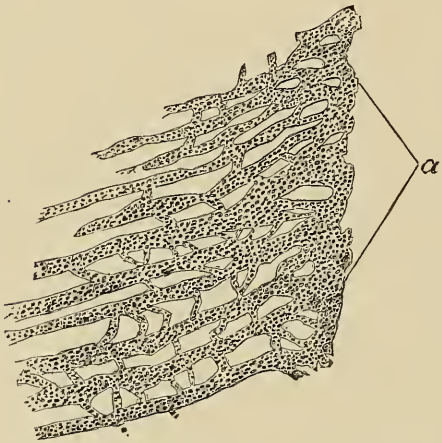

Carious dentin, stained with fuchsin to show microörganisms. The section shows the condition of the tubules as filled with microörganisms along the junction of the dentin with the enamel at *a*. The tubules are very much enlarged. (1/10 immersion objective.) (Black.)

pression of the decalcified intertubular substance, and the tubules assume an hexagonal shape owing to the mutual pressure (Fig. 355). The phenomenon is not a vital one, as it occurs in artificial caries. (Miller.)

The bacterial ferment possesses a digestive or peptonizing power, analogous to trypsin, and begins to liquefy the inner surface of the tubule wall. As it does so, the lumen is further increased and the

FIG. 353

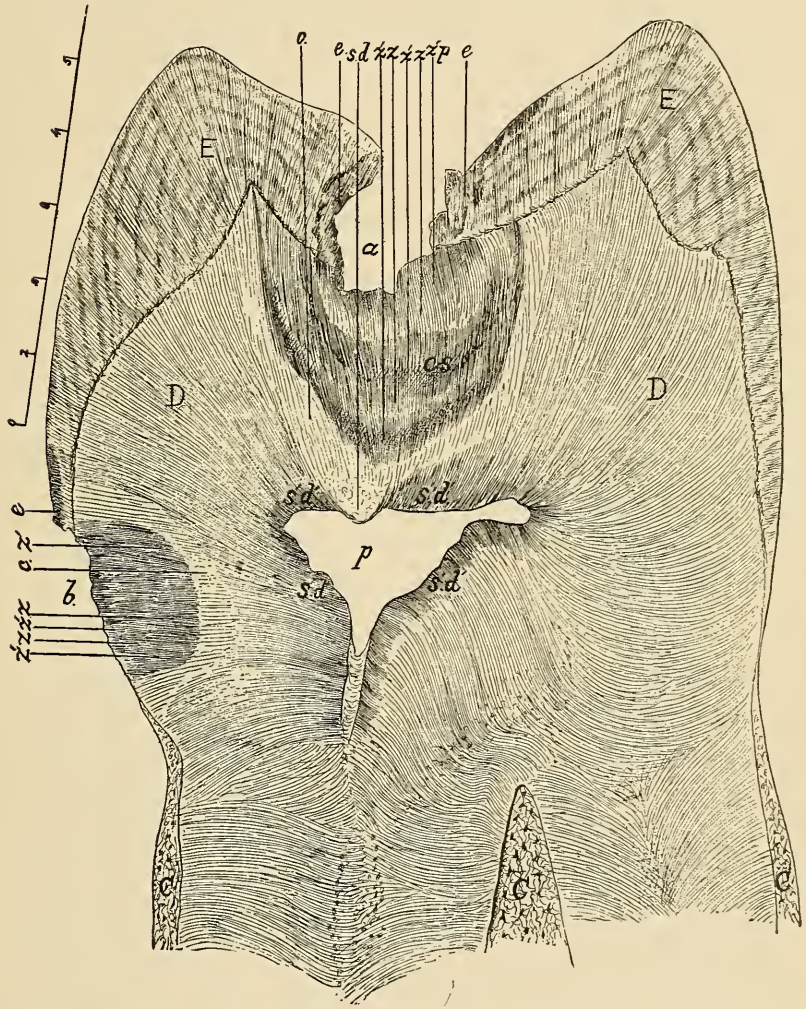

Longitudinal ground-section through the crown of an inferior molar of a negro: *E*, enamel; *D*, dentin; *C*, cement; *p*, pulp chamber; *a*, large decay, from the occlusal surface; *b*, small decay, from the mesial surface; *c s*, cone of septic invasion and discoloration; *e*, partially decalcified and discolored enamel around the carious cavity; *z*, dark cones; *z'*, clearer cones; *z' p*, oldest cones where putrefaction of the tooth cartilage begins; *c*, outer transparent zone, or zone of Tomes; *s d*, secondary dentin, caused by irritation; *s' d'*, secondary dentin deposited by normal physiological process, recession of the pulp. This figure is drawn from a ground and polished section mounted in Canada balsam. (Gysi.)

bacteria fill the acquired space. Taking up carbohydrates, lactic acid is produced, which combines with the calcium salts of deeper tubules and intertubular substance and prepares a path of decalcified tissue for bacterial advance (Fig. 356). This decalcified tissue, to all intents and purposes, becomes a culture medium.

Fig. 354

Carious dentin, showing invaded tubules and uninvaded but decalcified intertubular substance. (Miller.)

Fig. 355

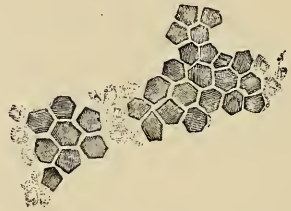

Cross-section of decayed dentin: the tubules through reciprocal pressure have assumed the shape of five- and six-sided prisms. (Miller.)

This combination of the acid with the calcium salts disposes of or neutralizes the acid, which, if accumulated to the strength of

Fig. 356

Section of decalcified dentin partly invaded by bacteria: *a*, uninvaded zone. (Miller.)

2 per cent., would cause the destruction of the bacteria, by their waste products. (Miller.) Calcium lactophosphate, calcium lactate, and magnesium lactophosphate are produced. This point has been

illuminated by Pickerill,[1] who placed teeth in a definite quantity of a known solution of lactic acid. This at first decalcified the teeth rapidly, but after thirty days, fresh teeth placed in the solution for twenty days were barely affected thus showing an exhaustion or neutralization of the acid.

Miller experimentally found that the calcium carbonate does so neutralize the acid formed by formation of calcium lactate, but

FIG. 357

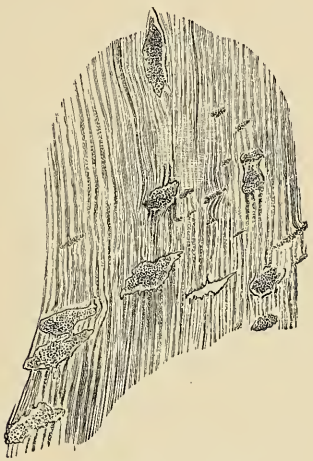

Liquefaction foci. (Miller.)

FIG. 358

Decayed dentin showing a mixed infection with cocci and bacilli. × 400. (Miller.)

the calcium phosphate does not, as it develops calcium lactophosphate, setting free phosphoric acid, which maintains the relative acidity. Experimentally, the addition of calcium phosphate to a solution of lactic acid did not reduce the decalcification in pieces of dentin placed in it, for the reason named. Howe[2] determined by experiments 'that a slight increase in phosphate produces great activity of bacteria in a starch or sugar solution, with large and rapid formation of acid.' That this is true also of the alcoholic fermentation (yeast) and in milk. The presence of chlorids he found to restrain fermentation.

The bacterial ferments continue to digest the wall of the tubule, and a time arrives when they have penetrated its substance. The intertubular substance is then removed in like manner. The same

[1] The Prevention of Dental Caries and Oral Sepsis, 2d Ed., p. 22.
[2] The Journal of The Allied Societies, June, 1912.

process occurring in adjoining tubules as well, the entire dentinal substance in the particular area at the cavity surface is destroyed—*i. e.*, liquefied and washed away (Fig. 353, *a*). A cavity results.

Occurring at a point beneath the general cavity surface, the bacteria in several adjoining tubules destroy their walls and the intervening intertubular substance, forming what Miller has called a "liquefaction focus" (pl. foci) (Fig. 357). This action proceeds until the enamel is undermined and the pulp is exposed. A decalcified area always exists in advance of the tubule invasion, sometimes large masses being found, though it lessens in quantity as the pulp is approached. As the enamel is undermined by the carious process, the bacteria and their acids decalcify its inner surface, the process proceeding from within outward, and termed "secondary caries," or "backward caries," of enamel (Fig. 345).

The enamel is thus weakened and at the same time deprived of dentinal support, and breaks down under stress of mastication.

Any interglobular spaces in the dentin being filled with transitional or uncalcified material like the tubule walls are rapidly invaded by the bacteria during their progress along the tubules (Fig. 359).

The character of the organisms in the tubules and the nature of the liquefaction seem to depend upon the particular germs present.

Miller has shown that in the deeper portions of tubules micrococci appear to predominate over the rod forms, which are also present; although one tubule may be filled with cocci and its neighbor with rod forms (Fig. 358). It is only in the more superficial layers that the thread forms are found in numbers.

Goadby[1] has done much interesting work in this direction, and offers the following classification of bacteria found in decayed dentin:

BACTERIA OF DENTAL CARIES.

Acid-forming Bacteria.

Streptococcus brevis	Deep layers of carious dentin.
B. necrodentalis	
Staphylococcus albus	
Streptococcus brevis	Superficial layers of carious dentin.
Sarcina lutea	
Sarcina aurantiaca	
Sarcina alba (Eisenberg)	
Staphylococcus albus	
Staphylococcus aureus	

Bacteria which Liquefy Dentin (Decalcified.)

None isolated as yet	Deep layers of carious dentin.
B. mesentericus ruber	Superficial layers of carious dentin.
B. mesentericus vulgatus	
B. mesentericus fuscus	
B. fervus	
B. gingivæ pyogenes	
B. liquefaciens fluorescens motilis	
B. subtilis	
Proteus Zenkeri	
B. plexiformis	

[1] Mycology of the Mouth, and Dental Cosmos.

Goadby states that his experiments show that the bacteria which dissolve blood serum also digest decalcified dentin, while those which only liquefy gelatin do not digest decalcified dentin.

His experiments also indicate that of the bacteria found in the superficial layers of carious dentin some produce digestive enzymes, others acid fermentation, and others have both functions.

Choquet[1] has confirmed the observation of Miller, Vignal, Gallipe, and Goadby that the deeper the portions of dentin examined, the fewer species of fungi are found in the tubules, and explains it upon the ground that the anaërobic or facultative aërobic organisms in the outer layers advance into the deeper dentin, because they are better suited to the conditions. Kirk advances the as yet unproven idea that these bacteria grow toward the pulp, because that is the direction of their food supply, *i. e.*, the juices in the protoplasm of the part. In this connection, the demonstration of Goadby that some bacteria liquefy decalcified dentin shows that this substance is a food supply.

Fig. 359

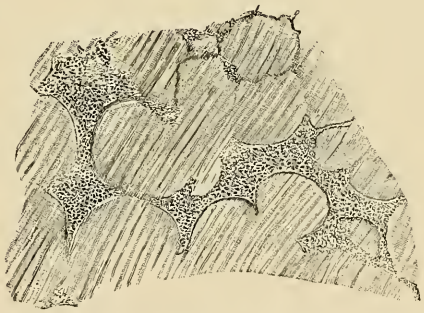

Interglobular spaces filled with bacteria. (Miller.)

These exact findings are interesting as bearing out the general demonstrations of Miller; at the same time, Miller's experiment showing absolute dissolution by a single bacterium in pure culture is to be recalled. (See page 342.)

Choquet[2] has shown that dental caries may proceed under fillings against sound dentin by the following experiment:

Artificial cavities were prepared in the incisors of a sheep. In these was securely sealed with cement, a small particle of a gelatin culture of caries fungi, applied on a sterilized platinum cap. Nine months later the dentin had become yellow, slightly decalcified, and the tubules penetrated by bacteria. This softened dentin was used to

[1] Microbes of Dental Caries, Dental Cosmos, 1900.
[2] Ibid.

inoculate a portion of the medium originally used, and the species again cultivated.

Miller[1] estimated the relative loss of inorganic and organic matter in dentin during the process of caries, by weighing and analyzing equal volumes of carious and sound dentin from the same teeth.

The carious dentin had lost about seven-ninths of its weight, which was due to the loss of twelve-thirteenths of its original calcium salts by decalcification, and two-fifths of its original organic matter by liquefaction of its substance.

Tube Casts.—In the zone of decalcification, in advance of bacterial invasion of the tubes, are found rod-shaped bodies or shining granules, first described by J. Tomes. They occur in both natural and artificial caries, hence it must be inferred that their presence is not the result of a vital process.

The rods do not dissolve in organic acids, but dilute sulphuric acid quickly dissolves them. They are unaffected by alcohol or chloroform, a proof that they are not composed of fat. Miller regards them as probably calcic formations against the tubule wall as a cast of the wall, and which become loosened when enlargement of the tubule occurs. They have a tubular structure, are brittle, and may contain a central thread-like filament which may possibly be the remains of a dentinal fibril. Bacteria may surround them, but do not enter them. The granules are probably broken rods.[2] The data point toward a probability that the rods are composed of calcium lactate and calcium lactophosphate, the result of a combination of lactic acid with the calcium salts of the dentin. The resultant salt is probably deposited as a tube cast, as suggested by Miller.

Fig. 360

Tube casts.

The Transparent Zone.—Around the zone of decalcified uninfected dentin appears a zone of dentin more transparent than the surrounding normal dentin. The zone extends from periphery to periphery around the cone of carious dentin (Fig. 353, *c*). The tubules in this area contain granular matter not seen in normal dentin, nor in the dentin of dead teeth in the same situation.[3]

Tomes and Magitot both regarded the transparency as an attempt made by nature to impede the progress of caries. Walkhoff regards it as due to a sclerotic action, the fibrillæ upon stimulation producing intercellular substance (tubule wall), at their own expense and

[1] Microörganisms of the Human Mouth.
[2] Miller.
[3] Ibid.

primarily of their offshoots. Black once regarded it as the earliest stage of decalcification, but has discarded this idea. Miller advanced the following data.[1]

1. Transparency indicates increased homogeneity as opposed to the heterogeneity of normal dentin—*i. e.*, the coefficients of light refraction are brought nearer together.

Fig. 361

Section from a lower incisor worn on a plate, extensive decay without increase of transparency. × 15. (Miller.)

2. It occurs in living dentin only and is not found in natural teeth mounted on plates and decayed in the mouth, nor in secondary caries of dentin from the pulp cavity to the periphery, and is, therefore, a result of vital action. (Compare Figs. 353 and 363 with Figs. 361 and 362.)

3. The tubules have their lumen lessened in diameter in the transparent areas, an agreement with the position of Walkhoff.

4. Secondary dentin may accompany the process in contiguity with the area; moreover, secondary dentin is translucent. It indicates a constructive excitation of the odontoblasts, of which the dentinal fibrils are prolongations (Figs. 353, *Sd*).

[1] Microörganisms of the Human Mouth.

5. Chemical analysis proved that no lime salts had been lost, and it was pointed out that a gain in the percentage of salts was unnecessary, as new dentin is necessarily composed of organic as well as inorganic matter, wherefore the analysis would not necessarily vary from that of normal dentin.

6. It is found in connection with abrasion of human teeth in which the activity of acid may possibly be an open question, and it also occurs in the worn teeth of dogs, the saliva of which is strongly alkaline.

Miller states that opacity may follow or be associated with transparency.[1]

Fig. 362

Secondary caries of dentin, advancing from pulp chamber and therefore occurring after death of the pulp. Absence of transparency. × 15. (Miller.)

The natural conclusion is that the transparency is a form of tubular calcification, and that it impedes the progress of caries; that it does not succeed, as a rule, is due to the overwhelming action of the bacteria.

In cavities from which the walls are broken away, freely exposing the carious dentin to mastication, the carious dentin and its contained bacteria may be removed by friction (Fig. 367, *B*).

[1] Dental Cosmos, April, 1903.

In the transparent area, the tubules become obliterated; a polished, discolored surface results, resembling in degree an abraded surface. This process is called "eburnation," and is really tubular calcification (which see). In the same tooth a more sheltered border of this spot may be undergoing the carious process. Miller records cases of badly decayed teeth, in which the process ceased spontaneously and the dentin became hard and smooth.

Pigmentation in Caries.—Pigmentation occurs in caries possibly from extraneous substances entering the carious area, possibly from the substances formed during putrefaction.

The slower the progress of the decay, the greater the discoloration. The colors vary from light yellow to reddish brown, dark brown, and black.

FIG. 363

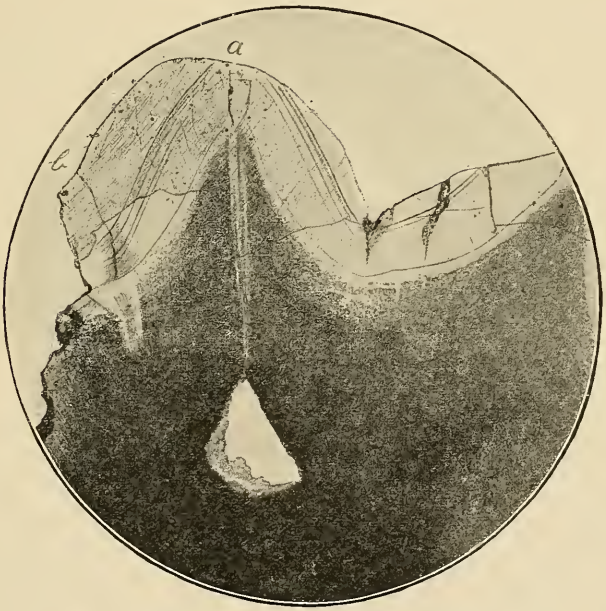

Transparency resulting from cracks in the enamel at *a* and *b*. × 20. (Miller.)

The color is, as a rule, darkest upon the outside of the carious dentin, but the pigment may extend through large masses and be found staining dentin beneath the caries, hard enough to leave *in situ*. As a rule, this is not the case.

Black suggests the possible formation of sulphids. Miller has found iron almost constantly present in carious dentin. The discoloration of dentin does not seem to be necessarily due to the carious process, as it may be seen in areas of abrasion. In a specimen

possessed by the editor, a limited cervical caries caused a growth of secondary dentin and an area of tubular calcification. From the pulpal surface of the secondary dentin to the area of caries, extends a sharply defined area which has a flesh-rose color (Fig. 364). Many areas of secondary dentin due to abrasion are stained a dark brown.

Artificial caries produced in teeth placed in a mixture of bread and saliva, and the mixture constantly renewed, was white. If putrefaction was allowed to occur, discolorations ensued (Miller).

The discolorations of carious dentin may be due to the action of chromogenic bacteria. Miller isolated from the mouth, an organism which he named Bacillus fuscans, and "which, cultivated on the surface of nutritive agar-agar, in a few weeks imparts to the medium a yellowish-brown color, which gradually darkens and extends deeper into the substratum as the age of the culture increases."

It is significant that the three acid-forming organisms found by Goadby, in the deep layers of carious dentin, do not form pigment in their artificial media.

Fig. 364

Cervical caries associated with secondary dentin. Area pigmented.

Fig. 365

Caries of cementum and dentin completely encircling the tooth.

Caries of Cementum.—Caries of cementum occurs when the gum has receded, exposing the cementum to the fluids of the mouth. As a rule, a triangular depression exists bounded by the thickened gum margin, the cementum, and the enamel. This favors the collection of the bacterial plaques, and caries follows. The gum may be much receded, yet no caries occurs. As a rule, however, recession and uncleanliness frequently assure its presence. Especially is this true in cases of general recession in aged or debilitated persons.

The path of bacterial invasion after decalcification, is by way of Sharpey's fibers to the lacunæ and canaliculi; later the dentin is invaded as in the crown. Frequently the form of the cementum is largely retained, while the decalcification is deep.

CLINICAL HISTORY OF CARIES.

The clinical history of dental caries records the observable phenomena associated with its inception, progress, and termination.

Inception of Caries.—Caries begins, after the manner described in the pathology, at favoring spots. As a rule, in molars the occlusal fissures are first decayed, being often carious in this situation before fully erupted. Uninformed parents usually consider the first permanent molar a temporary one, and frequently neglect it. It moreover has often seriously defective fissures, which afford lodgement for microbic plaques, which seem to be readily formed because of the unhygienic state of the temporary teeth, which are frequently carious, and the permanent molars are unbrushed during eruption. Not infrequently a cavity is produced on the mesial surface of this tooth by a carious condition of the distal surface of the second temporary molar. In other mouths, both teeth are affected alike, owing to the nature of the approximation. The relative liability of the various surfaces of the different teeth to caries may be averaged for a great number of persons, but tables drawn from clinical cases may have little application to a particular individual, as peculiarities of local predisposing causes and personal habits modify the inception. Nevertheless, such tables are exceedingly interesting as showing a general relative liability.

The following is from the U. S. Army report, 70,000 teeth being filled.

Teeth.	Average percentage of each carious.
First permanent molars	6.5
Second permanent molars	5.1
Upper central incisors	3.9
Premolars	2.8
Third molars	2.0
Upper canines	1.7
Lower incisors	0.7
Lower canines	0.5

The lower anterior teeth are the last of all to be affected, and it is common to see the six lower anterior teeth free from caries, years after all of the other teeth have been lost. This is attributable to the constant motion of the saliva, the presence of calculus, and to the mechanical effects of tongue movement, lip movement, and mastication.

In the temporary set, the molars decay much more frequently than the incisor teeth, partly because longer retained and partly because of the width of their approximations. The pulp is readily exposed because of its relatively larger size.

Approximal cavities are frequently more broad than deep, and present problems of anchorage.

The Progress of Caries.—The rapidity of progress of caries depends upon the intensity of the action of the exciting cause, the structure of the tooth, and the nature of the vital resistance offered. The exciting cause will act most intensely in mouths ill-cared for, and containing much carbohydrate debris, and these conditions being equal, enamel of poorer organization and presenting a greater degree of solubility, in teeth presenting broad approximations, will be the more rapidly destroyed. Caries does not begin, but may spread under the gum.

FIG. 366



Caries undermining enamel: *a*, masses of bacteria lining the cavity. × 50. (Miller.)

Williams has expressed the opinion that, as a rule, the process of enamel destruction occupies a considerable period of time, a fact which may account for the general lack of caries in the temporary teeth until about four or five years of age.

The decalcified enamel may retain its form for a time after dentin decalcification has begun. An opaque spot, often discolored, is seen upon the tooth, and is readily broken down by an instrument

before dentin decalcification occurs. If the approximating tooth be extracted, the carious process may cease, owing to the removal of the bacterial plaque, or a lack of food supply (retention). This result may not follow, if the dentin has been invaded before the extraction.

After enamel destruction at a limited area, caries progresses along its inner side and penetrates the dentin. The enamel is undermined. The extent of cavity orifice is no certain guide as to the depth of penetration. The under surface of the enamel then decalcifies. This is backward or secondary decay of enamel, and causes an opaque appearance of the undermined enamel.

Cases are frequently observed, in which the only external evidence of caries, in a molar or bicuspid, is a white or bluish-black line marking the fissure, and yet the dentin may be deeply and widely penetrated (Fig. 367, *A*).

FIG. 367

A *B*

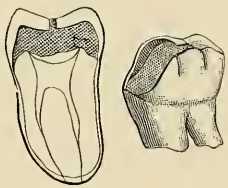

As a rule, however, as the cavity in the dentin enlarges, the enamel at the orifice becomes disintegrated, so that the orifice is enlarged and more food debris enters to accelerate the process (Fig. 353). A deep and wide cavity may thus be formed before the patient is objectively or even subjectively aware of its existence. After a time, the occlusal enamel boundary of the cavity breaks down and food is even more readily admitted.

It has been noted that if the enamel break away in such a manner as to expose the carious dentin to the friction of food masses which are not retained and to the access of saliva, the progress of the caries is delayed and in some cases ceases altogether. The process of eburnation is set up. (See Transparent Zone and Tubular Calcification.) (Fig. 367, *B*.)

The process is sometimes seen in certain cases in which caries has followed the dento-enamel junction, the enamel chipping off as undermined, so that almost the entire superficial portion of the dentin may be subjected to this process and remain of original form and discolored and eburnated. This is "spreading caries." In other cases the tubules are followed and the pulp is rapidly approached. This is "penetrating caries" (Fig. 345).

Caries may progress rapidly for a period, and then receive a check to its progress. Teeth previously free from the disease may suddenly fall victims to its rapid and widespread progress. No doubt, in many of these cases, there are removed from or added to the local oral conditions, constitutional influences which deter or favor the local development of caries producing bacteria. The editor has the models of the jaws of a boy, aged fourteen years, with every tooth but three decayed to the gum, and the three teeth contained six cavities.

Secondary dentin is less readily decalcified than primary dentin.

The dentin of pulpless teeth is more rapidly invaded after enamel decalcification than that of vital teeth, owing to the absence of vital resistance. This condition does not necessarily apply to the enamel of pulpless teeth.

While caries appears at all ages from childhood to old age, its ravages are most pronounced and its progress most rapid during the period of adolescence and early maturity. Its effects are most marked between the ages of eight and twenty-five years. As a rule, a denture which remains at twenty-five years unaffected by caries, remains unaffected or but slightly affected to an indefinite age. To be sure, this implies two conditions: (1) That the active causes of caries have been in but slight evidence, and (2) that the denture is of the highest order. The classes of dentures which escape are perfectly formed and symmetrically arranged teeth, in the mouths of patients who lead sanitary lives and care for the teeth, who masticate vigorously, and who escape other diseases. Very filthy dentures may escape, owing, as stated, to putrefaction. (See p. 361.)

Caries beginning at the junction of the cementum and enamel of the teeth has a somewhat different clinical history from that noted when its occurrence is in other situations. Its progress is subject to great variations. In any of the catarrhal conditions or atrophic conditions of the gum which lay bare the neck cementum, caries usually occurs. It occurs also as a process secondary to labial abrasion and erosion of the teeth. Teeth affected by erosion, however, at the ended area are commonly exempt from dental caries.

The Terminations of Caries.—After the pulp is exposed, it sooner or later becomes inflamed and hypertrophies or dies. In the latter case putrefaction results, which for a time may exert a restraining influence upon decay, but not for a long time.

Masses of food freely enter the pulp cavity and caries proceeds in the dentin from within toward the periphery. This is "secondary caries" of dentin, and as it occurs in dentin without vitality, no transparency results (Fig. 362). Notwithstanding, caries at this stage proceeds rather slowly, particularly if the crown be much

broken down. The result of secondary caries is a hollowing out of dentin of the root, and finally a decalcification of the cementum, which may persist for some time as a thin, elastic wall. Finally this is destroyed either at the occlusal periphery, or caries causes penetration to the pericemental tissue. This may occur laterally or through to the bifurcation of the roots. In either case it is called "perforation by caries." Into this perforation the pericemental tissue may become protruded by hypertrophy, and the condition of hyperplastic or fungous gum be established. Following the breaking down of the crown, the blood pressure in the pericementum begins an extrusive process, the pericementum becomes thickened, and the tooth is somewhat loosened.

Decay of the root face and interior, and breakage of the cemental margins proceed simultaneously with the extrusion, until finally but a small discolored bit of the root end lies upon the surface of the gum, from which it is removed by some slight force or is extracted.

The entire process of caries in a tooth may thus extend over a period of from ten to twenty years.

At times the extrusive force pushes a root up sidewise, particularly when the tooth has been tipped over before the loss of the crown. It may thus be retained in position and attached upon its under side for some time. The upper side may be polished by abrasion. The exposed end of a root undergoing extrusion is also sometimes made smooth by abrasion. A bit of root left *in situ* after breakage during extraction usually undergoes the same process of extrusion, but may not decay until it comes under oral influences. Usually a sinus leads to such a root, but very rarely the gum may heal over it.

Such a root may at any time become the source of apical abscess or of an intractable neuralgia, the cause being only determinable by radiography.

CHAPTER XIII.

DENTAL CARIES: DIAGNOSIS, SYMPTOMS, AND PROGNOSIS.

HYPERSENSITIVE DENTIN AND ITS THERAPEUTICS.

Diagnosis of Dental Caries.

The diagnosis of dental caries is made through both objective and subjective symptoms. The signs are the existence of cavities and of softened areas, directly visible or made evident through instrumental means. The symptoms are pains of several degrees of intensity. The nature and intensity of the pains furnish a guide to the depth of the carious invasion, and but an indirect indication of the location of the disease.

Diagnosis by Objective Symptoms.—The presence of the markings of superficial decay, decalcified surfaces, or cavities may often be detected at a glance or be seen reflected in a mouth mirror. Opacity of enamel is usually due to its superficial decalcification or caries beneath it, though at times a malformation may exist. Sometimes a zinc phosphate lining will cause an opacity resembling backward caries of enamel. The discoloration or opacity about a fissure should excite suspicion of caries. In the routine examination for cavities, sharp, finely pointed explorers bent at various angles are to be passed over all the surfaces of the teeth. If the enamel at any point admit the point of the explorer, caries is usually present. Fissures are sometimes deceptive in this respect. A good rule is to adjudge the presence of caries when the point catches slightly as removed. It is well to remember in this connection, that an unsuspected adjunct fissure will often contain beneath it caries deeper than the central point judged defective.

In the search for approximal caries great care is required, explorers with very short points being often necessary, as long points will not turn into the cavity owing to the close contact. The ordinary No. 7 explorer has not a short enough tine. Frequently a cavity may only be discoverable from one point of access, so that the approximal surfaces should be examined both from the labial and lingual sides. In the absence of evident cavities, some force should be applied to

FIG. 368

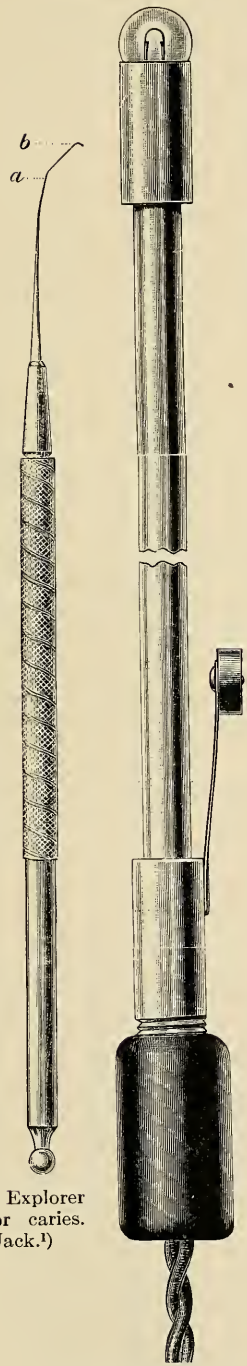

Explorer for caries. (Jack.[1])

FIG. 369

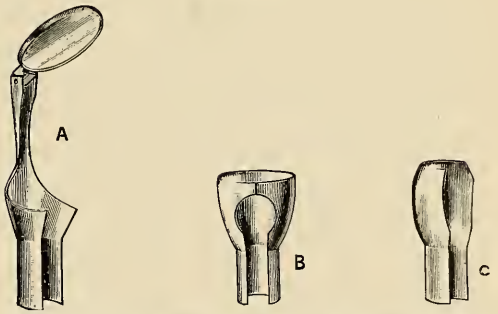

Dow electric lamp for mouth illumination, with reflectors. Reflector *A* is jointed to vary the angle of reflection. Reflector *B* is for illumination of the fauces. Reflector *C* is for lateral illumination. (Jack.[2])

detect softened spots of enamel. The catching of the explorer upon both teeth, after it has passed through the interspace, often simulates the catch in a cavity.

Unwaxed floss silk passed over carious surfaces indicates a rough surface by fraying. It may, however, at times pass readily over a cavity easily detected by instruments; so that it is not absolutely reliable as a test. It also catches on a rough filling or protruding filling margin. If the short, sharp pain of hypersensitive dentin is produced as floss passes between the contact points of the teeth, either a masked small cavity or a loose filling should be suspected, and if not found with the explorer or light, a wedge should be introduced.

The strong light of an electric mouth lamp transmitted through the teeth exhibits a cavity as an opaque spot outlined upon a pinkish background. It not only permits an easy diagnosis, but also affords evidence of the depth of penetration. Mechanical separators or wedges are at times necessary to press apart contiguous teeth sufficiently to admit exploring instruments.

[1] American Text-book of Operative Dentistry.

[2] Ibid.

The necks of the teeth should be examined with sharp points, to note any softness of the tooth tissues. The margins, particularly the cervical and neighboring margins, of every filling should be explored to test the integrity of the junction of filling and tooth, or any excess or deficiency of filling material.

The examination should be conducted by one of two systematic methods. In one method the occlusal faces of all the teeth are first examined in one survey, then the interproximal spaces, and lastly, the buccal and lingual surfaces of the teeth. In the other method, every portion of each tooth is examined, beginning with a central incisor or terminal molar, before passing to the adjoining tooth. Any cavity or condition found should be noted upon a diagram for reference at sittings.

Diagnosis by Subjective Symptoms.—Complaints by patients that cold or hot, salt, sweet, or acid substances taken into the mouth cause unlocalized or partly localized pain, indicate exposed and hypersensitive dentin or pulp exposure. Such complaint is to have due consideration. Slight pain has also been produced by the passage of floss over a minute cavity unexplorable before wedging, and is probably due to compression of liquid upon dentine. This symptom at the cervix of a tooth indicates hypersensitive exposed dentin.

Pain beginning without the application of special stimuli, is likewise ordinarily connected with caries or its sequelæ, and should be taken into account.

Pain produced upon mastication has either the significance of pressure on fibrils or pulp, or is a symptom of pericemental irritation.

Prognosis of Caries.

If existing caries be promptly treated in youth and a proper systematic prophylaxis be employed, its recurrence during youth may be largely prevented. At about adult age a fair degree of immunity may be expected. In the absence of treatment or prophylaxis, the exciting causes seem to become very active, and many teeth may be lost from caries or by reason of extraction for pulp and pericemental diseases. Extraction itself brings many evils in its train.

Even advanced caries may be checked by proper filling or crowning, and if then prophylaxis receive due attention, the prognosis for the teeth is generally good; indeed, it seems as though but few conditions exist dependent upon caries alone, which are not subject to correction by some of the means within the resources of the profession.

Hypersensitivity of Dentin.

The exposure of dentin to external agencies is so commonly followed by an increase in sensitivity, that the condition requires description in itself. It is a general condition attendant upon abrasion, erosion, and caries, and has a therapeutics of its own.

The term sensitive dentin applied to this condition is a misnomer; all vital dentin is sensitive, and its degree of sensitivity differs markedly in individuals; it is only when hypersensitivity is observed that the condition becomes pathological.

Hypersensitivity of dentin may be defined as such a degree of sensitiveness of the dentinal fibrils, as interferes with the comfortable excavation and shaping of a cavity of decay; or which, in the absence of dental ministrations, causes painful symptoms, as a rule, reflected about neighboring parts.

Causes and Pathology.—Normally the dentin is protected from external agencies by the enamel, and in the early stages of gum recession by the cementum, though it has been shown that in some cases the dentin is not covered by either. (See p. 182.)

With the removal of these coverings by caries, erosion, abrasion, or fracture, the terminal filaments of the dentinal fibrils become subjected to sudden variations of temperature, ranging from a little above 32° F., the temperature of ice-water, to 130° F., that of very hot foods or liquids.

These thermal stimuli at times give evidence of their effect by producing painful sensations. The pulp is stimulated through the odontoblasts and their relations with the terminals of sensory nerves in the pulp, and a degree of vascular overfulness occurs which may be denominated mild hyperemia. The effect of these reactions is to cause the sensory functions of the pulp to become somewhat exalted, and it therefore becomes more responsive to the stimuli.

Apart from the effect of thermal changes, other substances act as irritants. The lactic acid and other bacterial products in the cavity of decay, without doubt play a part in exalting the irritability of the fibrils. A slightly loosened filling holds the acid in contact, as such cases are often very sensitive. Salt, sweet, or acid substances introduced into the mouth are also evidently irritant, as active symptoms follow their application to hypersensitive dentin.

Mechanical abrasion or erosion may irritate the fibrils, or at least expose them to the action of other irritants. As a rule, however, the abraded or eroded surfaces are protected from hypersensitivity by the process of eburnation. (See Transparent Zone.)

The scraping of necks of teeth with scalers sometimes induces exposure of dentin. Within cavities of decay, the hypersensitivity is greatest, as a rule, at the dentinal periphery. That at this point the dichotomous endings of the tubules present a greater number of fibrils to the action of the irritant is quite evident (Fig. 117).

In cervical hypersensitivity, the cementum or enamel is removed by abrasion, erosion, or caries, and the fibrils are exposed. The presence of the granular layer of Tomes in this situation, and the possibility of this layer containing the expansions of the fibrils, are to be considered.

In certain cases, the irritation excited by the touch of an instrument to dentin adjacent to enamel is carried to the pulp by anastomosing dentinal fibrils. This was proved by a few cases, of which the following is an extreme one:

In a central incisor, secondary dentin had filled a portion of the pulp cavity (Fig. 370, *S D*). Caries had subsequently removed the incisal portion of this secondary growth and also the dentin containing fibrils leading from the pulp cavity to the middle of the incisal edge. The application of an excavator to dentin in the incisal portion of the cavity (at *A*), the fibrils of which could have no direct relation with the pulp, produced flashes of pain. This was unmistakably of the character of hypersensitive dentin.

FIG. 370

Indirect transmission of sensation in a case of hypersensitive dentin: *S D*, secondary dentin; *A*, point of hypersensitivity. (Diagrammatic.)

A professional friend claimed to feel sensitivity in a cervicolingual cavity of a molar, in which the filaments had been destroyed by suppuration for one-third of the length of the canals. If his contention was true, the sensation must have been conducted by way of the granular layer of Tomes to the level of the pulp, and thence by the fibrils to its substance. (See Fig. 126.)

Spots of cervical hypersensitivity have been occasionally recorded as occurring in teeth, the canals of which have been filled.

Head[1] records a case in which the dentin bounding the pulp canal remained hypersensitive for a year after the pulp was removed. In this connection the possibility of the presence of a vital pulp filament in the pulp canal, or of irritable apical tissue receiving the impact of liquid forced down upon it by a canal probe, or of a pericementum

[1] Dental Cosmos, 1899.

irritable to touch of any sort, must all have due differentiation. I have never seen a case of hypersensitivity of dentin in which some filament of pulp was not present, in at least a part of the tooth.

Dentin cannot become inflamed in the ordinary sense, as leukocytes cannot enter the tubules; nevertheless, the irritability of the fibrils, like that of other protoplasm, may be exalted (or lessened). It has been noted that during excavation of a cavity the irritability is, as a rule, greatest at the surface of the dentin—*i. e.*, at the point at which irritants are present in greatest amount, and the fibrils most numerous.

With hypersensitivity other functions are increased, and in conditions producing a constant stimulation, a constructive change may occur and the fibrils form tubular substances at their own expense. (See Transparent Zone and Tubular Calcification.)

That the hypersensitivity is primarily, as a rule, a disease of the fibrils involved, or of the fibrils and their odontoblasts is shown by the fact that occasionally of two cavities in the same tooth, one will present a hypersensitivity and another none; again, one part of a cavity may be hypersensitive and the rest not so. In other cases, perfectly normal dentin is hypersensitive, as noted when the attempt is made to reduce a sound tooth for bridge-work, or a sound fissure is opened for prevention of decay.

There have been two theories accounting for the transmission of the impulse which is translated by the patient as pain: (1) That a concontraction of the whole cell, fibril and odontoblast, occurs, the sensory nerve endings being pressed upon in the act—*i. e.*, contraction causes a lateral increase in size. (2) That a wave-like motion along the protoplasm is set up, causing excitation of the sensory nerves and due to the incompressibility of the water. (Gysi.)

The first is analogous to the contraction of a voluntary muscle cell under nerve impulse. The whole muscle cell contracts, though the nerve ending is supplied to only a portion of it.[1] This hypothesis fits the symptoms as excited by both mechanical and chemical irritants, while the second theory does not. If the contention of Robertson that the odontoblast is connected with the axis cylinders of the nerves be true, then the contraction pulls the nerve fibril.

If Mummery is correct in his statement that nerve fibres enter the tubules and end at their subenamel terminals, then even this theory must be modified, as the irritation will be direct. The contraction may still be possible. (See p. 181.)

[1] Black: American System of Dentistry.

Symptoms.—A certain degree of uneasiness of undefined character may at times be noted in teeth containing cavities, but, as a rule, pain other than pulp pain is only felt upon the application of special stimuli. Of course, the presence of ferments, acids, etc., in a cavity are real stimuli.

The infiltration of acid, salt, or sweet substances into contact with a hypersensitive surface is followed by a wave of gnawing pain, reflected usually along the course of contiguous nerve filaments. While not definitely localized, owing to the fact that the pulp does not possess a tactile or localizing sense, the pain may usually be referred to a certain part of the mouth. The pressure of an instrument upon the dentin is attended by a flash of sharp pain, which continues for a time, but lessens if the contact be maintained. In this test the pain is localized in the affected tooth, the touch of the instrument being followed by a recognition of position by the tactile organ of the tooth, the pericementum.

Occasionally, food forced by mastication against a hypersensitive surface, such as due to abrasion or caries in a crevice, will produce a sharp pain subsiding promptly, and which may not be repeated for some time. The mere rubbing together of opposing abraded surfaces may cause the symptom, and is more pronounced if a hard substance, as grit gets between them.

Cavities dried for filling usually produce a steady pain, caused by dryness and relieved by an analgesic or by filling.

It is beyond doubt that individuals differ as to the degrees of normal dentinal sensitivity; the dentin of one person may be cut freely without evidence of marked pain; in another, the touch of an instrument to the newly exposed dentin is productive of unbearable pain. The difference in degree of irritability is manifested in another manner: If a mild sedative—for example, oil of cloves or an obtundent—be applied to the hypersensitive dentin of one person, it may remove the distressing symptoms, but with others it may be necessary to employ the most extreme measures to reduce in any degree the hypersensitivity. In some cases, the exposure of dentin about the necks of teeth may induce such an unbearable local pain or neuralgic condition as to positively demand relief.

In a few cases enamel has exhibited sensitivity. In one case the effort to open sound fissures about a cavity for prevention excited sharp pain, ceasing upon removal of the instrument. The patient was, however, a sufferer from insomnia, and from the effects of morphine taken for it, and her dentin was exquisitely sensitive. The same phenomenon of enamel sensitivity is to be noted in one of her children.

In another patient, the side of the enamel exposed by a cavity in a molar analogous to that in Fig. 370 gave flashes of pain when touched with an excavator point, though no evident direct path of transmission to the pulp could be seen. Caush's tubes and indirect transmission seem the only basis of explanation. (See Fig. 179.)

There is a pseudohypersensitivity of enamel in some cases, due to apprehension. The patients can be ridiculed out of the idea by demonstrating its absurdity, as, for example, by touching a cusp and then showing them the part touched. Pericemental irritability at times must also be excluded.

Fig. 371



The Teter nitrous oxide and oxygen apparatus on apparatus stand.

Fig. 372

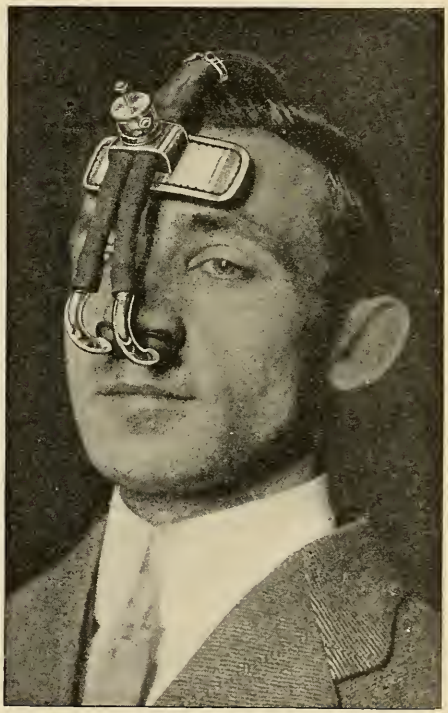

Gregg nasal inhaler.

There can be no question that systemic, nervous irritability from any cause aggravates the phenomenon of hypersensitivity, though whether it can make dentin more sensitive, or whether the patient is less able to endure pain, is not clear.

The general perceptivity of the individual seems to play a part, and even apparently normal dentin may be exquisitely hypersensitive. Again, pain produced in excavation may be due to the

character of the manipulation, heavy continued burring producing heat; lighter touches may excavate equally well, but produce much less pain. The dulness of the excavator or bur has a similar effect.

Diagnosis.—In the diagnosis the above characteristic symptoms are to be considered. The decisive test is made by pressing an instrument upon the suspected surface, when the characteristic pain is produced, subsiding upon or shortly after removal of the contact.

Upon the pulpal wall of deep cavities doubt may exist as to whether the pain is due to pulp irritation.

A suspected exposure may be differentiated by the localization of the pain upon touch, to a point corresponding to the pulp horn or pulp body, or by the point catching in the exposure. Hypersensitive dentin will be more generally distributed or occur at points at which exposure is impossible. Pulp abnormality or approach may be detected by means of a drop of cool water or a blast of cool air from a syringe. (See Hyperemia of the Pulp.)

Treatment.—The methods of treatment which have been followed for the relief of hypersensitivity of dentin, and the induction of such a degree of analgesia as will permit the necessary cutting of dentin, may be divided into general and local.

General Remedies.—The general remedies employed are those which abolish or lessen the perceptive function in the centres of the fifth pair of nerves, or which reduce hyperirritability of the nervous system. Either general anesthesia or general anodynes are employed to lessen perception. The inhalation of a few whiffs of chloroform or ethylic ether lessens the perception of pain, or a mixture of chloroform, ether, and alcohol may be used. Chloroform is usually avoided in this connection on account of its dangers when used in the sitting position. Slight etherization, the inhalation being carried only to the benumbing point, affords marked relief from the pain incidental to the cutting of hypersensitive dentin. Nitrous oxide and oxygen administered to the point at which "analgesia" without anesthesia occurs is a method now much employed. A special nasal inhaler admits the gases in various combinations, the mixture of the prepared gases being made in the mixing chamber of the apparatus, after the gases leave the cylinders.

It is preferable that the gases be warmed to avoid the irritation of the lungs by the cold gases, though for short operations this is often omitted.

Rebreathing the carbon dioxid and gases exhaled is also advocated as a respiratory stimulant and for economy. In view of hypersensitive dentin the method is now routine for cavity preparation and for the grinding of teeth with living pulps, for abutments or for other

work involving a reasonable amount of pain. It is not generally useful for pulp removal unless complete anesthesia is induced. The method has various dangers which, while not preventing its use in careful hands, renders it not to be carelessly employed. Fear is apt to contra-indicate its use in children.

The element of suggestion and confidence on the part of the operator seems to play an important part in the success of the analgesia, though the analgesia is not dependent upon it. The patient is able to coöperate with the operator, not having lost consciousness. In the practical application of the mixed gases, the apparatus is first set as to constancy of flow of both gases, the proportion of 95 per cent. N_2O and 5 per cent. O being first applied, until the patient reaches a condition of somnolence, of which he informs the operator. The proportions are now changed until approximately 80 per cent. N_2O and 20 per cent. O are being given, though this proportion is variable. The patient is instructed to breathe through the nose if pain is felt, thus obtaining deeper analgesia. Conversely, as work is not being done, he may breathe through the mouth. If greater depth of anesthesia is required, the exhaling valve which ordinarily vents the expirations is adjusted and the patient then rebreathes the gases together with his own carbon dioxid, which further stimulates respiration and gradually passes into anesthesia, especially if the percentage of oxygen be decreased. Without rebreathing, 95 per cent. N_2O and 5 per cent. O will produce anesthesia. The amount of rebreathing is controlled by a valve. Somnoform has also been used with a special inhaler (De Ford or Starck) to produce analgesia.

The administration of general anodynes, particularly the combination of morphin and atropin, has been found useful in this field.

℞—Morphinæ sulph. . . . . gr. $\frac{1}{8}$
Atropinæ sulph. . . . . gr. $\frac{1}{150}$
M. et ft. pil. No. 1.
Sig.—To be taken one-half hour before operation.

Flagg noted that blondes bear morphin sulphate better than brunettes; particularly are nervobilious and bilionervous patients idiosyncratically opposed to its use, the physiological action of the drug being reversed or the after-effects being pronounced. Patients having dark hair and blue eyes may be expected to be thus idiosyncratic. For them, he recommended morphin bimeconate solution in doses equivalent to $\frac{1}{8}$ grain of the salt, to be taken one the evening before, and the other before the operation.

[1] For details of apparatus and application read C. K. Teter, Dental Cosmos, August 1912; W. C. Teter, Dental Brief, August, 1911; A. E. Smith, Items of Interest, December, 1913; Harold B. Clark, Items of Interest, April, 1914, and others.

Chloral in 5 or 10 grain doses, administered in water before the operation, has a quieting effect upon the nervous system. Ambler[1] has suggested the use of from 10 to 20 drops of fluidextract of piscidia erythrina, to be administered about ten minutes before operating. Drowsiness may be expected. Phenobromate, 10 grains, before operation, or 15 grains for any great pain, may be administered in a copious draught of water.

For the reduction of excitement and nervousness in anticipation of dental operation, bromural, 5 grs., ordinarily to be administered while waiting, or 10 grs. in unusual cases, is highly recommended for this purpose by Hecker.[2] It is also useful in insomnia, and its associated hyperesthesia. Quinine sulphate, 5 grains a half-hour before operation, or better if preceded by another dose the day before it has been used.

Hyoscyamin hydrobromate, $\frac{1}{60}$ grain, will be useful in those cases which are associated with muscular spasm or hysteria.

The coal-tar derivatives, phenacetin, acetanilid, and others, are occasionally efficient. The preparation known as antikamnia (said to be a combination of acetanilid, caffein citrate, and sodium bicarbonate) and ammonol (acetanilid and ammonium carbonate, equal parts) are to be preferred in this connection. The dose of the latter two is 10 grains, administered one-half hour before operation.

The induction of the hypnotic state belongs in the category of means acting upon the nerve centres. The use of the ordinary suggestion that the work will not be unduly painful, considerate treatment, patience, and the employment of remedies all have a calming influence, permitting relaxation upon the part of the patient, who, if "keyed up" to expect great pain, will expect and feel unduly.

The use of blue-light anesthesia consists in causing the patient to gaze intently for a few minutes at a blue-globed electric light having a reflector behind it. A blue veil is thrown about the head and lamp to exclude daylight. Short operations have been performed under its sedative, or, possibly, hypnotic effects, though it seems to fail in some cases.

Local Treatment.—The local treatment of hypersensitive dentin may be considered from two standpoints, according to whether a concavity containing it requires excavation, or whether the hypersensitive spots are not to be excavated after treatment.

Treatment in Cavities of Decay.—The remedies employed in the endeavor to reduce or abolish hypersensitivity in a cavity of

[1] Dental Cosmos., 1901.

[2] Ibid., 1909, p. 844.

decay at the time of operation are quite numerous; few are, however, always effective. They may be classed under two headings:

1. Those which temporarily benumb or anesthetize the fibrillæ and prevent the transmission of sensation.

2. Those which chemically destroy the fibrillæ for a distance, thus preventing transmission of sensation.

Remedies which Benumb the Fibrillæ.—Chief among these for its universality of application is dryness. Dentin, which protests against even the touch of an instrument while wet, has its sensitivity so lessened after the application of a rubber dam and drying, that it may be cut freely, in many cases without the aid of medicinal agents. So well is this recognized that isolation and drying of teeth are regarded as a necessary preliminary to cavity preparation. The degree of insensitivity induced is in proportion to the dryness. The drying temporarily deprives the dentinal protoplasm of a portion of its water, and inhibits the transmission of sensation by reducing functional activity.

A continuous but gentle blast of air, passed from a compressed-air apparatus or double bulb through a heated metal bulb and nozzle, or through an electrically heated coil, should be employed until the dentin is desiccated. This is evidenced by its extreme whiteness. Other forms of hot-air syringes may be substituted with less satisfaction and greater fatigue to the operator. The double bulb may be operated by the patient.

The application of absolute alcohol assists the drying because of its affinity for water. The addition of a little menthol to the alcohol assists by anesthetic action. The pain from the warm air may at first be quite severe, but even in greatly hypersensitive cases the nozzle of the syringe may soon be approximated to the cavity, though in some cases it may be necessary to make an application of a mixture of equal parts of carbolic acid and oil of cloves, or of gum camphor and carbolic acid (phenol camphor), both of which have some anesthetic effect. Menthol may be added to either. When desirable, their effect may be hastened by pressure with unvulcanized rubber.

An instrument known as the "dehydrator" causes absolute alcohol placed in a special chamber between the bulb of the hot-air syringe and the nozzle to be vaporized upon the hypersensitive dentin. The drying effect is thereby augmented and the dentin satisfactorily obtunded.

Some degree of dryness is, as a rule, a necessary preliminary to success with other applications.

Following dryness, the excavation should be done with sharp instruments and burs. The latter should only be lightly touched to

the dentin and be revolved at high speed. Letting the bur occasionally run free cools it. The heat of friction is considerable and highly irritating.

The combination of potassium carbonate with glycerin makes a water-extracting combination having but little coagulating power. For this reason it may be used in the deeper cavities, but not in cases of almost exposed pulp, as in such cases its application is painful.

℞—Potassium carbonate . . . . . gr. xv
Glycerin . . . . . f℥j
Mix in a mortar.
To be applied on a pellet of cotton. (Flagg.)

It may be used with effect even upon slightly moist dentin.

Not being escharotic to the gum, this remedy is exceedingly useful about the sensitive but undecayed necks of teeth, and may be freely applied after moderate drying of the parts.

If necessary, the patient may be given the prescription and directed to apply by means of a clean tooth-pick, which should not be used a second time, as the mixture may be infected and spoiled.

Its pain simulates that of zinc chlorid, but is less severe in its character.

A mixture of tannin and glycerin has a similar effect.

℞—Tannin . . . . . ℥j or ℥ij
Glycerin . . . . . f℥j
Mix in a warm mortar.

Refrigeration by a spray of ether or ethyl or methyl chlorid reduces the temperature of the fibrils and pulp, benumbing them. The rubber dam should be applied to isolate the teeth operated upon. Ether is applied by means of a double-bulbed atomizer, or one operated by compressed air; the chlorids are contained in glass tubes conveniently capped. The cap being raised, the heat of the hand causes vaporization of the agent within the tube, which forces the liquid out of the orifice of the tube in a fine but forcible stream. A spraying nozzle is also obtainable. The cavity should at first contain a pellet of cotton, in order that the dentin may be gradually obtunded and painful response on the part of the pulp avoided. The method may be painful in application, but often satisfactory. Ether odorizes the operating room, and a flame must be avoided.

"Vapocain" and "potassocain," proprietary agents which consist of a 15 per cent. solution of cocain in ether, are applied to hypersensitive dentin upon the theory that the ether enters the tubules, carrying the cocain into contact with the fibrils; the ether evapo-

rates, leaving the cocain in aqueous solution to benumb them. This requires several minutes. They are useful in the deeper cavities. Jack recommends that the cavity acidity be neutralized before their application.[1]

FIG. 373

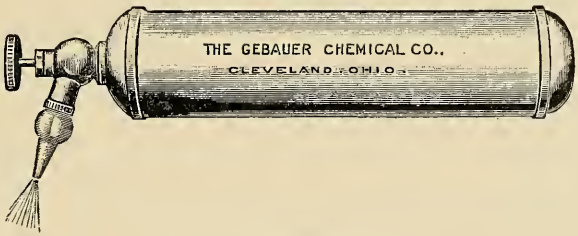

Ethyl chlorid spray tube.

A 10 to 25 per cent. solution of cocain hydrochlorate, or novocain in water may be forced into the tubules by applying it on a pellet of amadou, placing over this soft vulcanite rubber, and producing pressure with a burnisher for from three to six minutes. The pressure should be gradually applied. A gratifying degree of dentinal anesthesia may often be obtained.

Adrenalin chlorid solution, 1 to 1000, plus chloreton[2] or cocain, has been used in this manner with some effect. A few crystals of the cocain or novocain may be picked up on a pellet of cotton moistened with warm water and pressed upon the cavity surface.

Miller[3] has shown that by taking a modelling composition impression of the cavity, then applying a few threads of cotton saturated with cocain to the floor of the cavity, then placing a thickness of rubber dam over the entire cavity surface, replacing the modelling composition, and producing pressure, anesthesia can be produced when there is not a greasy condition of the cavity, nor thick layers of decalcified dentin nor much secondary dentin present.

Cataphoresis (Greek *kata*, down, and *phoreo*, I bear or bring) is, in technical parlance, the transference of substances from the anodal or positive pole of a battery toward the cathodal or negative pole. They are thus carried into the tissues.

Cataphoresis is to be distinguished from electrolysis, by which substances are decomposed and their elements carried from positive to negative or from negative to positive poles, according to their polarity. In cataphoresis a substance is carried unchanged from the positive toward the negative pole, after the manner of granules in protoplasm acted upon by the same force. (See p. 20.)

[1] American Text-book of Operative Dentistry.
[2] Parke, Davis & Co.
[3] Dental Review, 1906.

As applied to dentistry, a primary current from a battery arranged with the cells in series has the positive pole or conductor connected with a resistance or current controller, capable of being so manipulated as to gradually reduce the resistance to the current a fraction of a volt at a time. This is called a "fractional volt selector." This is usually a broken ring of graphite, to one end of which the incoming current is admitted by means of the conducting cord and travelling indicator (from the positive or carbon pole of the battery); at the other end the current passes out by a similar cord, which in turn is attached to a milliampèremeter, or instrument recording the quantity of current passing through the circuit. From this a cord leads to the positive electrode applied to the tooth cavity. To the face, neck, or wrist of the patient a moist electrode (negative) is applied, which by its conducting cord leads the current back to the negative or zinc pole of the battery. The current passes through the patient.

The milliampèremeter is a convenient but not an essential feature of the apparatus, and as a volt-selector, a rod of graphite or a glass tube with water resistance may be used. Fig. 374 shows the more elegant apparatus arranged almost as described.

In the use of the cataphoric apparatus, the tooth is securely insulated by well-ligated rubber dam and cotton saturated with a solution of cocain hydrochlorate or citrate, of a strength of from 10 per cent. to a saturated solution is placed in the cavity. The platinum anode is wrapped with cotton, dipped in the solution, and inserted into contact with the cotton in the cavity. The controller is now so manipulated as to gradually cut out its resistance to the current, and the high resistance of the dentin is gradually overcome.

The cocain solution should be renewed as dryness occurs, as dryness increases the resistance. The cocain is carried along the fibrils to the pulp by the electric current, and dentinal, followed by pulpal anesthesia results.

From eight to fifteen minutes, or sometimes longer, are required for dentinal anesthesia, which loss of time is largely regained in the facility of operation.[1]

Price[2] has shown that pulp anesthesia is gained more readily by concentrating the action of the cocain upon the pulpal wall by means of a small electrode. If general dentinal anesthesia is required he prefers this method, as the pain receptivity of the pulp is abolished. A broader application anesthetizes the dentin.

Woodward[3] has shown that in the latter case the dentin in a cavity

[1] Jack: American Text-book of Operative Dentistry. [2] Dental Summary, April, 1903.
[3] International Dental Journal, November, 1902.

upon the opposite side of a tooth being operated upon, may remain sensitive.

Fig. 374

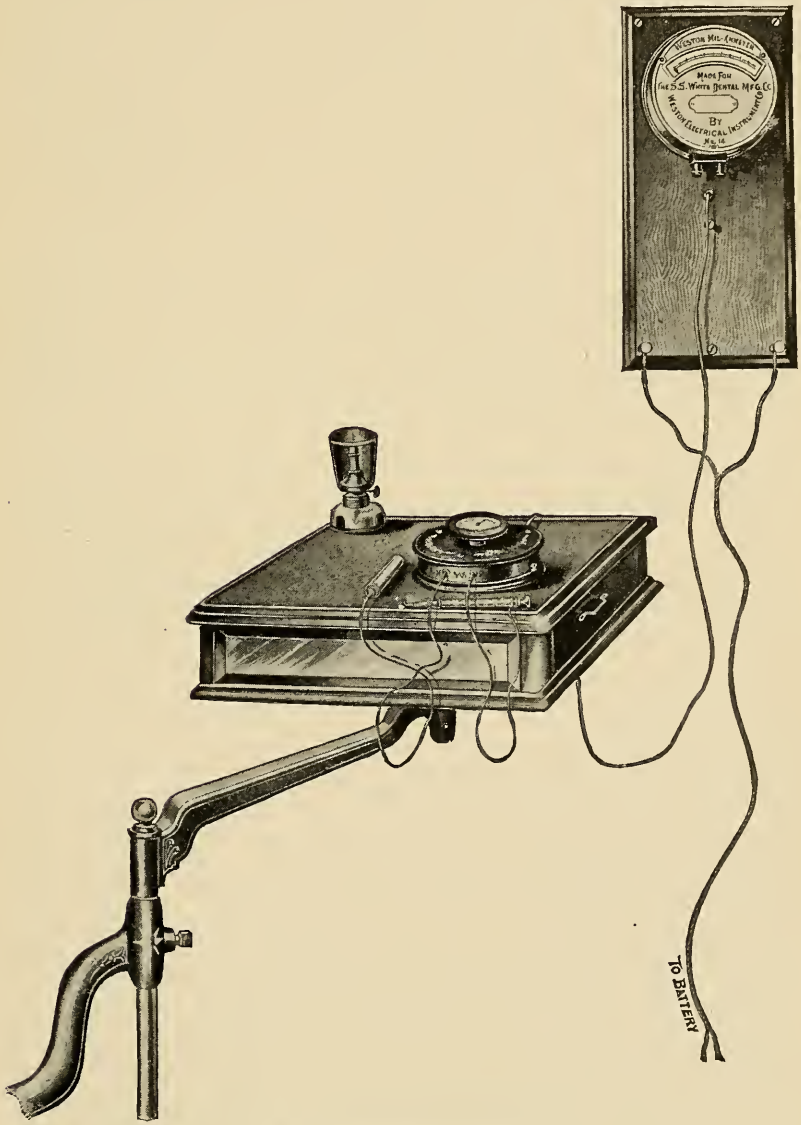

S. S. White cataphoric outfit.

The pulp may be anesthetized by this method for removal. In difficult conditions this is a very valuable means of therapeutics.

The pulp is not injuriously affected in ordinary applications, unless saturated by long application. A reaction resulting in hyperemia may take place. To obviate this, the pulp should not be oversaturated, the fibrils should be treated with carbolic acid, and in deep cavities a non-conductor should be used before filling.

In case absolute insensitivity is produced, the anatomy of the pulp must carefully be considered, so that it be not exposed during the excavation of the cavity. This can be determined by instrumental examination. Insulation of the pulp from thermal shock subsequent to filling is also to have consideration.

The pulp may have cocain or novocain forced into it by means of a powerful compound-pressure syringe. The Meyers syringe is one of the best. It is filled with a 2 to 4 per cent. solution of cocain or novocain in water; a convenient drill pit is made with a No. ½ bur; the nozzle of the filled syringe freed of air is forced into the opening and continuous or intermittent pressure produced without releasing

FIG. 375

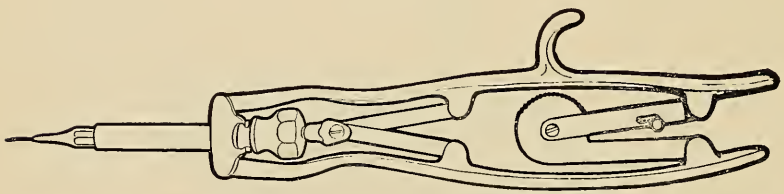

The Meyers compound syringe for forcing cocain solutions through the dentinal tubules.

the point for several minutes. It is well to allow the air to escape from the pit by holding loosely for a moment. No general cavity anesthesia will result until the solution has infiltrated the area of pulp underlying the fibrillar connections with the pulp. The forcing of cocain into so delicate a tissue should stop at that point, as more may produce expansive pressure, and may cause a later pulp reaction, as cocain is, to a degree, a protoplasmic poison. The method is useful in pulp extirpation rather than in hypersensitivity, but has occasional use, especially in cervical cavities. Secondary dentin is difficult of penetration, and gradual approaches must be made. It should be so injected into only sound dentin. If the cervix of a cavity is used as the point of injection, the pit should be made deeper than the syringe nozzle penetrates, as in this way the lateral tubules can carry the cocain, otherwise they may be occluded by the syringe point. The syringe nozzle may be made flat ended and the pit in the dentin be made with a cone-shaped bur.

Mucous and Conductive Anesthesia.—The anesthetization of the branch of the fifth nerve leading from the tooth, renders it incapable of transmitting sensation to the brain. In principle its application does not differ from local application to fibrils or pulp. The nerve paralysis is produced nearer the brain, as it were. Novocain is at present largely substituted for cocain for this purpose.

Guido Fischer recommends the following as an isotonic solvent:

Calcium chlorid	0.04 gram.
Potassium chlorid	0.02 gram.
Sodium chlorid	0.05 gram.
Distilled water (sterile)	100.00 grams or c.c.

Add novocain 1.0 or 1.5 or 2.0 grams, to make a 1 to 2 per cent. solution as desired. At the time of use add two drops of a 1 to 1000 solution of synthetic suprarenin to each 30 minims of solution—boil for sterilization. When only occasionally used, a sterile tablet (ready made), containing $\frac{1}{3}$ grain of novocain and a suitable proportion of synthetic suprarenin, may be dissolved in 30 minims of the isotonic solvent or normal salt solution, and the whole boiled for sterility. A tablet (E) is made by the Farbwerke-Hoechst Company and consists of:

℞—Novocain	0.02 gram.
Suprarenin	0.00005 gram.

Dissolve in 30 minims of solvent for a 1 per cent. solution and boil.

When mucous anesthesia is employed, the solution is injected into and beneath the periosteum, both buccally and lingually, as nearly over the apex of the root as possible. About ten minutes are required to produce satisfactory pulp anesthesia. Fischer[1] emphasizes the following conditions for success in mucous anesthesia:

1. The application of a stasis bandage slightly compressing the carotid artery and the veins of the neck, to help retain the anesthetic, and prevent cerebral anemia.
2. The periosteum, not the submucous tissue must be infiltrated.
3. One injection to be made on each side of the teeth. The fewer injections the better the effect.
4. The part must be sterilized with tincture of iodin and the sterile needle must have its orifice faced toward the bone.
5. Slow, moderately strong pressure during the injection.
6. The point of injection must be compressed with the finger, after the needle is withdrawn to allow diffusion of the anesthetic.

[1] Local Anesthesia in Dentistry.

In conductive anesthesia, the anesthetic is injected into the tissue contiguous to a nerve trunk. Its infiltration causes anesthesia of the part it supplies. Fischer directs that for upper posterior teeth supplied by the posterior superior dental branch of the superior maxillary division of the fifth nerve, a long needle should be driven into the mucosa beneath the zygomatic process and then advanced upward and backward to the foramen at which the nerve enters the tuberosity of the maxilla. One c.c. of solution is introduced. Palatally a mucous injection is made at the posterior palatine foramen. For upper first molars an additional palatal mucous injection over the first molar is advised. Ten minutes is allowed for operative anesthesia. The upper teeth anterior to the molars being supplied by the infraorbital terminals their sensibility, may be blocked by conductive anesthesia of the nerve within the infraorbital foramen above the first bicuspid. A 1 per cent. solution is used.

Fischer directs the introduction of the needle into the reflection of the mucous membrane just back of the cuspid apex and to be advanced upward and backward to the location of the infraorbital foramen, when some force is required to force the anesthetic into the foramen. Palatally a mucous injection is made parallel to the axis of the roots of the teeth to be anesthetized.

For anterior anesthesia in the mandible, injection is made into the region of the mental foramen, and as well a lingual mucous anesthesia is done. For complete anesthesia of the side of the mandible, injection is made in the soft tissue just above the retromolar triangle in the inside of the ramus. Twenty minutes are allowed for complete anesthesia. The technique of these injections and the local anatomy are so beautifully illustrated and described in Guido Fischer's book on Local Anesthesia in Dentistry that the reader is urged to master its details from a work devoted exhaustively to the subject.[1]

Diplœic Anesthesia.—For deep anesthesia about a molar, the gum may be anesthetized and a cut made to the bone, a small sterile drill is then driven through to the cancellated structure. A further injection is then made with a blunt needle, such as is used in high pressure work. This operation has been modified by the use of a needle constructed to simply indent the cortical layer of bone, so that the force of the plunger may cause the direct infiltration of the apical tissue. This uses the principle of high pressure anesthesia as applied to dentin.

While the operation of diplœic anesthesia seems heroic, there is no good reason for so regarding either this or the operation of conduc-

[1] Theodor Blum has an excellent article in Items of Interest, for July, 1914.

tive anesthesia in general as more dangerous than ordinary mucous injection. The rule of safety lies in knowledge of anatomy, safe dosage, and sterility—in short, in correct technique.

The introduction of a 5 or 10 per cent. solution of cocain upon cotton into the nostril, upon the side of operation, is endorsed by Peck, of Chicago, as a means of anesthetizing the nerve trunk leading from the upper incisors. Escat,[1] of Toulouse, France, has observed that a 0.1 per cent. solution on cotton about the size of an almond, placed in the nostril in close proximity to the anterior edge of the inferior turbinate, will in twenty minutes anesthetize the anterior superior dental branch of the fifth nerve, which lies in close proximity to the nasal mucous membrane at this point. The entire tissue about the incisors and cuspids of the side is anesthetized, as is sometimes that of the opposite side in part.

Reflex Anesthesia.—Claims are made by Dr. William H. Fitzgerald, M.D., that pressure with a metal probe tipped with cotton upon certain parts of the mouth and fingers, will produce satisfactory oral anesthesia and even of more distant parts. Curative effects in certain body diseases by proper manipulation are claimed. The method is too new for recommendation here.[2]

Söderberg[3] has shown that painless excavation of cavities otherwise uncontrollable may be effected by the use of nervocidin, an alkaloid obtained by Dr. D. Dalma from the East Indian plant *gasu-basu*. Twenty-four hours are required for complete dentinal anesthesia without pulp anesthesia unless a second application be made.

The primary effect of nervocidin being irritating, Söderberg recommends the additional use of cocain, both being mixed with zinc sulphate cement.

℞—Gum arabic	ʒj
Zinc sulphate	℥ss
Water	fʒj—M.

Dissolve the zinc sulphate in the water, add the gum arabic, stir; let stand for twenty-four hours and strain.

℞—Of above solution	fʒij
Nervocidin	gr. x
Cocain hydrochlorid	gr. x—M.

To a portion of the latter solution add uncalcined zinc oxid to make a cement, which is placed in the dried cavity. Uncalcined zinc

[1] Theodor Blum has an excellent article in Items of Interest, 1908, p. 181.

[2] Paper read before the N. J. State Dental Society, July, 1914. See Items of Interest to be published later, and Hogan, Items of Interest, June, 1913.

[3] Dental Cosmos, August, 1903.

oxid added to the first formula makes zinc sulphate cement. After excavation the acidity of the nervocidin should be neutralized. Buckley[1] has recommended:

℞—Mentholis . . . . . gr. xx
Chloroformi . . . . . f℥ss
Etheris . . . . . f℥j—M.
Sig.—Place a little in the cavity after the rubber dam is adjusted.

Hot water supplied by a tube leading from a coil heated by electricity and attached to the water supply pipe of the fountain cuspidor has been recommended by A. F. Merriman, Jr., for the obtunding of hypersensitive dentin in cases in which dryness is not readily obtainable, nor immediately or subsequently desirable.

It is claimed that satisfactory analgesia is obtained, and that the mucous membrane of the mouth is not unduly uncomfortable, even when the heat is objectionable to the finger of the operator. The advantages of the method for excavation and grinding are obvious and most useful, particularly for trimming live teeth.

Remedies which Chemically Destroy the Fibrils for a Distance, Preventing Transmission of Sensation.—Agents which chemically destroy the dentinal protoplasm form the most extensive group of dentinal obtundents. They include salts of metals, such as zinc chlorid and silver nitrate; carbolic acid and its derivatives, and like bodies; the cresols, etc.; mineral acids, notably sulphuric, chromic, and nitric; organic acids—trichloracetic and lactic acids—(full strength); alkalies—sodium and potassium hydrates and carbonates.

Zinc chlorid, silver nitrate, and carbolic acid all cause coagulation of the fibrils of the dentin. The mineral and organic acids chemically decompose both protoplasm and the calcified tissues. The concentrated alkalies chemically destroy protoplasm and bring about its quick dissolution. Like all active chemical substances, the extent of their action depends upon the freedom with which they are applied.

The application of any of these agents, as a rule, causes pain, the degree of suffering being usually in proportion to the depth of the cavity. For this reason the more powerful agents, like zinc chlorid and nitric acid, are to be confined to cavities of moderate depth, while carbolic acid, especially in combination with the oil of cloves, may be used in the deeper ones.

Fused zinc chlorid is used in its deliquesced form, and is most active when some of the salt is still undissolved in the bottle. Its

[1] Dental Cosmos, August, 1907, p. 328.

pain in suitable cavities is a full, bearable one, gradually increasing, sometimes in waves, until a crisis is reached, when the pain gradually ceases. It has a double action, not only coagulating protoplasm, but combining with its water, owing to its affinity for the latter. On account of this property its action may be limited by warm water.

An undue action of the zinc chlorid is indicated by a throbbing pain; this indicates that the pulp has been irritated. When, as occasionally occurs, no pain is produced, no obtundent effect is obtained. If this occur regularly the drug is oversaturated with water.

Bogue has suggested that cocain crystals be incorporated with the chlorid of zinc as a means of alleviating the pain incident to the application.

Miller, following Hoffheinz, advocated the use of equal parts of zinc chlorid and chloroform.

Buckley modified this by using the following:

℞—Zinc chlorid . . . . . gr xx
Chloroform,
Alcohol . . . . . āā f℥ iv—M.

Certain moderately deep cavities may be filled with oxychlorid of zinc cement, the free zinc chlorid acting as an obtundent. This requires a prolonged action, and is only resorted to in cases which do not admit of immediate work, or in which procrastination is desirable.

A formula of wide renown is known as Robinson's remedy; this may be made in one of two ways:

℞—Potassium hydrate
(or Sodium hydrate),
Carbolic acid . . . . . p. æq.—M.
Reduce the gelatinous mass formed with alcohol.

Or,

℞—Sodium hydrate (deliquesced),
Calvert's crystal carbolic acid . . . . p. æq.—M. (Huey.)
The liquid formed is spoiled when it effloresces upon the sides of the bottle neck.

The painfully caustic action of the sodium or potassium hydrate is modified by the carbolic acid.

The application of Robinson's remedy is useful in the simpler cavities and about the undecayed but hypersensitive necks of teeth and on occlusal surfaces. It is escharotic to the gum.

If this remedy or zinc chlorid be required about the periphery of deep cavities the plan suggested by Jack, of varnishing the cavity floor with chloro-percha as an impenetrable protective is valuable.

A method similar to the use of Robinson's remedy consists in applying carbolic acid to a cavity and then without removing it, placing a few granules of sodium dioxid.[1] Sodium dioxid alone in a slightly moist cavity, liberates nascent sodium hydrate (also H_2O_2), which will destroy the gum protoplasm, and is somewhat effective in hypersensitive dentin.

Carbolic acid in concentrated form may be applied to any cavity. Jenkins, of Dresden, has recommended that it be used hot; it is particularly useful for cavities containing masses of softened dentin. A variation consists in the application to the cavity, upon a pellet of cotton, and heating it with a hot burnisher.

Sodium bicarbonate is at times an efficacious remedy, and may be freely applied to the moist cavity. A 20 per cent. solution of ammonium carbonate, applied for five minutes or longer, is useful.[2]

The nitrate of silver powerfully coagulates fibrillar protoplasm, forming the albuminate of silver, which turns black upon exposure to the light. It is useful in posterior teeth well out of view, and to which the rubber dam cannot well be applied. It is also useful about undecayed hypersensitive necks of molar teeth. It penetrates the dentin for a short distance. For this reason its use is ordinarily confined to posterior teeth, though in some obstinate cases of hypersensitive necks of lower incisors and cuspids it may be used. To prevent the production of hypersensitivity in teeth ground for bridge-work, it should be applied over the entire crown. It may be used in saturated aqueous solution upon the dried dentin, or the crystal rubbed upon the slightly moistened dentin. The crystal or fused silver nitrate rubbed upon abraded and sensitive occlusal surfaces often affords much comfort.

Craven's method consists of taking up a few crystals upon a hot platinum wire, and then fusing them into a button upon its roughened end. This is then rubbed upon the dentin.

Miller has shown that the silver deposit lessens the penetration of acid decalcification (Fig. 376).

The subsequent use of sodium chlorid assists in partially removing the stains, argentic chlorid being formed.

Register has suggested the use of iodin followed by ammonia for this purpose.

Coming into contact with an amalgam filling, or a bit of amalgam, an intensely black deposit is instantly produced, which, while acid at first, is useful in slowly obtunding dentin in cavities out of view. Curiously enough, not all amalgams do this.

[1] H. J. Moore: Dental Review, 1906. [2] Thiesing: Dental Cosmos, Nov., 1903.

For severe cases not yielding to local treatment at the time desired, the following has been recommended.[1]

℞—Trioxymethylene
Orthoform . . . . . p. æq.
Make into a paste with carbolic acid.

Or,

℞—Menthol crystals . . . . . 5 parts.
Phenol crystals . . . . . 4 parts.
Reduce to a syrupy liquid to be used in place of the carbolic acid in the above formula.

This paste is applied to the cavity walls over even decayed dentin, covered with a pellet of cotton, and sealed in with temporary stopping or cement for twenty-four hours only. Formaldehyd gas is liberated in the nascent state and desensitizes the fibrils by harden-

FIG. 376



Dentin treated with silver nitrate at *a* only; the entire surface subjected to acid action shows penetration at *b*. (Miller.)

ing and fixing them as in histological specimens. The orthoform acts as an anesthetic during the action of formaldehyd. This principle has been used in cavities with the ordinary 37 per cent. formaldehyd solution, applied by the pressure method, and is useful about the hypersensitive necks of teeth. Buckley[2] has recently introduced a modification in a paste form having similar action.

℞—Neothesin (Lilly) . . . . . $\frac{1}{300}$ grain.
Trioxymethelene . . . . . $\frac{1}{43}$ grain.
Thymol . . . . . $\frac{1}{270}$ grain.
Petroleum base, coloring matter, and fibre.
(The figures indicate the approximate quantities in one application.)
S.—Apply to dry dentin and cover with cement for twenty-four to forty-eight hours.

[1] G. Mahe, M.D., Paris: Dental Cosmos, 1904.
[2] Items of Interest, December, 1914.

In shallow labial cavities it is to be applied and covered with very adhesive cement.

In shallow cavities and upon abraded surfaces, nitric and chromic acid accurately applied in small quantity upon a gold probe is useful. Any softened dentin must later be removed and filled.

For very obstinate cases of cervical hypersensitivity, Flagg recommended the use of the electric cautery, the spots to be seared. A very hot burnisher may occasionally serve.

Aside from the treatment of hypersensitive dentin, at the time of operation, analgesics may be introduced for their power of gradually lessening the hyperirritability of fibrillar protoplasm. If cotton wedges are introduced, antiseptic analgesics, particularly oil of cloves (or eugenol), equal parts of oil of cloves and carbolic acid, and phenol camphor, or Fletcher's carbolized resin, may be used on the cotton with advantage.

A partially prepared cavity may be moistened with eucalyptol and temporarily filled with temporary stopping or gutta-percha. This affords rest. If the gutta-percha leak, the cavity will be more sensitive.

A temporary filling made by mixing zinc oxid with Fletcher's carbolized resin or eugenol to a stiff paste will endure for some time, and reduce hypersensitivity. It is also useful as an antiseptic sedative test filling.

℞—Carbolic acid,
Colophony . . . . . āā ʒj
Chloroform . . . . . fʒss—M.
(Fletcher.)

The use of chalk applied nightly in a superficial cavity, as at the cervix, is useful for this purpose.

In cases in which devitalization is intended, arsenic may be used as an obtundent to effect a deeper placing of another portion as a devitalizing agent; twenty-four to forty-eight hours are required for this purpose. If left long enough it will devitalize the pulp even through a large mass of dentin.

There is no safety in short applications as a means of obtunding dentinal hypersensitivity. The pulp may die even after seeming excavation of all affected dentin.

Ninety per cent. of cavities may be comfortably excavated with sharp instruments by the aid of dryness and carbolic acid or simple obtundents. A small percentage require the use of strong caustics, etc., while in a still smaller number some of the extreme measures are necessary, though nitrous oxide is admissible in all cases.

During seasons in which acid fruits are consumed, much hypersensitivity may be induced. This should always lead to examination for cavities of decay, but such may not exist or may be properly filled.

For hypersensitivity about undecayed necks of teeth, the mouth should be kept in an alkaline condition by means of dilute phenol sodique or sodium bicarbonate, or, better, by the use of more lasting mild alkalies, such as chalk, or milk of magnesia, or a combination of the two. The manufacturers of milk of magnesia recommend a series of oil mixtures; 6 drops of any mixture to be shaken up with the contents of the original bottle as a flavor to remove the naturally raw taste of the preparation, which is disagreeable to some persons.[1] The following are two of the simplest.

℞—Oil of bitter almond . . . . . 1 part.
Oil of anise . . . . . 3 parts.

Or,

℞—Oil of cinnamon . . . . . 3 parts.
Oil of wintergreen . . . . . 4 parts.

The use of potassium carbonate in glycerin is indicated and may be given to the patient for free use.

For hypersensitive incisal edges or occlusal surfaces, Robinson's remedy may be thus dispensed with a caution as to its caustic nature.

At times zinc chlorid, Robinson's remedy, and silver nitrate or the actual or electric cautery must be used by the operator.

In a number of the localized cases fillings may be subsequently required unless rigid prophylaxis be practised. Prophylaxis may remove the superficial desensitized layer, and the application require renewal. I have been informed that a case of general hypersensitivity was cured by the lemon juice treatment given for systemic condition. The idea is worthy of attention. It might be explained upon the principle of induced alkalinity of salivary secretion as organic acids are known to increase the alkalinity of the urine.

In cavities not permitting exact excavation, oxyphosphate of copper cement left for a considerable time will often reduce exquisite sensitivity.

The use of potassium sulphocyanate internally in case of great general dental hypersensitivity has had good results claimed for it, especially in pregnant women. (See p. 361.)

[1] Items of Interest, 1905, p. 977.

CHAPTER XIV.

DENTAL CARIES: THERAPEUTICS AND PROPHYLAXIS.

According to the depth of invasion and variations in the therapeutics involved, caries may be divided into eight stages, as follows:

1. Superficial caries, or that stage in which the enamel has been partially decalcified, but the dentin not affected (Fig. 338).

2. Simple caries, in which the dentin has been affected slightly, in such manner as ordinarily to compel the formation of a cavity and its filling (Figs. 344 and 347).

3. Deep-seated caries, in which the complete excavation of the cavity renders pulp injury a possibility, but the pulp is not very dangerously approached (Fig. 353).

4. Almost exposed pulp. This is a refinement of the preceding stage, in which pulp exposure becomes imminent during excavation of the cavity and special therapeutics are demanded (Fig. 377).

5. Exposed pulp, in which the actual exposure of the pulp by decay or by accident or intention during excavation renders its treatment necessary, or in which disease of the pulp compels canal treatment.

6. Perforation by caries, in which after pulp death secondary caries of dentin and cementum has caused an opening into the pericemental tract (an extension from the condition in Fig. 362). (See Fig. 378.)

7. Loss of crown by caries.

8. Loss of root by caries.

Each of these stages of caries requires special consideration and a therapeutics adapted to each.

THERAPEUTICS OF SUPERFICIAL CARIES.

About cavity margins, beneath green stain, etc., along buccocervical margins, and at points of approximal contact of teeth may frequently be seen areas of enamel decalcification, the enamel not being entirely penetrated (Fig. 338).

It is possible at times to remove the decalcified portion by means of carborundum strips, files, or disks. If the surface be highly polished by means of pumice and chalk, and subsequent prophylaxis be employed, the practice may be endorsed for the better grades

of teeth, and particularly in the anterior part of the mouth. As a rule, however, the attempt to remove supposed superficial enamel caries demonstrates the fact that the enamel is deeply affected, and in all probability the dentin as well. The attempt to remove such caries upon proximal surfaces by files and stones results in tooth deformity, the exposure of dentin to the fluids of the mouth, and the destruction of the contact points, except, perhaps, when in the anterior teeth a lingual approach is made. It is sometimes proper to remove the slight superficial caries found about a cavity, either prior to excavation in order to determine the real cavity boundary, or after excavation if such removal would give an even better tooth form, and lessen a recurrence of decay, or, in some cases, after filling when both filling and margin are reduced together to a proper form and integrity of enamel. Some judgment is required in such a matter, and no enamel should be so treated if any doubt exist as to its future integrity, but the cavity should rather be extended to include the doubtful area.

It may be considered a safe rule to examine, by means of the electric mouth lamp, any cases of suspected superficial caries in order to determine the depth of enamel invasion.

The large majority of such cases, especially in the poorer grades of teeth, will be found to be of the class called here simple caries.

Upon the labial or buccal surfaces of anterior teeth a superficial decalcification may be found. Whether (1) this shall be removed and the surface polished, or (2) be left for the patient to care for by exact prophylaxis, or (3) be excavated and filled, depends upon the location, the depth of penetration, and the progress of the enamel decalcification. The writer has carried forward for a long time numerous white crescentic markings by prophylaxis which removes microbic plaques and food and aborts decalcification, though not removing the tissue decalcified.

In posterior teeth staining with silver nitrate alone or by touching later with amalgam to produce a rapid deposit of silver, grinding off with stones and then touching with silver nitrate, or filling the actual cavity with oxyphosphate of copper and staining and watching the remaining decalcification, have all given good results when conjoined with improved prophylaxis by the patient. Superficially decayed cementum may be removed or not and silver nitrate applied.

THERAPEUTICS OF SIMPLE CARIES.

The cases cited above as requiring excavation and all detectable cavities of very limited depth may be classed as cases of simple caries. The teeth should be wedged apart if this be needed for access,

all decalcified enamel and dentin removed, the cavity properly extended and shaped, and, as a rule, a metal filling inserted. All fissures about a cavity should be freely opened to their extremities, and made a part of the general cavity.

The extension upon approximal surfaces should include all superficial decay that cannot be so disked off as to bring the filling margin into the embrasures.

The treatment of simple approximal cavities is a difficult question. Undoubtedly extension enhances the longevity of the fillings. At times, however, the cavities may be kept purely approximal and by the use of gutta-percha, silicate cement or combination of amalgam and cement renewed or repaired as required, the case can be controlled for many years. This may be advisable in anterior teeth where gold may be objectionable or when systemic conditions or uncontrollable sensitivity warrant it. In the main, if endurable, cavities in posterior teeth should be extended, otherwise the renewal of the fillings will probably in time be necessary. In the anterior teeth esthetics often warrants keeping the cavities small. The question is one which can be settled after consideration of all the requirements. Subsequent prophylaxis is of importance, and to that end all fillings should be made as smooth and perfect as possible.

If a simple cavity prove inordinately sensitive, the more powerful remedies may be freely used to reduce the hypersensitivity, and the cavity should be treated with carbolic acid before filling, particularly when gold is to be used in cervicolabial cavities of incisors. By this means the subsequent effect of thermal changes is lessened.

THERAPEUTICS OF DEEP-SEATED CARIES.

In this stage of caries there is usually, although by no means always, an easily discoverable cavity of size (Fig. 353). After the removal of ragged and overhanging enamel margins, and of loose debris in the cavity, it is noted that the response to thermal impulse is painful and prompt. In washing such cavities, water at a temperature of about 100° F. should always be used; cold or very hot water being only employed in cavity irrigation to test the promptitude of response upon the part of the pulp. It is better to do this habitually.

In treating hypersensitivity of dentin carbolic acid is to be preferred, the mineral acids are avoided, and if strong agents like zinc chlorid or Robinson's remedy are used, the cavity floor is to be varnished with chloro-percha or "cavitine" varnish, which are impermeable. If necessary the sedative temporary methods may be employed. (See p. 414.)

The use of nervocidine or of trixymethylene are most applicable if sittings are a few days apart. For methods of dealing with hypersensitivity see p. 393.

Cocain cataphoresis is regarded as admissible in all stages of caries.

The removal of all the softened dentin, which should be done in these cases, forms a cavity of such magnitude that proximity to the pulp is evident. The softening has proceeded for a distance beneath the enamel, so that when all softened dentin is cut away from beneath it the latter tissue may overhang the general cavity unsupported. These overhanging walls are cut away until the region of strong enamel is reached, and then it may be that the walls still overhang the general cavity. It is usually not necessary nor advisable to remove this portion of enamel.

At the completion of excavation the pulpal wall of the cavity will be in fair proximity to the pulp. A blast of cool air from a chip syringe may produce an immediate response upon the part of the pulp, vigorous in proportion to the thinness of its dentinal covering and its irritability.

In many cases non-conducting substances are required as intermediates between the pulpal wall and the metal filling. In many other cases the metal filling may be placed directly upon the dentin without danger. In some cases a simple layer of non-conducting varnish, such as "cavitine,"[1] will be sufficient. In others zinc phosphate or gutta-percha must be added. The degree of the response to a blast of cool air will afford a guide to the nature of the intermediate required if any be deemed necessary. In no case should varnish or gutta-percha be allowed to remain in the portions of cavity that support the covering filling material, and which is subjected to the force of mastication. The resilient nature of such substances will cause the loosening of the filling and probably induce mechanical or infective irritation of the fibrils and through them of the pulp (Fig. 377).

In some cases the undermined state of the enamel wall necessitates the use of an adhesive zinc phosphate as a means of support by replacing the lost dentin, and in such the pulpal wall may be covered and so protected from impact as well as from thermal changes.

The action of zinc phosphate upon dentinal fibrils and the pulp being a matter of some doubt, it is better that the pulpal wall be varnished before it is introduced. The varnish not only acts as an

[1] Cavitine is a solution of trinitrocellulose in subacetate of amyl. Gum sandarac in alcohol, gum copal in ether, or Canada balsam or gum dammar in chloroform, about 30 to 60 grains to the ounce of solvent and a little hydronaphthol added, makes an antiseptic cavity varnish.

impervious coating, but also serves as an additional non-conductor. If made antiseptic it is still more useful.

After the cavity is prepared it is sterilized and dried, as described in the next stage of caries, is coated with varnish, and Harvard zinc phosphate plus 5 per cent. powdered thymol mixed stiff is packed into the undercuts and over the pulpal wall, and approximately formed.

Fig. 377

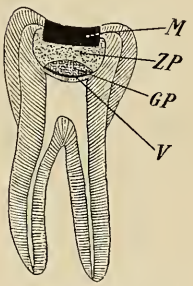

Diagram illustrating the use of pulp protectors: *V*, a layer of varnish; *GP*, a layer of low heat gutta-percha, or in case of exposure a layer of Jodoformagen, or zinc oxid and thymol in which case the varnish is omitted; *ZP*, zinc phosphate; with or without thymol added; *M*, metal covering.

When set the enamel margins are freed of cement and the cement is excavated to the form required. In some cases cement can only be placed over the pulpal wall, owing to lack of room for both cement and the covering filling. In such cases the combined use of soft cement and gold, or soft cement and amalgam, is useful.

In deep-seated caries the extension of cavity margins in such a manner as to prevent recurrence of decay is demanded. Upon approximal surfaces the ideal conditions are an extension of buccal and lingual margins to a point which will permit a contoured metal filling to have its corresponding buccal and lingual margins well irrigated by the action of the tooth-brush and food in mastication. Often a slight alteration of tooth form, together with contouring of fillings, accomplishes the end desired without undue cutting of tooth structure. Thus the cervical margin may be slightly reduced with strips or disks to assume an absence of contact, but the enamel must not be totally removed. The lingual or buccal margin may be treated in a similar manner.

The cervical margin of the cavity and filling are best protected when overlapped by healthy gum tissue, and if the gum be approached, should be so arranged. The cervical margin should always be extended beyond the contact point in such cases, whether carried beneath the gum or not. Incisal margins are to have similar consideration.

Firm approximal contact of fillings or filling and tooth are required to prevent packing of food into the interproximal space. This would both injure the gum and introduce the fermentable element in caries production. The point of contact should be neatly rounded to produce a normal contact. This contact should be obtained even if the filling must be overcontoured.

An exception may at times be made where a space has previously naturally existed, and the gum margin is healthy.

Teeth should never be joined by fillings alone, as one or both will usually loosen. If necessary for the protection of the gum, both may be crowned and the crowns united by solder, or a staple may be placed in the pulp canals of the two teeth. About this a common filling may be built. It may be that gold inlays, locked in spacious "doll heads" or the occlusal surfaces of both teeth, and extending over to distal approximal surfaces as well as into the cavities, may be joined or cast double as a means of support. The strain upon such fillings is very great when occlusion exists, as teeth are bodies with individual motion and are apt to be pushed away from the filling. (See Pyorrhea Alveolaris and Gingivitis.)

THERAPEUTICS OF ALMOST EXPOSED PULP.

In this stage of caries complaint is usually made that for some time pain has been produced by the presence in the mouth of cool or hot substances. Several classes of almost exposed pulps may be discovered after opening the cavity and removing the bulk of the decayed dentin. In the simplest class the pulpal wall may be found sound after removal of all decalcified dentin. This makes practically a case of deep-seated caries, and is to be treated as such, the close approach to the pulp simply demanding additional precautions as to non-conduction, prevention of compression, and infection. The cavity is to be neutralized with a solution of sodium bicarbonate or 5 per cent. sodium dioxid solution, etc., and dried; over the pulpal wall "cavitin" with hydronaphthol added or other antiseptic varnish, and dried again.

℞—Hydronaphthol . . . . . gr. ij
Alcohol . . . . . gtt. xx—M.
Add to the half-ounce bottle of "cavitine."

A thin wafer of softened gutta-percha is to be laid over the pulpal wall in such manner as not to interfere with the introduction of cement. In place of these any of the pulp capping cements may be used as a first layer (Fig. 377). Harvard zinc phosphate mixed to consistency just suited to the case may be pressed laterally into the undercuts, and will spread nicely over the gutta-percha without pressure. Under no circumstances must the superstructures depend upon the gutta-percha base as a support, as the filling may loosen or the wall be broken.

The operation may be varied for cases of but limited retaining periphery by gently spreading the zinc phosphate over the varnish, or, in some cases, the gold and zinc phosphate or amalgam and zinc phosphate combination may be required.

In the use of gold and zinc phosphate a portion of crystal gold is gently tapped into a mass of soft, quick-setting cement placed over the varnish and the setting of the cement awaited. The gold is then condensed and more added.

With the amalgam and zinc phosphate combination, after placing the gutta-percha, soft cement is placed upon one cavity margin, and a ball of previously prepared amalgam is laid upon it. Pressure upon the amalgam by means of a ball burnisher causes the cement to be spread over the cavity wall in advance of the amalgam. It practically inlays the metal filling, but permits a better marginal joint with the metal. The margins are freed of amalgam and cement, and the operation is completed with amalgam. It also prevents the shifting and dislodgement in any degree of the metal filling which sometimes occurs in the act of introduction, unless guarded against.

This, of course, refers to locations in which the latter is indicated. The cement in the combination increases the adhesion and prevents leakage and the discoloration of the walls by the amalgam. A trifle of thymol added to the cement (1 to 20) imparts to it an antiseptic character without impairing its integrity as a cement.

The second class of almost exposed pulp is that in which thorough excavation would cause exposure of the pulp.

If the dentin be of the disintegrated, boggy sort, it should be removed regardless of exposure; but if it be simply softened by decalcification and be quite firmly adherent to the cavity floor, and particularly if it be somewhat thickly distributed, the deeper layers may be left *in situ*, as a pulp covering.

In such cases all lateral walls should be thoroughly excavated and only a thin layer left over the pulp horns. While, without doubt, the tubules of decalcified dentin are liable to be invaded by bacteria, Miller has shown that frequently such dentin may exist without invasion. (See Fig. 356.)

The argument that such dentin contains poisonous products of bacteria deleterious to the pulp does not seem borne out by results in carefully handled cases. Decalcification is not putrefaction.

That some of these protected pulps may die is a fact not to be disputed, but that many live in security is also true. Whether such dentin can be recalcified has not yet been scientifically shown, but certain cases treated with oxychlorid of zinc have shown evidences of it, and Miller records cases of hardening of such caries even without treatment.

The treatment required for this dentin is: (1) Neutralization of the acid present; (2) saturation with a permanent antiseptic; (3) an antiseptic non-conductive covering.

After drying, a weak solution of sodium bicarbonate or ammonium carbonate will accomplish the first requirements. The dentin is then thoroughly dried and saturated with "cavitine" varnish containing hydronaphthol, or a solution of Canada balsam containing hydronaphthol, or thin chloro-percha containing aristol or iodoform, or the formaldehyd preparation known as "Jodoformagen" may be spread over it, or oxychlorid of zinc, the fluid of which has been diluted one-third with water, may be used as a covering (use fluid, 2 drops; distilled water, 1 drop), or a mixture of zinc oxid and thymol may be melted over it.

Williams[1] suggests that the decalcified dentin be first saturated with absolute alcohol for one minute, then dried, then wet with oil of cloves for one minute, then again dried, after which the varnish, etc., is to be used. Solution of sulphate of copper may be used to saturate the dentin, after which it should be dried and encased in varnish, etc. This last only in posterior teeth.

The use of these preparations obviates the necessity of sealing temporary antiseptics in the cavity, as they are in themselves more or less permanently antiseptic. The rigid preparations are most convenient. Over them zinc phosphate, made antiseptic with thymol (1 to 20), is packed or flowed, and if any doubt exist, the cavity is temporarily sealed with gutta-percha or temporary cement. When all doubt is at rest the metal filling may be placed. In another method, useful in doubtful cases in determining the possible bad reaction of the pulp, a quite stiffly mixed paste of eugenol and Hubbuck's zinc oxid may be introduced into the base of the cavity, gently pressed to place with cotton, and covered with sandarac on cotton, or at a subsequent sitting part of it may be left as a reasonably firm antiseptic foundation. If desired, the entire cavity may be filled with it, or better, to a slightly concave surface. Exposed to the saliva it hardens to a degree sufficient to act as a cement temporary filling for weeks or months, or, occasionally, even years.[2]

In some cases of deep-seated caries in which gold filling is desirable, but in which linings are contra-indicated, yet in which immediate filling with metal would involve such thorough excavation as to endanger pulp vitality either as the result of excavation or subsequent thermal shocks, oxychlorid of zinc may be placed in the peripherally prepared cavities, and over considerable masses of decalcified dentin. If allowed to remain for several months (three to six) the oxychlorid stimulates the pulp to the formation of some secondary dentin, and complete excavation to a sound basis may be made. There is also

[1] Items of Interest, 1898.

[2] Dr. S. Blair Luckie.

some evidence of hardening of the dentin. This method is open to the possible objection that secondary dentin is a source of future trouble, but the method has its advantages in badly decayed anterior teeth.[1] In very deep cavities the fluid of the oxychlorid should be diluted one-third with distilled water for the first portion.

In these cases porcelain inlays, with their underlying cement, should have due consideration as therapeutic means.

In deep and very deep-seated caries, in situations in which discoloration is not of great moment. Jodoformagen may be placed over the pulpal wall, avoiding the bearings and the cavity filled with oxyphosphate of copper for its antiseptic value. The cavity may be entirely filled with it, or it may be used as a combination with amalgam. Copper amalgam alone ordinarily becomes disintegrated and caries recurs. Occasionally it lasts well (especially Sullivan's); copper and its salts are germicidal in a short time. The ordinarily good behavior of somewhat doubtful dentin under it is thus explained.

Dobrzyniecki[2] (Budapest), in eight experimental cases upon microscopically sound-looking dentin, claims to have found the Bacillus gangrenæ pulpæ vital after months of enclosure under sealed dressings of camphor, concentrated carbolic acid, or eucalyptus oil. All other organisms were devitalized. As Arkövy's[3] experiments showed the decided influence of carbolic acid over this organism, and as root-canal antiseptics are nearly always successful in cases of moist gangrene of the pulp (Bacillus gangrenæ pulpæ Arkövy), the difficulty of destroying this germ by germicides left indefinitely in the cavity must be accepted with reservation.

In some desperate cases with the walls frail, the cements, either zinc phosphate or so-called silicate cements, or oxyphosphate of copper cements, may be used as a last resort before crowning. The silicate cements are less soluble in the acids contained in saliva or formed from carbohydrates against the filling than are the zinc phosphates.

Hinkins and Acree[4] claim that one-fifth of 1 per cent. is sufficient to dissolve the zinc phosphate, and that enough acid elements enter from the blood to affect it.

The silicate cements dissolve more readily under friction than under the action of acid, so that of two fillings the one which is not

[1] In some cases of this sort seen by the writer, and observed for from ten to twenty years, the ill-results of oxychlorid of zinc claimed have not been observed. In one case, after sixteen years, a lateral incisor crown broke off, and the pulp was found to have receded, but was otherwise apparently healthy. The question is one of the advisability of immediate devitalization, with its advantages and disadvantages in anterior teeth, or of a possible remote pulp death, etc.

[2] Söderberg upon Arkövy: Dental Cosmos, 1899.

[3] Ibid.

[4] See Dental Cosmos, June, 1901, and March. 1905.

exposed to attrition or brush action is usually in better condition after about two years. Much care is necessary to prevent the discoloration of silicate cements.

THERAPEUTICS OF EXPOSED PULP.

The exposure of the pulp may be the direct result of caries; the removal of boggy, disintegrated dentin may produce it, or it may be the result of the removal of a last layer of decalcified dentin or of the careless or inadvertent perforation of sound dentin by instruments. Fracture or abrasion are occasionally responsible for exposure. Erosion rarely causes it.

Diagnosis.—After excavation of the cavity, washing with tepid water, and moderate drying, direct vision or a reflected image in the mouth mirror may reveal the area of exposure as a round opening occupied by a pinkish or red body. If the exposure be reasonably large, pulsation of the red body may usually be observed. The exposure may be so slight as to be invisible, the depth of the cavity, however, indicating that exposure probably exists. Bleeding is a certain guide, but bleeding from the gum margin must be borne in mind. Truman advises that finely carded cotton be gently passed over the cavity walls, exposure being detected by the momentary pain produced when the fibres pass over the area of exposure.

As this test may fail, in cases of known exposure, it is not altogether reliable, but is fairly so when pain is produced, though hypersensitive dentin must be borne in mind.

A finely pointed probe may be gently dragged over the pulpal wall and catches in the orifice of exposure, however small. A slight, quick start upon the part of the patient is usually elicited. This may consist simply of a winking of the eyelid. Flagg warned against requesting an affirmative nod by the patient, as this would cause injury to the pulp. Delicately used, this test is the most reliable in all classes of cases, and is not painful.

It is to be remembered that disease may have caused a loss of a portion of a pulp horn, in which case the cotton test will fail; gentle exploration will detect the amount lost. Blood, or pus followed by blood, or sensation after entering the horn of the pulp cavity, are evidences of exposure.

Excruciating pain following mastication, or pressure or suction exerted upon the cavity by means of the tongue, are subjective symptoms indicating a probable diagnosis of exposure. Increase of pain, or throbbing pain following the use of salt, sweet, or acid foods, is fairly indicative of a practical exposure.

Treatment.—An exposed pulp is either to be capped or removed and the canals filled.

The consensus of opinion is that ordinarily all pulps should be removed, except those freshly exposed by removal of simply decalcified dentin and by accident. There is no certainty that pulps exposed by caries or practically so will live under capping materials, but the attempt may be made at times for special reasons.

Freshly exposed pulps may be capped or removed. Perhaps a good rule would confine capping to anterior teeth of the better grades in patients in good physical condition, and to pulps in teeth having incomplete roots. The improved methods of pulp removal and canal antisepsis warrant pulp destruction as a safer method than capping in most posterior teeth. Even in anterior teeth pulp removal for anchorage purposes, if needed, is quite warrantable. The advantages of capping are maintenance of tooth translucency and the avoidance of canal work.

The disadvantages are: (1) Possible death of the pulp by hyperemia due to conduction of thermal changes. (2) An overproduction of secondary dentin, the production of pulp nodules, or other degenerative changes, the pulp becoming exhausted and death ensuing. Increased difficulty of canal treatment may result. (3) Disease of the pulp due to infection beneath the capping material. (4) The time required for assurance of success or failure.

The object sought in capping is the protection of the pulp from thermal changes, infection, and compression, as either is fatal to pulp vitality. This is best accomplished by placing in contact with the pulp an antiseptic paste beneath a metal cap, or an antiseptic cement having, when set, sufficient rigidity to permit other work to be done. In the latter case the capping material may be spread over the pulp by means of an instrument or be carried on oiled paper which may be stripped off after the cement has set.

Prognosis is favorable for the cases selected as suggested.

Pulp Capping.—The metal cap should be made of platinum or gold for anterior teeth. Tin, lead, or silver may be used posteriorly. After punching or trimming to shape it should be made concavo-convex by pressing it into soft wood by means of the rounded end of an instrument handle. A film of wax is placed on the convex side; a warmed, small burnisher is attached, and the cap is adjusted in proper position by trying in the cavity. It is then to be filled with the capping material (a little of the latter placed in any depression at the point of exposure in order to exclude air); then one side of the cap is laid upon the dentin and the other gradually brought down, and the edges of the cap firmly adapted to the dentin. This causes

the paste to exude from beneath the cap. Any excess is gently removed with an excavator if not of an immediately setting paste. A little soft, quick-setting, zinc phosphate cement plus thymol or oxychlorid of zinc cement is now run over the floor as a protection and when set is allowed to go as a test. Later a partial excavation of the cement is done and better zinc phosphate or silicate cement placed, or gutta-percha used as a further test, which is allowed to remain a year.

These may be renewed as worn out if desirable, or a portion of the covering filling may be cut away and metal introduced. In all cases capping materials are not to be allowed to support the superjacent filling materials which should have their own support upon the cavity walls as shown in Fig. 377). In case a plastic filling is desirable in any event, the operation is to be completed at the time of capping or at a subsequent sitting.

The materials used with success as pulp cappers are:

1. A mixture of oil of cloves and zinc oxid (equal parts of carbolic acid and oil of cloves may be used as the menstruum). Hubbuck's zinc oxid or cement powder may be used. This is mixed to a consistency which will flow, yet set after some hours or days.

2. Oxysulphate of zinc, the fluid of which is a saturated solution of zinc sulphate in water. The powder is uncalcined zinc oxid. This will make a thin, creamy paste which flows readily and sets quickly. A trifle of aristol, iodoform, or hydronaphthol may be added to any setting cement.

3. Plaster of Paris mixed with a 1 per cent. solution of formaldehyd in water will make an antiseptic, quick-setting paste.

4. "Jodoformagen." This substance is said to have a mixture of eugenol and carbolic acid for the fluid, while the powder is of zinc oxid, containing paraform, the solid form of formaldehyd. It also contains salts of iodin. A cement is formed which sets quickly, and must, therefore, be made very thin when placed in the cap. This material has been successful as a capper even in exposures by caries, owing to its intense germicidal power. It is claimed that the formaldehyd penetrates the tissue of the pulp for a distance, yet permits its return to normality.

5. Oxychlorid of zinc, with the fluid diluted with 50 per cent. of distilled water (1 to 2), will cap successfully. It is well to add a little powdered thymol to lessen irritation and add antisepsis.

6. Crystallized thymol can be gently melted on the end of a burnisher and dropped on the point of exposure to crystallize, or a piece of a mixture of thymol and zinc oxid, made by melting the former and incorporating the latter, may be added to the drop of

thymol in position and melted with a warm burnisher. Setting cappers may be used without metal. Of these capping materials the writer prefers jodoformagen, which though proprietary, has positive sedative as well as germicidal and persistent antiseptic value.

Results of Capping.—If pain be initiated when the cap is placed and recur later, compression has occurred, and the capping must be removed, the pulp quieted, and the capping renewed or the pulp removed. Though no sensation be produced at the time of operation, a reaction to thermal changes may occur. If this gradually subside as counter-irritants are used, a diagnosis of arterial hyperemia (aseptic) is confirmed. If the reaction increase, the heat become more irritating than cold, and if at the same time paroxysms of pain or reflex pain occur, the diagnosis is that of venous hyperemia or infective inflammation, according to the character of the symptoms, and the pulp must be removed. In cases of incomplete roots the large foramen prevents the formation of a venous stasis. Even if the pulp be kept alive only until root completion, much good will be done. As an example, in one case a lower second molar, exposed by caries and capped at the age of fourteen, at twenty-five years reacts as vital to an interrupted electric current, and is perfectly comfortable.

A pulp may remain quiescent for weeks or months and then unfavorable symptoms set in, or it may die without any apparent pain. It is probable that in the latter case some reflex pains have been felt, but not related with the tooth, in the mind of the patient.

In the successful cases, either the orifice of exposure is covered over by a deposit of secondary dentin, or the pulp remains perfectly quiescent beneath the capping material, without formation of deposit.

Even when a deposit occurs the pulp may die from the atrophy and degeneration attendant upon the formation of much secondary dentin, and when no deposit occurs infection following leakages about filling and capping materials may take place after years of apparent success. While capping may be, and has been, successful in all grades of exposure, there is no certainty of success in the exposure by caries. The tentative treatment necessary offsets the labor of canal treatment. The alternative to capping the pulp is its removal. This requires a special chapter (which see).

THERAPEUTICS OF PERFORATION BY CARIES.

The progress of secondary caries in the dentin about the pulp chamber hollows out the root until at least at one point the chamber wall is but a decalcified layer of cementum covered by decomposing dentin. At some point the pericemental tissue will be uncovered by

excavation or by the carious process (Fig. 378). The crown will probably be badly decayed. Taking, as an example, a lower molar perforated at the bifurcation with the pericemental tissue hypertrophied into the opening (fungous gum), its treatment may be described as follows: The gum is first to be pressed out with cotton

Fig. 378

Diagram of treatment of perforation by decay.

Fig. 379

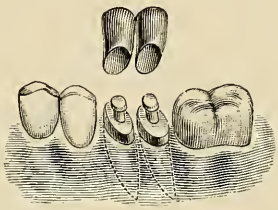

Crowning of divided roots. (Evans.)

medicated with an antiseptic varnish. Fletcher's carbolized resin, or aristol in chloroform, or sandarac varnish plus orthoform, will serve.

If immediate work be desired, polypoid fungous gum may be saturated with trichloracetic acid and cut away without bloodletting

Fig. 380

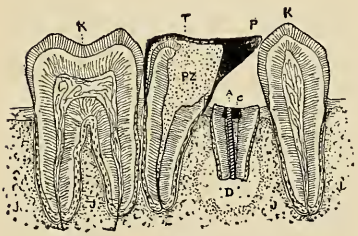

Cantilever crown. (Evans.[1])

Fig. 381

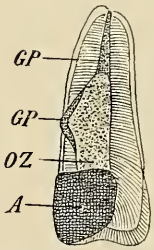

Diagram of a lateral perforation treated with gutta-percha; successful for seven years, when breakage of the crown occurred including the perforation: *GP*, gutta-percha; *OZ*, oxychlorid of zinc; *A*, amalgam.

by means of a large, sharp, spoon excavator, or cocain or ethyl chlorid may be used for local anesthesia. Large, rose-head burs are used to free the cavity of all decay. The canals are opened and

[1] Artificial Crown and bridge-work.

treated. If further treatment be desired, or be impossible until the perforation is disposed of, metal or wooden pegs (the Downie broach reamers will serve) are placed in the canals and a reasonably thin layer of copper amalgam is built about the pins and over the perforation. A slight movement of the pegs will permit their withdrawal, leaving openings in the amalgam through which the treatment may be subsequently conducted. The amalgam is then allowed to harden (Fig. 378). To carry on the treatment while hardening, formocresol on a cotton pellet may be inserted over the openings in the amalgam and sealed over with soft cement.

After canal filling the canals may be further reamed for screws or pins, which are inserted and the operation completed with amalgam, or zinc phosphate and amalgam if the condition of the crown admit of it; or, if crowning be required, this is arranged for in the building up with amalgam.

A long perforation at a bifurcation may practically divide molar roots. This is to be made a complete division after treatment of the canals. Each section may be fitted with a pin and amalgam stump, to which a gold barrel is fitted. The barrels are each given an occlusal face, or the two a common occlusal face, and soldered together (Fig. 379).

If one root be unsuitable it may be extracted and the other used as a foundation for a cantilever crown, a spur from which rests slightly upon the occlusal face of the adjoining tooth (Fig. 380), or the crown may carry a spur which rests in an inlay or filling in the adjoining tooth.

A smooth plaque of low-heat, white gutta-percha (not temporary stopping) makes an excellent covering for a perforation. It is made larger than the opening covered, warmed, pressed to place, and the edges sealed with a hot burnisher. The covering filling will retain it in position. The approach to the perforation should be widely funnelled to permit a ready adaptation. A splendid covering for accessible perforations is found in oxyphosphate of copper cement. The opening should be funnelled, the parts dried thoroughly and the cement properly mixed can be painted over the orifice, adhering tenaciously to the tooth and soft tissue without pressure. It exercises an antiseptic influence. If sepsis occur, the resulting abscess will occur opposite the perforation, or in some cases create a small pocket similar to a pyorrhea pocket. In all cases judgment must be exercised, and the attempt to conserve unsuitable cases avoided (Fig. 381). (See also Chapter XX.)

THERAPEUTICS OF LOSS OF CROWN BY CARIES.

If the portion of crown left after excavation be self-sustaining, but incapable of retaining a filling in the cavity, pins or screws may be placed in the root canal or the pulp cavity may be enlarged and made retentive. A filling is then built about or into the anchorage so made. At times the remainder of a tooth crown will support a hollow metal crown.

When the carious crown has broken away or filling has become practically impossible or undesirable, the original beauty or useful form of the tooth may be approximately restored by means of one of the many forms of dowelled porcelain crowns, specially constructed gold and porcelain crowns, or all-gold, hollow-metal crowns, or a broad band may be adjusted and filled in with amalgam after setting with cement, or where a portion of crown only remains soft amalgam may be used inside of the band to make the adaptation, and the band then filled in, completing the work on the side at which the band has no cervical adaptation. These operations have been successful for years, if the remnant of crown has any supporting ability.

If an anterior root be so hollowed out by caries as to be incapable of supporting a dowelled crown, with or without a cast base, it may be extracted, and the operation of transplantation performed, or, later, an implantation may be made.

In the former operation the existing alveolus is enlarged if necessary to accommodate a tooth; in the latter operation a new alveolus is created by means of appropriate trephines and bone reamers. The tooth is to be prepared as for replantation (which see).[1]

If teeth have been lost by extraction, the spaces created may be filled by means of bridge-work or plates of various sorts.

By common consent crown and bridge-work is considered a special department of dentistry.

Therapeutics of Loss of Roots by Caries.—This occurs in several ways:

1. After loss of the crown and the extension of the carious process into the interior of the root. In the later stages this root is rendered valueless for crowning purposes, and should be extracted. In some cases a transplantation operation would be warrantable, as in case of a single incisor, the other teeth being relatively sound. (See above.)

2. If an artificial crown has been so placed as to expose the joint to caries, the process may proceed to a considerable extent, but does not necessarily involve the root interior, owing to the presence

[1] For methods of implantation, see American Text-book of Operative Dentistry.

of the pin. Filling with amalgam or other plastic, or the recrowning is demanded if feasible. The gum having grown in, much packing out may be required; ablation may be required as well.

3. In some cases penetrating cervical caries will cause a partial or complete amputation of a lingual or buccal root of an upper molar, or, possibly, a bicuspid. The pulp, of course, will have died, at least at the carious area.

The cavity of decay should be cleansed and undercut, and an occlusal tap made for free entrance to the canals. The canals are to be reamed with Kerr broaches. The canal of the decayed root is to be enlarged with Kerr root reamers, after which everything is to be dried; a canal probe, or the largest reamer used, which may have wax in the spaces between the blades, is passed through the tap across the cavity into the farther portion of the root canal. Good amalgam is to be thoroughly packed into the cervical cavity and hardened by wafering. When nearly set, the filling is supported against dislodgement and the canal probe is carefully withdrawn. After appropriate sterilization of canals with formalin solutions, the canal is filled. If the decay has been severe, and fracture threatens, an iridioplatinum pin is to be fitted into the involved canal and the crown tap and the pin used as the canal former while filling the cavity. Later after sterilization it is cemented into the canal, thus strengthening the root against a threatened fracture.

Fig. 382

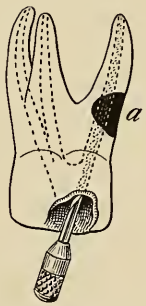

Method of restoring lost canal continuity. The cavity should have more retention form than shown, *a*, amalgam.

If actually separated by decay, excavation will make an open joint, which should be filled with amalgam after the pin has been run through the tap into the root. If this operation does not seem feasible, it is better to extract the separate root portion and trim the stump, as in ordinary root amputation.

While the retention of an amputated root is seldom demanded, the editor has several in satisfactory use. The prevention of a threatened fracture is more often demanded. (See also Heteroplasty.)

CARIES OF THE TEMPORARY TEETH.

Caries of the temporary teeth differs but little from that of the permanent teeth. The pulp cavities are, however, relatively larger, and the intensity of the carious process often causes rapid exposure

of the pulp. Owing to the flat character of the approximations of the teeth, there is often more approximal than occlusal caries, and the cavities often have weak peripheries.

Children have a fear of dental offices, excited by unpleasant experiences or the talk of their elders, and they do not mention slight pain such as that excited by hypersensitive dentin. There is, however, abundant evidence that the dentin of the temporary teeth may be hypersensitive. In cavities of simple nature the fillings indicated for adults serve if the operations are well borne.

The shapes of the teeth, the restlessness and fear of the little patients, and the free flow of saliva indicate, for the most part, the use of plastic fillings, though the rubber dam may often be readily used. In deep cavities not exposing the pulps, the methods employed for adults, of varnishing or insulating with gutta-percha and the subsequent use of zinc phosphate as a lining under metal fillings, arei ndicated. (See p. 421.) Certain occlusal cavities having small orifices and large interiors are well, and often permanently, filled with pink gutta-percha. Zinc oxid and eugenol made into a stiff paste often fills cavities acceptably, and lasts as well as oxyphosphate unless it is too freely masticated upon.

If cavities are observed before pain has been complained of, and prompt and quickly subsiding response to applications of cold water is obtained, indicating a normal pulp, the cavity should be excavated, with more regard to removing the marginal caries than to thorough excavation, dried, and an application of a 20 per cent. solution of silver nitrate made for a few minutes, the cavity being subsequently filled.

Fig. 383

Mode of preparing approximal cavities.

In cases of adjoining approximal cavities there is a disposition for the affected teeth to press together and lessen the size of the dental arch. Bonwill advised as a practice, followed by uniformly good results in such cases, to cleanse the cavities (Fig. 383) and insert masses of pink gutta-percha base-plate. The constant biting upon the gutta-percha causes a separation of the teeth, which increases the size of the arch and affords additional space for permanent successors. Hollingsworth introduced the idea of placing a small piece or cap of metal at the cervix, bridging the interdental space. A bit of gutta-percha is to be placed on the under side of the cap to make a gutta-percha adaptation; then more is built over it. Bonwill advised that before the gutta-percha masses are inserted, small pieces of blotting paper saturated with carbolic acid be laid against

the dentinal walls and the gutta-percha be packed over them. The more efficient and persistent antiseptic silver nitrate may be applied instead of the carbolic acid. Kirk advises that asbestos felt be heated to destroy any organic matter present in it which might combine with the silver, and then be soaked in a saturated solution of silver nitrate, dried, and kept in dark bottles away from the light. Small pieces of the prepared felt may be used as described. With cavities as good as shown in the illustration, wedging and contouring each tooth with amalgam, after the use of silver nitrate and varnish, is quite admissible after making suitable retention. There is no reason why occlusal extension for retention should not be made. The conditions will determine the choice of materials.

Fig. 384

Right upper temporary molar disked lingually and filled.

The silver-nitrate method is particularly applicable to shallow cavities in which excavation for filling is impracticable. The dentin surface is cleansed and dried, and the fused silver nitrate is rubbed upon the surface. This may be done after the method of Craven: a platinum wire is dipped into the powdered salt and held over a flame until the powder fuses into a button. By this means application can be directly and accurately made. The arch is apt to become somewhat contracted, and food is liable to wedge between the teeth. Combination fillings of zinc phosphate or oxyphosphate of copper and amalgam are of advantage in case of frail walls.

For the anterior teeth silicate, zinc phosphate, and gutta-percha fillings are useful, and for the posterior ones Ames' oxyphosphate of copper serves a good purpose.

Caries is very liable to occur upon the approximal surfaces of the second temporary and first permanent molar. If the former be found largely decayed distally, the latter will usually be found decayed on the mesial surface. Amalgam in cavities well extended buccally and lingually, or gutta-percha, serves well until the second temporary molar is lost, when a good gold filling may often be introduced before the second bicuspid erupts.

Well-contoured fillings must be inserted in such a case. As a preventive measure during eruption of the first molar, the second temporary molar may be disked to the form shown in Fig. 384.

If incipient or simple decay has occurred on the two teeth, or even the second molar alone, it is then best to wedge the teeth apart and to make a disk separation (on the temporary tooth only) from the lingual or buccal side, or both, and to contour the filling even in exaggeration, so that a minimum of contact shall exist. Any surface of dentin exposed by the disking should be included in the cavity, or, if this be not possible, then it should be rubbed with silver nitrate.

Such surfaces should be carefully observed at regular intervals; indeed, if prophylaxis can be regularly instituted early and before caries of the first permanent molar, much good will be done.

The pulp diseases resulting from caries of the temporary teeth will be considered with those of the permanent teeth. If the temporary teeth be so badly decayed as to be hopeless, so far as filling is concerned, they should be extracted. Occasionally the encircling of the teeth with pure gold bands cemented to place, or filled in with amalgam is good practice.

In the main the temporary teeth, especially the molars, should be filled with some view to the longevity of the fillings, as they often have to do service for years, and the general health of the mouth is improved.

The child should always be treated with kindness and truthfulness to establish faith, yet with sufficient firmness to command control.

Under no circumstances should the child be given an excessive dread of dental operations, or be broken by nervous shock, as this attitude defeats the object sought.

In one extreme case in which the child had never endured dental work, chloroform followed by ether was given and fifteen plastic fillings inserted. N_2O and O might be used for the purpose.

RECURRENCE OF CARIES.

Passing over, as disproved by Miller, the theory of Palmer, that caries recurs about fillings as the result of electric action, it may be stated, as proved by scientific and clinical experience, that it recurs because after teeth have been filled, conditions exist which may favor the collection of microbic plaques and stagnant food material even more strongly than the original conditions, and that when recurrence has been prevented, the work has been done in such a manner as to prevent such collections

The specific defects which favor the formation of bacterial plaques may be epitomized as follows:

1. Lack of approximal contact (food wedging between teeth).

2. Roughness of the filling at an otherwise good approximal contact point which menaces the approximating tooth or the margin of the cavity by causing food retention and the spreading of microbic plaques.

3. Unremoved excess of filling material at margins producing a ledge which collects food, etc. The edge of a crown may act in a similar manner. An excess well beneath the gum is more apt to produce gingivitis than caries.

4. Exposure of the cavity margin due to lack of covering by the filling material, whether not properly placed, flaked away, or due to fracture of margin during the filling process or subsequently thereto.

5. Exposure of the cavity margin due to shrinkage or shifting of the filling material. The use of material not enduring mastication in places subject to it; the washing out of cement from the joint of an inlay or combination filling or dowelled bandless crown has much the same effect, though often much delayed.

6. Solubility of the filling material, permitting the cavity wall to become exposed.

7. Roughness of tooth surface, produced by polishing fillings with rough approximal trimmers, coarse grit strips, disks, or wheels. Exposure of dentin by overpolishing may be classed with the above.

8. Lack of hygiene of surfaces which tend to decay, partly due to lack of extension of cavity margins. Even poor margins, if well extended, may not decay, whereas existing at or near contacts they are menaces. Lack of extension of approximal cavities often causes failure, through failure to include all carious enamel. Lack of extension of a filling into a fissure adjoining it, which fissure may be decayed or invite subsequent decay. Lack of extension of labial cavities sufficiently under the gum cervically and in the mesial and

distal direction, leaves a tissue vulnerable to microbic plaques if not already attacked superficially.

Treatment.—The treatment of recurrent caries does not differ materially from that of primary caries.

Repairs to obliterate crevices, breaks, or new decays may at times be made; but so often is it the case that apparently slight recurrences are found after removal of the filling, to involve the entire cavity wall, that the only sound recommendation applicable to all cases is that the filling be removed and the cavity reprepared and refilled. The exception exists when, after the new cavity of decay is all excavated, the adaptation of the filling is seen to be perfect. Decay at two or more points of recurrence not subject to accurate repair, or general inferiority of the filling should condemn the entire piece of work.

PROPHYLAXIS OF CARIES.

If the factors, or even one factor of caries be removed from the mouth, caries cannot occur. The microscopic plaques and fermentable food substances acting as the causes of caries should, therefore, be kept from collecting upon the teeth. The longer they remain, the further they may spread laterally over the tooth surface.

In the absence of absolutely exact knowledge of the relation of general systemic conditions to the production of microbic plaques, it may be said that the general health should, if possible, be maintained by the correction of any morbid body state, as, without doubt, perfect good health is a corrective of morbid oral secretions. (See p. 356, etc.)

Apart from this, oral cleanliness is of great importance, not only for the health of the teeth, but of the gums, and, indirectly, of the stomach and intestines, which can but be affected by unhealthy oral conditions. Thus while the general health may influence the mouth, the mouth may influence the general health.

It has been noted that caries is markedly lessened in well-kept dentures.

The first step in the prevention of caries is the removal of all possible causes of bacterial plaque formation. Cavities should be obliterated by means of exactly adapted, perfectly contoured, highly polished, insoluble (in so far as utilizable) fillings, the margins of which are extended into areas subjected to friction by ordinary forces, such as food excursions, brushing, etc. Departures from this principle are to be made for well-judged reasons only, and when made prophylaxis must be more rigorous.

Some dentists pursue the policy of filling only the larger cavities existing in a mouth, the others being neglected until a subsequent

period. Such a method is to be condemned as being a neglect of a plain duty and as tending to the propagation of caries in the mouth.

Periodical examinations should be made at short intervals, preferably at the time of cleansing, for cavities of decay, roughness of filling margins, or accidents to the same. By these means the soil may be rendered unsuitable to the growth of caries fungi, and their localization at the contacts and other favoring spots is largely prevented.

Silver nitrate, 40 per cent. to saturated solution, may be applied to surfaces likely to decay, as sulci, contact points, etc., as a means of prevention in mouths subject to same.[1] As a systemic and local prophylactic, the diet may be modified (see p. 361).

The presence of cavities, calculus, and pyorrhea alveolaris in the mouth all tend to cause infection of the digestive tract, with production of inflammatory (catarrhal) disturbance, and to cause infection of parts in close association with the teeth as well.

Undoubted cases of septic intoxication and infection from decayed teeth and other oral conditions have been reported, the connection having been shown by their cure after removal of the local cause alone; in other cases the parts (as the stomach) having the secondary infection well implanted, have required special treatment in addition to the removal of the primary exciting cause.[2] (See Systemic Effects of Pyorrhea Alveolaris.)

The loss of masticatory efficiency due to caries or the associate pain has a direct bearing upon insalivation of food and upon gastric digestion, though in this connection bacterial infection may play a part.

School children who suffer much from caries are apt to be less proficient in their studies than normal children, the effect being probably due to that of disturbed digestion upon metabolism and thus upon mentality in general. Pain, of course, is a direct cause reducing vitality in various ways and causing loss of time and attention to the duty of study, etc. The following quotation from a tabulation[3] shows typically the effect of dental normality upon

[1] L. C. Bryan and others.

[2] Hunter: International Dental Journal, 1899, abstract from Transactions of Odontological Society of Great Britain.

In an address at McGill University, Montreal, Hunter, 1910 (see Dental Brief, November, 1911), reaffirms extensive experience with gastritis, septic anemia, septic endocarditis, etc., as the result of oral sepsis in which decayed roots and extensive dental work, (bridge, etc.), covering septic conditions were cured by removal of the cause. While caries was not separately considered, it must be seen that caries is largely responsible, as the inception of the conditions through pyorrhea is also responsible.

[3] Dental Brief, 1911. Tabulation of the Effects of Dental Caries on the Mental Powers of the Dental Class in Marion School, Cleveland, Ohio.

mental powers. It has the lowest gain, which ranged from about 32 to about 918 per cent.

	Beginning.	Present.	Difference.	Per cent. of gain or loss.
Memory	66.65	66.6	00.05	00.07
Spontaneous association	74.25	90.7	16.50	22.22
Addition	46.00	63.0	17.00	36.95
Association by opposite	59.00	92.0	33.00	55.93
Quickness and accuracy of perception	41.50	60.5	19.00	45.78

Total gain . . . . 32.162 per cent. after deducting the losses.

Insomnia and a variety of other metabolic ills have been shown to be due to carious teeth and the sepsis associated, by the prompt or gradual recovery upon removal of the teeth. How many thousands of individuals suffer from partial sepsis, in entire ignorance and possibly without actual discomfort can only be conjectured. It is exceedingly difficult to state positively that a metabolic disorder is due to the state of the mouth, unless a microscopic examination from a separate locality demonstrates identical bacteria present. Even then the therapeutic test must decide. Therefore general deductions must govern advice. In all cases it is wise to put the mouth into a hygienic state and, if necessary, add such other therapy as the systemic condition demands.

The evils attendant upon sepsis are to be pointed out to patients who have often a seeming indifference to conditions ranging from simple uncleanliness to loathsome filth within the mouth, which would alarm them if existing in any other part of the body. Aside from all considerations of health or tooth integrity, it is poor economy, and especially for poor people, to neglect these measures which are largely applicable. The prophylaxis of the teeth apart from periodical cleansings is a matter for careful instruction and exhortation of patients who are apt to be persistent backsliders. Indeed, it is the opinion of the writer that most patients accept the validity of the arguments herewith presented and then persistently neglect or even frankly refuse to carry out the treatment. It is therefore no surprise that caries persists. The deduction may be made that the cleansing of teeth at spots that ordinarily do not decay is nearly equivalent to no brushing at all.

DAILY CLEANSING OF THE TEETH.

A small, well-made, fairly stiff brush, having its brushing surface serrated, is to be grasped in the palm of the hand with the ball of the thumb placed upon the back of the handle, or exactly the reverse, according to the movement desired. The bristles are to

be passed over the buccal and lingual surfaces of the teeth, from the gum toward the occlusal surfaces, by means of a dexterous, wiping motion imparted by a turn of the wrist. Figs. 385, 386, and 387

Fig. 385

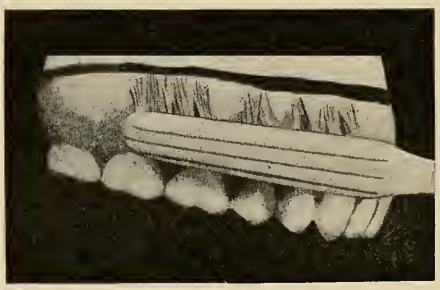

Fig. 386



Fig. 387

by S. Blair Luckie, show this. This cleanses the interproximal spaces so far as accessible to the brush. By a light to-and-fro motion, spreading the bristles over the cervices, the lingual and buccal cervices are freed of soft deposits which occur after each meal.

Unless the gums be actually torn, this light friction is not injurious. Special attention is to be paid to the buccal surfaces of third molars, which are often ignored even by conscientious patients. This is due to a habit of giving a downward sweep of the brush-tip, which escapes the rather upwardly placed third molar.

The lingual surfaces of incisors are cleansed by means of the tip of the brush. In cases of advanced recession of the gum about incisors, a brush with all the bristles except those of the tip cut away (and the stubble ground down) is advantageous. This is also useful for the lingual surfaces of bridge-work. Occlusal surfaces are to be freely brushed. Brushes of this form can be purchased.

A light brushing after each meal imparts to the mouth a pleasing sense of cleanliness, which has a good moral effect upon the patient, and removes from about the teeth much fermentable material.

The teeth should be thoroughly brushed upon retiring, to remove any debris about the teeth. A small rubber band should be stretched between the teeth, the inner end released, and then drawn through the interdental space, wiping the approximal surfaces and embrasures. This places the mouth in a fairly aseptic state for the night, during which the oral fluids are at rest and less interfere with fermentation, or neutralize its products. The brush itself should be sterilized after using. A good glass brush-holder is sold which has a small portion of paraform placed in the lower part, and is capped with a metal screw cap. In this the brush may remain until again needed.

Before breakfast the teeth should again be brushed.

Once a week the patient should rub tooth powder over the interproximal spaces, and carry floss silk between the teeth and rub the approximal surfaces, with the object of removing any bacterial collections upon these surfaces.

The floss silk should not be forced into the gum, as this will injure the gum margins and force infected material into it, but should be first carried gently beneath the gum, wrapped half around the tooth, and then sawed up over the contacts and be brought out from between the teeth. It should be reintroduced at the same interspace and the adjoining tooth polished. This use of floss still leaves at the middle of the buccal and lingual cervix a point often uncleansed (see Fig. 364). The use of the brush to accomplish this should be taught, otherwise cervical caries may supervene (see p. 384).

The lingual surface of lower incisors may usually be accurately flossed by throwing the floss around a single tooth, then crossing the strands and pulling on each alternately. This cleanses the entire circumference at the cervix, as the floss tends to go cervically

under such a manipulation as is shown by its use with the rubber dam. If there is any difficulty in the use of floss, it is due to faults about the approximal surface which should be remedied. In cases of lower incisors collecting calculus readily this may have to be done daily.

The twisted-wire bodkin shown in Fig. 389 is very valuable as a means of threading the floss through a bridge space. Being readily bent into a half-circle it returns toward the lips so as to be readily grasped. It should be bent in line with the flatness of the eye. To make them, take the temper from a thin shank like that of an old Gates Glidden drill, bend it into the form of a button-hook; over this loop a six-inch length of fine regulating wire. Revolve the hook in the engine and run the wire through the fingers of the left hand.

The periodical cleansing or prophylaxis suggested by D. D. Smith involves the monthly rubbing down of all surfaces accessible, to a wedge-shaped, wooden polishing point carried in a Jack porte. Powdered pumice is the abrasive suggested. The point is to be gently insinuated beneath the free gum margin for the purpose of effecting a cleanliness there, which shall prevent collections liable to produce pyorrhea alveolaris. (See Fig. 645.)

This method may be supplemented by a careful rubbing down of contact points and embrasures by means of floss silk, charged with powdered pumice as an additional precaution against approximal caries.

FIG. 388

Simple porte-polisher. One, shoe peg trimmed.

The slight cleansing apparently required after a few visits is a strong argument in favor of these prophylactic cleansings, and chalk may be substituted for the pumice. In case of fairly clean mouths, free of other disease than caries the patient may be instructed in the use of a shoe peg sharpened to a point, held in a simple porte-polisher, such as a tube of thin nickelled brass bent at one end to an angle of 45 degrees (Fig. 388), and the prophylaxis by the operator executed three or four times a year only. This wood point is useful in cleansing the lingual surfaces of bridge-work.

It is exceedingly difficult to instruct patients in the proper use of the wood point, but once properly instructed the results are little short of marvelous. In use it is to be held in the hand as though using the Spencerian system of penmanship. The third

and little finger rest upon the chin or teeth as a fulcrum. The point is first adjusted at the distal of the third molar and with a rocking motion of the hand it is drawn along the cervix. The rule is to "keep" on the tooth but "feel" the gum. Jumping from the buccal of one tooth to another is to be avoided. The point should be deliberately but gently drawn (not rubbed), until it rests in the interspace. Next the fulcrum fingers are slightly shifted and the next tooth cleansed.

Fig. 389

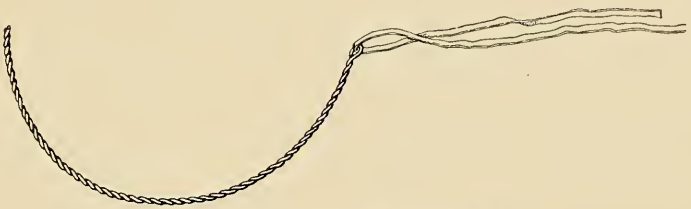

Flexible wire bodkin slightly enlarged.

When the anterior teeth are reached, the patient should begin again at the third (or last) molar of the opposite side. The motion is repeated upon the lingual surface. In no case should sight be depended upon. The sensation of contact is the best guide. As a means of instruction of the patient, tincture of iodine and alcohol equal parts should be applied and then washed off with water. The films will stain for a short time, during which the effect of the friction of floss and stick and the inefficiency of the usual brushing can be demonstrated. If desirable, the patient may occasionally use the stain as a means of self instruction.

The Dentifrice.—There is no contention as to the value of friction and the removal of the factors of caries, but of late the character of dentifrice to be used has been brought into question.

Pickerill has contended that antiseptics are of doubtful value and that ordinary alkaline dentifrices depress the flow of saliva and that, on the other hand, an acid dentifrice, as acid potassium tartrate in 1 to 200 solution, increases the flow of alkaline saliva, which being continuous neutralizes any acid formed. As aside from a detergent action, alkalinity is the object sought in a dentifrice, the method seems rational, especially as he has found that the acid does not injure the teeth.

Of his formulæ the following is said to be the most agreeable:

℞—Potassii bitartratis (P. tartratis acidi, B. P.) . . . gr. ij
Acidi tartarici . . . . . gr. j
Olei limonis . . . . . ♏ iij
Glusidi (saccharini) . . . . . gr. ¼
Aquæ . . . . . ad f℥j—M.

The contentions of Pickerill are based upon his observations of immunes, and experiments which curiously enough do not seem to include definite experimental applications to any particular individual susceptible to caries. It is seemingly becoming the fashion to claim that prophylaxis is a failure (Pickerill admits its occasional value), which will not be admitted for a moment by any one who has conscientiously performed it each three months, or oftener, with reasonable assistance from the patient (see footnote p. 358). Antiseptics are also denied a value, but even Pickerill admits their value in oral sepsis, so why can they be valueless in caries. They produce a disturbance in the medium, slight changes in which are known to affect bacteria, a fact taken advantage of by Pickerill as a claim for acid value. If disturbance of medium is of value, the frequent breaking up of plaques theoretically should be of immense value and in practice so proves.

Antiseptics have been shown to reduce general oral infection to a possible minimum when oral cleanliness is conjoined with their faithful use, but without exact prophylaxis cannot be depended upon.

The writer has found phenol sodique, 1 to 7 of water, a useful adjunct in this connection and as an occasional germicide to promote the action of milder antiseptics, the following mercuric chloride wash used for the space of two minutes is valuable:[1]

℞—Mercuric chlorid . . . . . gr. vj
Thymol . . . . . gr. ij
Menthol . . . . . gr. v
Oil eucalyptus . . . . . gtt. x
Glycerin . . . . . f℥ij
Alcohol . . . . . f℥ij
Auqæ gaultheriæ . . . . . q. s. ad. Oij—M.
S.—Use as directed as mouth wash.

The writer has found much value in the use of a potassium chlorate paste. This certainly has kept black stain from teeth which usually accumulated strong evidence of it within two weeks of prophylaxis, and caries is apparently much lessened by its use though prophylaxis is a confusing factor. Potassium chlorate has been condemned by dentists of high standing as systemically injurious, but whether such small doses as might be swallowed after tooth cleansing could be injurious has not been scientifically shown. On the other hand experiments[2] have been made on puppies which received thirty grams, daily for six weeks, were then killed and no renal lesions were found; the gastric mucosa showed no signs of irritation nor the blood any methemoglobinemia, and the animals showed normal growth. While

[1] C. R. Jackson, Dental Summary, 1904.
[2] Medical Brief, December, 1912.

large doses may have been injurious to humans this is entirely different from minute residue in the mouth. As a matter of fact, if the mouth be washed out with water no appreciable toothpaste need be swallowed.

The use of chewing gum after meals has been of value in susceptibles. Either it acts by friction, removing fermentable food or by promoting a free flow of saliva; perhaps in both ways.

Whether, however, it shall be best in the future to prescribe a weak organic acid as a dentifrice and trust to the flow of alkaline saliva or use a weak alkaline wash, as lime-water one-half strength, or even an alkaline tooth powder or paste must be decided by actual clinical experiment upon susceptibles, as immunes are valueless for observation unless they lapse from immunity. Even here the credit must not be given altogether to the acid treatment side of the contention unless prophylaxis is eliminated. In brief, the whole subject requires intelligent ventilation. We have to thank Pickerill and Gies, working on this line, for at least a new departure in our thinking regarding dentifrices.

By these means centres of infection are removed, and the problem is reduced to the care of the superficies of the teeth. Calculus should be thoroughly removed, the teeth highly polished and kept polished. This operation mechanically removes the plaques.

To prevent their return, daily cleansing of the teeth by the patient has always been practised, and a thorough cleansing once a month or oftener by the operator has been shown by D. D. Smith to be highly efficacious. The patient should be instructed regarding the location of the plaques producing dental disease. A good method is to apply tincture of iodin to the teeth, then douche them with water, which removes the iodin from the clean part. The teeth will generally then look like Fig. 321, which, while a figure of decay, will take the place of a special illustration. While thus stained the effectiveness of floss, etc., can be readily demonstrated. Inasmuch as caries is usually prevented by a thorough monthly prophylaxis followed by oral hygiene at the hands of the patient, it follows that if the bacterial plaque is frequently disturbed the most important link in the chain of factors is eliminated. Even if a systemically produced carbohydrate should be shown to be a factor as food supply for bacteria, it can produce no injury alone, while it is probable that bacteria plus extraneous carbohydrate is competent to produce caries.

Finally a dietary should be outlined which shall be proper for general health, shall reduce the carbohydrate element remaining in the mouth (as candy and cracker consumption between meals), and shall induce a flow of alkaline saliva after meals (see p. 361).

PROPHYLAXIS IN SYSTEMIC DISEASE.

During a prolonged illness, seasickness, pregnancy, etc., the prophylaxis of the teeth should be as rigidly enforced as possible as a means of preventing decay of the teeth and sepsis of the mouth.

It has been shown that during pregnancy osteomalacia may occur, and that it represents a demineralization by decalcification of the bones of the mother. Whether or not this may influence caries of enamel is not certain, though acid secretions occur from the gum margins, but there is no reason why the resistance of the fibrils of the dentin should not be lessened, or even that the dentin may not be to an extent demineralized, as positively claimed by some accurate observers (Black to the contrary). An excessive osteomalacia may be held to represent a deficiency of osteogenetic nutritive material for the child. This would lead to an inferior development of the child's temporary teeth.

Any abnormal condition of the mother should be corrected, if possible, in order that her general nutrition and that of the child may not suffer.

Probably upon the congenital constitution of the child depends much of its future susceptibility or immunity to caries.

Accepting the decalcification theory of osteomalacia, the use by the nursing or gravid mother of mild alkalies internally, such as a tablespoonful of lime water repeated, and the use of lime-containing foods, as the cereals, and mineral waters as beverages, cannot but be of values as antacids furnishing a neutralizing agent for the acid, while the lime probably enters into the development of bone (Hare), and, therefore, would be useful in supplying, *via* the placenta, mother's milk, and later the child's food, the element needed for the development of teeth. The use of glycerophosphate of lime and soda has been suggested.

The teeth should receive all needful care during pregnancy, that the mother should not suffer pain, but work should be of a temporary nature, if necessary, to avoid shock, especially at about the third month of gestation. Attention has been called to the fact that during menstruation a systemic hyperacidity exists, which can be combated by the use of lime internally and milk of magnesia or lime water locally.

In the care of the teeth during pregnancy the effect of the hydrochloric acid vomitus upon the teeth should be considered, an alkaline wash such as lime water or bicarbonate of soda solution to be used after the vomiting. The same would be true of seasickness and after the use of any acid drug or foodstuff, such as tincture of ferric chloride or buttermilk in case the latter is a constant diet. (See p. 354).

SECTION IV.

DISEASES OF THE DENTAL PULP.

CHAPTER XV.

CONSTRUCTIVE DISEASES.

Diseases of the dental pulp are both acute and chronic. According to the anatomical features, they may also be divided into constructive and destructive. The acute diseases are usually destructive; in the chronic, structural and constructive changes are commonly noted. Constructive diseases of the dental pulp are those attended by the formation of deposits of new masses of calcific substance. Destructive diseases are those which cause retrogressive and necrotic changes in the tissues of the pulp. The essential difference between the two classes of disease is in the mode and character of the degeneration—the one is acute, the other chronic.

Pathologically there is no abrupt line of demarcation between diseases of the dentin and those of the pulp, as the dentinal tubules contain the fibrillar prolongations of the odontoblasts of the pulp. Effects produced upon the fibrils cause, therefore, a pulp reaction which may lead either to a constructive or destructive activity according to the grade of hyperemia or inflammation set up.

As infection may travel via the tubules, even septic inflammation may result before the pulp is exposed.

Moreover, after constructive changes which are accompanied by more or less atrophy and degeneration, the pulp may undergo the more acute destructive changes. While the exact relations between symptoms and pathology are not all worked out and the symptoms are often obscure, due to the fact that the pulp is without the sense of touch or exact location, and, therefore, the pains induced are reflected, as a rule, yet clinical observation and the *x*-rays have done much to relate the symptoms and pathology, and one must depend upon these and applied tests for at least a tentative diagnosis, of which confirmation may be sought.

The pathological conditions of the pulp are judged by the phenomena induced by applications of air or water of varying temperatures, and by the presence of certain appearances of the tooth, which, taken with the symptoms and tests, lead to a fair inference of the disease present.

It was pointed out by Black[1] that if a healthy tooth be isolated by a double layer of rubber dam, and a jet of water at a temperature of 40° F. be directed against the tooth, a paroxysm of pain is produced. A jet of hot water will also induce a similar pain, and if the patient's eyes be shielded no difference in the sensations is noted; that is, the pulp responds to thermal stimuli, hot or cold, indifferently. The organ is accustomed to variations of temperature between 60° and 105° to 110° F., and within this range, in a condition of health, takes no apparent cognizance of this degree of change.

With a decrease in the amount of dentin covering the pulp—*e. g.*, with the advance of caries—the reaction to thermal stimuli increases in promptness until, when the pulp is nearly exposed, the response is immediate. As the pulp irritation increases there is prompt response to lesser degrees of temperature change, until finally the pulp responds immediately to water at a temperature but a few degrees below or over the bodily temperature, 98.6° another feature makes its appearance; instead of a sharp contraction pain, applications of moderate thermal stimuli are followed by a heavy, throbbing pain. Later, similar pains occur in the absence of tangible external sources of irritation. In conditions of abscess intense pain is later caused by hot applications, and cold applications afford relief.

In pulp degeneration the response to thermal stimuli may pursue the opposite course. The normally prompt response is followed by delays in reaction, until it is only after the continued application of cold to the exterior of a tooth that a paroxysm of pain is induced. In these cases there follows after a relatively long time an increasing response to heat, as in the former instance, the reaction occurring only upon decided or prolonged heat stimuli. Following upon the period of increased response to heat, in both cases there comes a period of quiescence, in which there is no response whatever to applications of intense cold, even that produced by the evaporation of a spray of ethyl or methyl chlorid—*i. e.*, the sensory function of the pulp is paralyzed. This only in intense venous hyperemia or degeneration.

These are the available subjective evidences of the pathological conditions of the pulp; while they indicate with a degree of accuracy,

[1] American System of Dentistry, vol. i.

useful in clinical work, the alterations in the pulp, the exact relations between the reactions and the morbid anatomy of the organ are not entirely clear. It is assumed that, in consequence of the loss of the normal protective covering of the pulp, its sensory and perhaps vasomotor nerve fibres become stimulated, overstimulated, irritated, and then paralyzed by thermal stimuli in the progress of caries. The bloodvessels, which retained their tone up to a certain point, suffer vasomotor irritation; next, paralysis leading to their dilatation and to the throbbing pain. Later, even change of posture is sufficient to cause distention of the paralyzed vessels, hence pain in resuming the reclining position. Stimulation by cold, until the later stages, causes a sharp, continuous pain, ascribed to the paroxysmal contraction of the vessels. In the stages of paralysis heat causes further distention of the vessels, and, if gases be present, causes their expansion with pressure upon nerve filaments.

The decreasing and delayed response to thermal stimuli must be referred to three sources: (1) An increase in the non-conducting covering of the pulp—*i. e.*, a lessening of the amount of the fluid contents of the dentinal tubuli and a thickening of the dentinal walls, which necessarily implies a recession of the pulp from its normal position; (2) to degeneration of the sensory nerve fibers themselves; and (3) changes in the walls of or about the bloodvessels, which check vasomotor response and changes in the caliber of the vessels. These three classes of reactions still further emphasize the division of the pulp diseases into two types, the acute and chronic; the first class of reaction is associated with the acute destructive diseases; the second, with the chronic constructive but degenerative conditions.

CONSTRUCTIVE DISEASES OF THE DENTAL PULP.

The constructive diseases of the dental pulp include all the secondary dentin formations, tubular calcification, the formation of pulp nodules and calcareous degeneration of the pulp.

Tubular Calcification.—**Definition.**—By tubular calcification, or, to express the condition more accurately, tubular dentinification, is meant the change that occurs in the dentin which leads to an obliteration of the dentinal tubuli by deposition of dentinal material along the inside of the walls of the tubules, with a corresponding atrophy of the fibrils. It is a sclerosis of dentin analogous to osteosclerosis.

Causes and Occurrence.—The apparent cause is a mild degree of irritation, not passing the stage inducing constructive metamorphosis, and apparently caused by direct irritation of the fibrils, more particularly through the action of thermal shock, brushing, mastication,

or action of acids. It occurs in the course of mechanical abrasion and erosion of the teeth, under metallic fillings, and probably a modification of the process precedes the slow invasion of dental caries. It begins at once the enamel is removed from the dentin at any point, and the dentin subjected to irritation, showing it to be due to a stimulation of the whole odontoblastic cell (including its fibrillar prolongation). It occurs in some degree as a normal vital change due to age, and is common in persons who are victims of the gouty or rheumatic diathesis. It also occurs in pyorrhetic teeth as a result of pulp stimulation (Figs. 304, 353, *c*, and 397).

Pathology.—The fibril is lessened in diameter as the lumen of the tubule becomes smaller. There is sometimes an increased, but more often a lessened, sensitivity of the dentin.

Other phases of the condition are discussed under transparency of the dentin, to which the disease corresponds. (See p. 380.)

The altered dentin becomes translucent, acquiring a horn-like appearance, and, usually, secondary dentin formation begins coincidently with it. Andrews claims that granules of calcific matter are pushed into the fibrillæ by the odontoblasts and deposited along the inner wall of the tubule, even to obliteration of them. These granules give the color to abraded dentin in the region of the pulp cavity.

Tubular calcification is, for the most part, to be regarded in the light of an effect due to a physiological process. It may be regarded as a physiological barrier erected against the progress of caries, erosion, or abrasion, threatening the invasion of the pulp. While it delays the disintegration of the tissue, it does not prevent it. In the cases due to age or the irritants produced by goutiness, it is probably a local expression of a general sclerotic change, the intercellular substance (tubule wall) being formed at the expense of the cellular (fibrilla). In senility the change in the dentin may cause the teeth to be almost transparent. It requires no treatment.

Secondary Dentin.—Definition.—By secondary dentin is meant a deposit of dentin upon the wall of the pulp chamber, as the result of pulp stimulation after the pulp has enjoyed a physiological period of rest from dentin formation. It is always attached to the dentin.

Causes.—The cause of formation of secondary dentin is a stimulation of the pulp to increased functional activity. This stimulus may be provided by any constant irritation of the dentinal fibrils. as, for example, when exposed at necks of teeth, upon abraded or eroded surfaces, or within cavities of decay. The presence of metallic fillings, conductive of thermal changes, may provide the necessary stimulus. Gold crowns upon ground-down crowns of vital teeth have a similar effect. The slightly irritative effects of oxychlorid of zinc

often produce much secondary dentin. It is associated with tubular calcification. A pulp capping may provide the stimulus and new dentin fill the orifice of exposure. Absolute exposure without treatment has been recorded as productive of secondary dentin. In two cases described by Charles Tomes, pulps widely exposed by fracture of crowns during extraction covered themselves completely in. The histological record, as seen in the photomicrograph, demonstrated that a plastic exudate was first exuded, which later calcified as an amorphous mass.

Next an irregular lamina was formed, and lastly, dentin containing tubules. It is to be inferred that both the pulp and its odontoblasts may take part in the process (Fig. 390).

I have seen one case in which a wide exposure had been covered in sufficiently to enable me to gently indent the covering, which was

Fig. 390

Secondary dentin formed after exposure of pulp by fracture during extraction. (Tomes.)

Fig. 391

Bicuspid in which a formation of secondary dentin has failed to obviate perforation of the pulp cavity by resorption. (Tomes.)

Fig. 392

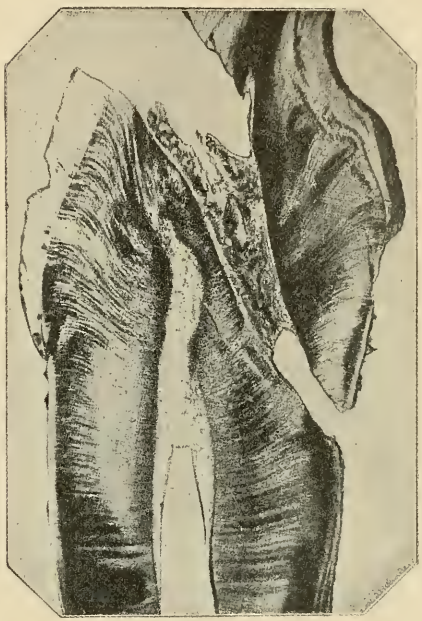

Harding's case of united fracture. The uniting material is of coarse osseous structure with numerous lacunal spaces. (Tomes.)

Fig. 393

Elastic layer of calcific material formed over an exposed pulp. (From a case.)

convex, with a ball burnisher. Upon removal of the instrument it resumed its original shape, owing to its elasticity. The periphery of the original exposure was clearly defined (Fig. 393). In another case of known exposure with bleeding the patient kept eugenol on cotton in the cavity. After several weeks the exposure could not be again discovered. Age seems to be a cause of general secondary dentin formation, but no doubt certain forms of irritation are introduced

Fig. 394

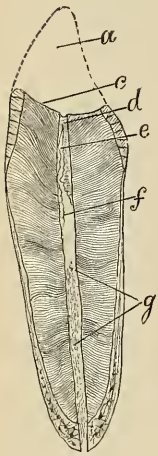

Fig. 395

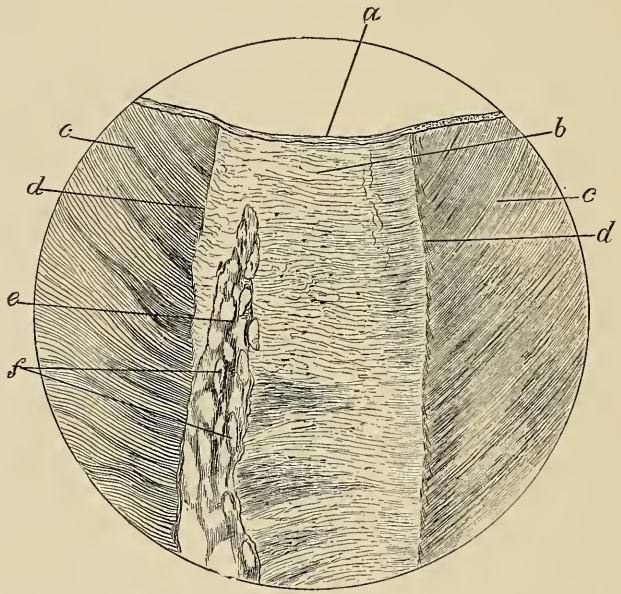

Fig. 394.—Secondary dentin filling the pulp chamber is a case of abrasion of a cuspid tooth: *a*, portion lost by abrasion; *c*, abraded surface; *d*, secondary dentin, filling a portion of the pulp chamber, and acting as a protection to the pulp; *e*, slender point of the pulp—irregular deposits are seen on the walls of the pulp chamber, as at *f*; *g*, cylindrical calcifications in the root portion of the pulp chamber.

Fig. 395.—Secondary dentin from the same specimen as Fig. 394, magnified sufficiently to show the difference in primary and secondary tissue: *a*, abraded surface crown; *b*, secondary dentin; *c*, primary dentin; *d*, junction of primary with secondary dentin; *e*, remains of pulp tissue; *f*, small oval masses of calcific material. (Black.)

competent to produce the changes; for example, slight looseness of teeth, causing a constant pulp stimulation. At times reflex irritation seems to be a competent cause, as in cases of partial abrasion the unworn teeth may be affected in equal degree with the worn ones.

It is also true that any form of chronic irritation of the pericementum of a tooth may produce arterial hyperemia of a pulp which will lead to the formation of secondary dentin or pulp nodule or both.

Non-occlusion, mal-occlusion, pyorrhea alveolaris are typical examples of the non-septic and septic classes of irritation. (See p. 469).

Pathology and Morbid Anatomy.—The formation is usually noted opposite to some area of injury, and may be distinguished from normal dentin by its translucency, or sometimes by its color, which may be a light brown. The deposit may be of fairly regular or irregular distribution, and even tumors attached to the dentin have been described (Fig. 396).

FIG. 396

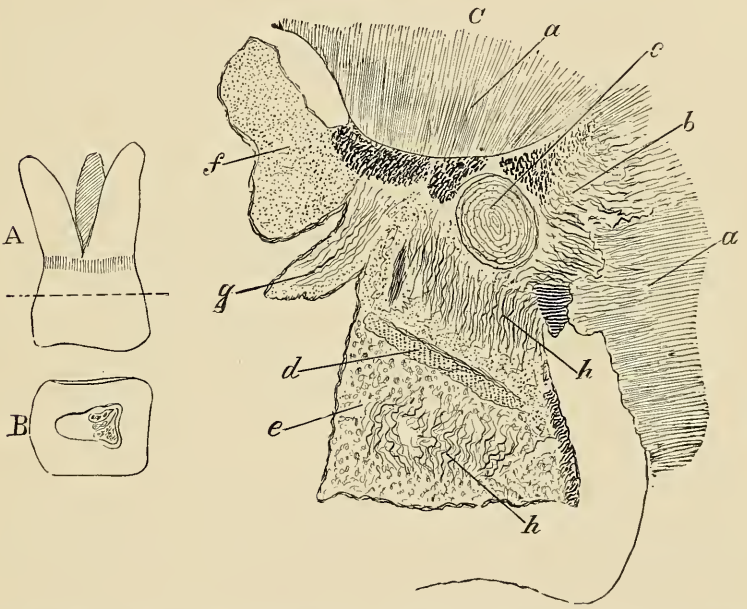

Dentinal tumor within pulp chamber: *A*, diagram of the tooth, with dotted line showing the position of the section *B*. In *B* the pulp chamber is shown in section, nearly natural size, showing the tumor within. *C* is an illustration of the tissue of the tumor; *a*, *a*, the primary dentin; *b*, irregular tubules connecting the newgrowth with the primary dentin—most of these are very dark and irregular; *c*, *c*, a calcospherite included in the mass; *d*, apparently a bloodvessel calcified; *e*, calcified tissue; *f*, a finely granular mass; *g*, a spur of very transparent dentin. Dentinal tubules appear at *h*, *h*. (Black.)

Black has shown that in the deposits against normal dentin the first-formed portion contains an almost normal number of tubules, but their direction is sharply changed. As the deposits become thicker the tubules become fewer, and finally the dentin becomes amorphous in character (Fig. 399.)

Black relates these appearances with the gradual atrophy and disappearance of the odontoblasts. As the pulp becomes smaller it also necessarily undergoes atrophy.

Hopewell-Smith,[1] treating of secondary dentin under the title of "Adventitious Dentin," mentions several varieties: (1) Fibrillar, or that containing tube-like markings finer and less regular than in normal dentin. This would correspond to that in Fig. 396, *h*. (2) Areolar, that containing interglobular spaces formed by the non-union of calcospherites. (3) Cellular, in which the cells of the pulp remain encapsulated in the calcifying matrix. (Fig. 400.) (4) Laminar, in which laminated spherites appear (Fig. 396, *c*). (5) Hyalin, having a granular or ground-glass-like appearance (the amorphous substance of Black) (Fig. 396, *f*). He regards the adventitious dentin as formed by pulp cells rather than by the odontoblasts. In these cases the pulp deposits calcoglobulin against the dentin.

Fig. 397

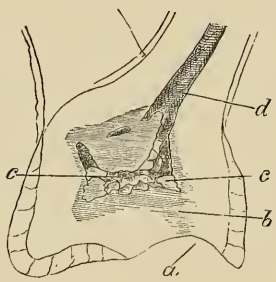

Fig. 398

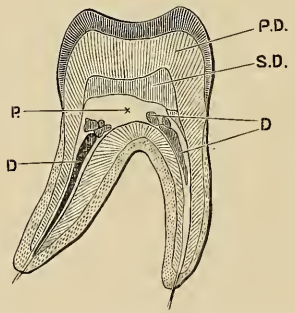

Fig. 397.—Illustration of the narrowing of the pulp chamber in a molar (superior) by the deposit of secondary dentin resulting from abrasion, showing the portions of the chamber in which the deposit usually occurs. The light-shaded portion (*b*) shows the original dimensions of the chamber, which, in this instance, seems to have been pretty large; *a*, a point of deep abrasion; *c*, *c*, remaining pulp chamber, which is mostly filled with irregular masses; *d*, one of the root canals. It will be observed that the narrowing of the root canal is within the original pulp chamber. (Black.)

Fig. 398.—*P.D.*, primary dentin; *S.D.*, secondary dentin; *P*, pulp chamber; *D*, *D*, nodules.

Apparently in some of Black's cases the calcoglobulin was deposited about preëxisting fibrillæ which continued to persist in the new formation, the remaining odontoblasts receding, while in Tomes' cases the pulps were compelled to calcify a plastic exudate as a sort of basis for the beginning of tubule formation. This is probably the case in formation of secondary dentin as a repair of exposure under a cap. Black has shown that in abrasion the deposit is more regular than in caries, without doubt due to the fact that the thermal irritation in caries is more irregular than the irritation of the fibrillæ by

[1] Histology and Patho-Histology of the Teeth.

abrasion. A deposit projecting from any point about the pulp cavity side into the pulp is called a "dentinal tumor" (Fig. 396).

The entire crown may be removed by abrasion and yet the pulp be protected. In some cases the protective action ceases and the pulp becomes closely approached or exposed (Fig. 280), probably due to a cessation of secondary dentin formation, the result of degeneration and loss of odontoblasts, or it may be due to very rapid wear (a later stage of Fig. 395).

The mode of deposition upon the sides of the canal in abrasion, shown by Fig. 394, is quite characteristic, and sometimes annoying in that it permits an unlooked-for exposure, which, upon cocain anesthesia, causes one to follow a fine opening for an eighth of an inch or more before finding a proper canal.

Deposits in canals may occur, lessening their lumen and increasing the difficulty of canal exploration (Fig. 398).

"Secondary growths in cases of abrasion are not confined alone to the abraded teeth, but other teeth which have escaped wear may be affected in equal degree. In all of these cases there is direct evidence that the odontoblastic layer has been stimulated to increased activity and produced the regular secondary deposition."[1] (See Reflex Hyperemia of the Pulp, p. 470).

Secondary dentin is often accompanied by other constructive changes in the pulp—*i. e.*, pulp nodules and calcareous degeneration (Figs. 398 and 404).

Miller has shown that dentin resorption by the pulp may be repaired by a new deposit of secondary dentin, which Hopewell-Smith has shown to be of the nature of cementum. (Fig. 422.)

Tomes[2] describes and illustrates a peculiar case of united fracture occurring in the practice of Mr. Harding. In an incisor an oblique fracture occurred which entirely separated the fractured segment, yet a plastic exudate occurred which, when calcified, attached it to the fixed portion of the tooth. The new formation did not resemble dentin (Fig. 392).

Fig. 309 illustrates a case of repair of an incisor fractured at a point well up beneath the gum, a condition reasonably insuring asepsis. A firm reattachment occurred. I have seen such a fracture which resulted in pulp death and the coronal portion remained *in situ* for two years (according to the patient). This would give time for such a plastic exudate to form. In another case I was compelled to remove a pulp for hyperemia two months after a fall fractured a tooth in this location (see p. 324).

[1] Black: American System of Dentistry, vol. i.

[2] Dental Surgery.

Kirk[1] records a case of immediate replantation in early life, followed in old age by root resorption. The tooth, when extracted, contained secondary dentin, which could only have formed as the result of a reattachment of the pulp.

W. H. Trueman[2] reported that hypersensitive dentin was noted some years after a replantation under similar conditions.

Fig. 399

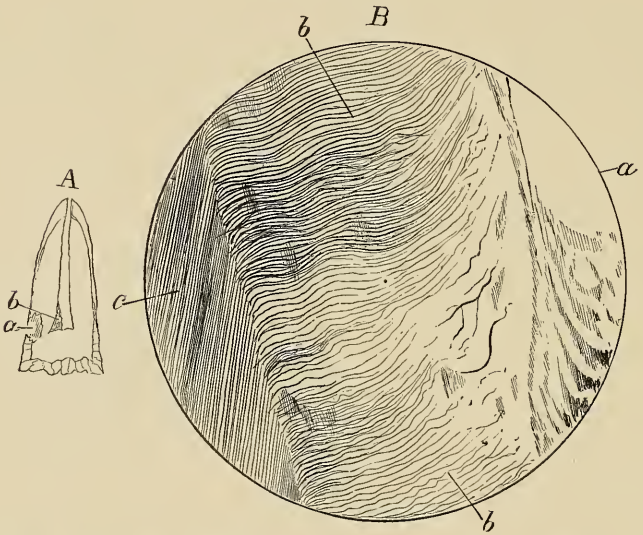

Calcification or deposit of secondary dentin, resulting from caries of an incisor: *A*, diagram of section of incisor, showing caries at *a*, and secondary dentin at *b*. *B*, illustration magnified 200 diameters, to show the tissue of the secondary dentin: *a*, pulp chamber; *b*, *b*, secondary dentin; *c*, primary dentin. It will be noticed that the dentinal tubes in the secondary dentin gradually disappear, giving place to a clear calcification. (Black.)

Osteodentin.—Tomes states that secondary dentinal deposits may assume the character of osteodentin, a form of dentin found in the teeth of some animals, in which the tissue presents combined characteristics of both bone and dentin. He cites the example also that elephants' tusks are frequently repaired with osteodentin after injury. The specimen illustrated (Fig. 400) was taken from a case in which the coronal portion of the pulp chamber was almost obliterated by a deposit of secondary dentin. Probably some of the pulp cells have taken on the characteristics of osteoblasts. Tissue resembling cementum seems to be frequently found as a tissue of repair (Fig. 400).

[1] Proceedings of the Academy of Stomatology, 1902. [2] Ibid.

Results of Secondary Dentin.—The formation of large masses of secondary dentin unquestionably brings about a degenerative condition of the pulp which may become a cause of neuralgia. The pulp may die, and, becoming infected, may produce pericemental irritation. In one case seen the secondary deposit in the pulp chamber had separated the canal filaments of the pulp of a multirooted tooth into independent pulps, one of which was dead and the others alive and undergoing degeneration. The specific symptoms were those of pericementitis—*i. e.*, elongation and tenderness to percussion.

In another case of a first upper bicuspid the lingual filament was perfectly covered in and vital. The buccal filament, likewise enclosed and isolated, contained an abscess within the pulp.

The symptoms complained of, however, were those of acute pericemental irritation, simulating incipient septic apical pericementitis (Fig. 432).

FIG. 400

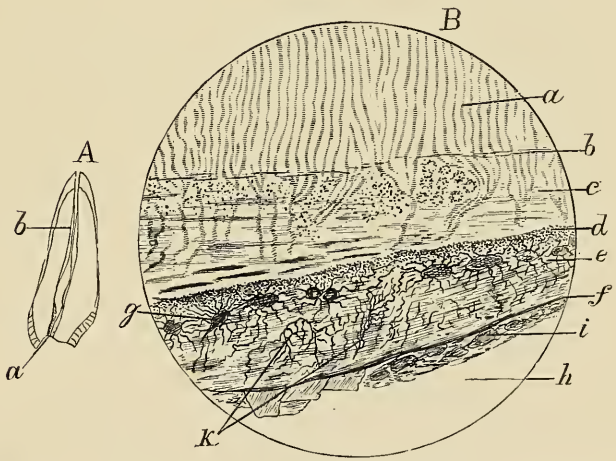

Osteodentin: *A*, outline of incisor, showing a narrowing of the root canal at *b* by a deposit of osteodentin. *B*, illustration of the tissue: *a*, primary dentin; *b*, line of the beginning of a growth of secondary dentin; *c*, secondary dentin; *d*, layer of granular matter; *e*, osteodentin; this has the lacunæ at *g* and dentinal tubes at *k*; *f* seems to be the surface of the osseous deposit; *i*, irregular crystalline deposits; *h*, the pulp chamber. × 350. (Black.). (Tomes.)

It has been shown by Hopewell-Smith that microörganisms may enter the pulp by way of the spaces or tubes in adventitious dentin. In Burchard's case a molar containing a deep cavity filled with zinc phosphate gave vague pain, finally referred to the tooth, which responded only faintly to hot applications and not at all to cold ones. Secondary dentin was found complicated by calcareous degeneration —*i. e.*, a degenerated pulp was present.

In certain cases a deposit extends well into a canal, totally obliterating it for much of its length. Unless symptoms be present it may ordinarily be left. In such cases thermal tests for pulp vitality seem often inconclusive. The electric current should be a more satisfactory means of diagnosis, provided the dentin be moist. Secondary dentin is sometimes quite hypersensitive, as shown by attempts at entering the pulp; in most cases it is quite insensitive until the pulp is reached. It is also difficult, as a rule, to force cocain through secondary dentin, even with a compound syringe, and arsenic acts slowly, though it devitalizes if the dentin be sensitive. (See Dry Gangrene, p. 562, also p. 424.)

Treatment.—Secondary dentin which has been regularly deposited, and particularly in the canals of anterior teeth, calls for no treatment. Should, however, great hypersensitivity of the dentin and pulp, or pulp disease, be evident or inferred from symptoms, the pulp should be removed. Canal opening may involve a search of some difficulty and necessitate the removal of much dentin. The canals may be much constricted, especially at that portion nearest the pulp chamber. The condition may be more or less complicated by the presence of pulp nodules or calcific degenerations in addition to the secondary dentin.

Pulp Nodules.—Definition.—Pulp nodules (pulp stones, nodular calcifications) are masses of more or less translucent, calcific material, apparently the result of secretion, having a fairly definite histological structure differing from that of dentin, and occupying a position within the pulp substance. They are rarely fused with the dentinal walls of the pulp chamber, and then are included by formation of secondary dentin about them.

Occurrence.—While these growths may occupy the pulp chambers of teeth in which the pulp has been the seat of direct irritation, their occurrence is by no means confined to such teeth. They are found not only in teeth which have suffered abrasion, erosin, and slowly progressing caries, but, as pointed out by Black, they may, and frequently do, form in other teeth of the same denture which are not directly involved in the irritation. This investigator notes that irritation of the pulp of one tooth of a denture very frequently causes a general hyperesthesia (due to mild reflex hyperemia) of the pulps of all of the teeth. Pyorrhea producing tooth movement or apical pericemental irritation can produce arterial hyperemia of the pulp and thereby pulp nodules. This is due to the constructive effect of mild hyperemia.

Nodules and secondary dentin or pulp hyperemia may occur in sound teeth ground for crowns. This simply indicates a necessity

for antisepsis in the cement, or a non-conductor as varnish, or chloropercha over the teeth before cementation. The conditions are not unlike those in a cavity of simple depth and to the mind of the writer do not necessitate devitalization before crowning, as many live for years. Nodules are found much more frequently in the teeth

FIG. 401

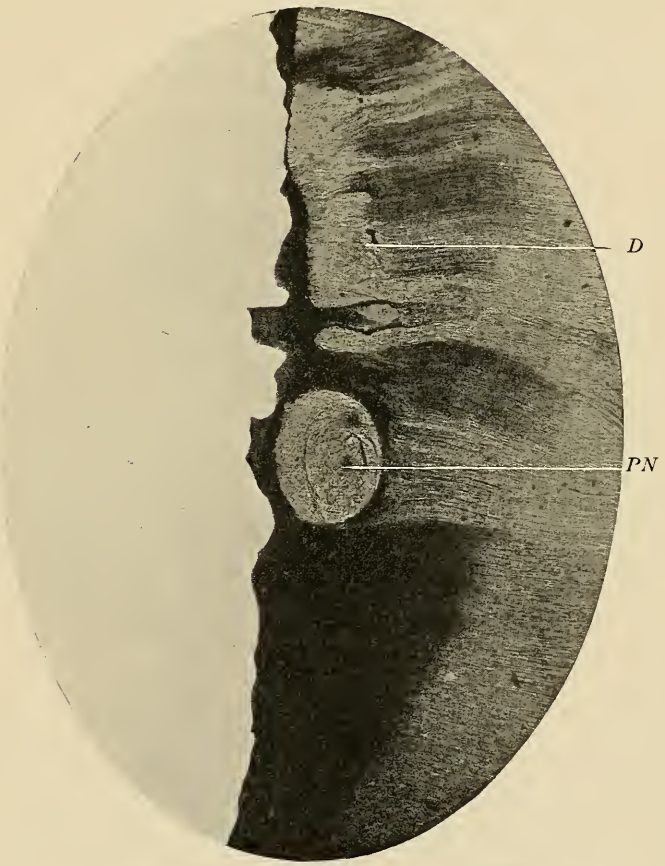

A pulp nodule fused to the parietes of a pulp cavity. Prepared by grinding: *PN*, pulp nodule; *D*, dentin of the tooth. × 15. From section by J. F. Colyer. (Hopewell-Smith.)

of middle-aged persons than in those of youth, although they may be present as early as the ninth year, as shown by skiagraphy. They occur more frequently multiple than single. Some of the larger nodules are evidently formed by the coalescence of smaller ones.

Pathology and Morbid Anatomy.—The structure of pulp nodules does not resemble that of dentin; they possess about the same degree

of translucency and hardness as secondary dentin. Outwardly they may assume almost any form; they range in size from minute bodies to a size sufficient to almost obliterate the pulp (Figs. 398 and 404).

Fig. 402

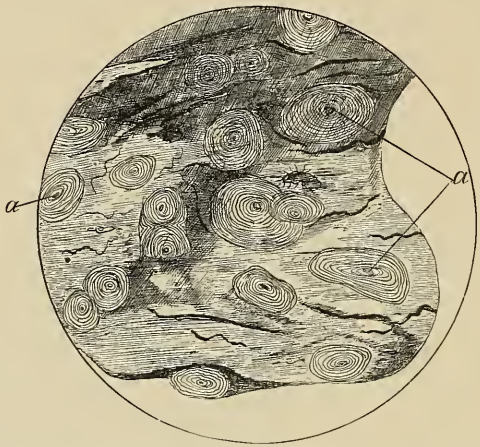

Section of a pulp nodule, showing many calcospherites, as pointed out by *a*, *a*. (Black.)

A section of a nodule exhibits the presence of a number of concentrically laminated bodies, recognizable as hardened calcospherites. Black found them to rarely make up any considerable portion of the bulk of the nodule. The remainder of the nodule is made up of structureless material which may contain a few fine tubes.

Fig. 403

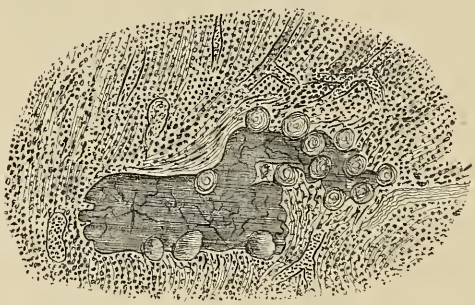

Deposit of calcoglobulin within the tisues of an inflamed pulp. (Black.)

He also found deposits in the pulp which throw light upon the possible origin of nodules in some cases, and to some extent upon the conditions under which they may be formed. In the pulp of a second molar of a girl, aged fifteen years, in which there had been

decided subjective evidences of pulpitis recurring at intervals for a period of two months, he found a mass representing a pulp nodule in its soft state. "About one-half of the coronal portion of the pulp was involved in the inflammation; lying a little inside of the layer of odontoblasts were several masses similar to Fig. 403, having globular forms in their mass or attached to their margins. The globular bodies present the laminated appearance of calcospherites." These masses may in all probability be interpreted as intermediate products in the formation of nodules; they have not yet become calcified.

FIG. 404

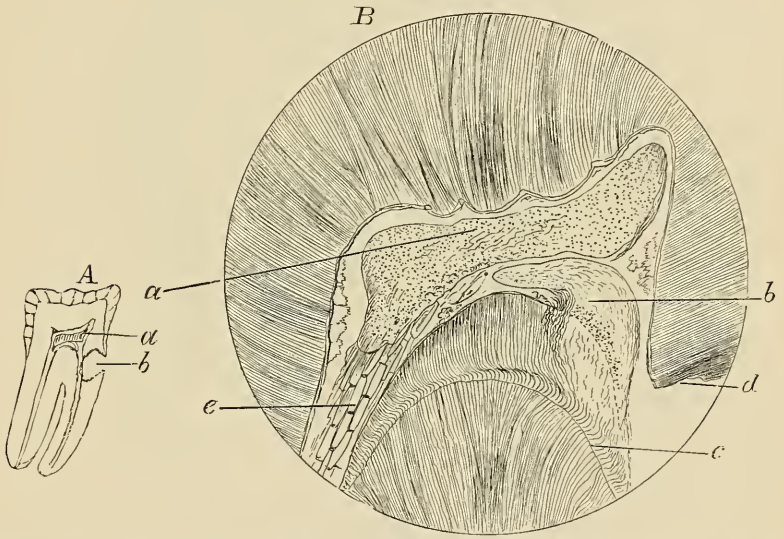

Calcification of the dental pulp: At *A* is shown the outline of a lower molar with a cavity at *b*. The pulp chamber is much reduced in size and filled with calcific material, as shown in *B*. *a*, *a*, large granular mass of calcific material, which is very transparent, but finely granular. A very few irregular lines are seen in the centre, which slightly resemble dentinal tubes; *b*, an erratic growth of irregularly formed and unusually transparent dentin; *c*, line of the growth of dentin from the floor of the pulp chamber—the growth from other directions is so perfectly regular as to leave no markings; *d*, margin of the cavity of decay; *e*, a bundle of cylindrical forms of calcific material extending down into the root canal. These extended to the apex of the root. (Black.)

A small nodule may be made up of laminated, structureless material, the laminæ being arranged about a central nucleus, the nature of which is not clear, but may possibly be calcified dead cells (Fig. 405).

The conditions of calcification of nodules are not definitely known. Hopewell-Smith considers that they are deposited by the pulp cells as a secretion about themselves, and that the cells are later obliterated or may persist *in situ* (Fig. 406). He also describes and illustrates

a case of a nodule which had within it a pulp cavity containing pulp tissue.

Pulp nodules occur, as a rule, in the better grades of teeth which show constructive tendencies upon the part of the pulp.

FIG. 405

A pulp nodule isolated from the pulp. Shows its central nuclear formation and its concentric lamination. Prepared by grinding. × 50. From collection of G. W. Watson. (Hopewell-Smith.)

It is possible that in these pulps the pulp cells under conditions of irritation secrete calcoglobulin, which in part is developed into spherites and in part remains without definite histological characteristics. The masses are probably calcified after their deposition. Whatever the origin of the masses—by cell secretion or otherwise—the histological record indicates a gradual increase in the size of the deposit. Pressure upon the nerves results in irritation and an increase in pulp hyperemia which causes the reaction to thermal changes. Pulp nodules are usually found in the coronal portion of the pulp, but sometimes exist in the root portions, either free or embedded in secondary dentin. If they obstruct the lumen of the canal they cause interference with the circulation and nerve tissue and may produce great pain. Bunting calls attention to the possibility that the nodule moving freely in the pulp may allow arterial pressure to raise it, permitting blood entrance, while the venous pressure may return it to place and prevent exit of blood thus inducing continued

internal pressure in the pulp (a venous hyperemia), thus causing functional disturbance and pain.[1] As in the case of secondary dentin, nodules may be produced by reflex hyperemia, as they are quite frequently found in teeth near to an impacted tooth.

Symptoms.—Multiple nodules may exist in a dental pulp and give rise to no evident symptoms whatever, as is shown by their presence in extracted teeth, many of them free from caries, and in which there was no history of pain. On the contrary, the pulp of a tooth may react persistently to thermal changes or even be the seat of intractable pain without a depth of carious invasion which would lead to the inference of acute pulp disease; and relief only be secured through devitalization of the pulp, which upon examination may reveal a small or large pulp nodule.

FIG. 406

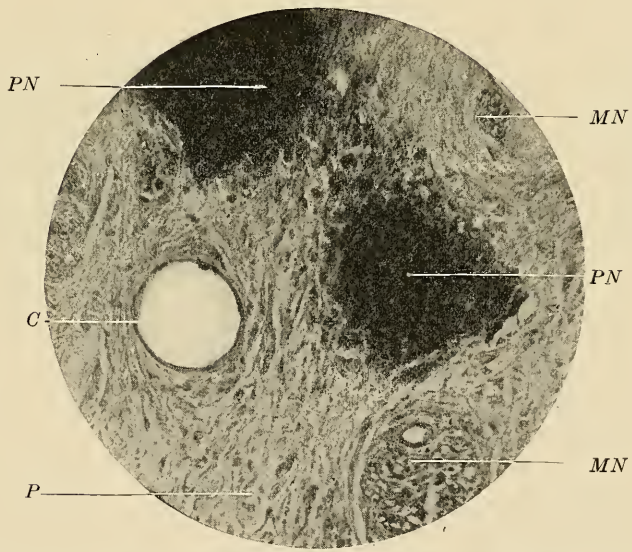

The formation of the pulp nodule. Prepared by Mr. Hopewell-Smith's process. *PN*, pulp nodules; *MN*, medullated nerve bundles; *T*, pulp tissue; *C*, capillary. × 230. (Hopewell-Smith.)

The symptoms attendant upon the presence of nodules, so far as they can be made out, appear to be of two types—those associated with small and those with extensive deposits. Reflex pain is the common associate of both.

SMALL DEPOSITS.—While it is true that pulp nodules may sometimes exist in apparently sound teeth without inducing pain, yet the

[1] Dental Cosmos, February, 1912, p. 169.

pulps of teeth containing them become excessively hyperesthetic under what are ordinarily mild sources of irritation. This is manifested, first, through the contents of the dentinal tubuli; the dentin becomes exquisitely sensitive and cool water directed into a shallow cavity produces a paroxysmal and excruciatingly painful response from the pulp. In the absence of direct, extraneous irritation of the pulp, the dental symptoms may be absent, but a persistent neuralgia may be located at some distant point. Pain *in* the ear is a frequent symptom. Occasionally an obstinate scalp neuralgia, with the existence of a hyperesthetic spot, appears. Pain in the eye, with tenderness over the supra-orbital foramen, is also common. Guilford[1] has reported a case of *tic douloureux* of two years' standing, the result of pulp nodules. The pain may be recurrent or persistent. If, in the absence of a more probable explanation of the pain, the pulp nodule be

FIG. 407



Pulp nodules in the radicular and coronal portions of the canal. (Skiagraphs by Price.[2])

FIG. 408

FIG. 409



First and second bicuspid roots filled. Pulp nodule in first molar. (Skiagraph by Lodge.)

suspected, and arsenical applications be made to devitalize the pulp, it is found that not only is intense pain caused, but examination after even a week or more shows the pulp to be still vital and hypersensitive; and, in order to effect its destruction, repeated applications and large doses of arsenic must be used. Cocain introduced by cataphoresis is also apt to be slow in action.

LARGE DEPOSITS.—In extensive deposits of pulp nodules the dentin may be almost devoid of sensation, and applications of heat or cold, even in large cavities, may be followed by delayed and faint pulp response. Such cases, however, commonly give a history of reflex neuralgia and vague dental pains extending over a period, it may be, of years. With some large deposit the pain may be exquisite.

Diagnosis.—Their diagnosis by means of the *x*-rays is positive (Figs. 407, 408, and 409), but their diagnosis by symptoms may only

[1] Private Communication.

[2] Items of Interest, 1901.

be inferential and confirmation be lacking until after devitalization of the pulp and the finding of the pulp nodules in its substance.

The tardy action of arsenic is also observed in the cases of large deposit, it being frequently necessary to devitalize the pulp piecemeal, and sometimes the arsenic will hardly be tolerated at all.

Treatment.—Pulps inferred or shown by *x*-rays to contain nodules should be removed. The cataphoric apparatus or compound syringe or even ordinary cocain pressure may be used to benumb the pulp by cocain; at least, sufficiently for the removal of the nodule. If desired, the remainder of the pulp may generally but not always be anesthetized by the same means and removed. The bloodletting attendant upon removal of the bulb of the pulp usually permits an arsenical application for devitalization of the remainder of the pulp to be painlessly made, but this is not always the case.

The same result may be attained by drilling open the pulp cavity while the patient is under the influence of nitrous oxid gas or somnoform, or, possibly, intra-alveolar injection of cocain.

At times arsenic may be applied to the pulpal wall of the cavity, if one exist, or in a specially prepared pocket, without production of painful reaction.

After forty-eight hours a portion of dentin is to be removed and a stronger application made. When the pulp is closely approached, the arsenic is to be left a week or longer in position, when, as a rule, the nodule may be removed. Another application may then be left in position for a week or longer to insure devitalization.

If, after devitalization, the nodule or calcific degeneration be found as a spicular deposit in the mouth of the canal, it may usually be removed by teasing it from side to side, first soaking the part with a sodium dioxid solution, or 50 per cent. sulphuric acid, which quickly destroys the organic matter of the pulp.

Pericemental reactions are quite apt to follow the removal of such pulps. This result is best obviated by awaiting the thorough death of the pulp filaments before attempting their removal.

If such reaction arise, strong sedatives, such as menthol solutions, are to be applied on cotton as root-canal dressings, and counter-irritants are to be applied to the gum. (See Non-septic Apical Pericementitis.)

Calcific Degeneration of the Pulp.—By calcific degeneration is meant the infiltration of inorganic matter derived from the lymph into tissue which is dead or undergoing degeneration. It occurs in any part of the body in which the necessary conditions are present. (See p. 87.)

Cause and Pathology.—The conditions apparently necessary for the production of calcific degeneration are those which occur in a

semistagnant blood current. An acid reaction occurs owing to the presence of an excess of carbon dioxid, which favors deposition of inorganic matter. The albuminous matter of the tissue undergoes degenerative changes owing to the faulty nutritive supply and waste removal.

Probably some cells die. They or their constituents have some affinity for inorganic salts which are taken up from the lymph. Thus gradually the tissue becomes infiltrated.

Those causes which produce a sufficient degeneration of pulp tissue to induce the above process are: (1) The pulp exhaustion due to the formation of secondary dentin or pulp nodules; (2) continued hyperemia or chronic inflammation in which venous hyperemia plays a part.

FIG. 410

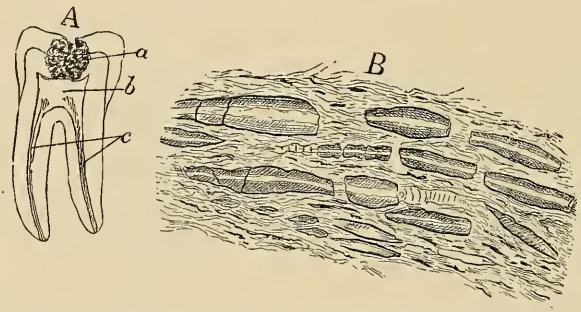

A, outline of a lower molar, with a large carious cavity at *a; b*, pulp chamber; the shaded portion, *c*, was occupied by cylindrical calcifications. *B*, cylindrical calcifications. × 100. (Black.)

Pathology and Morbid Anatomy.—The calcific material, unlike the cases of nodular calcification, encloses the anatomical elements of a pulp in process of degeneration in a mass produced by deposition, not secretion. In the root portions of pulps in which fibrous elements have become pronounced the calcification may be tubular or cylindrical in character, the nature of the calcareous masses being apparently a deposition about and along the fibers (Fig. 410).

The pulps are, of course, living. There is a comparative absence of cellular elements in the pulp—*i. e.*, they have atrophied, degenerated, and been absorbed. Upon optical examination the masses are seen to be opaque, are brittle, and decidedly unlike pulp nodules in form.

Another evidence of the cellular degeneration is seen in the great ease with which such pulps are removed after devitalization, even the most minute apical portions freely coming away after slightly catching a hook in the pulp—*i. e.*, the usual odontoblastic

attachment to the dentin is not present. When extracted these pulps have a granular feel to the fingers, and when dry may be quite stiff (Fig. 411).

Symptoms.—Degenerations of the pulp, as a rule, present symptoms of reflex pain, vaguely referred to other parts. The response to hot applications is usually greater than that to cold ones, and both are delayed—*i. e.*, five seconds or more may elapse before pain follows a severe test like the intensely cold spray of ethyl chlorid or a hot burnisher or blast of hot air. At times with an open pulp chamber the symptoms of chronic pulp inflammation are obtained. There may be a painful reaction to arsenic applied to the pulp.

FIG. 411

Lingual filament of pulp of an upper molar, broken in extraction. The rigidity of the filament was due to the presence of calcific granules.

Diagnosis and Treatment.—The *x*-rays may afford a positive diagnosis, but in their absence the diagnosis, apart from the inference from the symptoms, is a postmortem one. In cases warranting the interference, in which there is a delayed response to intense thermal tests applied to a filling or a clean pulpal wall, the dentin over the pulp should be removed and the pulp devitalized. Upon removal of the pulp it may be found to contain one or more large or many granular masses.

Fig. 411 illustrates a case discovered upon fracture of a molar during the operation of extraction. In another case the pulp was slightly bendable when extracted, but after drying for a half-hour became at its apical end of needle-like sharpness and stiffness. It was filled with calcific granules.

The constructive diseases of the pulp are an evidence of an attempt upon the part of the pulp to protect itself; but with the exception, perhaps, of a very regularly deposited secondary dentin the effects react upon the pulp itself, causing its destruction. To what extent, therefore, secondary dentin is beneficial is an open question.

Evidences of constructive action upon the part of the pulp may occasionally be noted in the temporary teeth—*e. g.*, secondary dentin following deep abrasion.

There do not seem to be any observations as to the formation of nodules or calcific degenerations in the pulps of temporary teeth, but there is no good reason why they should not occur, particularly after abrasion. The pulp diseases of the temporary teeth are usually of an acutely destructive nature, which may account in some degree for the absence of reports touching this subject.

CHAPTER XVI.

DESTRUCTIVE DISEASES OF THE DENTAL PULP.

This class of pulp diseases consists of those of an acute character, although chronic diseases may arise as sequels of the original conditions. They are essentially destructive in character and attended by prompt degeneration of pulp tissues. The most important, clinically, are those having an evident association with disorders of the bloodvessels of the pulp.

HYPEREMIA OF THE PULP.

Hyperemia of the pulp is an excess of blood in the more or less dilated vessels of that organ. It is of two forms: active or arterial hyperemia, and venous or passive hyperemia or congestion. These two classes differ in their probable direct causations and in effects.

Arterial Hyperemia of the Pulp.—Definition.—Active or arterial hyperemia of the pulp is an excess of blood in the dilated arteries and capillaries of the pulp, the pulp functions being increased in mild continued cases or disturbed by a gradual passage of the condition into a venous hyperemia in more severe cases.

Direct Causes (*Thermal Shock*).—The most common cause of active hyperemia of the pulp is a lessening of the non-conducting covering of the organ, enamel, and dentin, leading to either (1) direct pulp shock through the chilling or heating of dentin by thermal changes, or (2) by direct fibril irritation which through the odontoblasts and their neural connection invites, by vasomotor stimulation, a flow of blood. This increases the functions of the pulp and therefore its irritability and response either as pain or as further hyperemia or both. With a deep metal filling present the first explanation serves. With a shallow metal filling the second fits the fact of slow onset of hyperemia, recognizable by pain to cold. It is surprising to what an extent the pulp may protect itself against thermal stimuli by the formation of secondary dentin and tubular calcification. Thus teeth filled with metal alone often produce a pulp hyperemia, of which the patient complains as painful reaction to cold, but which passes away in a few weeks. When the cavity is of moderate depth the bruising of fibrils by filling and the thermal shock to fibrils are

causes acting through fibril stimulation. The vigorous use of sandpaper disks in finishing large fillings may precipitate an attack of pulp hyperemia, but only if the pulp is in a critical condition. The loss of tooth substance mentioned may occur either through abrasion, erosion, fracture, or caries. The condition frequently occurs without direct exposure of the dental pulp, and at times when cavities are relatively shallow. Even the simple cervical exposure of dentinal fibrils may cause it, but does not often do so. (See explanation 2.)

Fig. 412 Fig. 413 Fig. 414 Fig. 415

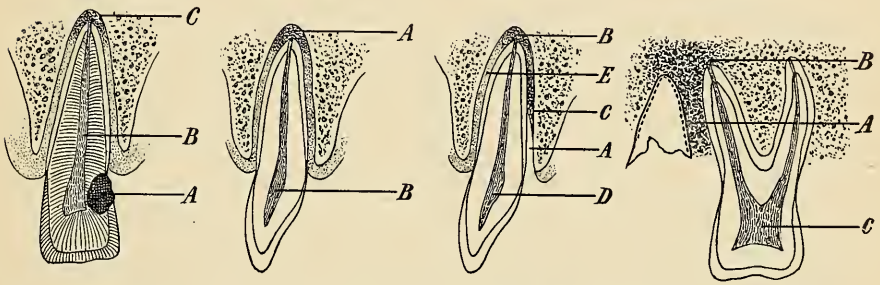

Fig. 412.—*A*, Cavity or metal filling approaching pulp: *B*, hyperemic (sometimes inflamed) pulp; *C*, area of hyperemia of apical tissue, due to extension from the pulp or possibly to back pressure of blood.

Fig. 413.—*A*, Area of non-septic inflammation of apical tissue due to injury as from a blow or malocclusion; *B*, hyperemia or mild non-septic inflammation of the pulp due to overflow from the apical tissue.

Fig. 414.—*A*, pyorrhea pocket; septic inflammation at *C*; *B*, area of lesser inflammation (non-septic); *D*, hyperemia of pulp; *E*, normal tissue.

Fig. 415.—*A*, ulcerated or necrotic alveolar wall due to injury and infection; *B*, inflammation more or less non-septic (lesser inflammation); *C*, hyperemia of pulp due to overflow of blood at *B*. An abscess on an adjoining root has the same pathology. If extending to the molar it infects its pulp from the apex. (See pages on Areas.)

Irritation of Fibrils by Sepsis.—Septic dentin beneath fillings acts as a cause by constantly irritating the dentinal fibrils. The leaving of septic dentin in a cavity and a leaking filling over sound dentin may so act. Inclusion of saliva beneath a metal or gutta-percha filling, and the imperceptible shifting of a filling during placement, are causes of septic dentin. Amalgam may so shift if slight yet excessive force be used in finishing at the first sitting. The sign is the appearance and disappearance of moisture at a visible margin as the filling is moved. This is often unobserved unless one be very thoughtful of its possibility. The cement beneath an ill-fitted crown also appears to become saturated with saliva or serum, and its odor indicates septic irritation. This is less likely to occur under gutta-percha, but odor can be noted in some such cases. This may be the real cause of death of pulp in ground sound teeth and calls for avoidance by the use of thymol in the cement. Acute hyperemia

may occur from the presence of a pulp nodule, probably also a result of mild hyperemia produced by some other cause.

Associated Hyperemia of Pericementum.—All pulp hyperemias, if intense, may extend into the apical tissue and cause pericemental hyperemia with symptoms of tenderness to touch (Fig. 412).

Indirect Causes.—*Extension of Inflammatory Area.*—Pulp hyperemia may also be caused by injury or disease of the apical tissue of a tooth containing a vital pulp. Malocclusion from any cause, overfull fillings or crowns, a blow, or overmalleting, or the extrusion occurring in pyorrhea alveolaris, is competent to produce an apical hyperemia or inflammation which extends into the pulp (Fig. 413). An abscess upon an adjacent tooth may have its area of hyperemia extend into the apical tissue of the tooth adjoining, thus producing hyperemia of the pulp (p. 135, Fig. 415). A fairly deep pyorrhea pocket may frequently act in a similar manner, the inflammation extending as a non-septic one up to the apical tissue (Fig. 414).

Reflex Action.—An intense hyperemia in the pulp of one tooth may, by reflex action, produce hyperemia, with its characteristic response to hot and cold applications, in another tooth. In a typical case an inflamed apical half of the pulp of a third molar produced a hyperemia in the pulp of the first bicuspid which subsided upon removal of the cause *in the molar.* Any of the causes exciting hypercementosis (being causes of pericemental hyperemia) may produce pulp hyperemia, the apical constriction being an added complication. An aphthous ulcer upon the gum over a tooth has produced arterial hyperemia of the pulp by reflex or by extension of the area of lesser inflammation which may in some cases extend a half inch or more. Also an ulcerated alveolar process resulting from infected alveolus, or the use of alveolar forceps, or even the regular healing of an alveolus after extraction, may cause it in a healthy adjoining tooth by extension of the area of inflammation or even in a distant tooth by reflex. Also any irritation along any branch of the fifth nerve or any of its terminals may reflexly induce a hyperemia of the pulp (Fig. 415). A common cold by irritating the terminals of the fifth nerve has produced it, as may a tumor.

Unquestionably, systemic conditions, as malaria, or syphilis, or irritation in another part of the body than that supplied by the fifth nerve, as the uterus or bladder, may excite reflex pain in the teeth, which, if repeated, sooner or later excites a hyperemia, as in the case of scalp tenderness from dental disease, and which will probably be temporary. The mode of hyperemia production is probably a dilatation of bloodvessels due to vasomotor disturbance produced by reflex action.

Apart from the hyperemia occurring in inflammation and that due to septic dentin, or a septic extradental inflammation, it may be said that arterial and venous hyperemia are mainly due to non-septic causes, and even in septic cases to be mainly in itself aseptic, in so far as the pulp is concerned. For this reason if the cause can be removed and the pulp sedated (when necessary) prognosis for pulp conservation is favorable, certainly in mild cases in which the pulp is not directly exposed by caries.

Idiopathic Hyperemia.—In some cases with sound teeth no obvious cause can be found, perhaps the case is one due to infarctions (which see) or pulp nodule. The latter can be located by skiagraphy. Lower incisors are especially prone to it.

Symptoms.—The symptoms of arterial hyperemia vary according to the degree of vascular disturbance. So long as a quick, sharp pain is produced by contact with cold or hot substances, ceasing immediately, and only reappearing in response to direct stimuli, no serious vascular disturbance is inferred; but when paroxysms of sharp pain, lasting from many minutes to hours, follow upon an application of cold to a carious cavity, an unbroken enamel surface, a filling, or an area of erosion or abrasion, a profound disturbance of the vessels of the pulp is indicated.

The pains, in the absence of direct irritation, are, as a rule, but vaguely located. During paroxysms it is of a lancinating character, and usually reflected to another part than the tooth affected—*e. g.*, a sound tooth at a distance, the gum between or above the teeth, the ear, the eye, the supra-orbital region, the infra-orbital region, the scalp, the chin, the arm, etc.

As a rule, when an upper tooth is affected, the pain is located in the superior maxillary division of the fifth nerve; if a lower, in the inferior maxillary division. The pain varies in intensity from a vague uneasiness to an acute neuralgic attack, with tender spots over the point of emergence of the nerve tracts, as at the supra-orbital and infra-orbital and mental foramina. The neuralgic pains are not always constant; they may disappear from the second or third division of the fifth nerve and appear in the first.

The proof of the direct connection between the pulp pain and the neuralgia may, in some cases, be clearly made out by the thermal test. When a jet of cool water is directed against the tooth whose pulp is affected, it may produce, in addition to a local pain, an aggravation of the neuralgic pains, but one must carefully exclude the extradental causes before diagnosticating a necessity for interference with the tooth tested.

Pathology and Morbid Anatomy.—The one distinctive and characteristic anatomical condition associated with active hyperemia is an irregular dilatation of the vessels of the pulp.[1] Fig. 416 represents a section of the pulp of a tooth extracted during a paroxysm of acute pain—"acute paroxysms of pain lasting for an hour or more were occasionally occurring in consequence of very trivial changes of temperature; the condition had existed for several weeks." In some cases of a similar character—*i. e.*, presenting the same symptoms, but extracted during an interval of quiet—nothing remarkable is presented. The gradual enlargement of the veins indicates the lessening outlet at the apical foramen; or, in other words, the beginning and establishment of a venous hyperemia.

The most rational explanation of the dilatation of the vessels is that it is an irregular paralysis of vessel walls—*i. e.*, of vasomotor nerves. Whether the more usual painful responses of the pulp to thermal stimuli are due to the stimulation of vasodilator fibres, which causes hyperemia, is a matter of doubt, but the pathological conditions noted in pronounced hyperemia signify a paralysis of vasoconstrictor fibers. Subjected to repeated overstimulation, they become inactive and the vessel walls yield to the pressure of the blood column. Black's researches indicate that the vessel walls may recover their tone and the vasoconstrictor nerves their functional activity after paralysis. Certainly, clinical experience shows that in all purely arterial hyperemias, or even those associated with mild venous hyperemia—for the two may be inseparable—in cases with symptoms, the cases can be cured if the causes can be removed.

When a tooth pulp responds to thermal stimuli, especially to moderate heat or cold, hyperemia is inferred; but whether the case is one of pure arterial hyperemia, mild or severe, or of venous hyperemia or of hyperemia of true inflammation must be decided by the nature of the cause acting, the physical condition of the pulp (whether exposed or not), the length of time continued, and the length of paroxysm produced. The fact of hyperemia and its location are first determined, next a cause is sought and, if direct, is removed or rendered incapable of action by treatment of the tooth; for example, placement of sedatives, intermediates, etc., in cavity cases, either without or with filling removed (if previously placed). Quiet ensuing and the pulp not being exposed, arterial hyperemia due to the appropriate *direct* cause is diagnosed, tentatively at the first sitting—positively after partial treatment. This also indicates the final treatment. If no explanation of cause be found in the crown of the

[1] Black: American System of Dentistry.

tooth in question, the various indirect causes or reflexes are looked for and if one be found it is removed by treatment. If relief ensue the tentative diagnosis of hyperemia by extension or reflex in the pulp which seemed at fault is confirmed by the therapeutic test.

Fig. 416

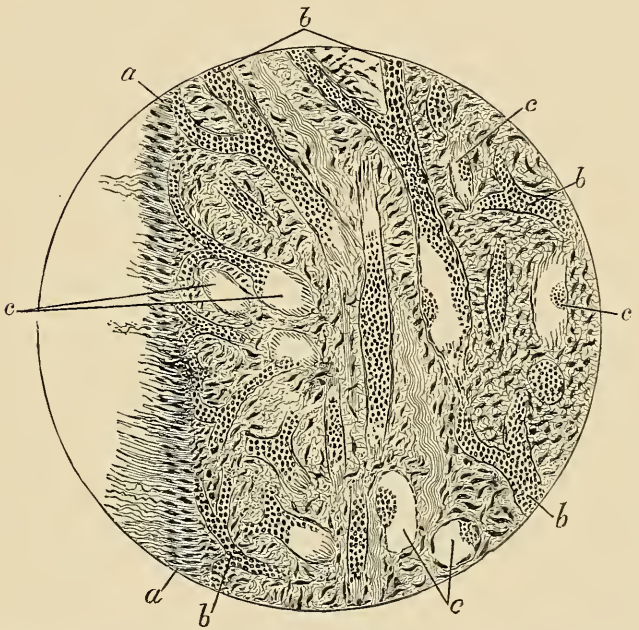

Hyperemia of the dental pulp, showing the injection of the vessels: *a*, *a*, membrana eboris, or layer of odontoblasts; *b*, *b*, *b*, *b*, vessel distended with blood: *c*, *c*, *c*, *c*, points from which the blood has fallen in handling the section. (Black.)

If the case be idiopathic and demand relief the pulp should be removed and the diagnosis of hyperemia is confirmed, though the cause may remain obscure if no nodule is found. In cases of cavity with pulp exposure, with possible sepsis and inflammation, or septic cases with suppuration, the symptoms noted under such conditions are considered. In routine work such pulps are said to be inflamed and removed; they may be conserved in special cases of course. Any hyperemia present is incidental to the inflammation.

The *x*-ray may be of use in clearing the diagnosis in some cases; for example, of pulp nodules or abscess on adjoining tooth.

The grade of severity of hyperemia is determined by the pain produced on application of the thermal test.

The following history of a case offers a good example of hyperemia (so diagnosticated). A central was drilled lingually with a round

bur, by a dentist who mistook a vital tooth for the one threatening an abscess. Finding it vital when the pulp was exposed at a minute orifice, he filled with gold, evidently laying a cylinder of gold across the exposure. For two years the pulp reacted to cold, the response finally becoming so severe that each effort at cleansing the teeth caused pain from thermal shock. As the adjoining tooth was without a lingual pit, and the electric light showed a deep filling, it was removed, and the condition related found. The attempts to remove the pulp by cocain pressure failed four times, once after sedation, and repeated applications of arsenic were necessary.

It is to be remembered that arterial hyperemia may be of several grades of severity, according to the vascular disturbance.

FIG. 417

Dilated bloodvessels from the dental pulp in hyperemia, from tooth extracted during a paroxysm of intense pain. (Black.)

The temperature of the water used in testing should not be lower than 60° F., and it should be applied drop by drop. A normal pulp will rarely respond painfully to a few drops of water at the temperature named, flowed into a cavity; but a hyperemic pulp will almost invariably respond vigorously. As a rule, a current of air from a chip blower is a test of sufficient severity.

In the absence of a carious cavity the source of the pain is to be sought in large fillings, testing each tooth by dropping cool water on the filling; in cases of erosion or abrasion the test is made upon the exposed dentin. The tooth which responds with a quick paroxysm of intense pain, passing away slowly, is diagnosticated as the seat of pulp hyperemia.

In making this test doubt may arise as to which of two adjoining teeth is at fault. A small square of rubber dam, with a single hole punched in its centre, may be passed over the tooth to be tested, thus

isolating it, yet the water will remain in the mouth. As before stated, however, the location of a hyperemic pulp does not always mean the location of the cause, which may be exterior to the tooth, and should be looked for elsewhere before interfering with the pulp hyperemia.

The prognosis of arterial hyperemia is favorable for pulp conservation in the indirect cases and in cases of cavities of decay which admit of cleansing without pulp exposure, or in cases of filled teeth if the fillings are removed, and in which the paroxysms have not been too severe or too often repeated. Properly protected from thermal shocks the vessels may recover their tone. It is also favorable in cases of light blows or malocclusion, if rest of the apical tissues be secured.

It would be favorable in cases of deep erosions which can be filled with non-conductors; but this condition is rarely seen in erosion. It is favorable in fractures without exposure if caps can be secured in place, but is unfavorable in ordinary abrasions unless so much deeper than the general occlusal level, that filling can be placed, or in sound teeth the pulps of which are irritated without evident cause, and in cases in which filling removal would not leave room for non-conductors. In cases of actual exposure of the pulp it contra-indicates attempts at conservation, except in the mildest varieties and most favorable circumstances, and then only when conservation is important.

Treatment.—The therapeutic principles involved in the treatment of this condition are the removal of the source of irritation and the securing of physical rest. The treatment is directed toward immediate relief of the existing condition and the prevention of its recurrence. If a carious cavity exist, it is to be freed from debris, and the grosser portions of the carious dentin are removed; the pulp, if unexposed, is to have the layer of softened dentin covering it left unremoved, if leathery and not disintegrated.

Sedative agents are imperatively called for; of those used the most effective being the oil of cloves, or eugenol, equal parts of oil of cloves, and phenol, equal parts of phenol and camphor (phenol camphor), equal parts of phenol and thymol (thymophen), a saturated solution of thymol in alcohol or of menthol in chloroform or menthol, 3 parts, phenol, 1 part, or solutions of cocain. Thymol or menthol crystals may be added to any of these. Dentalone and Phenandyne and the fluid of "Jodoformagen" are valuable proprietary preparations. These agents are all germicides as well as sedatives, and, therefore, sterilize the dentin of cavities in which they are sealed.

They are to be applied upon cotton used alone or the first pledget

may be covered with cotton and a non-irritating varnish, as inspissated tincture of benzoin, or chloro-percha, or a quick setting temporary cement is used as a covering or a previously prepared covering may be used (see arsenical covering). In from twenty-four to forty-eight hours the tooth is placed under the rubber dam and excavated (if not a case of filling removal); its walls are varnished, and over the wall nearest the pulp a disk of softened gutta-percha is laid. Over this zinc phosphate paste is flowed. "Jodoformagen" may be used in place of the gutta-percha. A stiff mixture of eugenol and Hubbuck's zinc oxid is a very valuable sedative cement to be placed against the floor of an excavated cavity. It hardens in saliva and may remain a time as a test and then be in part left as a permanent floor covering. After lining with zinc phosphate a gutta-percha filling may be introduced for a few weeks. In a case with some persistence zinc phosphate or gutta-percha may be used to complete the test for six months or a year. In mild cases the filling may be completed at once. The conductivity of zinc phosphate is too high to be used as the sole material over pulps which have been the seat of pronounced hyperemia; with varnish it is more useful.

It not infrequently happens that it becomes necessary to assist the pulp arteries to recover their tone by means of counterirritants applied to the gum over the apex of the root. This is especially true in cases of pulp capping. Dental tincture of iodin (iodin, ℥iij; alcohol, ℥j; dissolve by succussion;[1]) or potassium iodid, sat. sol., and zinc sulphate, sat. sol., p. æq., with iodin crystals to complete saturation[2] is to be applied in spots to the gums, or a mixture of equal parts of tincture of iodin and tincture of aconite may be painted upon the gum. A mixture made of two parts of tincture of aconite and one part of chloroform is recommended by Jack,[3] to be applied to the cleansed and dried mucous membrane by means of a pad of cottonoid, one-half inch wide by three-quarters of an inch long. It should be held in place by the finger for fifteen seconds. Tincture of aconite upon cotton, placed in the rubber cup-applicator of a cataphoric apparatus and held against the gum for a half minute while the current of a few cells is active, will produce a circumscribed area of irritation which may later lose its epidermis. This amount of irritation is valuable. A capsicum plaster may be used. For any case of obdurate pain systemic sedation or derivation may be employed. (See pp. 124 and 491.)

If the pulp be exposed, it is probably the part of wisdom to remove it, though if for any special reason capping be demanded, it may be

[1] Flagg.
[2] Northrop.
[3] American Text-book of Operative Dentistry.

done. When the hyperemia is active both cocain and arsenic may be resisted.

In cases of abrasion or erosion an obtundent is applied; an excavation having a retentive form is made, which is varnished in the pulp direction only and filled with preferably a combination of cement and metal; or in abrasion the pulp may require removal. A tooth containing a large metallic filling must have the filling removed, and after reducing the hyperemia a non-conducting layer must be placed between the pulp and the filling. The precaution should always be taken, when the pulps of teeth in which cavities have been prepared respond unduly to the temperature test, to cover the dentinal walls with a layer of non-conducting material. In the absence of this precaution the constant overstimulation of the pulp by thermal impulses conducted through the metallic filling may at any time result in hyperemia. The same precaution is necessary in any very deep cavity. It is also well to avoid fibril irritation by acid of cement, septic cement, or thermal shock when crowns are to be used on vital ground teeth. This may be done by using a thin varnish of gum damar in chloroform plus hydronaphthol over the tooth, and by adding powdered thymol to the cement and in some cases by lining the crowns and posts with chloropercha (see end of chapter on moist gangrene). If mild hyperemia occur after filling with metal, it ordinarily passes away after a few weeks. The fibrillæ at first rebel, then become tolerant, owing to tubular calcification, etc., see page 449.

In the cases due to hypersensitive dentin the powerful coagulants silver nitrate, formaldehyde, etc., are to be tried. (See Hypersensitive Dentin.)

In cases due to apical irritation not only must counterirritants be applied to the gum, but it may be necessary to cap an adjacent tooth with a rubber dam guard in order to guard against the irritation of the apical tissue by overocclusion. (See Acute Apical Abscess, Fig. 549).

If the hyperemia is of a gradual onset and due to an overoccluding filling or crown, this is, of course, to be reduced to normal occlusion. If due to the overocclusion induced by chronic pyorrhea, the overoccluding tooth is to be shortened. If of acute onset, a guard may also be necessary. As illustrating its effectiveness in combination with removal of the cause, may be cited a case of an upper third molar with a small pyorrhea pocket on the mesiolingual aspect of the root. It overoccluded one thirty-second of an inch, each bite producing excruciating local pain, with also reflex to the ear. In twenty-four hours' use of the guard, the pocket having been treated, the occlusion

was almost normal, the reflex pain gone, and the guard was removed and the tooth brought to normal occlusion. In all cases of cause external to the tooth the cause alone is to be treated. Trichloracetic acid, or silver nitrate in saturated aqueous solution, may be applied to inflamed bone or aphthæ; while "dry socket" or exposed and ulcerated alveolus surface must be treated as indicated. (See Index.) The patient is to be directed to avoid the use of very cold or hot substances.

In idiopathic hyperemia the pulp usually requires devitalization, though counterirritants may be tried.

The test of success of remedial measures is the gradual reduction of response to slight variations in temperature—*i. e.*, the pulp gradually bears higher and lower temperatures until, approximately, a normal tolerance is established.

As shown by Jack, this varies for hot applications from 152° F. to 118° F., and for cold ones from 74° F. to 32° F.

In order to determine the rate of tolerance normal to the individual he suggests that sound lower incisors be isolated by the rubber dam and tested by throwing upon them first water at a temperature of 80° F. The temperature of the water is then gradually lowered or raised until slight pain is produced by the test. The point registered by the thermometer will be the normal limit of thermal tolerance for the particular test.

The data gained are useful in determining the progress of a case of hyperemia.

A lack of success in the reduction of the arterial hyperemia is evidence that the more severe condition of venous hyperemia has supervened, or perhaps an infection has caused a true inflammation.

When, after fair trial of conservative treatment, the pulp is persistently irritable, it should be removed.

In the devitalization of hyperemic pulps there is often painful reaction to any of the means employed. Some of these pulps resist cocain pressure in any form even after sedation; some yield after sedation. Sedation or depletion should precede arsenical applications, and if at any time arsenic produce a painful hyperemia or aggravate one previously existing, it must be removed and sedatives used before its renewal, or it may be applied at another portion of the tooth while sedatives are kept against the pulp.

It is evident that such a grade of vascular excitement as exists in cases of exposed dentin is quite capable of producing the constructive diseases of the pulp described as secondary dentin and pulp nodules. On the other hand, inflammation of the pulp has produced resorption of the walls of the pulp chamber.

Pulp Irritation from Electric Action.—It is of quite common occurrence that galvanic electricity causes pulp irritation. The cataphoric current too long continued may induce a hyperirritability of the pulp amounting in some cases to evidence of hyperemia, which may subside under proper treatment or eventuate in pulp death from venous hyperemia. The occasional connection of a newly placed or bright amalgam filling with a gold filling, bridge, plate, or clasp, through the medium of saliva or food (which amounts practically to the same thing), will, at times, produce painful galvanic shocks in a vital tooth. Dr. Franz Trauner[1] has reported that such pain has been felt in devitalized teeth. This is outside of the editor's experience, and should not occur in totally devitalized teeth, as the electric current is a test for pulp vitality. The mouth mirror, or a fork or pin, touched to a new amalgam filling, may also produce the pain, but a nickelled steel instrument usually does not.

Painful shock is sometimes produced by the animal electricity discharged from the operator during dry, cold weather. It usually occurs when the finger is placed upon a metal filling, or the plugger point is returned to a metal filling. Touching the metal part of the chair before approaching the patient will obviate this disagreeable contact.

Treatment.—With cataphoresis, the mischief being accomplished, the case must be treated as other arterial hyperemias.

In the case of shocks from the presence of the two metals it may be ignored if slight and the filling new, as it will probably soon pass away. A well-set and brightly polished amalgam filling may be tarnished if necessary by touching it with a 1 per cent. solution of silver nitrate; or, if good color be a necessity, the pulp of the tooth may be well insulated by means of a gutta-percha substratum, or the pulp may be devitalized. If the fillings be in adjoining teeth, they should be contoured so as to touch persistently if possible. If in the same tooth, the fillings should be connected by either amalgam or gold.

Venous Hyperemia of the Pulp.—Definition.—By venous or passive hyperemia of the pulp is meant a condition of the pulp in which the return of the blood in the pulp to the heart is mechanically prevented.

Causes, Pathology, and Morbid Anatomy.—But two causes seem competent to produce such a venous hyperemia. These are: (1) A preëxistent arterial hyperemia; (2) thrombosis of vessels at the apex of the pulp canal. The venous hyperemia which is the second

[1] See Dental Cosmos, 1903.

stage of inflammation is to be remembered, but excluded from present consideration.

In arterial hyperemia the excess of blood is contained in enlarged capillaries and arterial trunks. The enlarged main trunks or trunk at the apex of the pulp *must* compress the veins, as the apex of the canal is unyielding. In proportion to the severity of the arterial hyperemia, therefore, are the emergent veins unable to remove the blood collected in the capillaries and venules, which gradually enlarge into varicosities in consequence.

It has been shown by Hopewell-Smith[1] that thrombosis of the small veins and capillaries throughout the pulp may result in rupture of the arteries, and hemorrhagic extravasations occur—either single or multiple. These he terms hemorrhagic infarcts, although the description given more accurately denotes a minute venous hyperemia. (See Fibroid Degeneration of the Pulp.)

Black has shown that the diapedesis of red corpuscles, which is a characteristic result of engorgement of the veins in venous hyperemia, occurs in the pulp. Edema, which usually accompanies venous hyperemia in other situations, cannot well occur in the pulp because of its unyielding surroundings (Fig. 418).

It is possible, however, that fluid may exude into the perivascular spaces, compressing the cellular elements. Black has shown that deposits of lymph may thus occur in pulpitis. The intense congestion and distention of the vessel walls permit a free diapedesis of red corpuscles into the pulp tissue. Disintegration of the red corpuscles may occur and the hemoglobin matter of the corpuscles may be diffused through the dentin, giving it a pink discoloration technically known as "suffusion." The infiltrated dentin may then become progressively discolored through the characteristic changes of color noted in connection with gradually decomposing hemoglobin —becoming purplish, dark blue, and finally blue black. The color may pass into the yellow or brown coloration (see Tomes' case). Cases have occurred of coronal suffusion in which the pulp vitality has persisted for months. In some cases the bulbar portion alone may be dead. Partial gangrene and the general darkening of the tooth may be present even in a single-rooted tooth with the pulp partly alive. This is proof that collateral circulation exists in the pulp. In cases of suffusion even all the root of a molar may be suffused, and pericementitis, associated with such a hyperemia, seems particularly intractable. The vasomotor paralysis is extreme.

Tomes[2] records a case of a blow upon four upper incisors, which

[1] Dental Cosmos, 1907.

[2] Manual of Dental Anatomy.

became loose and painful. A few days afterward reddish spots appeared upon the labial surface, which later became dark blue. These disappeared except for a slightly yellowish tint. Four years later the pulps were found vital and healthy. This rare case is confirmative of the previous statements.

If a tooth receive a blow of sufficient severity, its pulp may die without much evidence of pulp pain. On the other hand, if the blow be less severe, it may give evidence of an arterial hyperemia, gradually increasing in severity.

FIG. 418

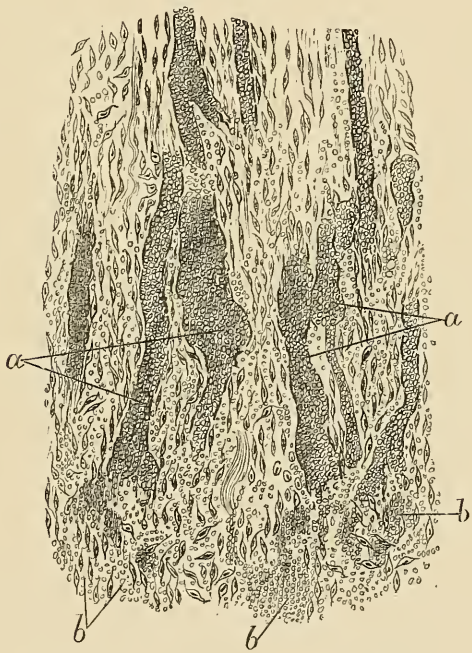

Section of hyperemic pulp, showing aneurysmal dilatation of the vessels, extravasations of blood, and red blood disks escaped apparently by diapedesis: *a*, *a*, dilated vessels; *b*, *b*, *b*, extravasated blood. Besides this, red blood disks are plentifully distributed everywhere in the neighborhood of the veins. The tooth was extracted during a paroxysm of pain. (Black.)

In the former case it is probable that the bruising of the apical tissue produces a condition of thrombosis at the apex which involves the pulp by shutting off both its afferent and efferent vessels. A stagnation results, and death from lack of nutrition occurs. This is also termed "jugulation."

In the latter case the thrombosis has not occurred, but an arterial

hyperemia is set up by the overflow of blood from the apical tissue into the pulp, and goes on to venous hyperemia.

It is quite probable that rapid death of the pulp in pulpitis is due to the associated venous hyperemia.

Kirk[1] mentioned an interesting case of venous hyperemia with intense suffusion of all the teeth as the result of hanging. In such a case there was arterial blood supplied to the teeth, but the venous flow was checked.

Symptoms.—The symptoms of this condition, in the absence of definite data, can only be inferential. When the paroxysms of pain are continuous, instead of temporary—that is, when the pain, instead of temporarily subsiding, maintains a constant intensity for hours and does not respond promptly to sedative therapeusis, and is accompanied by a sense of fulness rather than sharp agony—a condition of serious venous congestion is inferred. The case from which Fig. 418 was taken had been the seat of intense paroxysmal pain for some hours. Upon close approach to such a pulp, blueness of the horn instead of pinkness may sometimes be seen.

Prognosis.—Perfect recovery from this condition is extremely doubtful, so that if the pulp be not intentionally devitalized and removed, it will undergo degenerative changes. The fact that pulps have remained alive for years, after having been the seat of marked congestion, scarcely warrants the attempt to save so seriously crippled an organ.

Treatment.—The prognosis being doubtful, the pulp should be obtunded and devitalized. If the pulp pain does not yield to sedatives, it should be gently exposed if the excavation does not accomplish its exposure. An antiseptic is to be applied, and by means of a very sharp puncture probe the pulp is to be delicately punctured. A free flow of blood follows, which relieves the vascular engorgement. When this is accomplished the cavity is to be syringed out with warm water, and a pellet of cotton containing a saturated solution of menthol in chloroform may be sealed in the cavity, or simply retained by means of a second pellet of cotton saturated with inspissated tincture of benzoin or chloro-percha. After twenty-four hours an arsenical application may be made for the purpose of pulp devitalization, or the pulp may be removed by other means if tolerated. If desired, the bulb of the pulp may be taken out under general anesthesia, or the whole pulp under mucous, or conductive anesthesia (see p. 407), or, possibly, under cocain pressure anesthesia, though intense hyperemia counteracts, as a rule.

[1] Private communication.

The extreme paralysis of the vessel walls is occasionally shown by persistent hemorrhage after depletion, and which resists ordinary effort at limitation. In some cases the intense pain may continue as well. The application to the pulp of a mixture of powdered thymol and dried alum, equal parts, taken up on a pellet of cotton moistened with a saturated solution of thymol in alcohol, has proved useful in some cases. A general anodyne may be required for relief of the pain.

INFLAMMATION OF THE PULP (PULPITIS).

Definition.—Pulpitis is the occurrence of the phenomena of inflammation within the pulp tissue. The characteristic emigration of leukocytes from the bloodvessel into the perivascular tissues must have occurred.

Causes.—This morbid anatomy is usually found associated with diseases of the tooth crown or pericemental tissue which admit bacteria to the pulp. At the same time it is quite probable that a non-septic irritant, such, for example, as a partially absorbed extravasation of red corpuscles or undue pressure of a filling upon a thin lamina of healthy dentin overlying the pulp, or as has occurred of a metal filling upon or even extending into a pulp, or an escharotic applied to the pulp may induce the characteristic pathology of inflammation which may be non-septic or septic according to the sterility at the time of operation.

According to the character of the cause, therefore, inflammation of the pulp may be divided into simple and infective. It may be that a simple inflammation may become an infective one owing to the association of bacteria—*e. g.*, the pressure of a foreign body may initiate the process and the inflamed pulp become a soil for the propagation of the bacteria present.

The causes of pulpitis may be grouped under three headings:

1. Mechanical or physical causes, which irritate by acting as foreign bodies, or by pressure.

2. Chemical causes, which act as irritants by either producing a chemical destruction of pulp tissue, or by irritation without direct destruction. In the former case the dead tissue acts as a foreign body against which the pulp reacts in an effort to cause its exfoliation or absorption.

3. Parasitic or infective, which cause the phenomena of infective inflammation.

Pulpitis is classified, according to its extent, into partial and complete; according to its duration, into acute and chronic; according

to its infective character, into purulent and non-purulent; and, again, according to the character of the degeneration which follows upon the inflammatory process. While pathologically these conditions may be clearly differentiated from one another, they may be reduced to more compact groupings according to their clinical significance. For example, acute pulpitis is frequently infective, partial, and purulent; chronic pulpitis is frequently non-infective, extensive, non-purulent, and followed by secondary degenerations. It is, however, often purulent, and, of course, infective.

For the sake of convenience, pulpitis will receive a clinical division into acute and chronic.

Acute Pulpitis.—By acute pulpitis is meant that form of inflammation of the pulp which runs an active and more or less violent course toward pulp death, and has associated with it acute paroxysms of pain.

Causes.—The causes of acute pulpitis are direct and indirect, intrinsic and extrinsic; the vast majority of cases being due to extrinsic causes. The direct intrinsic causes are hemorrhagic extravasations accompanying venous congestion, or thrombosis (Infarction), pulp nodules, and injury of the vessels at the apex of the root. The direct extrinsic causes are, perhaps, invariably associated with bacterial invasion, a possible exception being the pressure of filling material upon a thin elastic lamina of softened dentin, covering the pulp. The dental pulp is intolerant of the slightest pressure, and rebels vigorously when subjected to compression. Irritating drugs may also act as irritants—*e. g.*, zinc chlorid. It is not necessary that the pulp should be exposed to permit bacterial infection, and extensive bacterial invasion is probably not necessary for the production of pulpitis. The waste products, ptomains, etc., of bacteria may find their way to the surface of the pulp *via* the dentinal tubuli, through a layer of softened dentin, and excite inflammation. It is extremely probable that infection of the pulp is an invariable consequence of its exposure by decay; but as a pulp may be exposed without subjective evidences of hyperemia or inflammation, it follows that infection does not necessarily imply inflammation, though the absence of acute symptoms may be accounted for by the escape of the effusions into the cavity of decay. The presence of a gross irritant, such as a mass of food debris, vegetable seeds, bread crumbs, etc., in contact with the pulp will precipitate an acute inflammation in which bacterial relations must be taken into consideration.

"The severity of the inflammation does not appear to be proportionate to the number of bacteria present, and in a highly in-

flamed pulp we may be able to find but few bacteria. . . . The conclusion seems to be justified that the inflammation is due to the combined action of the bacteria and their products (acids, ptomains, etc.) with which the carious dentin becomes impregnated."[1] Goadby has shown that the Streptococcus brevis and Bacillus necrodentalis may pass through the tubules of even secondary dentin.

Pulpitis from injury of the vessels at the apex of the pulp must be mentioned. It may occur in consequence of blows, biting upon hard substances, too rapid wedging, the rapid movement of teeth in orthodontia,[2] and the progressive loosening of teeth in pyorrhea alveolaris. In these cases the pericementum is primarily affected

FIG. 419

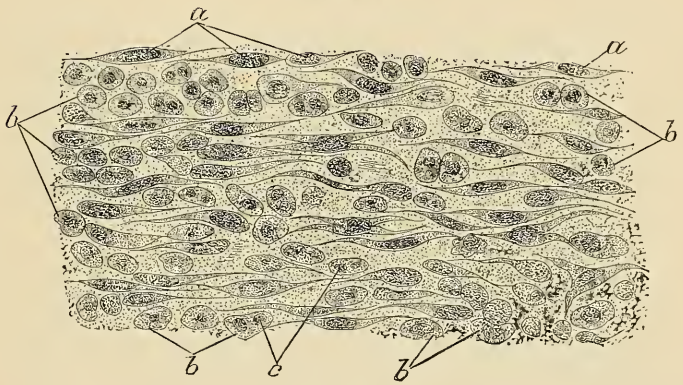

Inflammation of dental pulp: *a*, *a*, normal cells; *b*, *b*, *b*, *b*, inflammatory elements; *c*, cells in process of division ($\frac{1}{10}$ inch.) (Black.)

by a non-septic pericementitis which extends into the pulp, producing arterial hyperemia as an accompaniment, and the teeth are tender upon percussion as well as sensitive to thermal changes. In these cases the pulp may have either hyperemia or non-septic pulpitis, impossible of differentiation unless the tooth be extracted. Pain in the teeth upon assuming the recumbent position, dull, heavy uneasiness about the jaws, and inordinate response to thermal stimuli, particularly to heat, point to pulpitis. Bacteria from an abscess on an adjoining tooth or from a pyorrhea pocket when these actually reach the apical region of the tooth in question may

[1] Miller: Dental Cosmos, 1894.

[2] Buckley, through a circular letter to orthodontists, obtained opinions that the upper centrals and laterals are most liable owing to the frequency of displacement, character of movement, prominence of location, and the curve of lateral roots. Items of Interest, December, 1910.

infect a pulp from the apex. This will cause the death of a single pulp, but only inflammation in a multirooted pulp. Infection by way of the blood stream is a possibility. The pressure of an impacted tooth may also act as a cause by pressing the apical tissue, or by causing resorption of the root (see p. 292).

Morbid Anatomy and Pathology.—In determining the existence of pulpitis, no matter what the symptoms which have presented or the condition as to exposure, etc., the microscopic examination of sections of the affected organ constitutes the only decisive test; if the changes characteristic of inflammation be absent, no matter what the symptoms, pulpitis did not exist. The essential feature of the process is

FIG. 420

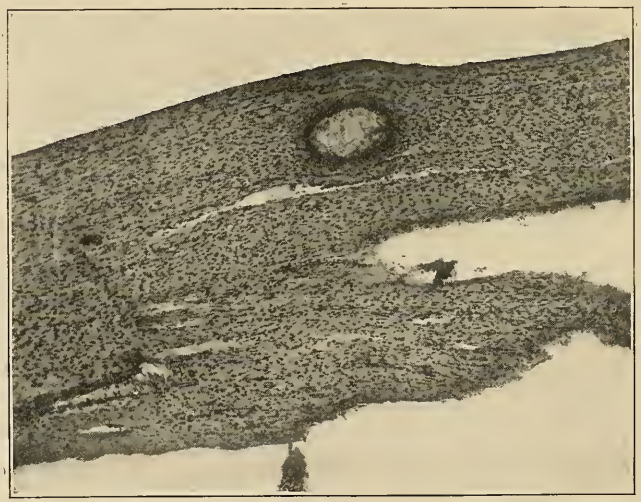

Interstitial pulpitis with pulp nodule *in situ*. (V. A. Latham.)

emigration of the white blood corpuscles from the small veins into the intercellular matrix of the pulp. At first the inflammatory elements (leukocytes) are scattered through the spaces between the pulp cells (Fig. 419); at a later stage the territory is occupied by round indifferent cells alone. The inflammation may be widespread, as shown in Fig. 420, or may be localized to some portion of the pulp, as one horn of a pulp; Black noted also inflammatory action occurring in small islands (Fig. 421).

Swelling of the pulp (from exudation) cannot occur unless there be a break in the wall of the pulp chamber through which additional space can be gained. Black has recorded that "he found *beneath* the

layer of odontoblasts in the region of an exposure an unmistakable deposit of inflammatory lymph. The case had a history of severe toothache for two days, two weeks previously. The pulp exhibited evidences of previous extravasations of blood from hyperemia."

There is evidence that the pulp may recover from attacks of inflammation, and that resolution occurs. In some cases, as shown under the head of calcareous degeneration, the tissues may become infiltrated with calcic material. In others, chronic degenerative changes—inflammatory degeneration—may supervene.

Fig. 421

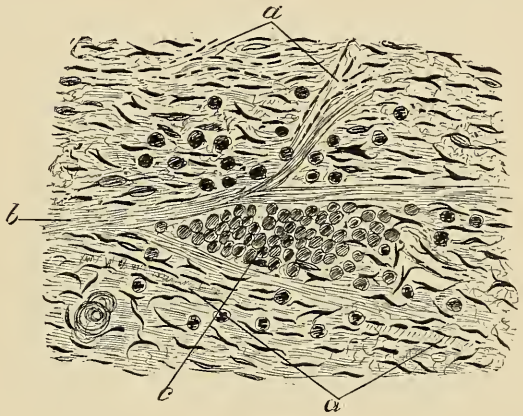

Minute inflammatory focus within the tissues of the pulp: *a*, *a*, arterial twigs; *b*, a nerve bundle; *c*, collection of leukocytes. (Black.)

Suppuration of the pulp is a common accompaniment of pulp inflammation; this, being necessarily infective, will be described separately.

Gaskell[1] has reported a case where a central incisor entirely free from caries exhibited on its palatal aspect a pinkish tinge, which increased in depth until the enamel overlying crushed in, revealing the pulp of the tooth lying immediately beneath; there had been a resorption of a large mass of the dentin lying between the pulp and the enamel. The pulp was removed and the tooth filled. No history is given as to the condition of the root, whether resorption had occurred there or not. Shortly after, the adjoining central incisor exhibited a like pink coloration, which increased, leading to the inference that resorption was in progress in this tooth also. At the suggestion of E. C. Kirk the patient received continued doses of

[1] Proceedings of the Academy of Stomatology, Philadelphia, 1895.

arsenic iodid and the compound syrup of the hypophosphites, in the hope of inducing a general and local constructive metamorphosis. This treatment was followed by a gradual disappearance of the pink coloration, an evidence of a redeposition of dentin. In the absence of histological data it is impossible to state just what was the nature of the repair tissue in this particular case, but Miller[1] has shown that the pulp may take up a resorptive function and remove dentin which may later be redeposited as anomalous tissue. The new dentin does not contain tubules, but has the characteristics of cemental tissue[2] (osteodentin), or even bone with Haversian systems[3] (Fig. 422). This process has its analogue in the tusks of elephants and also in the production of Howship's lacunæ in the resorption of the pericementum, these lacunæ later being filled up with cementum.

Fig. 422

Resorption of the walls of the pulp chamber and redeposition of new calcific matter: *a*, pulp chamber; *b*, *c*, *d*, portions of resorption areas not refilled and walled off by the new deposit-forming cavities occupied originally by the pulp tissue. (Miller.)

There have been cases of inflamed pulp in teeth decayed while yet impacted. In these cases there is usually some form of sinus connecting the tooth with the mouth.

Symptoms.—The early stage of inflammation is an arterial hyperemia, and as the leukocytes collect in the venules a venous hyperemia is established. No matter how far the area of stasis extends, beyond it will exist an area of arterial hyperemia. Owing to the enclosing

[1] Dental Cosmos, August, 1901.
[2] Hopewell-Smith: Histology and Pathohistology of the Teeth. [3] Salter.

canal walls and constricted apex a general venous hyperemia may be established which causes the death of the pulp.

In view of these facts it is not surprising that the symptoms of pulp inflammation take on somewhat the characteristics of both arterial and venous hyperemia. The diapedesis of leukocytes and exudation of fluid cause the phenomena of heavy, boring pain and a feeling of internal pressure.

The pulp may be exposed and no symptoms be present. A sudden pressure of food or toothpick, suction upon the pulp or the contact of cold or hot, salt, sweet, or acid substances, may excite an attack of throbbing or lancinating pain. This may be localized in the tooth or may be reflected to other teeth or the parts mentioned under hyperemia (p. 471).

The assumption of the recumbent position permits an increased flow of blood into the paretic vessels of the pulp and increased suffering results in correspondence with the law that inflamed parts are always more painful in the dependent position. (See p. 131 and 201.) Indeed, recumbency is sufficient at times to induce a paroxysm in a comparatively quiet but inflamed pulp. Under a capping or filling pressing on the pulp or thin dentin the pain may begin as a slight pain and gradually increase in intensity, or it may respond as a sudden agony, beginning even some time after the operation. This may have been known at the time of operation or been suspected later. In one typical case, violent reflexes occurred sometime after a metal filling was introduced over sound dentin. The diagnosis was uncertain but filling removal and placement of eugenol and zinc oxide cement for a month, removed the reflexes, permanent filling was done and after a year no trouble exists—diagnosis, pressure irritation. In the later stage of pulp inflammation the pain is of a heavy, boring, continuous character, the pericementum becomes somewhat hyperemic, and the tooth responds to tapping. In case of a highly irritable pulp, however, the concussion of the pulp produced by tapping may readily cause pain.

In pulpitis the pulp responds both to heat and cold, but, as a rule, more to the former than to the latter. There have been many cases of reflex neuroses developed by inflamed pulps, reflex pains in the face, eye, ear, neck, scalp, chest, arm, heart, etc., as well as functional disorders of the eye, ear, and brain. One case of dementia præcox was cured by removal of a tooth with inflamed exposed pulp.[1] One case of sensory paralysis of the entire left side was caused by inflammation of a portion of the pulp in a right upper cuspid and marked

[1] Upson: Dental Cosmos, 1910, p. 529.

relief began in about an hour after removal of a covering dressing and filling. The symptoms of suppurative inflammation may differ somewhat (see Abscess and Ulceration, p. 492).

Diagnosis.—The diagnosis is largely inferential and made by observation of the symptoms and conditions existing. The pulp may be exposed or closely approached by caries, or the pulp may be approximated by a large filling. If there be a leak about the filling, a septic fluid or actual decay beneath the filling may be the exciting cause. In the absence of evident causes such sepsis is always to have consideration, and, if necessary, the filling must be removed and tests applied. The more obscure causes, such as abscesses upon adjoining teeth, infection from the pericemental tract in the course of pyorrhea, looseness of teeth or traumatisms, are to be carefully considered. If the tooth involved be uncertain, each tooth should be placed under rubber dam and tested thoroughly.

Prognosis.—The prognosis is always bad for the comfortable conservation of the pulp, and it should be removed and the canal filled.

Treatment.—The treatment of pulpitis involves the reduction of the amount of blood in the vessels of the pulp, the sterilization of the infected area, the relief from the pain, and the removal of the pulp. It is usual to excavate the cavity of decay thoroughly enough to remove from over the pulp decayed dentin which would prevent the action of remedies or act as an irritant. The cavity is then washed and a sedative applied. (See p. 475.) A creamy paste of bicarbonate of soda in carbolic acid has been recommended.[1] The addition of a trifle of powdered alum to any of the sedatives acts as an astringent to the vessels. During the half hour succeeding the application the pulp should give some indication of relief. If it be somewhat decided, a portion of the remedy used should, if possible, be sealed in the cavity for twenty-four hours. The covering may be prepared first as for arsenic. (See p. 527.) If not possible to seal it in, it may be covered with cotton saturated with a varnish made by evaporating tincture of benzoin. This varnish hardens like sandarac varnish, but, unlike it, is not irritant. Claims are made for alcohol used as for pressure anesthesia.

If after the first half hour no indication of relief has been obtained, it is well to expose the pulp and to relieve the engorged vessels by delicately puncturing it. (See Extirpation of Pulp.) After exposing the pulp it will perhaps exude a bead of pus, which makes the diagnosis one of pulp suppuration. After free bleeding, which may be

[1] Gerdtzen.

encouraged by means of warm water, the sedatives will usually act. It may be necessary at times to employ short general anesthesia (nitrous oxid gas, etc.) as a means to obtain free bloodletting. Everything being prepared, the patient is anesthetized and the bulb of the pulp cut out, or if N_2O and O anesthesia can be used, the entire pulp may be taken out. At times cocain pressure anesthesia is effective at least for the removal of the bulb of the inflamed pulp, and sometimes of the entire pulp; often, however, it causes too much pain. When several trials have been made, and even the cotton forced into the pulp tissue without complete anesthesia, a pellet of devitalizing fibre may be put into the pulp chamber with no discomfort.

In case of partial extirpation, not only is free bleeding induced, but the diseased pulp tissue is largely removed. When hemorrhage ceases arsenic may be applied, or pressure anesthesia attempted. If the hemorrhage be obstinate the application of powdered thymol and dried alum may be used. (See Venous Hyperemia.) When sedatives are used upon the pulp, counterirritants applied to the gum are aids of great value, and are to be used as described under Arterial Hyperemia (p. 476).

In addition to these the principle of depletion may be employed. Deep cuts may be made with a sharp bistoury in the gum overlying the root apex. The anastomosis with the vessels of the apical tissue is expected to cause the cuts to act as openings made in veins leading from the inflamed pulp. According to Nancrede, depletion on the venous side of an inflamed area markedly reduces engorgement. In addition to these measures catharsis is a valuable means of derivation; a tablespoonful of sulphate of magnesia is to be dissolved in a goblet of water and taken internally at least a half hour before a meal.

If the pain be obdurate and its return feared, two $\frac{1}{8}$ grain sulphate of morphin tablets may be dispensed, preferably by the operator, to be taken only in case of severe pain and an hour apart. Acetanilid and phenacetin are also useful.

The following is a useful anodyne and antineuralgic prescription:

℞—Acetphenetidini (phenacetin),
Acetanilidi . . . . . āā gr. xxx
Quininæ sulphatis . . . . . gr. xv—M.
Pone in capsulas no. vi.
S.—One morning and evening.
(See also Treatment of Facial Neuralgia.)

Hall[1] has suggested:

℞—Aspirin . . . . . ʒss
Codein . . . . . gr. iss
M. et. ft. chart. No. vi.
Sig.—One every half-hour until relieved.

[1] Dental Cosmos, 1910, p. 1085.

Trigemin is also useful.

Quiet of the pulp must be secured before an arsenical application is made, or the latter merely increases the irritation instead of promptly devitalizing (an exception is noted above). Should such an irritation occur or be feared, arsenic may be sealed in an opening made in another part of the tooth (a "pocket"[1]), with a view to devitalizing the pulp through an avenue of healthy pulp tissue. At the same time the pulp may be quieted by sedative applications made in the cavity of decay.

Instead of drilling a special pit, the arsenic may be applied at a portion of healthy dentin in the cavity, which is at some distance from the orifice of exposure; over the latter the analgesic may be placed (see p. 515, etc.).

SUPPURATION OF THE PULP.

Definition.—By suppuration of the dental pulp is meant a formation of pus on its surface (ulceration) or in its substance (abscess). It occurs both as an acute and as a chronic affection.

Causes.—The immediate cause of suppuration of the pulp is the ingress of pyogenic organisms to the pulp. As in inflammation of the pulp, while usually associated with direct exposure of the pulp, suppuration may occur in pulps covered by softened or even unsoftened dentin.

Fig. 423

Invasion of pulp by micrococci. (Arkövy.)

Arkövy[2] first observed infection of the pulp while still covered by a layer of unsoftened dentin (Fig. 423).

Goadby has shown that microörganisms may penetrate even secondary dentin, a condition not infrequently seen (Fig. 423). Miller states that sections of the overlying dentin in a case of suppuration of the pulp showed the same forms of bacteria as were found in the pulp itself.

Bacteria which have entered the body through wounds, etc., may be deposited in the pulp as well as in any other part of the body, wherever there may be a lessened resistance at the time. While bacteria may thus enter from the circulation, there is usually abundant opportunity for their entrance from the mouth. Suppuration

[1] Flagg.

[2] Diagnostik der Zahnkrankheiten.

of the pulp is a not infrequent sequel of the capping of pulps which have given evidence of a previous hyperemia or inflammation.

Morbid Anatomy and Pathology.—Anatomically pulp suppuration (purulent or pyogenic pulpitis) is of two general varieties: one begins upon or close to the suface of an exposed pulp, and gradually destroys the organ through a process of progressive ulceration (Fig. 424); the second, that confined in the substance of the pulp, causes the gradual destruction of a part of the pulp through the formation of circumscribed abscesses (Fig. 425).

FIG. 424

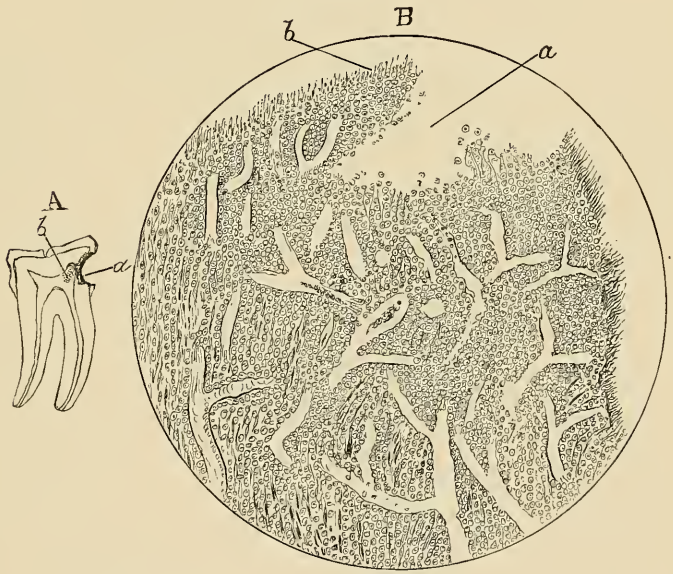

A, diagram of lower molar with caries at *a* which exposes the pulp; the darkened portion at *b* shows the extent of the inflammation; the rest of the organ was free from inflammatory change. *B*, illustration of the inflamed tissue, showing a part destroyed by suppuration at *a;* the odontoblasts are undermined at *b;* the bloodvessels which were filled with blood clot in the section are left blank here, that they may be more apparent. (Black.)

Ulceration of the Pulp.—Of these two forms, ulceration is the more common. The capillaries (Fig. 424) are blocked with coagulated blood (they are left open in the illustration to clearly mark their position); the intercapillary meshwork is occupied by inflammatory exudation; the surface of the pulp is eroded and covered with pus corpuscles; the ulcerative process is undermining the layer of odontoblasts. The suppurative process penetrates the body of the pulp, following the direction of its veins and hollowing out the organ

into a deep cavern. Black regards the persistence of the layer of odontoblasts as indicating an inferior vitality, as it shows they are less susceptible of change of form than the other cells of the organ.

Fig. 425

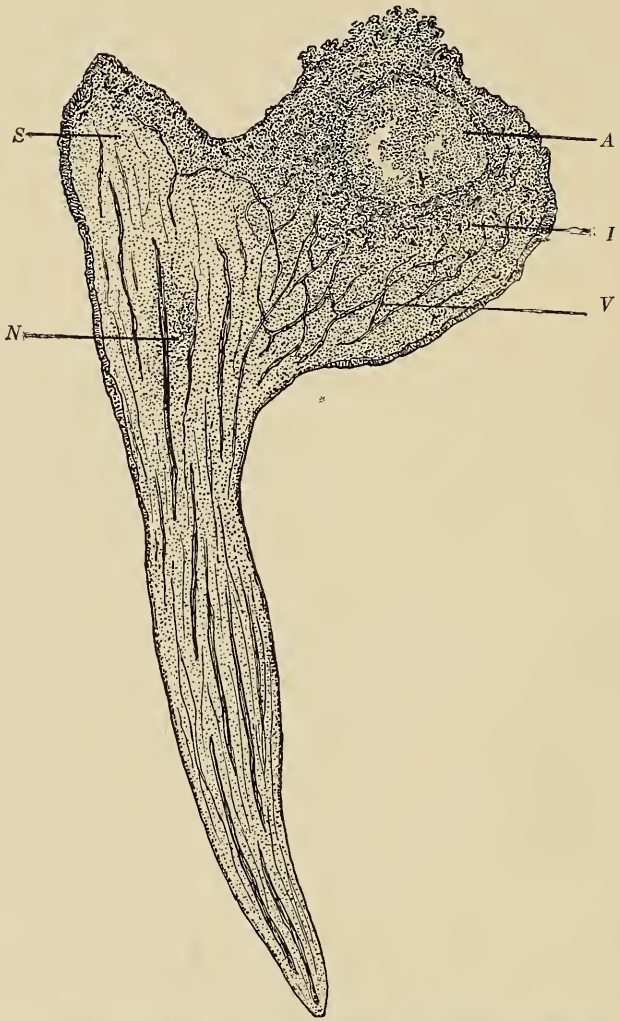

Acute suppurative pulpitis in the coronal portion; *I*, intensely inflamed horn; *A*, abscess; *V*, bloodvessels engorged with blood; *S*, superficially inflamed horn; *N*, nest of inflammation. × 10. (Bödecker.)

The process of ulceration may continue for weeks or months until the entire organ has been destroyed molecularly. The necrotic portions undergo putrefactive decomposition, probably passing through

the same stages that any albuminous substance passes in its serial decomposition, into the end-products—ammonia, carbon dioxid, hydrogen sulphid, and water.

"Very interesting and instructive results were obtained by examining the material from different parts of the same tooth. In the case illustrated in Fig. 426 the pulp chamber at *a* was wide open and filled with food particles, which had a foul, half-putrid odor; at *b* the pulp was putrid and foul-smelling; at *c* there was a small abscess, filled with pure white pus, while the tissue between this point and the apex of the root was highly inflamed and bright red. Material from the pulp chamber (Fig. 426, *a*) contained the forms shown in

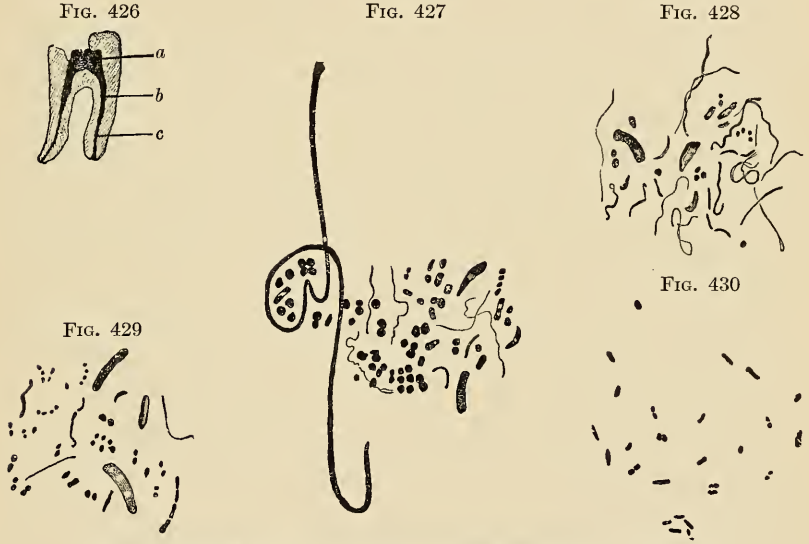

Microörganisms found in cultures from gangrenous pulp. (Miller.)

Fig. 427; material from point *b* those shown in Fig. 428, and from the point *c* those shown in Fig. 429. We perceive a gradual diminution of the large cocci, and the appearance of small, delicate cocci and diplococci." (Miller.[1]) The editor has observed cases of vital but finally ulcerated pulps under canal fillings. In one case twelve years had elapsed between the partial canal filling and the more recent observation.

Symptoms.—If the cavity of decay be open the pus and serous exudate may freely escape, so that the symptoms may not exceed a dull, gnawing pain, which is usually reflex in character.

[1] Dental Cosmos, 1894.

As a rule, the response to cold will be much delayed or even absent. Intense pain may exist when the pus cannot find exit owing to food debris being massed in the pulp chamber, or owing to the presence of a filling or mass of secondary dentin. The case then resembles and practically becomes one of abscess of the pulp.

The chief diagnostic feature of pulp ulceration is the presence of the subacute inflammatory symptoms described above and the presence of a pulp partially removed by decomposition of its upper portion.

Thus if the pulp chamber be open at one horn, and a probe may be passed into it for a short distance until it comes into contact with an irritable portion of pulp, and when withdrawn have the odor of putrefaction, the diagnosis is clear—loss of pulp substance by putrefactive changes, presumably by suppuration. In some teeth it may be by partial gangrene. Many phases of this condition may be seen; thus in an extreme case one canal of a lower molar contained a highly irritable vital filament of pulp extending but one-quarter inch from the apical foramen; a second canal was entirely occupied by a perfectly vital but ulcerating filament; the third canal contained an entirely dead pulp. The bulb of the pulp had disappeared, doubtless by suppuration.

Treatment.—The treatment of pulp ulceration in its early stages involves the opening of the orifice of exposure, the sterilization of the superfices of the pulp, and pulp removal.

Superficial sterilization may be accomplished by removing the pus or putrefactive material present by means of warm 3 per cent. hydrogen dioxid. The saturated solutions of thymol in alcohol or menthol in chloroform, or 2 per cent. formaldehyd or formocresol diluted to 3 per cent. formaldehyd strength may be sealed in position against the pulp for twenty-four hours as an antiseptic. The application of arsenic may then be safely made. In favorable cases the bulb of the pulp, or even the entire pulp, may be removed at the first or second sitting by means of cautiously applied cocain pressure anesthesia. In some cases, however, the patient will rebel. (See p. 515, etc.)

When a part of the canal filaments alone remain, after syringing to remove pus, the pressure anesthesia may be resorted to. A long thread of cotton is saturated with carbolic acid or carbolic acid and cocain, and gently packed into the canal against the pulp filament. Pressure with vulcanizable rubber is now produced, and after a few minutes the pulp will be sterilized and anesthetized sufficiently for removal. It is better to treat each canal separately as a general pressure will probably fail. Puncturing is also useful at times (see p.

531). Arsenic may be cautiously placed on cotton half-way up a canal against such a pulp filament. Another method consists of packing a thread of cotton dipped in carbolic acid tightly against the filament, in which thrombosis is thus induced. (See also p. 531.)

Abscess of the Pulp.—Abscess of the pulp is usually situated near the point of exposure of the organ. It may be confined to one horn of the pulp, or may involve nearly the entire substance of the pulp, the peripheral tissue of the pulp being unbroken. Abscess may exist at some distance beneath the surface of the pulp, and the latter be still covered with a layer of dentin. Burchard once uncovered the horn of a molar pulp which was covered by a lamina of hard dentin, and no fluid appeared; but upon passing a sharp probe into the *white* area of exposure for over one-eighth of an inch or more there was a free flow of pus which quickly filled the larger carious cavity. A pulp removed entire from a tooth, and which was yellowish white in color and unbroken, showed upon section its interior hollowed out into an enormous abscess cavity (Fig. 431). The bloodvessels were blocked; the peripheral tissues were unaltered; between the odontoblasts and the abscess cavity, the latter lined with pus corpuscles, evidences of inflammation were plenty. Black found that the odontoblasts retained their form after neighboring cells of the pulp had been destroyed.

Miller's[1] researches show a preponderance of cocci and micrococci in cases of enclosed abscess; cocci and diplococci were of constant occurrence. Many of the forms, both cocci and bacilli, were cultivable upon gelatin and agar-agar. Some of them, cocci and bacilli, brought about the liquefaction of gelatin; other did not. So that it must be inferred that infective inflammation and necrosis of the pulp may occur without suppuration. (See Gangrene of the Pulp.) In some instances streptococci were found. In the freely exposed pulps varieties of organisms were found which would render clear the possibility of a general infection by way of the dental pulp.

Symptoms.—The usual symptoms are as follows: In a tooth containing an enormous filling, one in which the pulp has been exposed, or in a tooth having a large carious cavity, the patient gives a history of discomfort or decided pain, appearing at intervals, sometimes appearing and disappearing suddenly, the existing condition having been ushered in by dull, gnawing pain, which is usually not positively located, although it may be. The pain grows in intensity, and, in contradistinction to the pulp conditions previously described, pain

[1] Dental Cosmos, 1894.

is relieved instead of increased by applications of cold. It may be, however, that the prolonged contact of iced water may induce a

Fig. 431

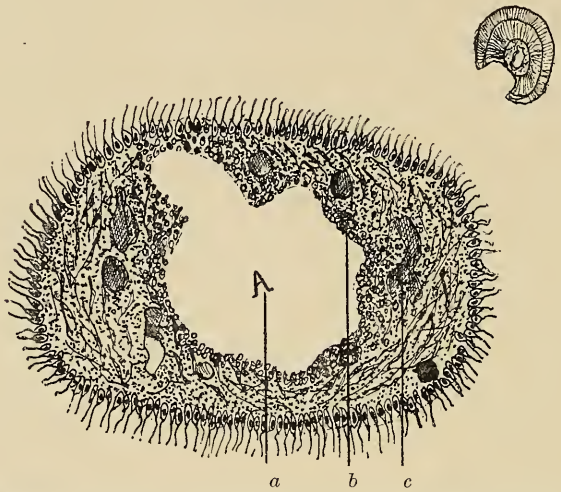

Transverse section of inferior bicuspid pulp, one-half diagrammatic: *a*, abscess cavity; *b*, embryonic cells at the periphery of the abscess cavity; *c*, occluded blood-vessels. (Burchard.)

response. The response to heat is marked, so that a mouthful of hot coffee or even the warmth of the tongue may precipitate an attack of severe and continued pain. Pain produced upon passing from a warm to a cold atmosphere, and *vice versa*, is also symptomatic. If the pulp be freely exposed and pricked with a sharp instrument, a flow of pus follows in many cases, and the relief is almost immediate. In the earlier stages a period of throbbing pain may follow evacuation of the pus.

Fig. 432

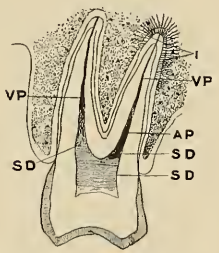

Abscess of the pulp after formation of a large amount of secondary dentin, dividing the pulp into two portions: *S D*, secondary dentin; *V P*, abscess or confined pus; *I*, area of apical inflammation. (Diagrammatic.) (After case in the mouth.)

In other cases the response to heat may decrease until it is almost absent, and the case only be seen when evidences of the action of bacterial products upon the pericementum appear, which they usually do in the later stages of pulp suppuration, when the tooth becomes loose, extruded, and tender upon percussion.

The symptoms of pericemental disturbance may simulate those of incipient, acute, apical abscess, even though a quarter of an inch or more of apical pulp tissue exist in a vital though highly inflamed condition. Upon clinical evidence it is assumed that the inflammation of the pulp produces inflammation of the apical tissue (Fig. 432). In one case the gum and contiguous parts about an upper molar were swollen, apical abscess diagnosticated, and a free flow of pus followed by blood obtained upon opening the crown. An examination made twenty-four hours later, after symptoms had subsided, demonstrated all three pulp filaments to be alive when a *post hoc* diagnosis of extensive abscess of the pulp was made. If untreated, symptoms of pulp and pericemental disturbance may disappear for weeks or months; but if the parts be not perfectly sterilized and reinfection prevented, it is only a question of time when septic pericementitis will arise.

Diagnosis.—The most valuable diagnostic symptom is the peculiar reaction to thermal stimuli—the decreasing, then absent response to cold, and the increasing reaction to applications of heat. This reaction, together with the continued gnawing and full sensation in the tooth, usually affords a diagnosis which is confirmed by evacuating pus from the pulp, which exudes usually as a minute bead followed by blood, although the reverse order may obtain.

In cases where several teeth are involved in the diagnosis, differentiation is made by isolation of each tooth by means of a small square of rubber dam. The thermal test is then applied. The presence of a quantity of secondary dentin will confuse by causing dulness of response. In such case the electric test should be resorted to. (See Dry Gangrene.) In some cases secondary dentin will have formed in the pulp cavity and the abscess may be found in one of the filaments, while the other will be apparently healthy. Fig. 432 is a diagram of a number of cases seen in practice.

Prognosis.—General experience regards ulceration and abscess of the pulp as precursors of the death of the organ. Usually this is by progressive suppuration. It is undoubtedly true, however, that attempts at circumvallation of the dead tissue are made in some cases (Fig. 433). The pus cells undergo degeneration and the abscess site may be the seat of calcareous deposits. Even in these cases death is delayed, not averted. The remainder of the pulp undergoes atrophic changes, and commonly suppuration reappears.

Treatment.—The treatment of the case consists in relieving the existing pain, completing the devitalization of the pulp, and removing it in such a manner that no organisms or dead matter are carried beyond the apex of the root.

To secure relief, evacuation of the pus is imperatively necessary. The organ is freely exposed, exercising no pressure in gaining free access to it. If pus does not flow upon exposure of the surface of

FIG. 433

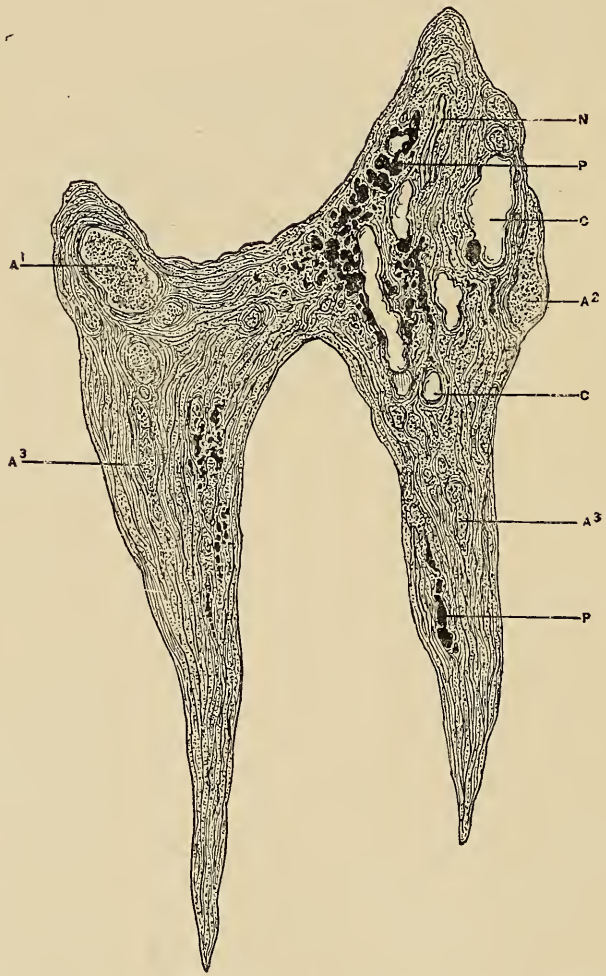

Chronic suppurative pulpitis terminating in calcification of the pus and atrophy of the pulp: A^1, larger abscess, filled with calcified pus; A^2, abscess at the periphery of the pulp; A^3, A^3, small longitudinal abscesses, all calcified; *N*, calcified nerve bundle; *C*, *C*, calcareous depositions in the fibrous pulp tissue; *P*, *P*, pigment clusters from previous hemorrhage. × 10. (Bödecker.)

the pulp, a sharp, slender, sterilized probe is quickly passed into the substance of the pulp, when, if pus be present, it will usually escape freely through the opening thus made and be followed by blood.

If the pus formation be limited and circumscribed, throbbing pain may follow, which a sedative promptly quiets. The application is not made until the pus flow ceases. A pellet of cotton wet with a 1 per cent. solution of formalin, or a saturated solution of thymol in alcohol or other antiseptic sedative, is laid upon the pulp and the cavity is sealed for twenty-four hours (never longer), and then the pulp is removed. Should the exposed portion of the pulp be insensitive it is cut away until access is had to the vital portion, where the arsenic is to be applied. The pulp may sometimes be anesthetized by cocain for removal. The rubber dam need not necessarily be applied for the treatment preliminary to devitalization, but the pulp should be kept under the influence of antiseptics. (See p. 515, etc.)

CHRONIC INFLAMMATION OF THE PULP.

In cases in which the resistive force of the pulp is great and the causes of less violent nature or less violent in action, the inflammation may be of low grade and continue for some time. Pulp ulceration may pursue a chronic course, as has already been described. Abscess of the pulp may also become chronic, and the pulp may even encapsule the pus area, and, the bacteria dying, the abscess area may become the seat of calcareous deposits.

FIG. 434



Chronic inflammation of the pulp, areolation, and degeneration (Black.)

Sclerosis of the Pulp.—Inflammation of a low grade may persist in the pulp for long periods, giving rise to an increase of its fibrous tissue with atrophy of the cellular elements, producing a condition found in chronic interstitial inflammation in some other tissues—a sclerosis. Instead of the usual distribution of myxomatous tissue, bands and bundles of fibrous tissue appear. The pulp appears shrunken and stiff, bloodvessels are contracted and sclerotic, and the nerve fibres have undergone partial or complete atrophy and degeneration (Figs. 434 and 435).

Fig. 435

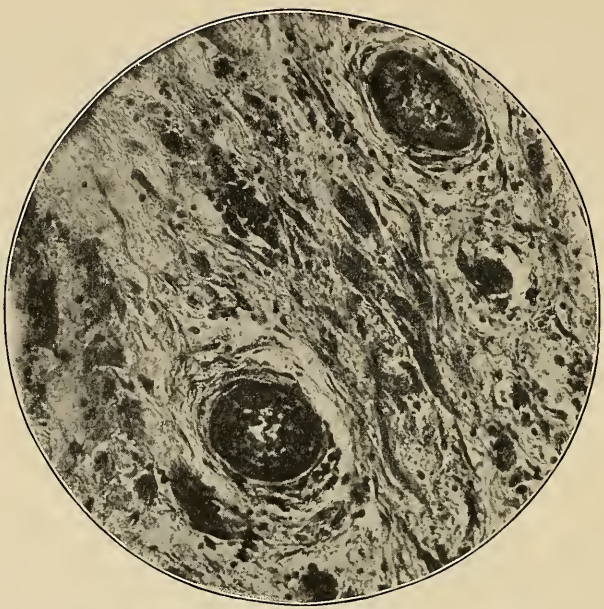

Pulpitis arteriosclerosis; nerve degeneration. (V. A. Latham.)

Fig. 436

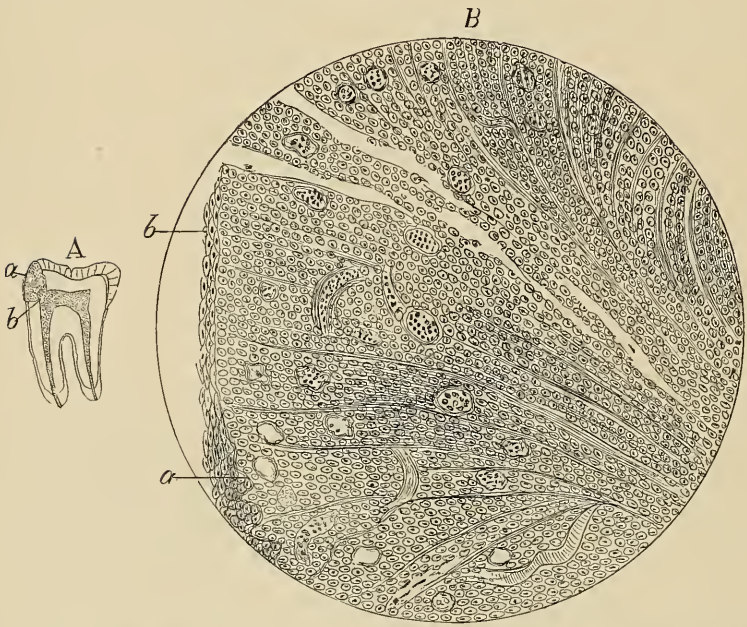

A, a first lower molar with a cavity at *a* completely filled by an hypertrophy of the pulp, which has grown out through the orifice, exposing the pulp at *b*. *B*, a field illustrating the tissue of the growth, which is composed almost entirely of granulation tissue of a very primitive type; *a*, a covering of epithelium presenting papillæ; *b*, epithelium apparently without papillæ. (Black.)

Black found that in the late stages of sclerotic atrophy areolæ developed in the bundles of connective tissue, the inflammatory elements having disappeared and the areolæ being occupied by fluid. Arkövy describes the condition as reticular atrophy of the pulp (Fig. 434).

Sclerotic and other chronic degenerations of the pulp usually present the history of one or more attacks of pulpitis in the past, with more or less continuous uneasiness extending over a long period. The response of the pulp to all tests becomes diminished and dull.

Treatment.—Such pulps are to be devitalized and removed.

Chronic Hyperplastic (Hypertrophic) Pulpitis.—When the pulp is exposed over a wide area, long-continued chronic inflammation may lead to an enlargement of the organ with a protrusion of an altered pulp mass through the orifice of exposure, producing the condition known clinically as fungous pulp. When the growth extends beyond the boundaries of the orifice and then increases in bulk it forms a pedunculated mass to which the term polypus of the pulp has been applied.

Morbid Anatomy and Pathology.—The growth has its origin in a chronic inflammation of the body of the pulp; the organ swells, and contact with the sharp edges of the orifice of exposure excites a continued irritation, leading to further proliferation of the cells of the inflamed part, so that a large mass of embryonic tissue is formed (Fig. 436), termed by Black granulation tissue of a low type. As in the granulation tissue of repair, bloodvessels grow into this mass, so that it may bleed at a slight touch. Black noted in his case illustrated, a covering of squamous epithelium upon the periphery of the growth, which might be interpreted as the transformation of mesoblastic into epiblastic tissue, but the correct explanation beyond doubt is that advanced by the same author, that the epithelium is transplanted from the gums, and grows after the manner of a skin graft. The growth does not contain nerves. The cavity in which it lies is often fairly free from decalcified dentin, the walls appearing as though subjected to an absorbent action.

These growths may undergo further changes; higher organization of the granulation tissue occurs and fibrous tissue is formed; the cells may undergo degenerations, first granular, then fatty, and suppuration and gangrene may occur. Tomes[1] records a case where calcification of an hypertrophied section of a pulp occurred; but as the case was due to traumatism (fracture of a tooth), different vital conditions existed from those in the cases under discussion. Actual

[1] Dental Surgery, third edition.

calcification of the mass is scarcely possible, although calcareous degeneration may occur within the fungous mass (Fig. 437, *G*).

While the growth occupies a cavity of decay, it seems at times to have acted upon the carious dentin so as to remove it by absorption, leaving the cavity more or less clean.

FIG. 437

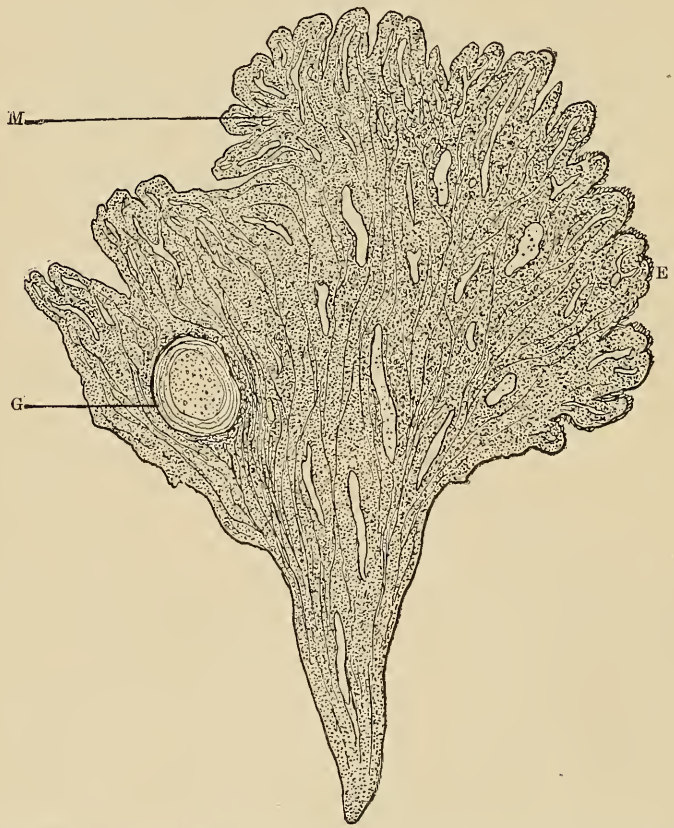

Hyperplastic myxomatous pulp, which filled a carious cavity: *M*, lobules made up of papillæ of a myxomatous structure, rich in capillary and venous bloodvessels; *G*, calcareous globule; *E*, epithelial cover of papillæ. × 10. (Bödecker.)

Resorption of the walls of the pulp chamber may occur as an accompaniment of chronic pulpitis. What appears to be an idiopathic dentin resorption is described on p. 487. Black records a case where, after pulp capping in a lower molar and the insertion of a large gold filling, the tooth was examined at the end of ten years; for two or three years the pulp had given evidences of irritability, and when the pulp was removed the pulp chamber was found enor-

mously enlarged and opening into the pericementum between the roots of the teeth. Fig. 438 exhibits resorption of previously formed secondary dentin with the probable agency through which the

Fig. 438

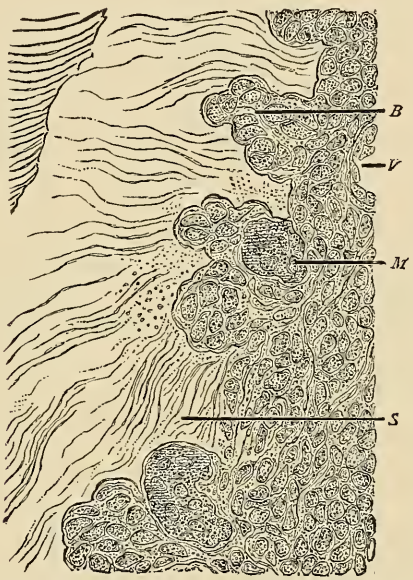

Acute pulpitis: *S*, secondary dentin; *B*, bay-like excavations filled with medullary or inflammatory corpuscles; *V*, transverse section of a bloodvessel; *M*, multinuclear body. × 300. (Bödecker.)

resorption is brought about. The area of resorption is invaded by numerous multinucleated cells, which are evidently performing the function of odontoblasts.

Fig. 439 Fig. 440 Fig. 441 Fig. 442

Hypertrophy of pulps. (Garreston.)

As shown by Miller, Hopewell-Smith, and others, a reconstructive change may occur and adventitious dentin be redeposited in the area of resorption (Fig. 422).

Symptoms.—The symptoms of chronic pulp inflammations and degenerations are usually those of long-continued discomfort, with

reflex pains, which rarely persist into the latest stages of degeneration. The response to heat and cold, present at first, declines until the pulp scarcely reacts, and then but slowly.

No nerve fibres develop in the hypertrophic pulp tissue, so that the newgrowth has no sensitivity in itself. although pressure upon it may cause sharp pain through the still vital pulp nerves themselves.

Four or five of these hypertrophies may exist in a mouth, filling whole cavities of decay, the surrounding tooth structure being in various stages of disintegration. They seem to be comparatively insensitive to mastication (Fig. 440).

Fig. 443

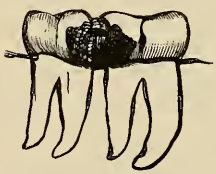

Hypertrophy of the gum. (Garretson.)

Fig. 444

Hypertrophy of the pericementum. (Garretson.)

Hypertrophy of the pulp also may be associated with pulp ulceration, the growth arising from one canal of a tooth.

Regeneration of an extirpated pulp has been claimed. These are probably referable to the above form of hypertrophy, or to a fungoid growth from the pericementum or supposed extirpation under cocaine.

Diagnosis.—The only condition with which hypertrophic pulp may be confounded is a pedunculated growth of gum tissue through a cavity at the neck of a tooth beneath the gum margin, or through a perforation either accidental or by caries (Fig. 444). It is important to differentiate between these conditions, because, if an application of arsenical paste be made to a fungous gum, the destruction of tissue may extend into the sound pericementum. The physical appearances of the two are alike; they both bleed freely and have about the same degree of sensitivity.

Histological examination of this class of hypertrophy of the gums, conducted by Dr. Luigi Ancone,[1] of Italy, demonstrated that the growth is a simple exaggeration of the normal elements of the part.

If the tumor be central to the tooth tissue and the latter not decayed out to very thin walls, it may be at times laid aside by means of a blunt instrument and be seen to have its origin from an orifice of exposure (Fig. 439). As a rule, a hyperplastic pericementum will

[1] Abstract from l'Odontologia, by Dr. W. Dunn, in International Dental Journal, 1899.

be found to have its attachment much lower or more lateral than a hyperplastic pulp, and the pulp cavity be seen to have been enlarged by caries, even more than shown in Fig. 362. It is then fairly inferred to be a gum mass, especially if the tooth has never been operated upon. The diagnosis may be a doubtful one, in which case the rubber dam is to be applied, the polypus frozen by means of a spray of ethyl or methyl chlorid, and the mass removed with a sharp blade passed across its peduncle. The electric cautery may be used to ablate the mass.

The source of the tumor may then be usually clearly seen. As an alternative proceeding the tissue may be thoroughly saturated with a strong solution of trichloracetic acid and then ablated. If any further doubt exist, the pulp is to be sterilized with hydrogen dioxid, etc., and a pellet of cotton saturated with oil of cloves, carbolic acid, or dental tincture of iodin is laid upon it, and over this temporary stopping is firmly packed. By this means the growth may be pressed away until it is seen to arise from either a pulp chamber or a perforation made by decay or accidental excavation into the pericemental tract.

Pressure anesthesia may be resorted to partly as a diagnostic measure. In such case no danger exists beyond the possible forcing of cocain into the gum tissue. Nervocidin should be useful in cases of doubt. Skiagraphy should afford a diagnosis. Hemorrhage may be checked with alum and thymol in powder or solution, or by the use of trichloracetic acid, silver nitrate, zinc chlorid, or iodin.

Treatment.—If the case be one of pulp hypertrophy, arsenic may be applied or pressure anesthesia attempted for pulp removal.

Crystals of iodin have been used with satisfaction in combination with pressure for pulp devitalization.[1] If a perforation exist, it is to be treated by sealing the orifice with gutta-percha, copper amalgam, or oxyphosphate of copper cement. (See p. 561.)

Infarction of the Pulp.—The production of infarction may result as described under Fibroid Degeneration, and as described consists of minute circumscribed hemorrhages from end arteries into the pulp tissue. This differs somewhat from a true infarction. (See p. 119, and Fig. 445.)

Fibroid Degeneration of the Pulp.—Apart from the degenerations due to inflammatory conditions, a form of degeneration occurs "as a natural old-age termination of the life of a healthy pulp, and similar to senile changes occurring in the pericementum." (See Fibroid Degeneration of Pericementum). This change, as described by

[1] Truman.

Hopewell-Smith,[1] occurs in teeth of the aged in whose mouths simple alveolar resorption has occurred, though later he[2] has shown that it may occur in the pulps of young persons, in sound teeth extracted for irregularity, and even in teeth in which the dentinal wall or pulp cavity is not completed to a typical calcification. He regards it

FIG. 445

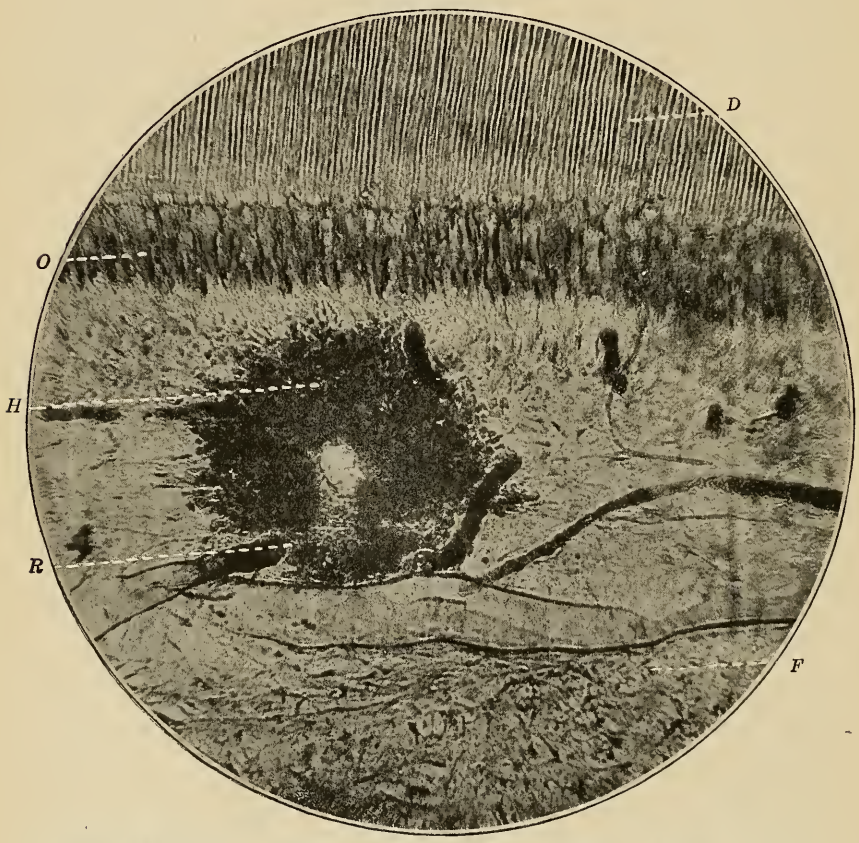

H, hemorrhagic infarct; *R*, rupture of bloodvessel; *D*, dentin; *O*, vacuolated odontoblasts; *F*, early fibrosis of pulp. × 250. (Hopewell-Smith.)

as due to a primary thrombosis of the capillaries and veins, with permanent dilatation of the arteries, with or without tiny hemorrhages, the lack of collateral circulation and lymphatics contributing to the atrophy. As a cause he suggests chemical change in the blood through systemic derangement, as anemia, chlorosis, or exhaustive diseases, the red corpuscles being fewer and the

[1] Histology and Pathohistology of the Teeth. [2] Dental Cosmos, 1907.

leukocytes and blood platelets increased, thus favoring a thrombosis of small vessels; also, that here inflammatory changes in the peri-

FIG. 446

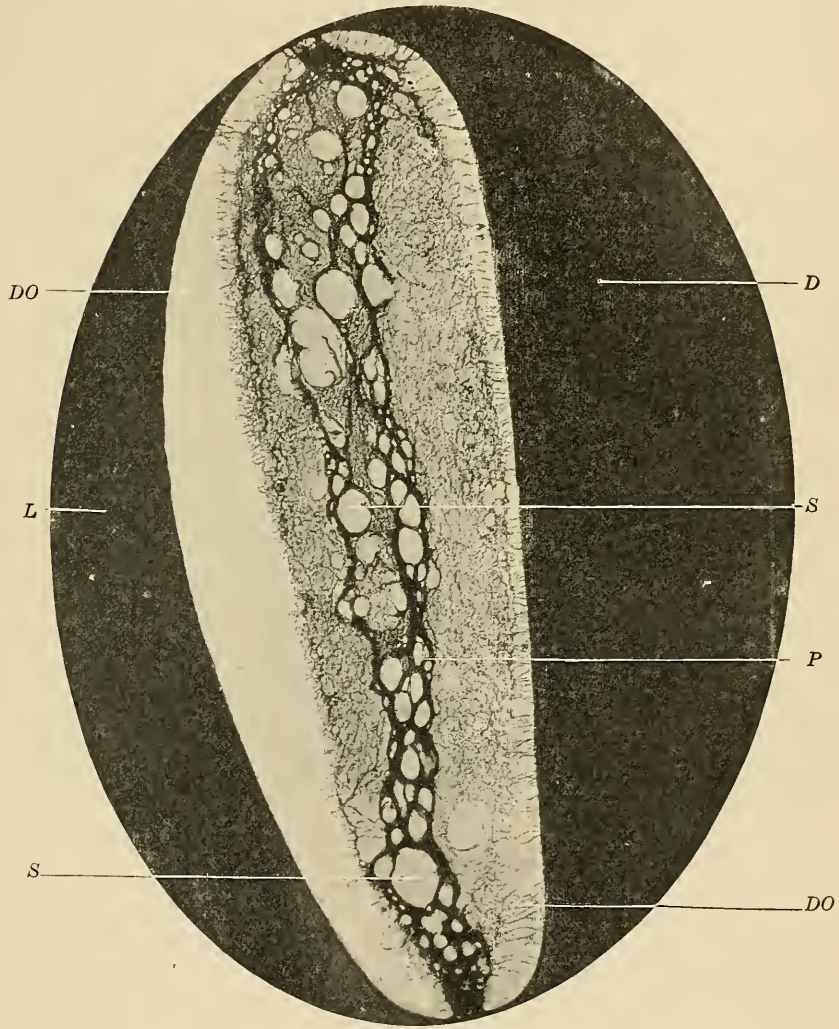

Horizontal section of fibroid degeneration of the pulp *in situ*. Prepared by Mr. Hopewell-Smith's process: *D*, deeply stained dentin; *S*, large areollar spaces; *DO*, degenerate odontoblasts; *P*, fibroid tissue of pulp. × 45. (Hopewel-Smith.)

cemental tissue might interfere with the pulp circulation sufficiently to produce it.

Clinical Significance.—While the form of thrombosis or fibrosis may not be diagnosticated because of lack of related symptoms, Hopewell-Smith argues that they should be suspected in weak and unhealthy patients, and that such suspicion should contra-indicate conservative operations, also that they may explain certain difficulties of devitalization or anesthetization of the pulp or cause a related change in the pericementum or brittleness in the dentin.

Fig. 447

Fibroid degeneration of the pulp: *D*, dentin with tubules; *FO*, fibroid odontoblasts; *P*, atrophied pulp tissue.

Morbid Anatomy.—"The odontoblasts become sheaved with or without fatty degeneration; the arteries, permanently distended, undergo hyaline degeneration; a reticular atrophy occurs, with disappearance of cells and nuclei of both pulp and vessels and nerves, and, at the same time, the connective-tissue fibres undergo hyperplasia. The pulp goes more or less gradually through the stages shown in Fig. 445, finally producing the stage shown in Figs. 446 and 447, in which the pulps are shrunken and may have left the wall of the pulp chamber. "Many areolar spaces appear which may be arranged in chains. The odontoblasts are degenerated. The pulp

stroma is very dense, has a clear, fibrous structure, becomes very marked in staining, and is highly differentiated from the surrounding tissue. The bloodvessels, nerves, cells, and connective-tissue have all disappeared, and their place is taken by a new, firm, fibrous structure devoid of cells, nuclei, or any regular arrangement of constituent parts."

FIG. 448

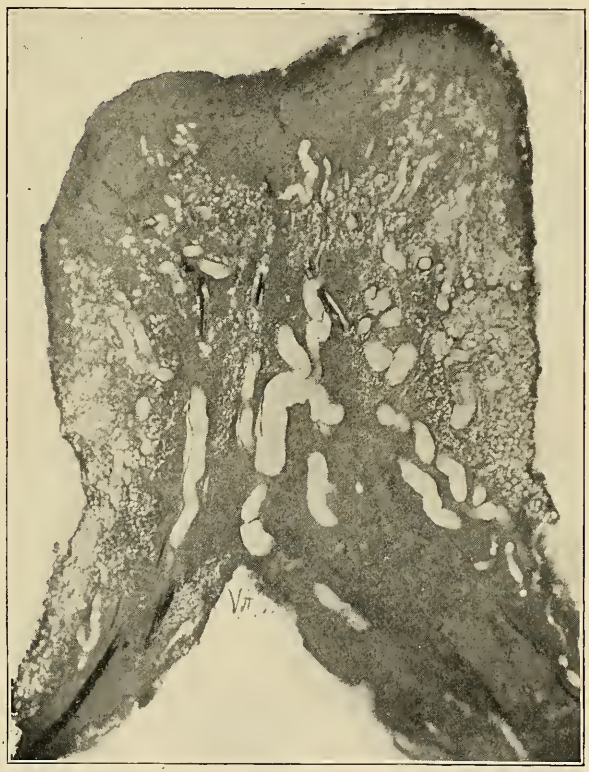

Fatty degeneration of the pulp. (V. A. Latham.)

"There is no calcification of the pulp and no obliteration of the dentinal tubules.

"The proximate cause and associate phenomena are not as yet clearly related."

Fatty Degeneration of the Pulp.—During the course of degeneration of the elements of the pulp fatty changes may occur as in other parts. The fatty changes occur in the walls of the arteries and sheaths of the nerves, and in the odontoblasts. (Hopewell-Smith.)

Cloudy swelling also appears. (Latham.) (See Fig. 512.)

Fig. 449

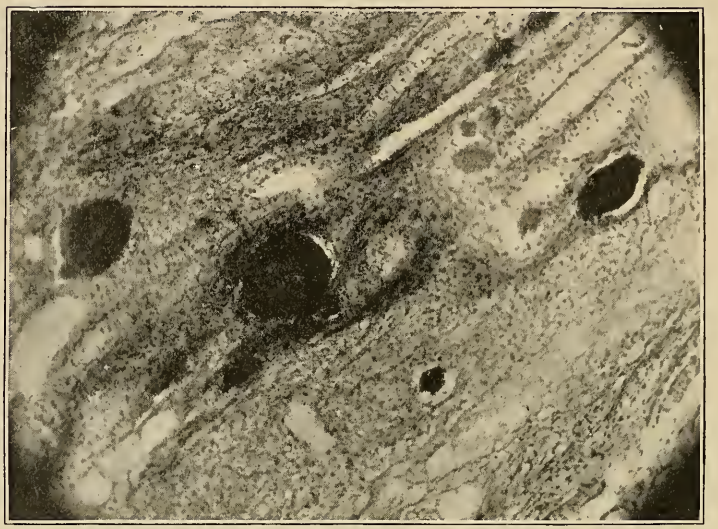

Cloudy swelling; parenchymatous degeneration; pulp nodules. (V. A. Latham.[1])

Fig. 450

Colloid degeneration of the pulp. Compare with Fig. 49. (V. A. Latham.)

[1] Dr. Vida A. Latham's illustrations are from her paper on Some Pathological Features of the Pulp, Journal of the American Medical Association, September 22, 1906.

FIG. 451

Great thickening of nerve bundle. From a case of chronic neuralgia. Patient had many teeth extracted for neuritis. (V. A. Latham.)

FIG. 452

Neoplasm of the pulp. (V. A. Latham.)

Colloid Degeneration of the Pulp.—The demonstration of colloid material within the pulp has been made by Latham, as shown in Fig. 450. She states that it may become calcified. The condition is very rare. Other degenerations such as Wallerian, hyaline, and amyloid have been noted.[1] It would seem that the pulp may be subject to any form of degeneration seen elsewhere.

Nerve-end Degeneration of the Pulp.—The degeneration of nerves occurs in the pulp as it may in the pericementum and from the same causes that produce endarteritis. The bundles may be enlarged. Neuralgia may be associated with it.

Neoplasm of the Pulp.—Latham claims that a neoplasm may occur in the pulp, and offers the photomicrograph shown in Fig. 452 as proof of the fact. I do not know of any cases in which such a pulp condition has been related with a malignant growth outside of the pulp cavity, though it may not be impossible.

Many of the destructive pulp diseases occur in the pulps of the temporary teeth, and are to be treated in like manner, except as to the use of arsenic, which, being accompanied by greater danger, should, for the most part, be replaced by other methods of pulp removal. This point is discussed at length in the chapter upon Removal of the Pulp.

If the tooth roots be largely resorbed, the pulp may bear capping even when ulceration has occurred. The pulp may die under this capping, when the case is further treated as indicated. (See Chronic Apical Abscess.)

[1] Talbot: Dental Cosmos, 1909, p. 1150.

CHAPTER XVII.

METHODS OF REMOVAL OF THE DENTAL PULP AND ROOT-CANAL FILLING.

THERE are four general methods by which a patient or pulp may be prepared for the operation of pulp extirpation. These are as follows:

1. Anesthetization of the patient and removal of the pulp during the period of anesthesia.

2. Anesthetization of the pulp by cocain or novocain, or in some cases by nervocidin, and the removal of the pulp.

3. Anesthetization of the apical tissue with novocain by the mucous or conductive method and removal of the pulp.

4. Devitalization of the pulp followed by its removal.

1. **General Anesthesia.**—The pulp of a single-rooted tooth may be readily extirpated while the patient is anesthetized by nitrous oxid, nitrous oxid and oxygen, or by somnoform. The instruments should be in readiness, the patient anesthetized, the pulp uncovered by an engine bur, and the pulp extirpated with a barbed broach or Donaldson cleanser.

In cases of multirooted teeth the available anesthetics are ether, which is rarely used for the purpose, and nitrous oxid and oxygen administered by nasal inhalation. The latter is accomplished by means of a special apparatus having a hood covering the nose, or bulbs entering the nostrils. This is designed to prolong the anesthesia by administering nitrous oxid and oxygen. As it is equally applicable to the excavation of cavities of decay and extractions, it is a valuable means for this purpose. (See p. 398.)

The ordinary outfit is, however, of value by enabling the operator to remove the diseased bulb of the pulp of a multirooted tooth, after which and while the patient is conscious other methods of removal of the radicular portions of the pulp may be employed. (See p. 491.)

2. **Anesthesia of the Pulp.**—For this purpose cocain hydrochlorid or novocain are employed. There are three practical methods by which it may be introduced into a pulp:

(*a*) By pressure accomplished by means of raw vulcanite. A strong solution (50 per cent. to saturated solution) of cocain hydrochlorid or novocain is made in water, or preferably in some mild antiseptic

solution which does not cloud on admixture (as Borine) A small piece of amadou (spunk) is saturated with it and laid upon the orifice of exposure. The cavity is filled with the rubber, and upon this is placed a flat-ended plugger or burnisher broad enough to concentrate the force upon the amadou. A broad piece of amadou placed over the rubber is sometimes of assistance in preventing the slipping about of the rubber. Gentle pressure is now made and a slight pain is usually felt. The pressure should be maintained until this passes away, then it is increased little by little until some force is exerted. The rubber and amadou are then removed, the pulp cavity opened, the progress of the anesthesia tested with a fine broach, and the pulp lifted away. Some prefer to place a prepared pellet of cocain or novocain upon the pulp.

For multirooted teeth the pressure should be prolonged, and to prevent return of sensation and hemorrhage while extirpating it is well to instil carbolic acid into the pulp tissue by means of a fine, smooth broach.

In some cases the operation fails because the direction of the pressure has been away from the pulp or because the spunk has slipped from its place. Sometimes the orifice of exposure may be enlarged, but as sensation is discovered a fresh application must be made. In cases with large foramina the application may fail; with the incomplete foramen of moderate size it is more successful.

Sometimes repeated applications fail to effect, though the application is not painful, and at times the pressure is not tolerated at all, owing to the irritability of the pulp, due to continued hyperemia or inflammation. Even six or eight applications have at times failed even when a fair and accessible exposure existed. Sedation for a day or two sometimes permits a successful application. The pressure is sometimes tolerated, yet failure results. This action of cocain corresponds to that in inflamed tissue. Sometimes, even when the spunk enters the pulp tissue, the pulp is still sensitive higher up. In such a case I have often packed devitalizing fiber into the pulp in place of the spunk and without further pain. In cases of cavities without walls to confine the rubber, it is well to enclose the buccal and lingual embrasures with the thumb and forefinger. In very broad occlusal cavities the finger-tip confines the rubber nicely.

When only canal filaments are present, any septic matter present should be removed by syringing repeatedly with an antiseptic solution; then the canals should be thoroughly dried, and the cocain, dissolved in an antiseptic, is carried on a cotton thread into the canals and against the pulp remnant. A small piece of rubber is placed in

one canal and the pressure confined to that canal by means of a plugger which will about fill the canal. The action is then repeated in the other canals. This produces better results than a general pressure over all the canals at once.

If used after arsenic has been applied the results are not usually so good, but sometimes the method is successful. To avoid the introduction of arsenic into apical tissue all sloughing portions should be removed and all arsenic washed out.

When the pulp is not exposed, the application to the dentin over the pulp permits advance, a pocket being created in the dentin with a bur, which aids the further instillation of the cocain; finally, the pulp is exposed and the anesthesia is completed.

Clyde Davis recommends for the purpose of producing the exposure the use of a drop of 1 to 1000 adrenalin chlorid followed by a drop of 37 per cent. formaldehyd, then pressure with raw vulcanite.

Where calcific formations are present they present some difficulty, though with persistence one may be enabled to anesthetize the pulp. Custer recommends 75° to 90° sulphuric acid to aid in loosening the nodule. Cook recommended an application of 10 per cent. sulphuric acid for a few minutes, followed by sodium bicarbonate previous to a reapplication of the pressure anesthesia, as highly effective in aiding penetration of the cocain. Desiccation is always a valuable preliminary, aiding penetration. Claims are made for eucain, or alcohol for producing pulp anesthesia by pressure.

There is a possibility of the introduction of cocain into the general circulation, and some systemic effect may be noted, though often this will be due to the agitation of the patient. Some patients have complained of tingling in the fingers. If syncope be threatened aromatic spirit of ammonia should be administered, the head lowered, the feet elevated, and smelling salts or amyl nitrite applied to the nostrils. It is always well to administer aromatic spirit of ammonia or camphorated validol before using cocain for any purpose.

Hemorrhage following the extirpation of the pulp is sometimes copious. To avoid this, carbolic acid should be instilled into the pulp tissue by means of a smooth broach. A fine Donaldson cleanser may be passed to the apex of the canal and slowly twisted, the operation consuming several minutes. This torsion of the pulp largely limits the hemorrhage. If it occur it should be allowed to check itself, though if desired a trifle of a mixture of powdered alum and powdered thymol may be taken upon cotton wet with phenol-camphor and passed to the end of the canal. Deliquesced zinc chlorid checks hemorrhage promptly; a dilution is less painful.

It is an open question whether canals from which living pulps

have been removed should be filled immediately or not. There is liable to be a secondary hemorrhage, particularly when adrenalin is used with the cocain. Many prefer to fill at once, claiming that surgical pericementitis is the only result. The writer, as a rule, wraps a twist of cotton upon a Swiss broach, dips it into phenol-camphor, then into formocresol, and applies it to the canal. This, as a rule, permits the healing of the parts without much tenderness, and really consumes but little more time in the aggregate. Moreover, the formocresol tends to mummify the fibrils left in the dentinal tubules.

All work should be done under aseptic precautions. Where applicable and not liable to be too painful, the rubber dam should be applied. The writer often uses napkins instead, and relies upon the carbolic acid instilled into the pulp and the formocresol dressing to maintain asepsis. This is repeated if the cavity be douched out.

(*b*) When considerable dentin overlies the pulp, or when a tooth is sound, the most expeditious method of pulp anesthesia is by means of the compound syringe. This consists of a strong metal syringe, the piston of which is actuated by means of levers which multiply the power of the hand. The Myers syringe is one of the best, though several forms are obtainable (see Fig. 375). The syringe nozzle is embedded in a small hole drilled in the dentin by one of two methods: The hole may be made small with parallel sides, as when drilled with a No. $\frac{1}{2}$ bur; the syringe nozzle has then slightly conical sides at the point, intended to jam a fit when introduced with force into the drill pit. In the other method the drill pit is made with a cone-pointed bur or bud bur, and the syringe point is made flat-ended, a form easy to maintain upon the point. A 4 to 10 per cent. novocain solution is sufficient, and all air must be expelled from the syringe. It is wise also to expel all air from the drill pit by a slight pressure while the syringe point is loosely held in the pit. Then a rotary motion under forward pressure embeds the point.

If no leakage occurs the force of the piston drives the anesthetic through the fibrils in the tubules and into the pulp. The pressure must be maintained for about three minutes. The anesthesia is then tested by drilling with a No. $\frac{1}{2}$ bur in the direction of the pulp. If the dentin be sensitive the syringe is to be reapplied. Often the bur sinks into a sensitive pulp without warning by dentinal sensitivity. In such case the syringe is reapplied for a moment, when, as a rule, the anesthesia will be complete. In all cases when testing the drill hole should not be enlarged, as this prevents reapplication. Too much cocain should not be introduced, as it has happened that the area about the apical tissue has been profoundly injected, with,

of course, possibility of systemic complication. This warning applies to the second application rather than the first. Novocain is less dangerous. When desirable, the enamel of a sound tooth which is to be crowned may be ground away until the dentin is reached, or if enamel must be removed in only limited degree, as for a tap upon the lingual side of an incisor or in the fissure of a bicuspid, a "spot" is first made with a dentate bur, then a spear drill is driven through the enamel only just reaching the dentin. The drill hole is then enlarged as widely as permissible, after which the pit is made in the dentin with a No. ½ bur.

The lingual side of upper incisors will permit of sufficiently direct pressure to enable the operator to centre the syringe point, but in many cases in which crowns are indicated the labial side may be used with advantage, especially at the neck when the cementum is exposed. Later, the entrance tap is made in line with the pulp axis. The labial or mesiobuccal side must always be used in the lower teeth, unless a cavity be used, sometimes preferably at the neck, sometimes higher up. In cavities having sufficient dentin over the pulp the pit may be made in the pulpal wall, and if for any reason it is needed the drill pit may begin at the cervical portion of the cavity and extend into the root dentin and parallel with the pulp. The pit must be deeper than the syringe point will penetrate, so that the pressure may force the solution laterally through the tubules, which are at a right angle to the axis of the pulp and the pit. In some cases solutions of antiseptics have been as effective with this instrument as the cocain solution. The experiment may not be successful.

According to Brouardel,[1] of Paris, the effects of cocain are acute and chronic. The former develop usually in ten or fifteen minutes, or even up to three-quarters of an hour after the injection. They are: precordial anxiety, filiform and extra rapid pulse, lividity of the face, coldness in the extremities, and abundant perspiration; rise in temperature, irregular respiration, tingling sensations in the hands, blunted tactile sensibility, excitement, loquacity, weeping, anger or hysterical fits; bilious vomiting with or without diarrhea, anuria, symptomatic epilepsy, followed by motor and sensory paralysis. Death occurs in from two minutes to five hours after administration, though in the chronic cases fatality usually does not result.

Placing the patient in the horizontal position, give inhalations of amyl nitrite, and, if further cardiac stimulation be necessary, hypodermic injections of ether or strychnin.

The chronic poisoning occurs mostly in those addicted to its use.

[1] Dental Cosmos, 1905, p. 1508.

Some develop a tolerance of the drug, withstanding from 30 to 120 grains. Tachycardia and intense psychic disturbances, leading to physical and mental collapse, are observed.

(*c*) The third and least desirable form of cocain anesthesia of the pulp consists of its introduction by the cataphoric current. It has the disadvantage of consuming more time, but may serve when patients are timid. A 10 per cent. solution of cocain hydrochlorid is applied to the pulpal wall of the cavity, the tooth being previously placed under rubber dam. The anode of the cataphoric outfit is applied to the cotton and the cathode placed in the hand or at the cheek.

The dentin may be anesthetized as well. If desired, this method may be used to obtain a pulp exposure and the pressure method employed to complete the operation.

When beginning with an exposed pulp, about fifteen minutes will be required unless hyperemia of the pulp exists, when a longer time will be required. As with the pressure method, there may be occasional failures. It will be noted that there is advantage in time and convenience in the pressure methods. (See p. 403.)

(*d*) The fourth method of producing pressure anesthesia consists in the use of carbolic acid in place of the cocain, or in case of obstinate canal filaments of a solution of cocain in carbolic acid. (See p. 496.)

(*e*) The fifth method of producing pulpal anesthesia is by the application of nervocidin, an alkaloid obtained by D. Dalma from the East Indian plant *gasu-basu*. Arkövy recommended that a portion be applied to the exposed pulp for twenty-four hours, when it may be removed painlessly. Söderberg[1] suggests the addition of a small amount of cocain hydrochlorid to overcome the primary irritating effect of the nervocidin. If dentin be over the pulp, an additional application of twenty-four hours' duration is required to obtain an exposure. (See p. 409.)

Sprays of rapidly vaporizable substances, such as ethyl or methyl chlorid, directed against the exposed pulp, the tooth being isolated under rubber dam, will, in some cases, render the pulp entirely insensitive, although, as a rule, they fail to entirely anesthetize to the apical foramen. The method is painful and not applicable in many cases of highly irritable pulps. (See p. 402.)

3. **Anesthesia of the Conductive Apparatus.**—The third general principle consists in the use of mucous, diploëic or conductive anesthesia to block the transmission through the fifth nerve leading from the part. This has been previously described for hypersensitive

[1] Dental Cosmos, 1901 and 1902.

dentin (see page 407). Claims have been made for a slight sidewise blow struck upon the tooth to paralyze the pulp nerves by a stretching shock.

4. **Devitalization of the Pulp.**—Devitalization of the pulp by the use of arsenic trioxid as a preliminary to its successful removal is the oldest of the methods employed at the present day,[1] and as shown, it still has to be resorted to either from necessity or convenience.

The method has its value in the very teeth in which its use is least objectionable, namely, the posterior teeth. There is no danger of the use of arsenic in teeth having completed roots, or in unresorbed temporary teeth, provided the arsenic be accurately sealed in the cavity so that it does not escape upon the gum. If it does escape it may destroy the gum or pericementum and cause partial necrosis of bone or the complete loss of the tooth together with some bone. The pulp always dies through a process of venous hyperemia induced by the protoplasmic irritant and poison. Some of this is absorbed by the pulp. This hyperemia is progressive from the pulp bulb toward the apex of the root, and there it causes the death of the apical portion of pulp through interference with its nutrition. Sometimes this hyperemia of the pulp extends into the apical tissue, but if the pulp be left *in situ*, necrosis of apical tissue never results, but, on the contrary, the hyperemia becomes resolved after the death of the pulp.

The writer fails to see wherein such a hyperemia differs in consequence from that produced by the surgical removal of a pulp and denominated with favor as surgical pericementitis. In his hands such teeth have given quite as good results as when other methods have been employed. By this it is not meant that there has been no difficulty in devitalizing some pulps, particularly some of those in which repeated applications of cocain under pressure failed to anesthetize, but that when carefully handled and sufficient time for pulp death has been allowed, careful filling of the canal has been successful.

Action of Arsenic upon the Pulp.—Arkövy[2] was the first to point out the details of the action of arsenic upon the dental tissues:

"1. As_2O_3 brought into contact with the tooth pulp acts in the following way: A certain degree of inflammatory hyperemia, total or partial, depending upon the quantity of the agent applied, sets in; the bloodvessels become expanded, and here have a tendency to thrombosis. This latter effect may also be in connection with

[1] Introduced by Spooner in 1836.

[2] Transactions of the International Medical Congress, London, 1881.

embolism of the capillaries, when the agent is quickly taken up into the bloodvessels.

"2. As_2O_3 produces no coagulation of tissue whatever.

"3. It has a specific influence upon the blood corpuscles, combining with the hemoglobin to form a compound of arsen-hemoglobin, and of this chemical process there seems to be evidence in the profuse yellowish tinge of the whole pulp tissue and in the discoloration of blood in several of the bloodvessels.

"4. In nearly every case it is taken up *in substantia* (in form of molecules) into the blood-ways; when there it produces besides the above-mentioned changes, granular detritus of the contents and anemic collapse—shrinkage, the latter effect being brought about nearly exclusively in cases where greater doses were used.

"5. The bulk of the pulp tissue—viz., connective-tissue fibers and odontoblasts—undergoes no change whatever; not so the connective tissue cells, which increase three or four times their normal size.

"6. The special action of arsenic trioxid upon the nerve element consists in the following: the neurilemma is only so far influenced that its nuclei are somewhat increased; a more essential change takes place in the axial part, where, after the application of more than 1 mg., granular destruction of myelin sets in, and the axis-cylinder commences here and there to disappear. A very surprising alteration may be seen in the notchy tumefaction of the axis-cylinder, described heretofore almost only in cases of central lesions.

"7. All these alterations occur in and among normal-looking tissue.

"8. The action of arsenic trioxid is macroscopically exhibited by a brownish-red tinging of the whole or of certain parts of the pulp body, as well as of the neighboring dentin and the cementum, this latter in cases treated with greater doses—viz., 2 to 5 mg. This alteration is most expressed at the top of the crown pulp and at the apical one-fourth to one-third part. This circumstance may be considered as an external evidence of the devitalization being completely attained to."

In some cases the pinkish discoloration of the dentin may be marked; the broken-down corpuscles of the extravasated blood have their coloring matter taken up by the odontoblasts, and being distributed through their protoplasmic processes produce a condition technically known as suffusion. The same result may be an attendant upon injury to the vessels from other causes, producing hyperemia, as when teeth are moved too rapidly in regulating. (See p. 480.)

Miller's experiments[1] upon the tails of mice (made without and

[1] Dental Cosmos, 1894.

with rings at the root of the tail to simulate the surrounding of the apical vessels of a tooth; made without and with encasement of the tails in plaster of Paris to imitate the rigid surroundings of the dental pulp) showed that in the absence of the plaster encasement enormous edema of the tail was produced and a sensory paralysis of the hind limbs; complete anesthesia of the tail occurred in forty-eight hours. "The action of arsenic appeared somewhat accelerated when a glass ring was applied close to the root of the tail. In more than forty cases there was not one in which the action of the arsenic extended beyond the ring, and the action was not appreciably affected by enclosing the tails in plaster casts. The action of the arsenic is of a progressive nature, beginning at the point of application and extending gradually in each direction."

Flagg[1] devitalized ten pulps and removed them, cut off the portion of the bulb of each which had contact with the arsenic, and tested the ten pulps together by Reinsch's test. Arsenic was found, estimated at a one-hundred-thousandth part of a grain, or one-millionth of a grain for each pulp. Allowing for possible mechanical introduction or contact of arsenic during extirpation, the quantity of arsenic introduced by the circulation must be very minute indeed.

Flagg argued that as the pulp subsequently putrefies it cannot have died as the result of arsenical poisoning alone.

In the roots with large foramina arsenic may be absorbed, as areas of devitalization of the apical and overlying gum tissue have been noted. In several apparently authentic cases the pericementum of a mature tooth has been said to be destroyed from the apex down and the tooth lost. I have never seen such a case resulting from the arsenical method alone in either clinical or private practice, although cases of marginal gum, alveolar, and pericemental death, beginning as the result of leakage or application to perforations, have been noted. It is probable that as stasis proceeds the apical portion of the pulp becomes involved in advance of arsenic absorption. Miller's experiments show that arsenic does not pass the point of constriction.

Variations in the Action of Arsenic.—In most cases of fully formed, single-rooted teeth in young adults an application of arsenical paste directly to the exposed pulp will be followed by the complete death of the organ in forty-eight hours. At the expiration of that time a sterilized broach may be passed almost to the apex of the root and the pulp removed *en masse* without pain. Pulps of molars require a longer time, often a week, before the filaments are dead. The finer filaments resist longer than the larger ones. If pulp nodules exist,

[1] Dental Cosmos, 1868.

the action of the arsenic may be delayed or in some cases be almost *nil.* In calcareous and other chronic pulp degenerations the action is also delayed. If arsenical applications are made over a layer of dentin, the same delay is noted, and is increased in very dense teeth. There is also a greater tendency to suffusion.

Some pulp, irrespective of the pulp condition, exhibits a peculiar idiosyncrasy in resisting the action of arsenic, requiring large doses and long applications before succumbing. Second applications often require more time to kill the balance of the pulp than the first application would have required. The time used in investigation is practically lost. The editor, therefore, allows plenty of time; about ten days for molars, five for single-rooted teeth, and prefers to find the pulp entirely dead.

The rational objections to arsenic, aside from its escape upon the gum, are: (1) The possible production of pain. (2) Possible suffusion of the tooth. (3) The time required.

The production of pain may largely be obviated by observance of certain technique. The pulp should ordinarily be exposed and be slightly bled to relieve any hyperemia or inflammatory engorgement present, as this seems to prevent the absorption of the arsenic. A powerful sedative, such as thymol, menthol, cocain hydrochlorid or morphin acetate, should be employed as a corrective, and the menstruum should be sedative rather than coagulant. All pressure on the pulp should be avoided as this produces pain.

Sufficient time for complete death should be allowed, say, from a week to ten days. If, upon examination with a fine smooth broach, vitality be discovered, a sedative should be applied and pulp death awaited. Leaving the dead portion against the vital part of the pulp is even better than making a second application, as its removal relieves the congestion by opening the vessels, and the congestion is necessary to the end in view. If the pulp give but little response upon probing it may be removed. Sometimes the diapedesis of red corpuscles, associated with the venous hyperemia, causes a staining of the pulp and dentinal fibrils with the liberated hemoglobin. This is unfortunate, but can be treated by bleaching with 25 per cent. ethereal pyrozone sealed in the pulp cavity for about twenty-four hours after the pulp is removed. The third objection, the matter of time, does not apply to the cases of prompt devitalization, as the time spent in pulpal anesthesia and checking hemorrhage is in the aggregate no less than in the arsenical cases. In the delayed action of arsenic the objection is valid, but the conductive and general anesthesia methods are still open to trial. The arsenical method, of course, requires a longer period of treatment. Pulpal anesthesia

can be tried when arsenic does not act well, but should be avoided when it originally failed. Mucous, diploëic and conductive anesthesia, or general anesthesia may be used if arsenic fails. As stated, these considerations apply mainly to posterior teeth.

Forms in Which Used.—The following is an excellent formula for arsenical paste:

℞—Arsenici trioxidi . . . . . gr. xv
Cocainæ hydrochloridi. . . . . gr. xx
Thymolis (vel mentholis) . . . . . gr. v
Olei caryophylli . . . . . q. s. ft. pasta—M.

This should be finely ground in a mortar and spread over the bottom of a wide glass jar so that some of the paste may be taken up from the bottom. The arsenic settles to the bottom.

Buckley recommends the following formula:

℞—Arsenic trioxid . . . . . gr. clxxx
Cocain alkaloid . . . . . gr. xxx
Thymol . . . . . gr. xv
Petronal . . . . . ♏xv—M.

Either of the above may have the powdered ingredients mixed. The cotton pellet may be wet with the menstruum and then dipped into the powder. Lamp black added to the paste colors it so that it is easily distinguishable in a cavity.

Prinz has suggested the rational improvement of using a concentrated solution of cocain or novocain before applying arsenic. This renders its primary action less painful, or painless.[1]

The following are other formulæ: The analgesics included are intended to dilute the arsenic and quiet the pulp, and thus both directly and indirectly modify the pain.

℞—Acidi arsenosi,
Morphinæ sulph. . . . . āā gr. x
Acidi carbolici . . . . . q. s. ft. pasta—M.
(J. D. White.)

℞—Acidi arsenosi . . . . . gr. x
Morphinæ acetatis . . . . . gr. xx
Olei caryophylli . . . . . q. s. ft. pasta—M.
(J. Foster Flagg.)

Creosote may be substituted for oil of cloves.

℞—Acidi arsenosi . . . . . gr. x
Cocainæ hydroch. . . . . gr. xx
Olei cinnamomi . . . . . q. s. ft. pasta—M.
(E. C. Kirk.)

℞—Arsenic . . . . . gr. x
Alum . . . . . gr. x
Thymol . . . . . gr. x
Oil of cloves . . . . . q. s. ft. pasta—M.

[1] Dental Materia Medica and Therapeutics.

As the ordinary pastes tend to separate into layers of arsenic, morphin, etc., and menstruum if made thin, they should either be made into stiff pastes or spread over the bottom of a wide jar, so that some arsenic may be scraped off the bottom at each application.

W. H. Truman indorses the opinion of J. D. White that thorough trituration for two hours more finely divides the arsenic and prevents separation, and claims that the use of arsenic triturated with wood creosote and glycerin is the most effective preparation.[1]

Miller offers the following general rules as deductions from his observations:

"1. The rapidity and intensity of the action of arsenous acid depend, under certain circumstances, to a very considerable degree upon the substance or substances with which it is incorporated.

"2. Where there is but a small point of exposure, and in particular where extensive calcification has taken place in the pulp, escharotics should be avoided, since the coagulation of the tissue retards the absorption of the arsenic. This retardation is but slight where there is a broad surface of exposure. In stubborn cases, where applications of the ordinary paste fail to effect the devitalization, a paste consisting of arsenous acid in oil of cloves, glycerin, or salt solution should be employed, undiluted by any third constituent.

"3. Thymol is worthy of a trial as a substitute for morphin, on account of its anesthetic and antiseptic properties.

"4. For devitalizing pulps of temporary teeth or remains of pulp tissue in root canals, arsenous acid, if employed at all, should be diluted with two or three parts of some other constituent (thymol, zinc, oxid, morphin, iodoform)."

Cobalt was introduced by Robert Arthur as a devitalizing agent some forty years ago. Within recent years it has been employed, notably by the Herbst method, to destroy pulps. The cobalt paste of Herbst was analyzed by E. C. Kirk, and found to consist of *metallic* arsenic and cocain hydrochlorid. Kirk suggests that free acids which cocain salts may contain, or the chlorin from the chlorid, may combine with the metallic arsenic and form soluble salts. The use of arsenic pentoxid and soluble arsenates has been suggested by Fette, and for which he claims advantages.[2]

There are some advantages in the so-called devitalizing fiber introduced by J. Foster Flagg. To make this, absorbent cotton is cross-cut with scissors to a fine lint. This is dusted into the paste or ground up with it in the mortar. It may then be dried on a blotter

[1] Dental Brief, June, 1913.

[2] Dental Cosmos, November, 1914.

and be bottled for use. As it lacks long fibers, a small portion may be detached and be placed upon the pulp. There are cases, however, in which the paste should be carried to the exposure upon a probe and gently inducted into a fine exposure. Here its tendency to spread or penetrate is valuable. The fiber has no such tendency, which makes it less dangerous in use. In making the application a minute portion of paste is to be laid upon the pulp, or a pin-head pellet of cotton is rolled in it, the excess of menstruum removed, and it is then applied to the pulp, or a portion of devitalizing fiber is used. This is then sealed in.

The cavity should be prepared for the reception of arsenic, decay being removed as far as practicable, and the cavity dried. Any redundant gum must be pressed away or saturated with trichloracetic acid and ablated.

There are two good methods of sealing the arsenic. In cases not approaching the gum, or where dryness can be maintained, the application may be accurately made and quick-setting cement flowed over it. This cement is capable of being fairly dropped into a cavity or led around the periphery by a probe, and should be very adhesive, also be readily removable. A still safer method consists in applying a pellet of amadou over a part of the pulpal wall. The cement is then introduced about the periphery of the cavity, the amadou being left largely uncovered. When hard, any cement over the amadou is removed and the latter lifted out, thus leaving a box-like receptacle for the arsenic and a pellet of amadou partly wet with eugenol in which menthol is dissolved. When placed, the orifice is dried and more cement added. This method of first making the covering is of special advantage when the cavity cervix is near the gum, and prevents the forcing of arsenic toward the gum in the act of making the covering. Amalgam or facing amalgam[1] or temporary stopping may be used in place of the cement (Fig. 453). Temporary stopping is not very safe against masticatory force.

FIG. 453

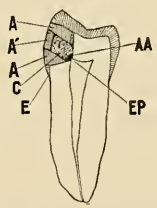

Diagram showing method of first making the covering for an arsenical or sedative application. (See text.) *EP*, exposed pulp; *AA*, arsenical application; *C*, sedative covering to same; *A*, amalgam placed before these applications; *A'*, amalgam to seal them in; *E*, enamel.

The rubber dam is generally insisted upon, but cannot be used in the worst cases, hence an expert may dispense with it. There is a

[1] Facing amalgam is silver 40, tin 55, zinc 5 parts, and mercury.

tendency among students to rely upon the rubber dam alone to prevent accidents. This is a fallacy, as the same results may occur with it as well as without it. The chief danger lies in the use of temporary stopping after placing paste. Capillarity and pressure often carry the paste to the cervical margin. Making the covering first or using fiber constitute the best precautions.

In case of a very dangerous cavity, as a distocervical one, a special drill pit known as a "pocket" is to be made at some other point extending in the direction of the pulp horn and as near to it as can be made without too much infliction of pain. In this the arsenic is to be sealed while antiseptic sedatives are to be placed on cotton in the cavity of decay. This method is also valuable when the pulp is very irritable, and permits devitalization through a more or less healthy portion of pulp.

The presence of pulp nodules may necessitate an application after lifting away the nodule (Fig. 404).

The arsenical method may be used after a preliminary general anesthesia and bulb removal, or may even be used against an obdurate pulp canal filament. When pulp removal is intended the application may be removed through the opening and a probe may be passed into the pulp to test the progress of the devitalization. If needed, a second application may be made or the tooth may be temporarily closed. In case the pulp be found partially dead, it is better to allow more time for complete devitalization than to make a second application, as removing a portion relieves the congestion.

Symptoms.—The large majority of pulps die under arsenic with but little pain. Sometimes throbbing pain results, passing into a heavy fulness as congestion supervenes. If too great, the pulp should be uncovered and bled slightly, then a sedative should be applied, iodin used as a counterirritant upon the gum, and pulp death awaited. Ordinarily the pain passes away as the pulp becomes more fully congested. Apical irritation may result and may be ignored if slight, or if severe be treated in the same way as the pulp irritation (Fig. 412). A guard to prevent overocclusion is sometimes useful (Fig. 549).

Accidents from Arsenical Applications.—If a portion of an arsenical application escape from beneath its covering, it may destroy much or a little gum tissue, according to the amount which escapes. The teeth should be seen early in doubtful cases and the condition of the gum observed.

The arsenic may attack the gum festoon, inducing in it stasis followed by necrosis. The gum assumes a purplish turgidity, which later changes to a dirty yellow slough.

The bone is usually devitalized for a distance.

If the necrosis be self-limited, as is usually the case, a small sequestrum comes away after a few weeks.

In some cases the arsenic may follow the festoon of the gum of one or more teeth, causing disagreeable sloughs and ulcerations. It may follow the pericemental tract, kill the pericementum, and the tooth drops out. In one case of a boy, aged twelve years, an application was made in a first lower molar. A blow from a base-ball was subsequently received and a slight leakage occurred merely a trifling slough of the gum being apparent mesially. Later the living gum margin appeared flabby and could be lifted away. Finally and gradually, during nine months, the buccal pocket deepened without loss of the gum, the tooth gradually loosened, the bone septum between the roots was found necrosed, the tooth was removed, and the socket healed without further necrosis. The alveolar process about one or several teeth may be devitalized and a sequestrum occur which includes the teeth. Certain toothache nostrums are sold which contain arsenic. Dr. G. C. Chance[1] records a case of arsenical necrosis occurring from this source. Dr. J. E. Powers[2] records a case in which extensive necrosis occurred from the use of colored woolen yarn (as a cleanser of interdental spaces) which contained arsenic used in the dye.

From the infirmary of the Philadelphia Dental College was referred to the oral clinic a case of extensive coagulation necrosis, resulting from the rubbing of "toothache drops" upon the gum. Analysis showed the preparation used contained arsenic. Collapse from blood poisoning being the immediate danger, the child was operated upon by Prof. Boenning for drainage of the parts. During the recovery, the teeth from the right lower cuspid to the left lower second temporary molar, and the gums over the process, were lost, leaving a blackened alveolar process, to be later removed surgically (Fig. 454).

Arsenic is liable to pass through the apical foramina of unformed or much resorbed roots. It may possibly pass through mature roots when an application is placed high up in the canal, rarely when applied under normal conditions (as recorded by some), or, as occurred in one case, by the application being pushed through the apex. It may be forced through in the act of broaching, or through the subsequent use of the cataphoric current or pressure anesthesia without the preliminary precaution of removing the arsenic.

In some cases arsenic has been applied to perforations made through the sides of roots under the impression that the vital tissue

[1] Proceedings of the Academy of Stomatology, Philadelphia, 1898.
[2] International Dental Journal, November, 1902.

found was pulp tissue. In such case its necrotic effects will be noted upon the gum overlying the root apex or over the perforation, the tooth being loosened and extruded and may possibly be lost.

E. C. Kirk[1] has recorded several cases of loss of teeth from arsenical necrosis of the pericemental tissue following the use of mummifying paste to pulp stumps previously impregnated with arsenic. His theory is that the arsenic was liberated by the affinity of the ingredients of the mummifying paste for the proteid constituents of the pulp tissue. The editor has often used such pastes after arsenic and without untoward results, and feels that some other element must have entered in Kirk's cases.

Fig. 454

Boenning's case of coagulation necrosis due to arsenic; shows exposed and blackened alveolar process.

Such dangers as these demand that extreme precautions be taken against the careless use of quantities of the agent. The rules laid down should be adhered to.

The only cure of the condition consists in the thorough removal of every particle of the arsenic. Any projecting masses of edematous gum should be cut away, as they are dead and will slough at any rate, and a freer access to deep parts is had—the blood-flow may itself wash away the arsenic. The forcible washing should be prolonged and repeated, or 10 per cent. silver nitrate should be used to form arsenite. Dialyzed iron or tincture of iodin might be applied with a view to possible neutralization of the arsenic.

The editor, in a case of known application of arsenic to an obscure

[1] Dental Cosmos, October, 1903.

perforation, succeeded in causing regeneration of tissue by removing surgically the dead tissue and inviting repair.

It may, therefore, be that after minute portions of arsenic, forced through foramina, exert their full effect, the resulting dead tissue may be removed by resorption or even exfoliation; indeed, this result has been noted in which no other explanation seemed possible.

If the teeth are loosened and lost as the result of arsenical necrosis, either beginning at the gum margin or at the apical space, the alveolus will exhibit a bare periphery and even some odor of putrefaction may be present. The alveolus should be sterilized and the walls burred away to a tissue capable of healthy granulation.

If suffusion occur, essential oils or phenol should be avoided in the subsequent treatment, as they tend to set the color by acting as a mordant (Kirk), rendering bleaching difficult. After the pulp is removed it is well to fill the apical portion of the canal, and then at once bleach with 25 per cent. ethereal pyrozone, after which the balance of the canal and the cavity may be filled. (See Moist Gangrene of the Pulp, p. 580.)

Special Methods of Preparing Pulps for Removal.—A fully exposed pulp in a single-rooted tooth or single root of a multirooted tooth, may be suddenly "knocked out" by means of a delicately pointed orange-wood stick or Portuguese toothpick. The point is dipped in carbolic acid and suddenly and boldly driven into the pulp, either by hand or mallet force. The method is not so agreeably delicate as pressure anesthesia, but is effective. It must not be used in partial exposure, as, not reaching the apex, it may cause pain. Its use is only indicated in emergency or occasionally in crown work after excision of the crown by excising forceps.

A vital remnant of pulp may be removed after instilling a strong cocain solution, or carbolic acid, or a paste of carbolic acid and acetate of morphin, into its substance by means of a "puncture probe." This instrument may be made by filing down a Donaldson bristle to a fine point, which is further whetted on an oil stone. The sides of the probe are polished by folding a cuttle-fish disk upon itself, holding it between the thumb and forefinger of the left hand, and drawing the probe through it. The pulp canal is flooded with the carbolic acid, and gentle thrusts are made into the pulp until the probe is stopped at the apex. If it pass through, that must be judged by the sense of touch. Custer recommends 75 to 90 per cent. sulphuric acid as superior to carbolic acid. At times a small end of pulp filament may be seared with a hot Evans' root drier, which is quickly thrust into it. This does not necessarily give much pain.

A slow but effective method of disposing of these filaments, when

hyperirritable or when patients are timid, consists in packing a cotton twist saturated with carbolic acid containing cocain hydrochlorate in solution into contact with the pulp, and then gently compressing the pulp. The cotton is to be left in position for a day or two, when, as a rule, the pulp may be removed. It induces thrombosis, and carbolic acid may be used with pressure to produce anesthesia at the time of operation. A dressing of tincture of iodin has been suggested for the purpose.

Devitalization of Pulps in Temporary Teeth.—All of the anesthetic measures are as applicable to temporary teeth as to the permanent ones if the little patient will tolerate their application.

If the child present an exposed pulp in a tooth the roots of which are not resorbed, arsenic much diluted, may be applied for twenty-four hours and then be removed, the pulp being then allowed to die. When roots are resorbed it is better to cap the pulp with Jodo-Formagen cement, or if necessary, apply a pellet of cotton wet with phenol, then touched to iodoform, and seal in with temporary stopping, making a slight pressure. This may remain a week or more and be renewed if necessary.

Darby has used cantharides, $\frac{1}{20}$ grain in carbolic acid, with success. It must be carefully sealed, as strangury is a possibility.[1] Figs. 146 and 116 are guides as to the condition of the end of the root.

THE EXTIRPATION OF THE PULP.

After the pulp is prepared for removal or the patient is anesthetized, free access to all parts of the pulp cavity and canals must be obtained. This is usually best accomplished by an opening made in direct line with the axis of the pulp canal. In general terms this involves for sound teeth an opening upon the lingual surface of incisors and cuspids and upon the occlusal surface of bicuspids and molars.

This access may consist of a new opening or an extension of a cavity, or at times the cavity and canal may simply be made continuous.

When a cavity of decay exists the pulpal wall should be perforated and a large bud bur should be used to cut away the dentin overhanging the pulp cavity. It is usually necessary to extend the cavity in the central occlusal direction, so as to permit direct access to each canal (Figs. 455 to 462).

When a tooth crown would be irremediably weakened by such a

[1] Dr. J. Foster Flagg had such a case.

course, a slight indirectness is permissible when flexible cleansers can be used instead of drills. This leaving of tooth structure should be done with judgment. The canals must be cleansed. In cavity approaches the *outer* wall of the pulp cavity should be cut away to permit an obtuse-angled approach rather than a right-angled one (Figs. 460 and 462, *A*). All pulp cavity corners should be burred to a shape that obviates retention of pulp debris, the subsequent decomposition of which would lead to discoloration. The opening shown in Fig. 458 is faulty for this reason, and is better if extended more toward the incisal edge, making an oblong opening with rounded ends.

Fig. 455 Fig. 456 Fig. 457 Fig. 458

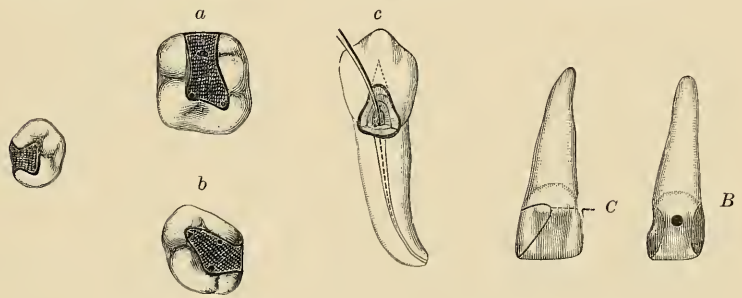

Fig. 459 Fig. 460 Fig. 461 Fig. 462

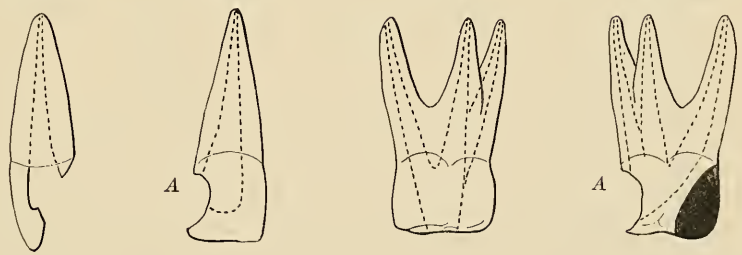

In sound teeth the entrance to the canal is made with a small spear drill, after the enamel has had a "spot" made in its surface with a sharp dentate bur. This centres the spear drill and prevents its slipping about. After it has entered the pulp cavity dentate burs are used to enlarge the opening to the desired size and shape. A sawing motion creates more rapid clearance and cutting of tooth tissue.

One should not always suppose that the spear drill will drop into an appreciable pulp cavity. The careless driving of a drill into a

tooth may cause a perforation. Secondary dentin or a large nodule, and, in previously treated teeth, zinc phosphate may occupy the pulp chamber. Therefore, when doubt arises, open well that portion of tooth or filling which has been drilled through, and note the conditions, then go ahead carefully. In opening a located pulp chamber with burs a bud bur is very useful, but all burs once placed through the drill hole and into the pulp chamber must be used laterally or the heel of the bur used with an outward sweep toward the occlusal aspect for the sake of safety.

FIG. 463

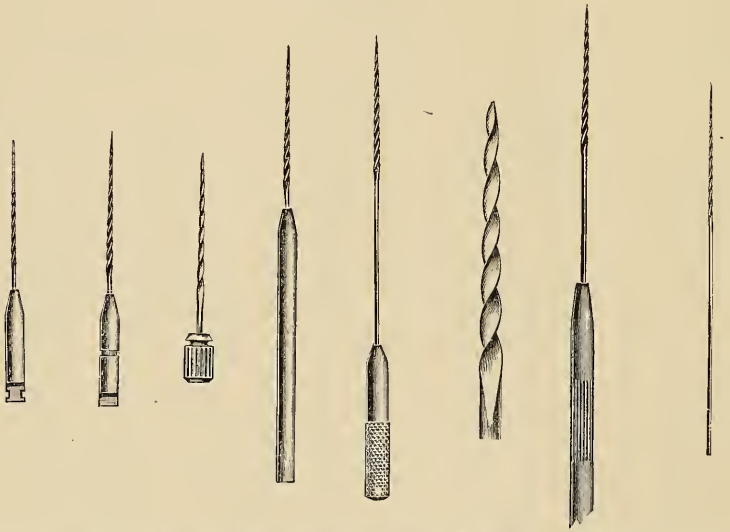

Kerr or Downie broaches. Various finer sizes of these broaches and reamers may be had. They should have accurate taper.

The canal (or canals) is now to be explored, and if of operable size a Donaldson cleanser or barbed broach is passed to the canal apex, twisted so as to engage its teeth with the pulp substance, and the pulp extirpated.

If there be any difficulty in finding the canals after this preparation, by reason of the broach catching on the edge of the orifice, the mouth of the canal should be made continuous with the wall of the pulp chamber by means of a small bud bur. The wall then leads the broach into the root lumen.

In single-rooted teeth with finer apices a fine Kerr engine root reamer (Fig. 463) may be passed by hand to the apical portion of the root and gently rotated. It is then mounted in the hand piece, passed gently to the apex, slightly withdrawn, and then operated by

engine power. It is pressed lightly laterally to enlarge the canal slightly. The next larger size is then used in like manner, and finally the larger admissible sizes. This gives a beautifully tapered canal form useful in canal filling and for the adaptation of dowels. The pulp is simultaneously removed, generally being churned out

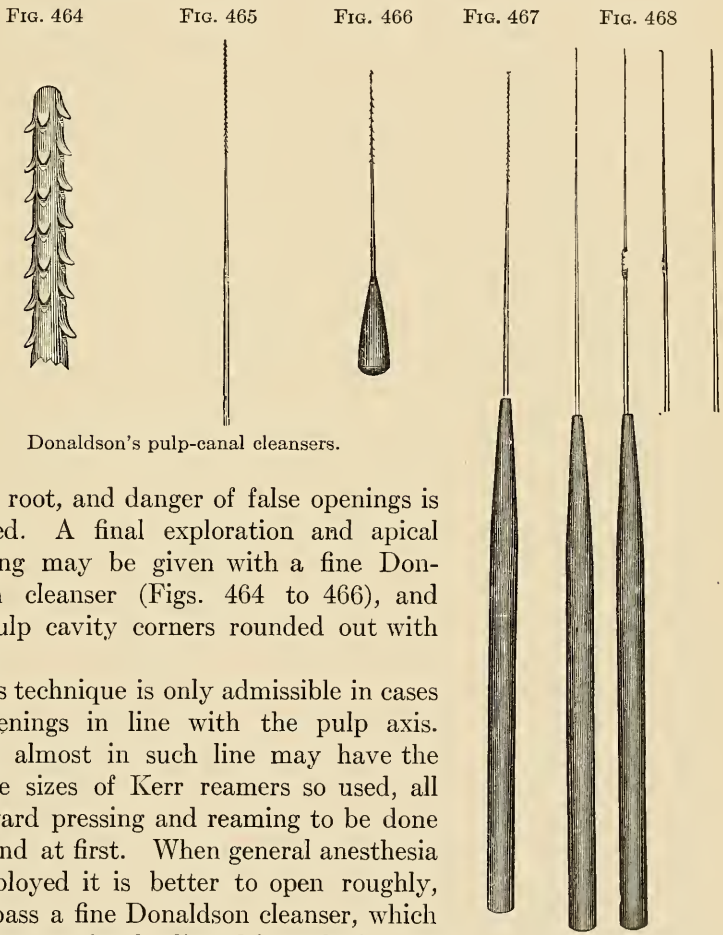

Donaldson's pulp-canal cleansers.

of the root, and danger of false openings is avoided. A final exploration and apical scraping may be given with a fine Donaldson cleanser (Figs. 464 to 466), and the pulp cavity corners rounded out with burs.

This technique is only admissible in cases of openings in line with the pulp axis. Those almost in such line may have the flexible sizes of Kerr reamers so used, all apexward pressing and reaming to be done by hand at first. When general anesthesia is employed it is better to open roughly, then pass a fine Donaldson cleanser, which has been previously dipped in carbolic acid and laid aside in readiness, to the apex of the root canal. It is given a few turns to engage the pulp, and the latter is lifted away. The other work is to be done upon return to consciousness.

Donaldson's spring-tempered nerve bristles.

As the Kerr broaches and reamers are made of a variety of forms, it should be stated that only those which have a gradual taper from point to shank can be relied upon to satisfactorily carry out this

technique. In these the successive sizes follow one another without danger of perforation of the canal walls.

It is sometimes better to drive a fine hand Kerr broach to the canal apex, and, if the engine broach be not permissible, to continue with the different sizes of hand broaches. One soon obtains a familiarity with the canal curve and size when working with the hand which gives confidence and safety when later working with engine power.

In molar teeth and upper first bicuspids, after the pulp chamber has been prepared, the canals are to be located with a fine smooth broach or a Kerr broach. The finest root reamer is then used by hand and gently twisted and forced apexward into each canal in turn. The next smaller is then used. As these canals are normally somewhat curved, only flexible forms should be used unless the larger size follows readily the rather curved canal made by the previous one. Following this, Donaldson cleansers are operated by hand to scrape the sides and inequalities of the somewhat flattened canals which the reamers have not reached.

In place of drills the process of canal enlargement devised by Callahan[1] may be employed. The general cavity wall is varnished to prevent the action of the acid upon the dentin, and by means of a pair of Flagg's dressing pliers or a minim dropper a drop of sulphuric acid (50 per cent. solution) is deposited at the mouth of the canal to be operated upon. The finest size of Donalson's canal cleanser is then passed into the canal as far as it will go, using a pumping movement to carry the acid farther into the canal and to scrape the canal walls softened by the action of the acid. The acid chemically destroys any organic matter—*i. e.*, pulp tissue—present, releases the calcium of the dentin from its combination, and forms calcium sulphate, which is mechanically removed by scrapers. Care must be observed not to strain the broaches too greatly, as they may break. The operation is continued until the apex of the root is reached. F. T. Hayes suggests the use of aqua regia as less injurious to broaches; lactic acid is also less injurious. When the cleanser will not enter readily it is well to file away the barbs from an old cleanser and leave it roughened, and to use it for a time with the acid until the cleanser proper can be employed. Even then it may be necessary to use a cleanser with only part of the barbs filed away. Iridio-platinum or gold broaches may be used for this purpose.

Some operators prefer the use of the alloy kalium-natrium, used on the broach as a means of facilitating the opening of the canals.

In the canals of posterior teeth short cleansers are mounted in a

[1] Proceedings of the Ohio State Dental Society, 1894.

chuck handle and the shank sharply bent at a right or obtuse angle. If the cleanser bind in the canal, it should be grasped with the thumb and forefinger and given a straight pull to relieve it.

FIG. 469



FIG. 470

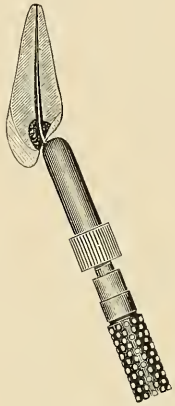

FIG. 471

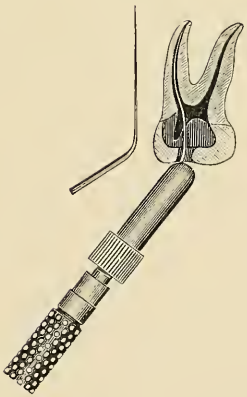

FIG. 472

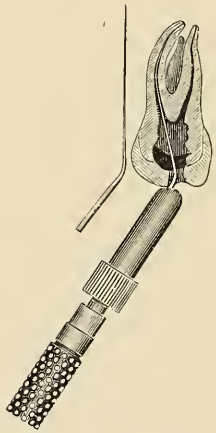

If acid be used it should be neutralized with sodium bicarbonate or sodium dioxid. The improved Gates-Glidden drill (Fig. 473) has some use in the enlargement of canals the lumen of which has been determined by the above methods. They should not be used for the preliminary opening of fine canals, as they tend to form false channels in the side of the canals which constantly catch even fine bristles and may render a canal into a form even less advantageous than that it already possesses. The canal filament of pulps in molars and upper first bicuspids may be lifted away with barbed

broaches or cleansers if the canals are large, but it is ordinarily a waste of time to attempt it in the finer canals, as the other work must be done in the apical regions.

The use of 5 per cent. formalin, tannin, or alum, to be specially applied about two days after the application of arsenic, has been suggested for the toughening of pulps. Their use necessitates a visit for their special application. They toughen the pulp, and, while the advantage in pulp removal is offset by the special visit needed, may, in fine canals, mummify inaccessible portions of pulp tissue.

Fig. 473

Improved Gates-Glidden nerve-canal drill for engine work.

The point of importance is the removal from the pulp canal of all removable portions of pulp tissue and an enlargement sufficient to admit a satisfactory root filling. It is an open question whether in multirooted teeth this is ever complete, or whether it is necessary that it be made absolutely so, regardless of other dangers. In molars and even other teeth there may be more than one foramen and at times delta-like formations are present. Therefore one should use all safe means and rely upon antiseptic measures for the impossible cases. In this connection a radiograph before and after canal exploration will be of assistance.

A perfectly safe rule for mechanical procedures is as follows: Use drills only when they advance readily into the root lumen; prefer Downie broaches and Donaldson cleansers under other circumstances. Advance no large reamers into delicate apical portions of roots, as a lateral perforation may be made. If a fine broach cannot be passed through the apical foramen, do not attempt its enlargement; and it is better to preserve a normal foramen, as large foramina present greater difficulty of filling than normal ones.

If doubt exist as to the presence of a portion of pulp in the apex of the root, papain paste may be placed in the canals for a few days to digest the remaining pulp tissue. (See Pulp Digestion.)

If the pulp be removed as far as possible by careful work and the canal sealed to that point with a mechanically perfect and antiseptic root filling, it is improbable that any future trouble will arise, and *it is better that any such trouble should be subsequently treated than that immediate trouble should be set up by perforation in an endeavor to force a finding of canals which a very fine Downie or Kerr cleanser, or broach, will not explore.*

This technique is, as a rule, best carried out under rubber dam, to prevent the septic contamination of canals by entrance of infected

saliva; but if this be impossible it is wise to sterilize the mouth and napkin it, and to place a drop of carbolic acid or formocresol in the canals and continue the work under *antiseptic* precautions.

It is wise to have the patient first brush the teeth, using soap or a tooth paste or powder. After application of the dam or napkin the cavity is cleansed of the debris of decay if any be present. Then the cavity is to be wiped out with phenol camphor. Next the application of cocain, etc., is made. Before entering the pulp chamber or just after, a drop of formocresol is to be placed on the field of operation and a clean bur used to enter the pulp cavity. The debris is removed, the canals located, and a fresh drop of formocresol placed before continuing with the canal work.

As the napkins become wet they may be removed, the cavity douched with a jet of warm water, the patient rested for a moment, and then the napkins are reapplied, the cavity dried, and the operation repeated. The napkins may be renewed without disturbing the treatment, but it is often desirable to wash out the debris, and the rest is often agreeable to the patient.

The scraping of the canals removes the possible remnants of pulp tissue, odontoblasts, etc., adhering to the dentin walls, and also a part of the wall with the large ends of the fibrils. All these are decomposable media, may become septic, and are wisely removed.

The final removal of all pulp debris, coagulated blood, etc., is best done with a fine Donaldson cleanser, moved to and fro in the canal with one hand, while with the other a stream of warm water is gently introduced by means of a Moffat syringe. A large cottonoid roll or a napkin may be held by the patient or assistant to absorb the excess of moisture when the rubber dam is in position.

If the operations have been done under antiseptic precautions, the root is ready for filling, unless irritation of the apical tissues be severe, in which case a sedative antiseptic—*e. g.*, menthol in chloroform—on cotton should be sealed in the canal. The gum should be painted with iodin as a counterirritant, and the subsidence of the symptoms awaited. (See Non-septic Apical Pericementitis.)

Rhein recommends for the treatment of inaccessible portions of recently devitalized pulps the use of a chemically pure zinc point, to be placed in the root moistened with a 1 to 500 mercuric chlorid in hydrogen dioxid (3 per cent. solution) and the anode of the cataphoric appliance applied to it, the cathode sponge to be placed under the dam on the cheek. From 1 to 5 milliampères of current are used and maintained for from three to seven minutes, according to the exigency.

Zinc oxychlorid is produced and carried into the tissue.

It is always, perhaps, safer to introduce a sealed dressing of phenol camphor plus menthol or thymol until all possible hemorrhage or irritation has subsided. In case of pressure anesthesia with free hemorrhage a little alum and thymol, equal parts, is well added to the phenol camphor, or even a dry dressing, to absorb any secondary hemorrhage. (Ottolengui.)

DESCRIPTION OF FIGS. 474, 475, AND 476.[1]

FIG. 474.—Fig. 3 gives in contrast a sectional view of deciduous and permanent upper teeth divided through their lateral diameters.

FIG. 4, a sectional view of the corresponding lower teeth divided through their anteroposterior diameters: *a*, *b*, *c* represent respectively the deciduous and permanent front incisors in contrast; *d*, *e*, *f*, the lateral incisors; *g*, *h*, *i*, the canines; *k*, deciduous molars, upper and lower; *l*, *m*, the successors to the deciduous molars, the bicuspids; *n*, *o*, represent permanent molars; *c*, *f*, *i*, *m*, *o*, have dotted lines indicating the thickness of enamel removed by wear, atrophy of the cementum, and reduction in the size of the pulp due to progressive calcification, these changes being incident to old age.

FIG. 475 erpresents in Fig. 1, letters *a* to *h* and *a* to *h*, the longitudinal or vertical sections of the sixteen upper teeth, showing the labiopalatal diameter of the pulp chamber and canal in crown and roots, the section of the molars being through the anterior buccal and palatal roots, while the bicuspids *d e* and *d e* illustrate the result of such a compression of the root as to divide the pulp chamber into two canals—a condition which so frequently exists in these flattened roots. The double-lettered series, *d d* to *h h* and *d d* to *h h*, represent in the molars a section through the posterior buccal and the palatal roots, from which is quite readily recognized the slightly greater lateral diameter of the pulp chamber in the crown and the larger canal in the posterior buccal root over that in the anterior buccal root, while the bicuspids lettered *e e d d* and *d d e e* illustrate modified pulp chamber and canal, with bifurcation of the root in one, these being cut through a different axis or plane from the single-lettered series.

Fig. 2, letters *a* to *h* and *a* to *h*, represent the sixteen lower teeth with the section through their long diameters, as in the upper series. These incisors illustrate the compressed or flattened condition of their roots in contrast with the cylindrical character of the roots of the upper incisors, while the bicuspids *d e* and *d e* illustrate the singleness of their pulp chamber and the cylindrical condition of their roots as in contrast with the flattened or compressed condition of the roots of the upper bicuspids. The molars *f*, *g*, *h*, and *f*, *g*, *h* represent sections through the anterior root, illustrating its compressed condition and divided pulp chamber in the first and second molar, and a somewhat flattened one in the anterior root of the third molar; *f f*, *g g*, *h h* and *f f*, *g g*, *h h* represent the single and cylindrical pulp chamber in the posterior root of the lower molars, while *b b*, *c c* and *a a*, *b b* represent the incisors and canines of the same series, with modified pulp chambers arising from modified development.

FIG. 476.—Fig. 1, from *a* to *h* and *a* to *h*, represent the upper teeth, with transverse or horizontal section through the base of the pulp chamber in the crown, viewing the entrance to the canals of the several roots, while the same letters in Fig. 2 represent the lower series in the same manner.

Fig. 3 represents the upper teeth, with the transverse or horizontal section made below the largest diameter of the pulp chamber and through the canals after they have diverged from the central chamber, but before the roots into which they run have in the molars bifurcated.

Fig. 4 in like manner represents the lower series, well illustrating the flattened or compressed condition of the canal anterior roots of the molars and the division of the chamber, as is frequently found in the roots of the lower incisors.

The letters *a a*, *b b*, *c c*, *d d*, *f f*, *d d*, and *e e* (Fig. 3) represent the relative shapes, whether circular, oval, or flattened, of the pulp canal in the roots of the upper central and lateral incisors, the canines, the first and second bicuspids, and the first, second, and third molars, while the same letters in Fig. 4 represent the relative shapes of the pulp canal in similar teeth in the lower series.

[1] These figures are taken from v. Carabelli's Anatomie des Mundes.

FIG. 474

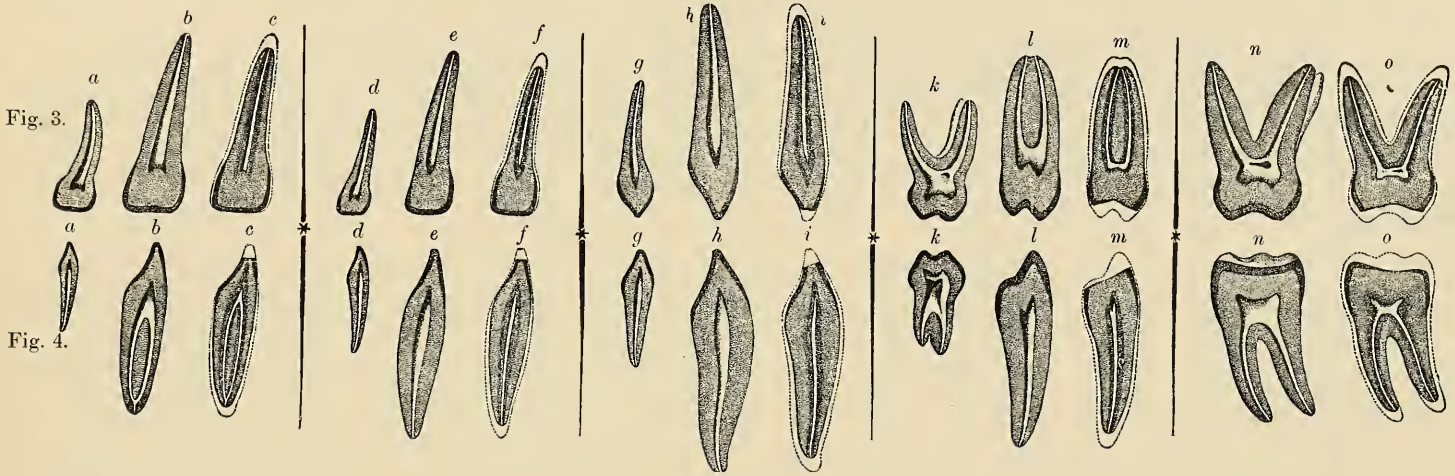

FIG. 475

Fig. 1.
hh gg ff ee dd
h g f e d c b a a b c d e f g h
Fig. 2.
h g f e d c b a a b c d e f g h
hh gg ff
cc bb aa bb
ff gg hh

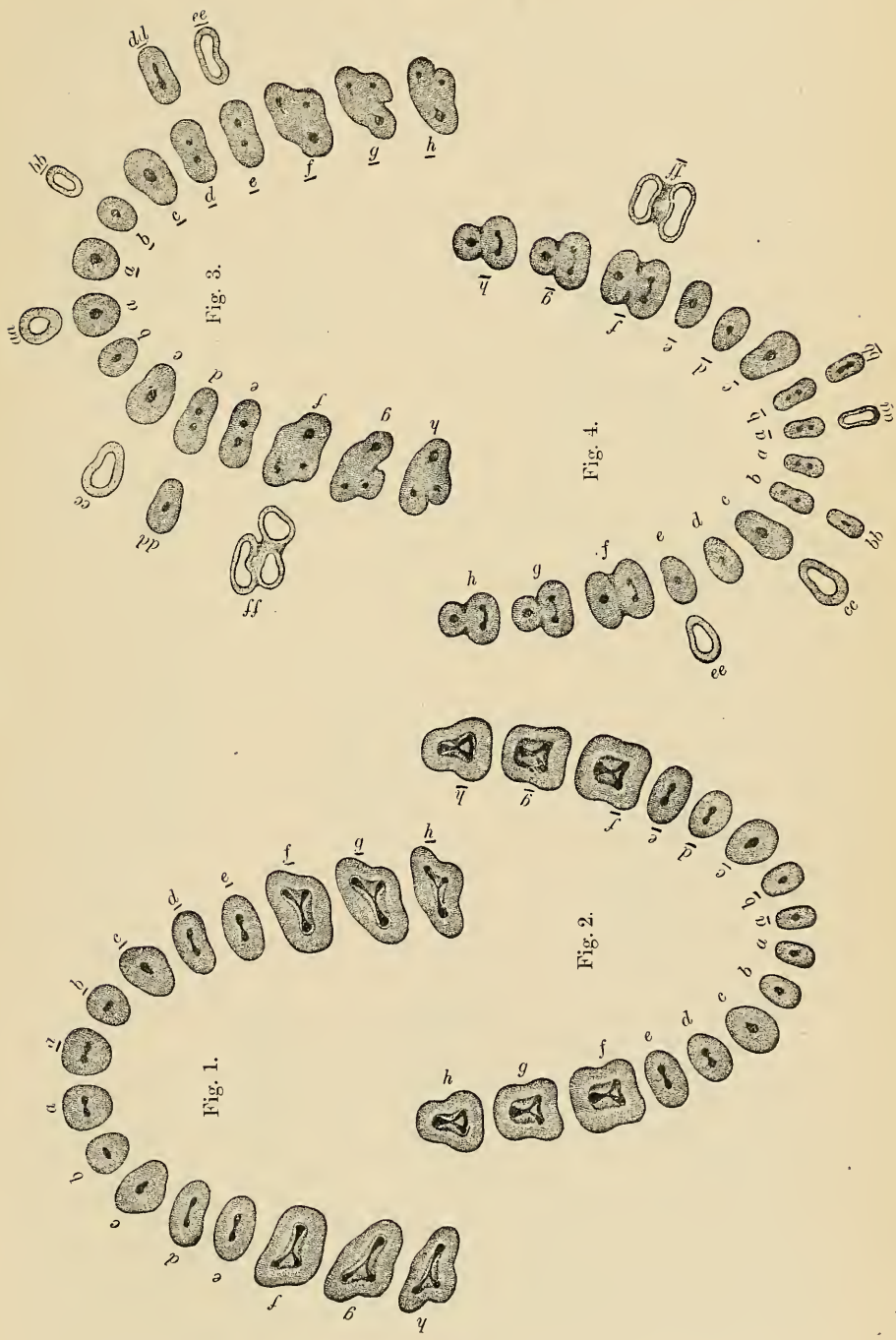

Fig 476

Sometimes it is desirable to mummify any possible irremovable portion of pulp or the fibrils by the use of formalin solutions which are usually tolerated.

Fig. 477

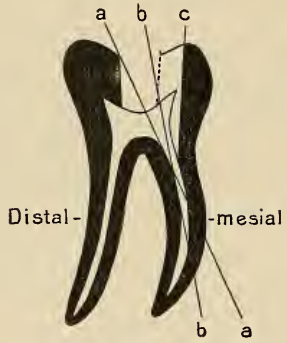

Diagram illustrating the improvement in access *C*, to the deeper portions of enamel by cutting in accordance with a radiograph. The dotted line shows the ordinary opening permitting the access *b b*. (Rhein.)

Fig. 478 Fig. 479 Fig. 480

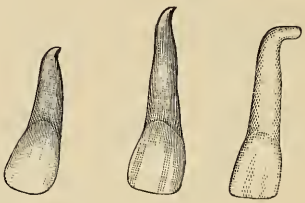

Upper lateral incisors. (Ottolengui).

Fig. 481 Fig. 482 Fig. 483

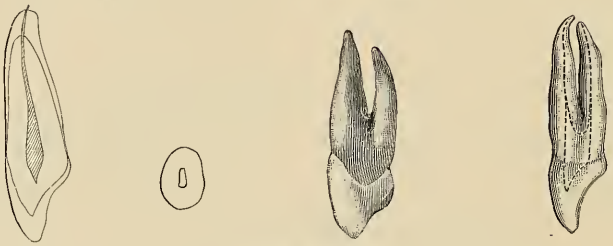

Upper canines.

Fig. 484 Fig. 485 Fig. 486

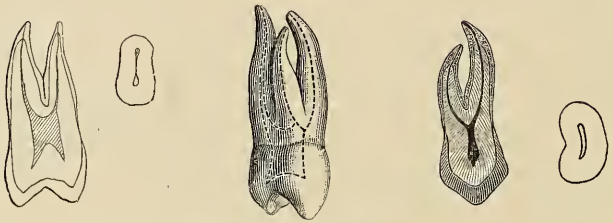

Upper first bicuspids.

The carrying out of canal treatment involves a knowledge of the topographical anatomy of the teeth and their pulp canals. As an aid to this Figs. 474, 475, and 476 are introduced, showing the normal

outlines of the teeth and their pulp chambers; Fig. 476 shows the appearance and locations of the pulp canal openings at their coronal ends. It is to be borne in mind that the roots are not always normal as shown in Fig. 475, and that various degrees of lack of development or resorption may cause the root canals to be unusually open or short, with the treatment complicated by the presence of vital tissue at the root ends. In a general way it may be stated that much resorbed roots, as indicated by the age in deciduous teeth, or largely incomplete roots, as indicated by the age in permanent teeth, indicate a pulp-capping operation rather than extirpation; in the permanent teeth, to permit better root formation. If unavoidable, one must do the best possible.

FIG. 487

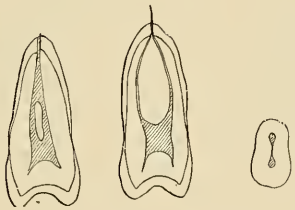

b *a*

Upper second bicuspid.

FIG. 488

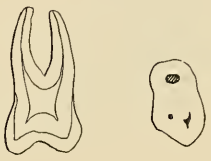

b *a*

Upper first molar.

FIG. 489

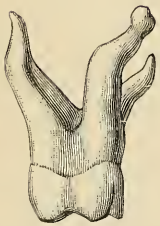

Upper molar.

FIG. 490

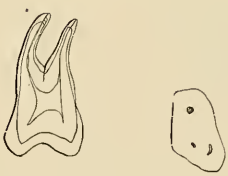

b *a*

FIG. 491

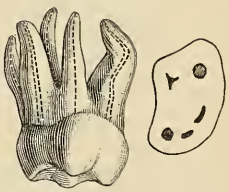

b *a*

Upper second molars.

In the penetration and enlargement of canals the larger and straighter canals may be cleansed thoroughly to the apex, but in very fine and tortuous roots (Figs. 478 to 507) the operator is often confronted with the option of taking the chances of perforation by forcing further entrance or of leaving some doubtful apical portion uncleansed. To further perfect the operation of canal cleansing a radiograph may be taken as indicated by Rhein, and the cavity extension made so as to permit as direct an access as possible (Fig. 477). In very bad cases the decision should be that the danger

of perforation is the greater evil, and agents of a mummifying character should be employed to render any such filament into a state lessening the danger of subsequent putrefaction.

Fig. 492 Fig. 493 Fig. 494

Fig. 495 Fig. 496 Fig. 497

Upper molars. (Ottolengui.)

Fig. 498 Fig. 499

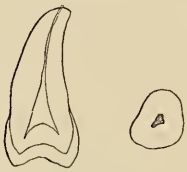
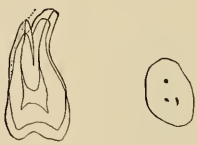

a *b*

Upper third molars.

The writer regards the use of formocresol (equal parts of 37 per cent. aqueous formaldehyd solution and cresol) as especially valuable where immediate root filling is not indicated. If the patient be of a nervous and irritable type this may be diluted to 5 or 10 per cent. formaldehyd strength by the use of cresol or camphophenique without impairing its value. Often the full strength may be used on cotton as a temporary dressing. This hardens any remaining pulp and also probably the fibrils in the tubules. It also permits the apical tissue to heal and resume its normal sensitivity when the pulp has been entirely removed, which is of value in determining the extent to which pressure may be applied in filling the canals. In anterior teeth it is better to use aqueous formaldehyd solutions, as the cresol may cause discoloration, but in these situations more perfect mechanical work can be done.

In a few cases in which cervical cavities obliterate the canal or cause annoying approach to it, it is desirable to remedy the con-

Fig. 500

Fig. 501

Fig. 502

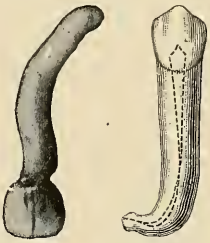

Lower bicuspids.

Fig. 503

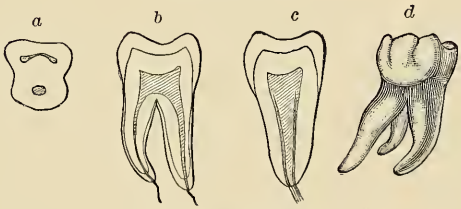

Lower first molars.

Fig. 504

a

Lower first molar.

Fig. 505

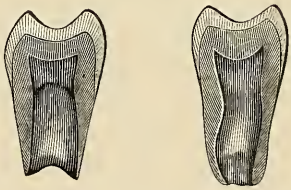

b

Lower first molar, immature.

Fig. 506

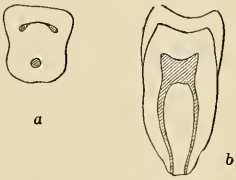

Lower second molar.

Fig. 507

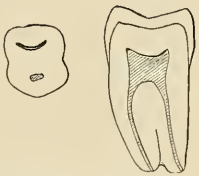

Lower third molar.

dition. In such case the canals are opened as usual and enlarged, and the cavity prepared with suitable retentions for filling. The last-used reamer is then to be placed in the canal and the filling

inserted. The filling is then supported by pressure while the reamer is slowly twisted to the right and withdrawn, leaving a canal through the filling. This may be done with amalgam or with zinc phosphate if a later removal be required. If the root be much weakened, a tapering dowel may be cemented through the crown and canal, thus attaching the root to the crown more firmly (Fig. 508, also p. 432).

FIG. 508

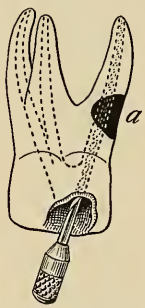

Method of restoring lost canal continuity. The cavity should have more retention form than shown: *a*, amalgam.

ACCIDENTS IN CANAL OPENING.

The chief accidents that may occur are the perforation of the root wall and the breaking of the instruments used. If the technique laid down be carefully followed the danger of perforation is practically eliminated. In fact, the greatest danger is the penetration and enlargement of the apical foramen. To avoid this the Kerr reamers should always be passed to the apex of the canal by hand or while the reamer is not revolving. It is then withdrawn a trifle and revolved, and one may always judge the distance the reamer was withdrawn. Accidents are usually the result of thoughtless forward pressure of reamers and drills, and care will reduce this to a minimum. Sometimes one must take the chances with the Kerr engine reamer. When doubt exists as to canal locations, the desiccation of the pulp chamber is of great assistance by bringing them into view, and if secondary deposits exist one should always use a small bud bur and keep well within the limits of the dentin of a root while gently seeking a canal lumen.

Frequent exploration should follow gentle advances, and, as a rule, the canal will be found of fairly normal size just beyond the point of constriction. In some cases 50 per cent. sulphuric acid should be sealed against the suspected canal and the operation deferred to another sitting.

If a perforation be accidentally made it should be covered as in any case of perforation (which see).

Always one should be able to diagnosticate such an opening and arsenic should never be applied to such. Cases of extensive necrosis have occurred from carelessness in this direction. The breakage of broaches is largely avoidable through the use of new instruments and by adhering to the rule of using the smaller sizes until the canals are sufficiently enlarged to permit the use of larger sizes, and, in case of

engine reamers, of starting the power with the reamer loose in the canal. The engine broach seems to be of better temper than the engine reamer.

Accidents of this sort usually occur with barbed instruments of the Donaldson cleanser type, especially when used with force. Sulphuric acid tends to disintegrate the broach, so that lactic acid is often better used with it, or the alloy of sodium and potassium with a smooth broach will open the canal so that the cleanser will not bind. If it does it should be grasped with the thumb and finger and given a straight pull.

While avoidance is far better than the application of the remedy, if the accident occur, the broach should be removed if possible.

If lying loosely in the canal a new cleanser may be passed to one side of it and then be pressed against it. It should engage the barbs and jig it out.

Cotton wrapped on a small Swiss broach may be pressed down at one side of the broken broach and its fibres made to engage its barbs.

Moving the broach back and forth while sulphuric acid, sodium dioxid, or sodium and potassium is about it, will sometimes loosen it. One may sometimes drill to one side of a broken instrument with a Kerr hand broach in order to more readily engage it with a barbed instrument. If very loose a magnetized probe will attract it and draw it out.

If the broach be tightly fixed in the canal, sodium chlorid, tincture of iodin, sulphuric acid, aqua regia, or 25 per cent. pyrozone may be sealed in, in the hope of chemically disintegrating it.

Fig. 509

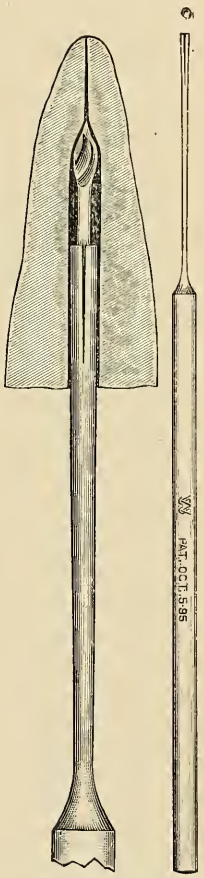

Split and threaded instrument for engaging the shank of a Gates-Glidden drill.

The head of a Gates-Glidden drill or Kerr reamer is treated in the same manner. Sometimes in straight roots the How appliance shown in Fig. 509 is useful. If any broach be irremovable, iodoform paste or embalming paste should be packed over it and sealed in, in order to keep the part permanently sterile. In a septic case the formocresol treatment should precede such root filling.

THE FILLING OF ROOT CANALS.

In all cases in which the removal of the dental pulp from the canals is necessary, it is imperative that the pulp canals shall be filled with some substance that shall mechanically obliterate it by sealing it throughout its length, in order to prevent the ingress of fluid either from the mouth or apical tissue. Such fluid is liable to putrefaction, and the results of putrefaction follow. If made antiseptic, it also tends to kill out any bacteria which may find a partial entrance. The mechanical sealing may be defective, even when the best possible effort is put forth to make it perfect, so that the addition of more or less permanent antiseptics is valuable. Prinz has suggested that it should be impervious to *x*-rays so that it may be radiographed.

It matters little whether a canal filling is hard or soft provided it seals the canal permanently, that it is permanently antiseptic, non-irritating, and that it is not disturbed by any subsequent work. It is better that it be capable of removal with a reasonable amount of safe work.

It also makes very little difference whether the pulp has been removed while aseptic or has been in a septic state, provided the canal has been rendered sterile by appropriate means.

In other words, when the canal is aseptic and the apical tissues sterile and healthy, the canal is ready for filling. The length of time this may require also makes no difference. Therefore, what is here said applies to all cases requiring root filling. Much has been written of the impossibility of sterilizing the tubules of root canals and of the liability of return of sepsis from bacteria located in them. This simply means that one should employ the best means of gaining sterility known and then employ permanent antiseptics. To seal and keep these tubules as sterile as possible, the use of a thin varnish of resin, 12 grs., in chloroform, f℥iij, has been suggested by Callahan to be applied after desiccation and before root filling. The size of the apical foramen, the presence of inaccessible apical portions of canals, the presence of perforations and some other conditions, however, indicate a choice of some root filling rather than others, so that there is no absolute rule for all cases.

The following root canal fillings are useful.

Gutta-percha.—This is usually the ordinary, low heat, pink gutta-percha base plate containing vermilion and zinc oxid. Cones may be rolled or left with flat sides. Prepared cones may be purchased which have an accurate taper and are either round or flat-sided. The flat side permits any adjunct plastic filling material or solvent

to flow down the side of the cone rather than be forced toward the apex.

Temporary stopping may be melted in a spoon and aristol added to it. It is then rolled into cones for use. Instead, a stick of it may be warmed at a point away from the end and then be pulled out into two cones which may be further rolled out. They may be rolled in powdered aristol if desired.

Ottolengui advises the use of bits of floss silk an inch long to be saturated with chloro-percha and dried. These are to be pressed into chloro-percha previously placed in the canal and crimped to place. An end is left projecting into the pulp chamber. If necessary this may be caught and the dressing withdrawn.

Chloro-percha.—This is a solution of gutta-percha base-plate in chloroform. Usually a quantity of aristol or iodoform is added to make it antiseptic. As it shrinks in hardening it should be used in conjunction with gutta-percha cones or carried upon cotton twist or upon floss silk, which it saturates, transforming them practically into a solid mass when the chloroform evaporates.

Euca-percha.—The basis of this substance is a solution of gutta-percha base-plate in eucalyptol. To this various antiseptics may be added. There are various modes of making this substance. B. L. Cochran[1] suggests the following:

℞—Gutta-percha base-plate	ʒss
Dissolve in chloroform q. s. to a thin solution.	
Add saturated solution of thymol in eucalyptol . . .	fʒss
Let the chloroform evaporate.	

Euca-percha Compound (Buckley, Lilly) is a simple solution of base-plate in eucalyptol made by aid of heat.

Formo-percha (Blair) has paraform and oil of cassia added.

This material may be warmed into a creamy paste and be used either on cotton or be used in conjunction with gutta-percha cones.

Zinc Oxychlorid.—This consists of the ordinary zinc oxychlorid cement, which consists of modified calcined zinc oxid for the powder and diluted zinc chlorid as the fluid.

It is antiseptic for a time at least, and may have iodoform incorporated with it if desired. It is carried to place on a thread of cotton, or may be used with gutta-percha cones. The addition of a trifle of glycerin retards setting.

Embalming Paste.—A so-called embalming paste is prepared as follows:

[1] Dental Review, 1905.

℞—Paraform	1 part
Thymol	1 part
Glycerin	1 part
Zinc oxid	1 part or more.

Or,

℞—Paraform	1 part
Thymol	2 parts
Alum	1 part
Zinc oxid	2 parts

Creosote to a thick or thin paste.

This is used as a temporary germicidal canal dressing on cotton or as a root-filling with gutta-percha or temporary stopping cones which are pressed into it.

FIG. 510

Radiograph of a perfect gutta-percha root filling. (Rhein.)

FIG. 511

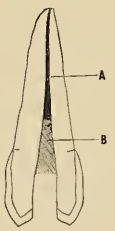

Root-canal filling: *A*, gutta-percha; *B*, zinc oxychlorid.

Wax or Paraffin.—Either of these may have a third of its bulk of salol, aristol, or iodoform, or a fifth of paraform added to it while melted in a spoon. It is then rolled into cones or small pellets. In use a pellet is dropped into the dried pulp chamber and a hot Evans root drier point applied. As it melts, the metal point is carried down into the root and the fluid material pumped to the apex. Capillarity does part of the work. It adjusts itself to the tissue and the canal walls. The pulp chamber is then cleared of excess wax, etc., and filled without pressure.

Prinz[1] recommends the use of hard paraffin having a melting point of not less than 132° F. in the following combination:

℞—Thymol	2 parts
Bismuth trioxid	30 parts
Hard paraffin	68 parts

The canal is to be thoroughly dried, then merely moistened with liquid albolene, a cone of the compound then to be placed in the

[1] Dental Cosmos, October, 1912, p. 1089.

canal and melted with a root drier (an electric drier or Evans' or Reithmüller's modification[1]). The albolene combines with it and leads it to place with exclusion of air. The bismuth is added to make it impervious to the *x*-rays, hence it throws a radiographic shadow.

Prinz states that iodoform added to paraffin can be only superficially antiseptic. This is, however, quite sufficient. Mixed into wax it persistently odorizes the air in its vicinity, hence should have antiseptic value. The influence of iodiform for long continued usefulness is unquestionable.

Salol.—This is a solid antiseptic, melting at 104° F. It is used much as paraffin is. A gutta-percha cone may be thrust into it while fluid. It often seems to disappear from canals, and unless used with paraffin is to be used only as a temporary root filling.

FIG. 512

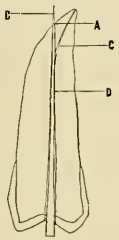

A, perforation through side of apex; *D*, cone of gutta-percha passing through; *B*, portion to be cut off; *C*, portion of canal not treated.

FIG. 513

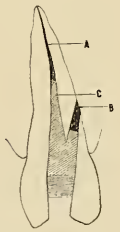

Lateral perforation due to holding a bur at a wrong angle to the axis of the root: *A*, root canal subsequently filled with gutta-percha; *B*, perforation filled with a fitted cone of gutta-percha; *C*, zinc oxy-chlorid.

Canada Balsam.—A solution of Canada balsam in chloroform to which hydronaphthol is added (Williams) makes a useful solution in which to saturate cotton twists or to moisten canals previous to the introduction of a cone of gutta-percha. Balsam of Peru is now on trial, but its soft condition is liable to render it a failure.

Colophony.—Callahan[2] recommends violin resin, grain 12, in chloroform, 3 fluidrams, as a thin solution for filling the desiccated tubuli. The canals having been reamed to permit cones to enter, they are filled with the solution and a gutta-percha cone pumped back and forth forty to sixty times to dissolve the cone and force adaptation. The cone is then packed in with pluggers touched to a cake of paraffin.

[1] See Dental Cosmos, March, 1913, p. 342.
[2] Journal of the Allied Sciences, March, 1914.

Normal Tapering Well-opened Canals.—In these canals gutta-percha is admirable; a little eucalyptol is applied to the canal walls and a section of a suitable cone mounted by heat on the end of a canal plugger which will go to or nearly to the canal end is gently but firmly pressed into the apex of the canal. Temporary stopping cones are more readily adapted, and as they can be made antiseptic, are valuable.

The rest of the canal is then filled with other sections or with zinc oxychlorid made thin and carried to place on cotton twists. The latter may be used for the entire canal, and should then be preceded by a tiny bit of cotton saturated with an essential oil to prevent irritation of the apical tissue. It is claimed that this cotton is acted upon by the zinc chlorid, being transformed into an amyloid condition. If used alone a slight degree of moisture aids in carrying to the apical foramen (Fig. 513).

A variant consists in moistening the canal with chloro-percha or euca-percha, and using the section of cone or pressing in an entire cone. A second cone may be placed at the side of the first and both compacted after warming with a hot air blast, or the first cone alone used.

Another variant is the use of chloro-percha on cotton, which makes a very accurate and easily introduced root filling when carried to place on a properly formed and tempered Swiss broach or prepared Donaldson bristle. A little iodoform may be taken up with it.

When the broach must be bent to enter canals, loosen the broach first before introducing into the canal, thus leaving the cotton loosely mounted on the broach. To prepare a Donaldson bristle cut off the hook and flatten the end upon an Arkansas stone, and slightly flatten on two sides, then lay upon a glass slab and burnish thoroughly to remove any bur left. In use the cotton and broach are rolled with the left forefinger and thumb only. It is obvious that to do this the broach must be perfectly straight. When slightly bent the method of rolling the cotton next described may be employed. The writer believes the prepared Swiss broach not only more facile but economical in use.

To prepare broaches, select accurately tapering Swiss or English broaches from which the temper has not been drawn. Next, draw the temper by placing a few in a test-tube and heating first at the shank, gradually drawing the tube over the flame toward the points. The blue color seen on the shank should be run out to the tip; let cool on any open surface. The soft broaches usually sold are nearly useless. The point is left if canal exploration is intended. For carrying cotton twists, cut the end off with scissors. To wind the

cotton lay a wisp on the left forefinger, lay the broach upon it, close down the thumb, then quickly revolve the broach with the right forefinger and thumb, pushing the cotton through those of the left hand to form a symmetrical cone. To use as a swab, rotate in the canal to the right. To leave the cotton in the canal, rotate to the right as the twist is pressed to the apex. Then turn the broach once or twice to the left to loosen it from the cotton, withdraw a little, then press in again. Thus the cotton is crimped upon itself.

Roots with Open Foramina.—These may be incomplete roots with very large apical openings, in which case wax with aristol is the best filling used, as previously stated. It should be said again, however, that if possible the pulp of such a tooth should be capped to permit root formation to be completed.

FIG. 514

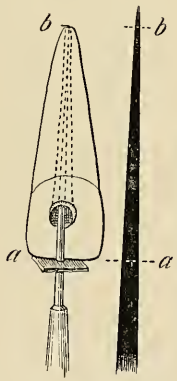

Manner of measuring the length of a root and fitting a gutta-percha cone.

FIG. 515

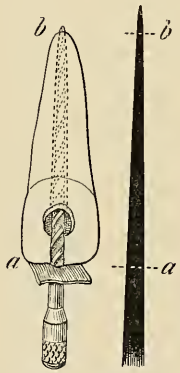

Manner of tapering a canal to fit a cone of the same size.

If the foramen is of moderate extent and either natural or unfortunately made with drills, gutta-percha cones are valuable. To determine the size of the cone, one of two methods may be employed. Perhaps the more accurate is the employment of a series of gradually increasing sizes of canal pluggers. One should be selected which will just fit the apex or be a trifle too large. By placing this in the hole of a draw plate, a specially rolled cone or even a slightly tapering size may be made to fit the hole in the plate. The canal is moistened with eucalyptol or chloro-percha and a quarter-inch section of the cone is carried on the plugger to its place in the root-canal apex. A slight protrusion is not ordinarily productive of injury. A cardboard perforated by the respective plugger will do instead of the draw plate. If the root length was previously measured with a piece of rubber dam slipped over the plugger shank and some known point on the

tooth used as a guide, the cone should be seen to go down until it chokes the foramen, when the dam should be above the guide point a distance equal to the length of the cone section used.

In the second method a long, tapering cone is prepared. Some point on this must fit the foramen. It is tried in and as often as sensation is felt it is cut off a trifle and tried again until it chokes the foramen without sensation.

In case of abscess, especially if filling is a means to a cure, this may extend beyond the apex of the tooth.

The cone should be marked at a point corresponding to the guide point chosen and be laid aside. Next, a fine hook made by bending the tip of a fine broach to a right angle, then cutting it close to the shank, has a piece of rubber dam slipped over it and is passed through the apex and hooked upon the edge (Fig. 514). The dam is slipped to the chosen guide point. The probe hook is withdrawn, the dam laid at the mark on the cone, and the cone cut off at the lower edge of the hook (Fig. 514, *b*). In use, a little solvent, preferably chloropercha, is placed in the canal and the cone slowly slipped to place until the mark coincides with the guide point. The cone is then cut off with a hot instrument, warmed, and gently packed into the canal.

When the canal has been reamed with a small engine reamer, and the apex enlarged, the hook may be placed and have a bit of rubber dam on it as a guide. Then slip a bit of dam over a larger tapering root reamer at a corresponding length. Drive the reamer in until at the guide point. This gives a tapering cone shape to the canal and is a guide in the construction of the cone (Fig. 515).

In some cases of large foramina or perforation a bit of sterile grafting sponge may be introduced into the apical space and the filling placed against it.[1]

Canals with Inaccessible Apices.—Any tissue in such apices should have been mummified or sterilized with formocresol or be treated by Rhein's method[2] of filling a canal with mercuric chlorid in hydrogen dioxid (1 to 500), passing in a zinc probe, then applying the anode of a cataphoric outfit with from 1 to 5 milliampères of current from three to seven minutes (the cathode at the cheek). The object is to form zinc oxychlorid in the apical root canal through electrolytic action. The canal must be regarded as doubtful, but if well opened to the inaccessible portion a trifle of formo-percha may be placed on cotton at this point and the balance of the canal be filled with antiseptic temporary stopping. The paraform and cassia in the formo-percha are active agents.

[1] G. Brunton, England: Dental Cosmos, 1900.
[2] Dental Cosmos, 1905, p. 1196.

A variant consists in the use of embalming paste or Söderberg's mummifying paste, either made stiff and introduced with successive sizes of pluggers, beginning with the largest admissible and proceeding to the smallest, or moistening the canal with the thinner paste and packing a cone into it. The use of such a paste in connection with a cone of gutta-percha is valuable as an agent embalming the fibrils in the dentin of teeth from which living pulps have been removed, or of keeping sterile the tubules of those teeth in which the pulp is gangrenous (see p. 559).

If conditions admit of it, provision for future entrance of the canals should be made, and it is always well to divide the operation of canal filling and crown filling by a short period of time.

Iodoform paste with or without cotton may be placed in the apical third of the canal.

Root Canals in Temporary Teeth.—These may at times be well filled with gutta-percha points, which, if aseptic, do not interfere with resorption, but a material of easier adaptation which absorbs with the root is preferable. The waxes meet the indications, as they can be pumped while fluid from the action of a hot root drier into all inequalities, where they adjust their relation to the soft tissue.

Buckley recommends in cases of chronic abscess the use of a stiff mixture of calcium phosphate and formocresol (formalin, 1 part; cresol, 2 parts), to be packed into the pulp cavity and zinc phosphate flowed over it.

Johnson recommends euca-percha to be pumped into the canals and pressure with temporary stopping to be exerted until the solution appears at the fistula. Such temporary stopping as does not interfere with filling integrity should be left.

There are various other methods of filling root canals, such as driving wood points saturated in carbolic acid into the canals; the use of iodoform paste, with or without cotton, or of creosote on cotton (preferably raw cotton); the use of balsamo del deserto, etc., which have had advocates, but the methods given are those which have had long-continued and successful use.

The Covering of the Root Canal Filling.—The bulb of the pulp chamber may be filled with any of the more solid materials. In case of a strong crown, temporary stopping makes a good occupant of this cavity, though gutta-percha is often used; oxychlorid of zinc aids in keeping good color. In the weaker teeth or sometimes for other reasons the final filling may extend into the pulp canal to assist in anchorage.

Partial Removal of Pulp.—The Cobalt method of pulp treatment has been alluded to. Wm. Herbst, of Bremen, advanced the idea

that if the bulbous portion of the pulp be devitalized by cobalt and removed, leaving the root portions, the latter will remain vital if protected after a manner described by him. The bulbous portion of the pulp is cut away and the pulp chamber enlarged by means of large rose burs. Over the pulp stumps a cylinder of tin-foil is laid, and burnished to fit the floor of the pulp chamber without pressure upon the pulp stumps (Fig. 516). Over this a filling is placed. Herbst

FIG. 516

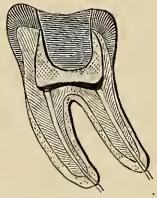

Herbst's method of preserving pulp stumps.

claims that the pulp stumps will remain vital. Were this to be depended upon, it would be a marked saving of time and trouble and would lessen the chances of pericementitis subsequent to pulp removal; but when it is known that the cobalt of Herbst is metallic arsenic, the ultimate death and decomposition of the pulp remnants seem almost inevitable, and in fact does occur. The method should not be employed.

MUMMIFICATION OF THE PULP.

Many experiments have been performed relative to leaving *in situ* portions of pulps and covering them with substances having for their object the chemical alteration of the pulp tissue, so that no pericementitis shall result from its putrefaction. The first effort in this direction is credited to Witzel in 1874.

Miller,[1] after many experiments with various materials, has shown that none but the most powerful and penetrating antiseptics have value as permanent sterilizers. These are the cyanid, bichlorid, and salicylate of mercury, sulphate of copper, and oil of cinnamon. Orthocresol, carbolic acid, trichlorphenol, and zinc chlorid penetrate the pulp tissue rapidly, but are too diffusible, their effects disappearing in a few weeks.

He classifies salicylic acid, eugenol, camphophenique, hydronaphthol, α-naphthol and β-naphthol, aceticotartrate of aluminum, and some essential oils, resorcin, thallin, sulphocarbolate of zinc, etc., as being of doubtful value.

[1] Proceedings of Columbian Dental Congress, 1893.

Those nearly or quite worthless are iodoform, basic anilin coloring matters, borax, boric acid, dermatol, europhen, calcium chlorid, hydrogen dioxid, sozoiodol salts, tincture of iodin, spirit of camphor, and naphthalin.

The preparation giving the best results consisted of mercuric chlorid, 0.0075 gram; thymol, 0.0075 gram, in tablet form.

The pulp is devitalized; the crown portion and all the root portion readily accessible are removed; one of the tablets is placed in the pulp chamber, crushed by means of an amalgam plugger, and covered with gold-foil. The mercury salt tends to discolor the crown of the tooth, so that its employment should be restricted to the posterior teeth; indeed, the necessity for its use would be, as a rule, found with these teeth, being those from which it is most difficult to extract pulp remnants. Miller expresses faith in the power of oil of cinnamon to permanently sterilize pulp fragments.

Söderberg[1] recommended a paste composed as follows:

℞—Alum exsic.,
Thymol,
Glycerol . . . . . āā ʒj
Zinci oxidi . . . . . q.s. to make a stiff paste—M.

It is preferable to add the zinc oxid as needed or to make a small quantity of the paste frequently, as it gradually hardens. To the paste used a crystal of cocain is added to prevent pain. Bennette, of England, has advised the use of paraform incorporated in the paste, for its well-known antiseptic and hardening effects. Greenbaum suggested the use of a drop of 40 per cent. formaldehyd solution to be incorporated with the paste. Both reduce the pulp to the consistence of catgut.

Söderberg reopened cases months after application of the paste to pulp stumps, and found them shrunken and with an odor of thymol about them.

He applied the paste in the manner shown in Figs. 517 and 518. In 1900 Söderberg reported the use of the paste in about 900 cases, of which 220 were test cases of from two to six years' standing. He claims that in no case did apical pericemental disturbance arise from the use of the paste as described.

This method has met with much opposition from prominent operators, who prefer the thorough cleansing and filling of the canals. No doubt the rational method of procedure is to cleanse the canals as well as possible, and to use the paste against unremovable pulp stumps.

While the paste may effect mummification of entire canal filaments

[1] Dental Cosmos, November, 1895.

of pulp, leakage is always imminent about shrunken pulps, and the only safeguard is the antiseptic effect of the paste. This is much enhanced if the bulk of putrefiable material be replaced with the antiseptic paste used as a root filling. Many such root fillings have done good service for many years.

Fig. 517

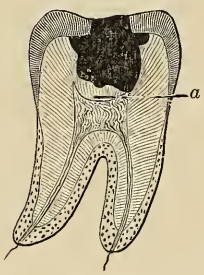

a, caries exposing a horn of the pulp.

Fig. 518

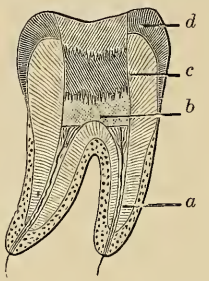

a, root portion of pulp; *b*, mummifying paste; *c*, zinc phosphate; *d*, gold or amalgam.

A certain percentage of failures would be no argument against the employment of the method when indicated, as no method is infallible in all circumstances, and particularly in those in which the present method is indicated.

Pulp Digestion.—Harlan recommended that the following paste be applied to unremoved portions of dead pulps as a means of digesting them preparatory to root filling:

℞—Papain	gr. v
Price's pure glycerin	♏iv
Sol. 1 to 200 hydrochloric acid	♏v—M.

This is applied in the pulp canal, covered with blotting paper soaked in liquid vaselin, and the whole temporarily sealed for a few days. The pulp is reduced to the consistence of jelly and can be readily washed out.

The method, on the whole, does not seem preferable to either mummification or the Rhein treatment or the formocresol treatment of inextricable portions of pulps in curved roots, etc., inasmuch as the occupancy of a canal by a sterile pulp remnant is better than leaving an empty root canal apex or filling only a portion of it in such manner as to render subsequent treatment almost impossible. In fact, it is better that dentists recognize their limitations and put themselves in position to do future good to the patient, than to blindly obstruct efforts in that direction.

Perforations and Resorptions.—The same accidents that occur in canal opening in the case of the removal of anesthetized or devitalized

pulps may occur in all gangrenous cases with somewhat increased liability to infection of the pericemental tissue.

In old cases the pericemental tissue may hypertrophy, causing the condition of hyperplastic (fungoid) gum. This should be sterilized and burned away with the electric cautery or may be frozen with ethyl chlorid and ablated with sharp instruments, or it may be saturated with trichloracetic acid and ablated, or it may be pressed away (resorbed) with cotton saturated with tincture of iodin or an antiseptic oil. The perforation is then covered.

The Filling of Perforations.—Perforations made high up in the canal, after being appropriately sterilized with formocresol, should be filled with wax or with gutta-percha cones, which have been accurately fitted to the openings. It is often difficult to do this accurately, but the effort should be made. When ready, a little antiseptic chloro-percha is to be placed in the perforation or upon the cone, and the latter packed to place.

In low perforations without a fistula associated, the opening of the perforations should be enlarged inwardly and a ball or plaque of aseptic, warm, low-heat gutta-percha, or even temporary stopping, adapted to the opening. A piece of pure gold plate may be burnished over an accessible opening, and be adapted with thick chloro-percha or temporary stopping. Any of these may be fixed in place with oxyphosphate of zinc. Quick-setting oxyphosphate of copper in its soft, gummy, state may be painted over the tissue and root opening by means of an instrument, or the perforation may often be satisfactorily closed with copper amalgam. When in posterior teeth a pin must be used, the pin may be made smaller than the root canal and be coated with wax, soft oxyphosphate of copper is put in the canal, and the pin gently thrust in. When the cement has set the pin may be heated and withdrawn, and when included in the intended superstructure, the pin may be again cemented in place (see Figs. 378, 381, and 382).

When a perforation threatens to produce an abscess an artificial fistula should be made and the case treated accordingly.

If a perforation have a fistula associated with it, the oxyphosphate of copper or zinc oxychlorid may be allowed to go through the fistula, by way of which any excess may be removed.

In case of resorption of the roots of permanent teeth great difficulty may present, the soft, absorbent tissue having grown into the cavity in the root side which it has made. A radiograph will aid in determining the extent of the lesion, which usually renders canal treatment impossible and extraction imperative.

CHAPTER XVIII.

GANGRENE OF THE PULP.

Definition.—By gangrene of the pulp is meant its death through an interference with its nutrition. It may be partial, as when an abscess in the pulp or violent irritation causes the bulbar portion to die, the canal portions being found alive; or when only one canal portion is dead, the others being alive. Either dry or moist gangrene may occur.

Causes.—It is probable that a construction of apical root tissue (hypercementosis) about the pulp may so constrict it as to bring about its death. (For the primary causes of this see Hypercementosis.) Sudden shocks, such as occur from thread, string, or cigar biting, or blows or rapid movement in regulating or wedging, or non-fixation after regulation, may cause torsion or tension of the bloodvessels entering the apex of the pulp.

These influences may either cause pulp hyperemia or strangulation of the apical bloodvessels, or, possibly, an area of apical thrombosis, cutting off the nutritive supply to the pulp. Septic or aseptic inflammation of the pulp may cause its total death. Death of pulp tissue due to arsenic produces results in nowise differing from gangrene, provided the pulp be left *in situ*. (See p. 521.)

DRY GANGRENE OF THE PULP.

Definition.—By dry gangrene of the dental pulp is meant its death *in toto* and its subsequent transformation into a dry, shrivelled mass occupying the pulp chamber and canal.

Causes and Pathology.—If the pulp die and remain under conditions which exclude bacteria from contact with it, the water of the pulp may be removed, leaving the organ as a tough, shrivelled mass (Fig. 519). The conditions most favorable seem to be: (1) Pulp death from some aseptic cause, *e. g.*, the hyperemia resulting from a blow on a sound tooth; (2) constriction of the apical foramen, due to hypercementosis, the result of thread biting or other mild irritation of the pericementum; (3) the presence of secondary dentin over the bulbar portion of the pulp, causing pulp exhaustion yet protecting it from infection; (4) the capping of the pulp with zinc oxychlorid or formagen paste, the pulp being permeated with the drug or dried by it; (5) the

covering of pulp stumps with a paste containing a tannifying substance, such as alum, formaldehyde, or tannin.

The water necessary to putrefaction is abstracted, either naturally or chemically, and probably bacteria are at the same time excluded, either mechanically or because the chemical substances used have penetrated the pulp tissue, acting as antiseptics.

Symptoms.—The tooth has a nearly normal color, but under a reflected light is seen to have lost perfect translucency. There is no response to thermal or electric tests for pulp vitality. The dentin is insensitive to cutting instruments, and the cuttings upon the bur have no odor. There is no odor or fluid in the pulp canal when this is entered, and the pulp is found as a tough, dry mass not unlike that seen in a dry extracted tooth which contained a vital pulp at the time of extraction. These cases as spontaneous occurrences are relatively rare.

Tests for Pulp Vitality.—The diagnosis of pulp vitality or death being in practice almost daily required, the decisive tests are here indicated.

A tooth containing a vital pulp is translucent and pink; that containing a dead one always opaque to transmitted light, and usually clouded to a gray or bluish black. The ordinary appearance by reflected light often corresponds to this, but sometimes a tooth is clouded by fillings, or looks dead, but is vital.

An electric mouth lamp with or without a reflector so arranged as to reflect the light upon the lingual surface of the tooth will supply the means for this test. In its absence strong sunlight may be reflected by means of a mouth mirror, but is not nearly so good a means as the electric light (Fig. 369).

If the tooth be isolated by means of rubber dam and, first, cold water be thrown, or, later, ethyl or methyl chlorid be sprayed upon it or upon the filling contained in it, absence of response will indicate either partial or total pulp death or the formation of a quantity of secondary dentin. In the latter case the test must be renewed as the excavation proceeds.

A hot burnisher or hot gutta-percha applied to a filling or dentin, or very hot water thrown upon an isolated tooth, should provoke at least a delayed response from a vital pulp.

The application of a small high frequency glass electrode to the tip of a vital tooth produces a peculiar sensation not unlike that of hypersensitive dentin. It is due to the fact that the enamel is like glass unable to insulate the high frequency current which passes to the dentinal fibril. A devitalized tooth will not respond. The facility of this test makes the apparatus a very valuable time saver.

It is well to take up the current with the fingers on the side of the tube at first and to raise the finger after the glass is in contact with the tooth.

Woodward has shown that if a few cells of a cataphoric apparatus are in action and the positive electrode be applied to the dentin or metal filling in a vital tooth, while the negative pole is at the cheek or wrist of the patient, a distinct sensation should be felt, while in case of a dead pulp there will be no response; usually even a small filling will transmit a distinct shock in a vital tooth which is absent in a devitalized tooth. A mild interrupted current has also been used for the test. There may be no response through a metal filling, while such response may be obtained by packing wet cotton against the dentin after some drilling. A mild current should always be used unless there is no response, when the strength of the current should be increased. It is generally possible to test some evidently vital tooth nearby as a control. If the filling reach the gum, the current may be transmitted by it. The possibility of contact of the filling with another in a vital tooth is to be remembered. Insulation with rubber dam is indicated in such a case.

Fig. 519

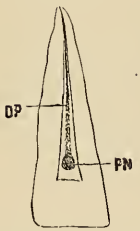

Dry gangrene of the pulp: *PN*, pulp nodule; *DP*, shrivelled pulp. (From a specimen of pulp extracted intact in this condition.)

Fig. 520

Caries; moist gangrene in imprisoned temporary molar. (Skiagraph by Hagopian from editor's case.)

Fig. 521

Moist gangrene. Skiagraph of unfilled root canals with large mass of filling material built in over them. (Price.[1])

In doubtful cases, such as that shown in Fig. 521, the *x*-ray skiagraph is valuable, and indicates at least the removal of the filling for further diagnosis and treatment. When dentin is insensitive, pulp death should be suspected.

A strong odor of putrefaction may be obtained from bur cuttings in cases of moist gangrene only. This must be differentiated from

[1] Items of Interest, 1901.

the odor of decayed dentin, which usually also has an acid character. In case of partial death of the pulp not discoverable by the tests given above, a fine, sharp probe passed into contact with the pulp remnant will demonstrate its vitality.

Treatment.—If septic matter be introduced a violent pericementitis may be lighted up; but if aseptic precautions be employed in opening the canal, and this be kept under the influence of a germicide, such as 5 per cent. formaldehyde or sodium dioxid, the root may be filled. A dressing of formocresol may be introduced for a time and the root then filled.

A temporary filling of pink base-plate gutta-percha is to be inserted in the crown cavity until all irritation, if any, subsides.

Slight aseptic apical irritation may be anticipated as a matter of precaution by the use of iodin as a counterirritant at the time of root filling (see p. 476). Such irritation is either mechanical or due to the chemical substances used.

MOIST GANGRENE OF THE PULP.

Definition.—By moist gangrene of the pulp is meant death of pulp tissue *en masse* and its subsequent decomposition by the action of putrefactive agencies. As putrefactive decomposition is the essential feature in these cases, and that which gives the process its pathological significance, the causes, nature, effects, and treatment of putrefactive decomposition of the pulp are included under this subheading.

Causes.—The causes of moist gangrene are such as may cause the death of the pulp and its subsequent decomposition by bacteria. Without bacteria putrefaction cannot occur. Among these the Bacillus gangrenæ pulpæ (Arkövy) figures prominently.[1] Four types of cases are seen: (1) In teeth apparently sound; (2) in teeth filled, but the canals not treated—*i. e.*, death of the pulp has occurred after filling; (3) in teeth filled with canals partly filled; (4) in teeth having open cavities and canals.

In the first type of cases the bacteria may enter by way of the blood channels, but it is not improbable that slight cracks or histological defects in the enamel may admit to the dentinal tubules the necessary bacteria, or that they may gain entrace by way of the cementum and dentin at the neck of the tooth. (See Caush's Tubes). The inference is similar in case of trimmed crowns of teeth underlying gold caps.

[1] Siberth and Goadby regard this microörganism as a variety of Bacillus mesentericus, probably "niger." Mycology of the Mouth, p. 148.

A case presenting some analogy to these teeth is that of an egg with apparently perfect shell, but in which intense decomposition has occurred. That the gases and other odorous products are somewhat confined the author proved to his dismay as a boy by smashing with a hatchet one found in the brush.

Many of these teeth do not develop abscesses even after the tooth has become dark in color; perhaps the bacteria are killed by their own products. If the dentin be exposed, as at the incisal edge, the abscess may develop. The entrance of air or beginning of treatment often starts an abscess unless treatment is instituted.

FIG. 522

Pigment. Sulphur + hemoglobin.

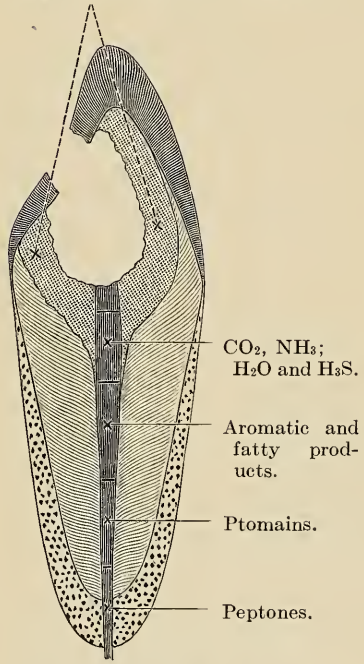

Diagram illustrating the more complete decomposition of the pulp at its coronal end.

In the filled cases crevices about crown and root fillings may admit bacteria, which may pass through the tubules of even secondary dentin in some amount. On the other hand, it is irrational not to admit the possibility of an infection *via* the circulation.

In cases of obvious pulp infection beneath fillings—*e. g.*, suppuration of the pulp—the bacteria necessary are *in situ*.

In the open cases the infection obviously arises from the mouth.

Pathology and Morbid Anatomy.—The pulp being wholly or partly dead from any cause whatever, saprophytic bacteria gain access to it, and the serial decomposition it undergoes is in exact correspondence with that of moist gangrene or putrefaction in other localities. In this serial decomposition albuminous substances are first transformed into peptones and allied substances, some of them being very toxic. Compound ammonias, known as ptomains, or animal alkaloids, such as putrescin, neuridin, and cadaverin, are probably next formed. Next the nitrogenous bases—leucin, tyrosin (amido-acid), and the amines (methyl, ethyl, and propyl)—make their appearance, together with organic fatty acids, Next aromatic

products, indol, phenol, cresol, etc., and finally hydrogen sulphid, ammonia sulphid, carbon dioxid, and water. By alternating processes of hydration, reduction, and oxidation, bodies of increasing simplicity of chemical composition are formed. "Fermentation and

FIG. 523

FIG. 524

FIG. 525

FIG. 526

FIG. 527

FIG. 528



FIG. 529

FIG. 530

putrefaction can only occur where the fungi concerned live and the extent of decomposition is conditioned by the number of fungi."[1] The contents of the tubules (fibrillæ) also are putrefied. These

[1] Ziegler: General Pathology.

products are derived from the following chemical constituents found in normal pulps, according to Hodgen: Proteins and albuminoid, fibrin, hemoglobin, collagen, elastin, fats, tripalmitin, stearin, and olein.

The irritant bodies are probably the gases and ptomains which have experimentally been found capable of producing suppuration in the absence of bacteria.

Miller[1] found, in the deepest portions of the degenerating, putrefying pulps, where inflammation and suppuration were in progress a preponderance of small cocci and diplococci, and proceeding toward the open pulp chamber an increasing number of large cocci, several forms of bacilli, vibrios, and other spirillæ, spirochetæ, and long thread forms (Figs. 523 to 530). Figs. 529 and 530 are from the same pulp; Fig. 524 was taken from the radicular portion of a pulp which was alive and suppurating; Fig. 529 was from the putrid crown portion. Miller found that bacteria of pulp putrefaction cultivated in gelatin, with and without the access of air, exhibited a difference in the poisonous properties of their products. Those developed with free access of air produced stronger reaction, and more extensive suppuration than those developed without the access of air.

Arkövy,[2] in an examination of 43 cases of chronic apical abscess, pulp gangrene, etc., found the Bacillus gangrenæ pulpæ present in 41; the Staphylococcus pyogenes aureus in 15; Staphylococcus pyogenes albus in 8; Staphylococcus pyogenes citreus in 2; Streptococcus pyogenes in 10, and Bacillus pyocyaneus in 4.

He found the Bacillus gangrenæ pulpæ in mouths free of caries as well as in mouths containing carious teeth, and established the fact that it is pleomorphous (bacillus and coccus form).

He inoculated healthy pulps with this bacterium, and found that in pure culture it produced total gangrene without suppuration; while mixed cultures, and even the mixed pleomorphic forms of the same bacillus, produced chronic pulpitis.

On gelatin cultures a putrid, cheese-like odor was perceptible. The germ is subject to the antiseptic effects of strong acids, alkalies, carbolic acid, and tincture of iodin, which explains, in part, the success of the treatment hereinafter mentioned.

Arkövy's demonstration seems a satisfactory explanation of cases of quiet death of pulps under fillings.

The hydrogen sulphid combines with the HN_3 of proteid origin, to form ammonium sulphid $(NH_4)_2S$, which, again, combines with the iron in the hemoglobin of the red corpuscles, producing ferrous

[1] Dental Cosmos, 1894.

[2] Synopsis by Söderberg: Dental Cosmos, 1899.

sulphid, Fe_2S, which darkens the decomposing tissue, and, entering the tubules, stains the dentin a slate-gray or bluish-black color. Other derivatives of hemoglobin may be responsible for the yellowish brown discoloration often seen in cases in which bacteria have not reached the pulp until long after pulp death. The color is, therefore, not due to the presence of hydrogen sulphid.

Miller[1] found that the reaction in cases of putrefaction was *alkaline* unless a certain percentage of sugar was introduced into the medium, when it was *acid*. He explains the voluminous foul odor of confined dead pulps as due to the absence of oxygen of air. If present as in open pulp cavities the gases escape, the volume being therefore reduced, oxidation of gases increased, and an acid reaction due to entering carbohydrate permitted. The exact nature of pulp decomposition is in some doubt.

Fig. 522 is a diagram illustrating these changes; it being assumed that the decomposition is most advanced at the crown portion of the pulp, owing to the entrance of bacteria at that point.

In the early stage of the process the gangrenous pulp resembles a yellowish mass of sloughing tissue, with reasonably tough consistence, which can be easily removed. In the later stages it is more decomposed and dark and jelly-like, and yields to the broach. Naturally the greatest number of fungi will have, by multiplication, invaded and putrefied that end nearest the source of infection, while the more consistent (less putrefied) portion of the pulp will exist at the apex. In the final stages nothing but fluid, or even an almost dry canal, may be found. This last condition must not be confounded with dry gangrene. If fluid, or odor without fluid, be present the case is one of moist gangrene.

Gangrenous pulps do not necessarily produce abscesses at once, but often clinical history shows that a year or two, or even more, may elapse, though as short a time as two or three weeks has sometimes been sufficient. In one case of a boy, aged ten years, the time between a capping of a bleeding pulp with Jodoformagen and the presence of a fistula upon the gum was but two weeks. It was, however, in a temporary first molar, and the cement covering the cap was found to be loose.

The forcing of gangrenous pulp tissue by instrumentation into apical tissue generally results in an abscess, even when extraneous bacteria are presumably not introduced.

The irritating substances in a decomposing pulp are presumably the bacteria, the ptomains, and the expanding gases.

[1] Microörganism of the Human Mouth, 1890

Many decomposed pulps produce no pain, but in these cases the gases may escape *via* dentinal tubules and leaks about fillings (Fig. 521).

Clinically, putrefactive pulps may be found in sound teeth, in filled teeth, and in teeth the pulp cavities of which are open to the oral fluids, either actually or through the medium of open tubules in the dentin over them, or in apical portions of poorly cleansed or partly filled canals. A cotton dressing having a bad odor, or an apparently empty apical portion of canal or a leaky gutta-percha canal filling associated with a bad odor, even though the pulp has been successfully removed, have a similar pathology. There is little difference in principle between putrefactive serum or tubule contents and a putrefactive pulp. Any of these may cause abscess or remain quiescent.

Symptoms.—The symptoms are opacity of the tooth evident to the eye or noted by transmitted light, bluish or brownish discoloration of varying degrees, odor, and discoloration of the dentin in a cavity.

There is a lack of response to cutting, thermal, and electric tests. Sometimes a bad taste due to leakage about fillings is present. Upon drilling out a filling the odor of putrefaction may be clearly noticed even before entrance of the canal, and sometimes rises to the operator's nostrils. The odor of the bur cuttings is diagnostic in less pronounced cases. The gases may be present in quantity without symptoms of pain. Looseness, tenderness to percussion, incipient and acute abscess, or a chronic fistula are evidences of pericemental irritation.

Pain to heat, while usually indicative of pulp irritation, also sometimes occurs, and is explainable upon the same theory of the expansion of gases against vital tissue—in this case the apical tissue. These symptoms are all explained by the pathology of the condition.

A confusing condition clinically is found where one-half of a pulp has died and undergone decomposition, as in molars, the other half remaining vital, although the seat of infection and inflammatory action. So far may this condition go, that abscess, acute or chronic, may be present upon the root of one tooth long before the second segment of the pulp has succumbed. The diagnosis of such cases is made by the light test, by obtaining the painful reaction to heat and perhaps to electricity, and usually some tenderness upon percussion upon some particular portion of the tooth; upon opening the tooth the peculiar condition described is found. The *x*-rays should show the condition.

In one case of a lower molar with a fistula related with the distal root I found the pulp apparently vital upon entering the pulp chamber

with a bur at a point about midway between the horns. There was apparently a persistence or hypertrophy of the pulp bulb attached to the mesial filaments. The distal canal was found to contain only the fluid remains of a dead pulp filament. In cases seen at the right time the bulbal half of a pulp may be gangrenous without positive putrefaction, while the apical half is still vital.

J. H. McQuillen[1] recorded a case of longitudinal fracture of a bicuspid tooth extending from the sulcus to the bifurcation of the roots, and which was apparently due to the expansion of the gases of decomposition. Poinsot[2] records a similar case, and states that several teeth containing decomposed pulps confined in a glass tube caused the latter to break.

FIG. 531

Tooth split by gas. (Roff.)

Dr. S. H. Roff,[3] of Cincinnati, Ohio, has presented the case shown in Fig. 531. He had it under observation for seven years. He regarded the case as one of slow progressive cracking (a run) with final irritation and death of the pulp and the final clean longitudinal fracture as due to the gases from the partially decomposed pulp. When one considers the fact that wet plugs of soft wood will split granite boulders we must accept the possibility of tooth fracture by gas pressure.

Observations previous to that of McQuillen have recorded a sound, as of an explosion, to have occurred simultaneously with the fracture of the tooth. I have looked all my professional life for such a case, but though I have seen quite a number of clean fractures I have never been able to eliminate the possibility of fracture from ordinary causes and in some of the cases have had positive histories of direct violence.

Treatment.—The pulp being presumably infected, all quiescent gangrenous pulps or putrefactive conditions under any conditions

[1] Dental Cosmos, 1871.
[2] Ibid., 1901.
[3] Items of Interest, March, 1912.

discovered indicate a similar treatment, namely, first disinfection to remove or kill bacteria which might cause an abscess and at the same time to destroy the chemical nature of the gases and ptomains. After this the canals are to thoroughly opened, cleansed, further disinfected for the sake of surety, and later filled.

Three substances are preëminent in this direction—(1) formaldehyd, (2) nascent oxygen, (3) iodin or its derivatives.

At the present writing no substance equals formaldehyd, because of its rapid diffusion as a gas through all canals, tubules, and even abscess tracts.

The first and best treatment consists in opening the pulp cavity and gently removing the bulk of decomposed pulp from the pulp chamber and canals, care being employed to avoid forcing any putrid material into the apical tissue by broaching or plunging of the bur. Also, no bacteria should be introduced from outside. The opening should not be too freely made, and should be funnelled or countersunk outwardly to secure the seal against being plunged into the pulp cavity in mastication (Fig. 532).

This being done, the canals are dried with cotton and hot air, and a small pellet of cotton saturated with formocresol or 10 per cent. aqueous formaldehyde solution, or geranium formol[1] is to be placed in the pulp chamber.

℞—Formaldehyd . . . . . 40 parts
Essence of geranium, distilled . . . . . 20 parts
Alcohol 80 per cent. . . . . 40 parts

Any that has come in contact with the orifice should be removed with alcohol. The orifice is then dried and a small piece of dry spunk placed over the application, but not so as to interfere with the seal. Quick-setting, adhesive, hydraulic cement is now flowed into the orifice, air bubbles being avoided by flowing it in with an instrument (Fig. 532). A bit of paraform accomplishes the same purpose as the solution, namely, the liberation of formaldehyd gas.

When opportunity for self-relief seems proper, as when the operator is leaving his practice for a short time, or may otherwise be inaccessible, hot temporary stopping may be used and the patient instructed as to the proper procedure to obtain relief. An ordinary pin crooked at the point by striking it across any hard surface will serve to pick out the stopping and cotton. In all cases tight coverings must be made, as the object is to concentrate the action of the formaldehyd gas upon the canal and tubular contents.

In some cavities it is well to make the covering first, as done for

[1] Geranium-formol introduced by André and de Marion, l'Odontologie; abstract by International Dental Journal, 1901.

arsenic (see Fig. 453), and to seal the dressing in with a further addition of cement or temporary stopping. The latter does not permit mastication like the former.

Fig. 532

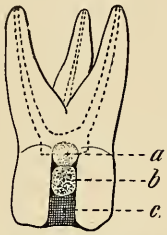

a, cotton and formocresol; *b*, spunk; *c*, cement.

Fig. 533

Cervical wall built up with amalgam to permit canal sterilization and treatment.

If there be a broad cavity extending beneath the gum, it is well to press the gum away with cotton pellets, then to form the cavity and open the canal orifices. Then a retention at the cervical portion of the cavity should be made, even if it be necessary to drill a series of pits along it with a No. 1 bur. Spunk is now placed over the pulp canals and quick-setting amalgam is to be permanently built in at this part of the cavity. When set the spunk is withdrawn, formocresol in cotton is placed instead of the spunk, and the covering completed with cement. The amalgam is finished as far as practicable at the one sitting, and the case dismissed. At future sittings the rubber dam may be applied and the canal work done (Fig. 533). When cavity walls are frail, spunk may be placed in the pulp cavity, and a permanent cement lining built into the cavity. This can be perforated to the spunk, thus leaving the walls supported during the treatment.

Formocresol, introduced by Buckley, consists of equal parts of 37 per cent. aqueous formaldehyd solution and cresol, which combine well.

According to Buckley, the formaldehyd not only acts as a germicide, but combines with the ammonia of ammonium sulphid to form urotropin and water, $6CH_2O + 4NH_3 = (CH_2)_6N_4 + 6H_2O$, and with hydrogen sulphid to form sulphur and methyl alcohol, $2CH_2O + 2H_2S = S_2 + 2CH_3OH$. The cresol is supposed to act upon the fatty compounds, changing them into a compound resembling lysol. Thus, antiseptic substances are formed from poisonous ones. This does not necessarily represent all the reactions occurring, as many other compounds may result from putrefaction. The probability is

that the thoroughly bactericidal action is the one of greatest value. This action has been shown by Mayrhofer to be true only for the first twenty-four hours; thereafter the bacteria in the tubules may grow back into the canal and the dressing, in spite of the fact that the odor of the dressing is present. The canal should therefore be mechanically cleaned after twenty-four hours, and a fresh application be made.[1] Mayrhofer claimed inability to sterilize permanently with formocresol. Nevertheless the editor treats such cases at wide intervals ordinarily with impunity. In a few cases an abscess has supervened after the first dressing, but none as yet after the second. Leakage of the formaldehyd gas may have been the reason, but a chronic apical abscess in the third stage (which see) has been a suspicion. Cleansing and reaming the canals at the first sitting is another danger, even when formaldehyd is subsequently used. This must sometimes be done as when a crown is broken away and the root canal is foul.

Formaldehyd is so efficacious in the writer's hands that it has displaced other methods in his practice. All other methods of disinfection produce results less certain than those produced by it, and are more cumbersome, therefore they will be here dispensed with. While this is true for a great majority of the cases, occasionally a patient is met with whose tissues do not tolerate formaldehyd well. Formocresol then should be reduced to a 5 per cent. solution with cresol or phenol camphor, and in some cases abandoned for more sedative antiseptic remedies, such as eugenol or phenol camphor with menthol or thymol or iodoform may be tried.

This first dressing may be left for from twenty-four hours to a week or longer if the patient is comfortable.

At the second sitting the rubber dam is to be applied and the canal opening thoroughly made under formocresol influence, just as though the pulps were vital, the technique differing in no respect. (See pp. 532 to 548.) A second dressing is introduced into the canals. Whether this shall carry the full strength formocresol or it shall be modified by the addition of cresol or phenol camphor depends upon the history of any irritation or perfect comfort as a result of the first application. The object of a second dressing is to determine whether the odor (gases) has been discharged from the tubules. When the dressing has absence of putrefactive odor, no pus can be detected, and the patient is comfortable, the canal is ready for filling. Less than this result is too soon, and delay beyond this is a loss of time.

[1] Viulleumier: Items of Interest, March, 1910.

When one pulp filament is gangrenous and another vital, the treatment is the same, it being the writer's experience that formocresol loosely placed is not incompatible with ulcerated pulps, and, indeed, is an excellent dressing for suppurative pulps when modified to a 3 to 5 per cent. strength; even full strength has been acceptably used. Later, the vital portion is appropriately removed.

When apical pericementitis of a subacute nature is present on a filled tooth, as when a tooth shows some looseness and tenderness, with some injection of the gum, all faulty root canal fillings should be removed with barbed broaches, cleansers, or root reamers, and the case is then resolved into one of moist gangrene and treated accordingly.

Wax may be removed by over heating with the hot root drier and absorption with cotton, or oil of cajeput may be used as a solvent. Paraffin may be removed in like manner, xylol is a solvent.

If a cotton root filling be found it sometimes allows the broach to tear loose. In such case a Kerr broach is driven into it to create a central opening, after which the fibres become engaged by the barbed broach.

Eucalyptol or chloroform may be used to soften gutta-percha root canal fillings, and at times the smallest Kerr or Downie broach is to be bibevelled at its end and used as a drill, cutting its way. Oxychlorid and other cement fillings may have 50 per cent. sulphuric acid or strong ammonia water applied to them to assist in breaking up the bond of the cement by chemically destroying either the zinc oxid or the acid. The drill will tamp the fluid into the cement and cut the cement at the same time.

All root fillings of cement nature are apt to be faulty when used as such, because the air in the canal prevents ingress, though it may appear to be well filled. This fact is of importance in diagnosis in filled teeth, giving evidence of chronic pericementitis, *i. e.*, there is probably an unfilled portion of root canal containing putrefied pulp or serum.

It is a weakness of many good operators, if not all, to think that their individual canal fillings are perfectly made. The writer was once associated with a most conscientious man, and possesses a gutta-percha canal filling of his in a molar now successful for twenty years. On one occasion he declared that he had filled perfectly a canal of an upper second bicuspid, because the material had been felt by the patient as it reached the apex. Two weeks later the tooth was extracted, though comfortable, for orthodontic purposes. Its well-opened canal was empty for a quarter of an inch at the apex.

To remove pins from roots a bibevelled Kerr broach may be driven

into the cement or dentin about it and the drifts united. The pin may often be forced to one side and then jigged loose. If there be sufficient pin extending above the face of the root a "pin puller" may be used. If the pin cannot be loosened it must be drilled out bodily. A sharp round bur should be used to countersink the end of the pin, and then by the aid of oil it is cut into shavings. Frequent desiccation and examination to observe the presence of a metal remnant is necessary to avoid the accident of perforation.

In drying with the compressed-air syringe, care should be employed to avoid extensive emphysema of the cheek, which may be induced by intense pressure. If it occur, the emphysema should be reduced by manipulation, with a view to gently forcing the air back through the root. Christensen[1] and L. Greenbaum have each reported a case, and the editor had his first case when desiccating an accidental lateral perforation. This occurred even without close application of the syringe nozzle, 35 pounds pressure being used.

Another case occurred while an upper lateral with large apical foramen and even with an open fistula was being dried out. The entire right cheek and lower eyelid was instantly puffed up. The patient called attention to a stiffness and coldness. It subsided upon manipulation. There might be dangerous sequelæ if sepsis were present.

The immediate treatment of canals containing gangrenous pulps may at times be necessary. The mechanical work should be done while the canal is flooded with formocresol, and embalming paste containing paraform should be used with gutta-percha canal points, or sometimes on cotton twists.

If any inaccessible portion of root canal remain it may be treated according to Rhein's method. (See p. 539.)

Root sterilization may be immediately attempted after the rubber dam has been placed and the crown washed with 5 per cent. formalin or alcohol and water.

A little dry sodium dioxid is placed upon a slab with a drop of water near it. A broach is drawn through the water, then through the powder, and the adherent powder carried to the canal and gently passed into the moist putrid contents of the canal; a reaction occurs between the water and sodium dioxid as follows: $Na_2O_2 + 2H_2O = H_2O_2 + 2NaOH$, producing hydrogen dioxid and sodium hydrate.

The sodium hydrate or lye saponifies all fatty matters and destroys organic matter, even living matter, and the hydrogen dioxid liberates nascent oxygen, which is a disinfectant. No oil or phenol

[1] Dental Cosmos, 1904, p. 151.

should be used with dry sodium dioxid, as an explosion may occur. The use of the alloy kalium natrium in a moist canal causes an oxidation of the metals by the O of the water, flame being the result of ignition of the hydrogen. Sodium and potassium hydrate are formed.

The result of the reaction should be washed out with a gentle stream of warm water, while a broach is gently passed to and fro through the mass. The action is then repeated as far as it can be carried.

The danger in the use of these materials lies in the possibility of the production of a chemical inflammation of the apical tissue, due to the nascent hydrates, if the foramen be open, which inflammation may be severe, or in the possibility of a non-sterilization of the contents of inaccessible canals. For this reason it may be well in fine roots to follow with the Rhein method, or to use a formalin solution for the purpose of completing the sterilization in the more open roots, and 20 per cent. formalin or 25 per cent. ethereal pyrozone (H_2O_2) for the finer roots.

Following this the root filling is either attempted immediately with removable antiseptic root fillings or a dressing of 5 per cent. formalin introduced into the dried canal for a few days.

Any irritation of chemical nature may be treated in anticipation by the use of counterirritants applied to the gum. While this may be done in some cases the occasional production of an abscess leads the editor to strongly advise the first treatment suggested. The writer on a Monday lanced an acute abscess on a cuspid treated with kalium natrium by a clinician at a clinic on Saturday. Opening the canals under antisepsis with formocresol kept in them while broaching, etc., is an even better immediate method, but still not so good as twenty-four hours' sterilization, then free opening.

The filling of canals by driving wood points saturated in carbolic acid into the infected canals, forcing carbolic acid by pressure into the apical tissue, and the filling with gutta-percha are all successful in many cases; but there is much likelihood of apical abscess, or, at least, of traumatic or chemical irritation, which it requires much courage not to undo, with a patient complaining, and some doubt as to whether an abscess will result, so that more gradual yet thorough work is advisable, at least for the young practitioner who must retain the confidence of the patient.

Hoffendahl,[1] of Berlin, has extended the demonstration of Zierler and shown that the constant galvanic electric current from a battery

[1] Dental Cosmos, 1905.

of from 30 to 40 Leclanche cells to overcome the resistance of the tissues will electrolytically decompose 0.75 per cent. sodium chlorid solution and drive nascent chlorin, H_2O_2, and oxygen through even fine root canals and into the infected tissue about an abscess cavity. Thus, electrolysis and cataphoresis are brought into play. The current does not pass through the side of the root; a street or central direct current with a rheostat attachment reducing the current to from 0 to 80 volts is equally effective.

The tooth should be rubber dammed to insulate the gum. The canal should be carefully cleansed, so as not to permit ptomains to pass into the apical tissues, and then filled with a sodium chlorid solution. A fine platinum electrode is introduced into the moist canal, and must be attached to the positive pole of the battery. A large moist negative electrode is to be applied to the hand to lessen resistance and conduct the current to the negative pole of the battery. The size prevents uncomfortable sensations about the tooth. The rheostat should be manipulated so as to introduce the current gradually until about 1.5 mi. is recorded on the meter, and should be continued for five minutes. An antiseptic dressing is then inserted, and a few days later the current is repeated to destroy any bacteria developed in the interim, when the root may be filled. Hoffendahl employs a paste of paraform, thymol, oil of cloves, and zinc oxid packed by means of asbestos fibres.

In experiments in conjunction with W. D. Miller they found 0.6 mi. passed for ten minutes through a putrid pulp to which pure cultures of germs were added, sterilized the pulp so that agar cultures failed; canals of multirooted teeth are best treated separately.

The principle involved in immediate sterilization is the destruction of all septic matter within the canal and beyond the apex at the first sitting.

After the canal disinfection is accomplished by one or more of the various immediate means suggested, its walls should be desiccated and made absorbent by means of hot air, then moistened with eucalyptol or forma-percha, and a root filling of temporary stopping or gutta-percha packed in. If aristol be added to these the effect is increased. Cotton and formo-percha make a readily removable filling suitable to cases in which some doubt exists. I have had excellent results in molars with this material. (See p. 551.) A temporary filling of base-plate gutta-percha is then placed in the crown cavity as a test filling, or, in case of need, the filling may be inserted.

Any apical irritation may be attributed to the disinfectant and be treated by counterirritation, or the counterirritant may be applied as a precaution at the time of operation. Refrigeration of the gum

over the root by means of ethyl chlorid is a valuable means of reducing inflammation in these cases. This traumatic irritation is often mistaken for acute septic pericementitis. Any irritation not too severe is to be considered as due to non-septic causes and treated accordingly. A few of these cases may, of course, result in failure owing to imperfection in the application of the method. The great majority of cases are successful. Still, if one desire still fewer failures, employ the first method.

The withdrawal of the cotton dressing in the tentative method should be done under aseptic precautions. There may be found no collection upon cotton. In such case a fresh twist on a Swiss broach should be passed to the apex to determine its condition. If nothing be found the root may be dried and filled unless odor be present, when the root should be resterilized before filling, or the dressing renewed.

Active hemorrhage may ensue or serum may ooze from the apical tissue. This may be checked with 25 per cent. pyrozone, adrenalin chlorid, 1 to 1000, or, preferably, alum and thymol, and the root filled.

If the apical foramen be a large one, and if a pus flow follow the removal of the temporary dressing and be but slight, the pyrozone or zinc chlorid (or both) should be used and the root filled. The condition is one of apical abscess without fistula, and is often amenable to immediate root filling. If, however, this be not considered advisable, the temporary dressings may be renewed, though often without benefit. Sometimes a thick, glairy fluid will ooze from the apical tissue. This is coagulable lymph, and the parts require treatment in the same manner as when a slight amount of pus is present. The principle involved in the departure to an immediate method of treatment is based upon the thorough sterilization of the apical tissue, the sealing of the canal to prevent infection from the mouth, and the prevention of effusions from the apical tissue into the canal. This done, the apical tissue is expected to care for itself.

In order to prevent apical irritation in so far as possible, the gum is to be painted with ordinary tincture of iodin or spotted with the dental tincture of iodin, both lingually and buccally, as a counter-irritant.

℞—Iodin . . . . . ʒiij
Alcohol . . . . . ʒj
Shake frequently for a week or two. (Flagg.)

If infection of the apical tissue by any chance ensue, either as the result of the operation of canal cleansing or previous to operative

interference, the disease known as septic apical pericementitis is established.

Pericementitis following the opening of teeth containing gangrenous pulps has been explained upon the ground that the bacteria in the absence of free admission of oxygen have lost their virulence, which is restored when the air is admitted. It is quite likely that either this is true or that extraneous bacteria are introduced during the course of treatment.

In case of partial moist gangrene in which a portion of a filament is gangrenous and the balance of it vital, or in which one root filament is dead and the other vital, the treatment must be varied to suit the requirements. The dead portion is removed as described and the living portions treated as ulcerated pulps. (See p. 496.)

In a few cases the continuity of the canal has been lost because it has become involved in caries upon one side of the root. This may be treated as described on p. 432.

Discoloration of the Teeth by Moist Gangrene.—In the final decomposition of the pulp a pigment molecule is formed, which, entering the tubules or formed in it, stains the dentin and imparts an abnormal color to a portion or nearly all of the crown, which ranges from an almost imperceptible loss of translucency to a yellow-brown, slate-gray, or bluish-black color. Also in conditions of venous hyperemia or pulpitis, with which venous hyperemia (stasis) is associated, the escape of the red corpuscles into the tissue, their disintegration, and the solution of the hemoglobin then occurs, and the solution enters the tubules, staining the dentin a pink color, which soon passes into a purplish rose, and finally becomes bluish-black or slate-gray.

Those cases resulting in the yellowish or brownish coloration are usually associated with the loss of the pulp in comparatively sound or totally sound teeth, the loss occurring probably through traumatism or through slow atrophic changes, such as occur in the formation of pulp nodules, secondary dentin, apical constriction, etc. Apical abscess is often much delayed, but sometimes occurs, showing that pulp decomposition or a later infection has occurred. The demonstration by Hopewell-Smith of fibrosis of the pulp and the obliteration of vascular structures may account for a lessened vascularity, and the absence of the production of iron sulphid because of the absence of necessary putrefaction and the production of the hematoidin products, as shown below. The first class of cases occurs either in sound teeth in which the pulps have died by traumatism, or in filled teeth with pulps not exposed, or in teeth the pulps of which are exposed to the fluids of the mouth, permitting putrefactive

agencies and extraneous coloring or color-setting materials to enter. This discoloration is most rapid in the exposed cases.

These color changes are rationally explained by Kirk[1] as due to the decomposition products of hemoglobin existing in the pulp at the time of its death, and having an analogue in the pigmentary degeneration occurring in the hemoglobin in a bruise (extravasation of blood), in which the part becomes, first, "black and blue," then passes through a series of color changes, in which yellow, green, and bluish-black are notable. These are due to new chemical compounds which crystallize in the tissue. These compounds are divided into two classes: Hemosiderins, or those containing iron, and hematoidins, those without it. Each class of these has several distinct substances in it, each having its own color molecule.

Kirk states that methemoglobin is brownish-red, hemin bluish-black, hematin dark brown or bluish-black, and hematoidin orange.

Jakob (Stengel) gives light pea-green and brownish-red as the colors of hematoidin for an old hemorrhagic focus, showing a probable slight chemical variation in the composition of the color molecule.

As the color changes in a bruise are effected under aseptic conditions, and usually the colors finally produced are lighter than the "black and blue" first resulting, it is rational to suppose that the yellowish or brownish discoloration of teeth results under such conditions of aseptic decomposition (probably autolysis). These colors, as remarked by Kirk, are more or less permanent.

When a permanent or progressively darkening slate-gray or bluish-black color is produced, it is considered by Kirk to be due to the formation of iron sulphid or an analogous product in which iron and sulphur are constituents, and that it is analogous to the black discoloration occurring in the visceral walls of animals undergoing putrefactive decomposition. The iron is liberated from the hemoglobin present by putrefaction, and combines with the ammonium sulphid which is formed from the ammonium and hydrogen sulphid produced by the putrefactive decomposition.

Treatment.—The treatment of discolorations consists in what is known as the bleaching process, which means the reduction of the color molecule to another chemical molecule which is colorless, and then washing that out of the tubules. This is usually done by the use of chemicals which directly supply a molecule of nascent oxygen when coming in contact with the putrefactive material or its product, the color molecule; or which, as chlorin, abstract hydrogen from the water present and so liberate a molecule of nascent oxygen, which combines with the color molecule. These are direct or indirect

[1] American Text-book of Operative Dentistry.

oxidizing agents, the effect being the same, *i. e.*, an oxidation of the color molecule. A second class, as sulphurous acid, which abstract oxygen from the color molecule, are called reducing agents, and may be effective when the oxidizing agents fail.

In the use of bleaching agents the canal should have been cleansed and disinfected with a simple aqueous solution of formalin or 25 per cent. ethereal pyrozone, or an aqueous solution of hydrogen dioxid, or with sodium dioxid, all oils or other materials likely to complicate the color molecule being avoided. With the exception of formalin, these are also bleaching agents and to an extent aid the subsequent operation. Formalin would best be avoided in cases of recent pulp death, as it may harden the undecomposed fibrils in the dentin. The upper half or two-thirds of the canal should then be filled with gutta-percha or oxychlorid of zinc, leaving the crown and one-third of the root dentin to be bleached.

After accurate rubber damming the most valuable and facile method consists of placing a pellet of cotton saturated with 25 per cent. ethereal pyrozone in the pulp chamber and sealing it after careful drying of the lingual tap or cavity orifice by dropping soft, quick-setting cement upon the margin and sealing the entire tap.

The rubber dam should not be removed until the cement has set, as the ether or oxygen gas may cause it to bulge or blister. This is then allowed to have twenty-four or even more hours of action, when, if necessary, it may be removed. The operation may be watched at the first or the second sitting if desired, though it may be somewhat prolonged.

Aqueous 25 per cent. pyrozone may be made by shaking together in a test-tube one volume of distilled water and two volumes of 25 per cent. ethereal pyrozone and evaporating the ether, the H_2O_2 being left in aqueous solution; the addition of sodium acetate or sulphate assists the passage of the current. This is introduced by means of the cataphoric current, the positive pole being in the tooth, the negative at the hand. Occasionally the reversal of the pole succeeds after failure, the tubular contents probably being discharged with the H_2O_2 present in them.

Oxygen may be liberated from sodium dioxid (Na_2O_2) by sulphuric acid. A saturated solution of sodium dioxid is made by surrounding a small beaker containing about 2 drams of distilled water, with cracked ice. When cold the sodium dioxid powder is to be slowly dusted into it until it assumes a semi-opaque appearance, indicating saturation. In use the dried dentin is saturated with it, asbestos fibre being used to carry it to place, and 10 per cent. sulphuric acid is used to produce the liberation of oxygen with the following equation: $Na_2O_2 + H_2SO_4 = Na_2SO_4 + H_2O_2$.

The effervescence forces the tubular contents out. The sodium dioxid acts upon putrefactive material, decomposing it, and also saponifies fatty matters.

If the operation fall short of success, this is due, in Kirk's opinion, to the formation of iron oxid, which can be removed with oxalic acid by sealing a crystal of it in the pulp chamber for twenty-four hours.

The tubular contents being entirely removed by the sodium-dioxid method, the tooth is more translucent than by other bleaching methods in which the bleached organic debris remains in the tubules.

The chlorin method, introduced by Truman, depends for its efficiency upon the affinity of chlorin for hydrogen, forming hydrochloric acid (HCl). Finding this in the water, it liberates nascent O, which oxidizes the color molecule, or, possibly, it abstracts H from the organic matter. The chlorin is usually evolved from chlorinated lime, that sold in paraffined paper cartons or glass bottles being the best. That sold in metal cans is often contaminated by the metallic chlorids.

The dry powder is packed into the cavity, moistened with 50 per cent. acetic acid, and sealed in with oxyphosphate or temporary stopping for one or two days, and repeated if necessary. Only vulcanite, bone, ivory, or wood instruments should be used, as metal instruments are acted upon by the chlorin. All gold or metallic fillings should be removed for the same reason, and if their removal would cause hardship or so render the tooth into a condition indicating crowning, either this should be done or the direct oxidizing method tried.

The liberation of sulphurous acid may be induced from a powder consisting of a mixture of sodium sulphite, 100 grains, and boric acid, 70 grains, separately desiccated and afterward ground together in a mortar, by acting upon it with a drop of water. The cavity is stopped by a plug of gutta-percha previously prepared and warmed. The following reaction occurs:

$$2H_3BO_3 + 3Na_2SO_3 = 2Na_3BO_3 + 3H_2O + 3SO_2.$$

In all the methods, except the use of Na_2O_2, the apex of the canals should be sealed before and after bleaching; at least 1 pint of hot distilled water should be forcibly injected into the tooth to dissolve out all products of chemical action remaining in the tubules, a towel being used to catch the drip. The tooth is then thoroughly dried, and if any organic matter may be present in the tubules the pulp cavity should be thinly lined with oxychlorid of zinc to coagulate it. If it has been removed, as in the sodium dioxid method, leaving the tubules empty, they should be filled with cavitin varnish after

desiccation to promote absorption, and the thin lining then placed. A temporary filling is to be inserted over this until success is evident, when the permanent work is completed with zinc phosphate and a metal filling.

The removal of metallic stains has been referred to on page 335.

Moist Gangrene of Pulps of Temporary Teeth.—The same considerations pertain to moist gangrene of the pulps of temporary teeth, but as the roots are resorbed to some extent or are to be resorbed, the root filling should be of such a character as to permit its resorption. Probably a combination of paraffin and aristol will best fulfil the indications. An iodoform paste is preferred by some. (See Root Canal Fillings.)

If the roots be much resorbed, it is better to use a material which will permit venting of the tooth if necessary. The canals and pulp chamber may be filled with a combination of vaselin and aristol, and this covered by a filling. If trouble arise, a spear drill is driven into the pulp cavity from a point beneath the gum margin, establishing a vent. The patient should be instructed to keep this open, and be furnished a Swiss broach for the purpose.

At an age when the permanent tooth will shortly thereafter erupt, extraction of the temporary tooth is often to be preferred to treatment.

Root-canal Work in Cases of Gangrenous Pulps Involving Future Consideration.—In some cases of doubtful root sterilization or filling, and in which crowning by means of dowelled crowns is a necessity, provision may be made for future relief or treatment by the employment of one of two excellent methods of procedure:

1. Kirk has suggested that the post and band of a Richmond crown be painted while warm with a solution of gutta-percha in chloroform. The solvent evaporates, leaving a coating of gutta-percha. This should be reasonably thick. The crown is then set with cement. By warming the crown with a hot crown-setting tool (How) or forceps, it may be removed without destruction of the piece. Bridges so set are very firm. The crown may be set with gutta-percha alone or in some cases with temporary stopping.

2. Girdwood (Edinburgh) has suggested root intubation, the tube being closed at the end with temporary stopping and then set with cement. Immediately thereafter the temporary stopping and soft cement are removed with Donaldson cleansers, leaving the root lumen free to the apical foramen or root filling. The tube and canal are then treated as a continuous root canal would be. The idea is also applied to a Richmond or all-porcelain crown, the tube being used in place of the pin, and allowed to extend through the backing, to be later filled as desired.

SECTION V.

DISEASES OF THE PERICEMENTUM.

CHAPTER XIX.

SEPTIC APICAL PERICEMENTITIS (ACUTE).

Classification—The dental periosteum and ligament, or the pericementum, is the seat of numerous nutritive and functional disturbances, which may be grouped, according to their causes, into septic and non-septic.

The term pericementitis has been indiscriminately applied to all affections of the pericementum, and in some cases erroneously, for in not all affections of this structure do the phenomena of inflammation appear; in some hyperemia alone may exist. However, most of the acute and chronic degenerations are accompanied by evidences of inflammation.

Bödecker's division of the affections of the pericementum into purulent and non-purulent is misleading. Cases may be due to septic causes without pus formation; pus formation represents but one form of sepsis.

The most convenient clinical classification of these disorders is that offered by G. V. Black:[1] (1) Diseases of the pericementum beginning at the apex of the root; (2) those beginning at the gum margin; (3) those beginning in some intermediate portion of the pericementum. These may again be divided, according to their causes, into septic and non-septic. Another clinical classification would be into localized and general disturbances—another into acute and chronic.

Evidences of Pericemental Disturbance—It was noted in the study of the diseases of the dental pulp that the diagnostic signs of pulp disturbance were exaggerated or diminished response to thermal stimuli; reflected instead of localized pains; and, except in rare cases of advanced hyperemia, no tenderness upon percussion. Disturbances of the pericementum are accompanied by entirely different symptoms which serve to distinguish between them and diseases of

[1] American System of Dentistry, vol. i.

the pulp. They are, in general, tenderness upon percussion. As shown by Black,[1] the pericementum is the touch organ of the tooth, its tactile organ, through which a tooth locates force applied to the tooth. The pains of pericemental disturbance are, therefore, in the majority of cases, exactly localized, instead of not being localized, as in the case of the pulp. A tooth tender upon percussion has its pericementum as the seat of disturbance. Most cases of pericemental diseases are accompanied by vascular reactions ranging from an increased blood flow, or grades of hyperemia to pronounced inflammation, and have the corresponding symptoms. The increased volume of the pericementum causes the protrusion and loosening of the tooth, heightened sensitivity being the accompaniment. As the vascular supply of the pericementum and that of the gum are in a degree collateral (see p. 190), evidences of vascular engorgement are seen in the gum overlying the affected tooth. Owing to the altered density of the parts surrounding the tooth root, percussion upon the tooth elicits a different sound from that observed in health —the sound is dull. The general symptoms of pericemental affections are, therefore, tenderness upon percussion and a dull percussion note, more or less protrusion, and looseness of the tooth and a deepening of the local gum color.

DISEASE OF THE PERICEMENTUM BEGINNING AT THE APEX.

Diseases of the pericementum beginning at the apex of the root are of two classes, septic and non-septic. The septic cases are almost invariably the sequel to diseases of the pulp, namely, suppuration and gangrene, or arise in consequence of infection through the canals of pulpless teeth. The non-septic cases are due to mechanical and chemical irritants, and in rare cases to undiscovered causes.

Acute Septic Apical Pericementitis; Acute Alveolodental Abscess; Dento-alveolar Abscess.—Definition.—By septic apical pericementitis is meant an inflammation of the apical pericementum due to the entrance of bacteria into the tissue lying in the apical space.

Causes.—The most common causes of septic apical pericementitis are:

1. Bacteria engaged in the putrefaction of a gangrenous pulp. The gases and toxic products evolved by the process also cause much irritation.

2. Pyogenic organisms engaged in the production of suppuration of the pulp in its later stages.

[1] American System of Dentistry, vol. i.

3. Pyogenic organisms introduced into the otherwise aseptic tissues of the apical space by means of instrumentation or other lack of aseptic precautions.

FIG. 534

Alveolar abscess pointing externally. The abscess is caused by the only-slightly-impacted and not-malposed lower, third molar. (Raper).

4. Infection of an apical space by an abscess arising in some contiguous part and extending in the direction of the apical space under consideration.

5. Septic infection from a pyorrhea pocket located upon the side of the tooth in question, the deepest portion of which approximates

the apical space. An alveolar abscess about an impacted tooth may find its way apically and even discharge through the cheek.

6. Possible infection by way of the pericemental tract from the gum margin or by way of the circulation, which infection may cause a pericemental abscess located in the apical tissue.

The last two conditions would be septic apical pericementitis, but are to be considered separately as pericemental abscess or true alveolar abscess. (See Pyorrhea Alveolaris.) As a cause of apical abscess it is rare, but has been seen.

Apart from these causes infective inflammation of apical tissue does not seem to occur. It is to be remembered that a small portion of gangrenous pulp beneath a root-canal filling is equivalent to an entire gangrenous pulp as a cause of pericementitis. The vast majority of cases occur as a sequel to moist gangrene of the pulp, either before or after instrumentation, or as a result of infection of the apical tissue by instruments either unsterilized or reinfected by contact with the oral fluids.

The organisms found in acute apical abscesses are those usually found in gangrenous and suppurating pulps, and in a certain percentage of even healthy mouths. (See p. 51.) Schreier found the Diplococcus pneumoniæ in 15 out of 20 cases examined. He also found Staphylococcus pyogenes albus and aureus, and occasionally Streptococcus pyogenes.

Arkövy found the Bacillus gangrenæ pulpæ in a number of cases. (See p. 568.) These are virtually the same organisms that are found in the deeper portions of a suppurating or gangrenous pulp; this fact in itself is enough to show the continuity of infection from the pulp canal. It is a well-known clinical fact that acute outbreaks of septic apical pericementitis are most liable to occur under those conditions when patients "take cold." Schreier points out that these atmospheric states produce a bodily condition which favors the development of the Diplococcus pneumoniæ (Pneumococcus), and finds in the association of these factors the reason why this diplococcus should be pathogenic in the dental condition.

Pathology, Morbid Anatomy, and Symptoms.—The Inflammatory Stage.—As in abscess elsewhere there is first infection by pyogenic organisms which produce the phenomena of infective inflammation within the substance of the apical tissue, and in the later stages in the contiguous tissues.

Following the infection, arterial hyperemia is produced, sensation is exalted, and the tooth becomes tender upon percussion; but if forcibly pressed upon—*i. e.*, if the arteries be compressed—the hyperemia is momentarily lessened and the pressure brings a sense

of relief. At this stage the gum over the apex looks normal, but may respond to pressure.

Following the arterial hyperemia, the venous obstruction which ends in stasis is inaugurated and diapedesis of leukocytes and fibrinous exudation into the intervascular tissue occurs. The fixed cells undergo proliferation.

FIG. 535

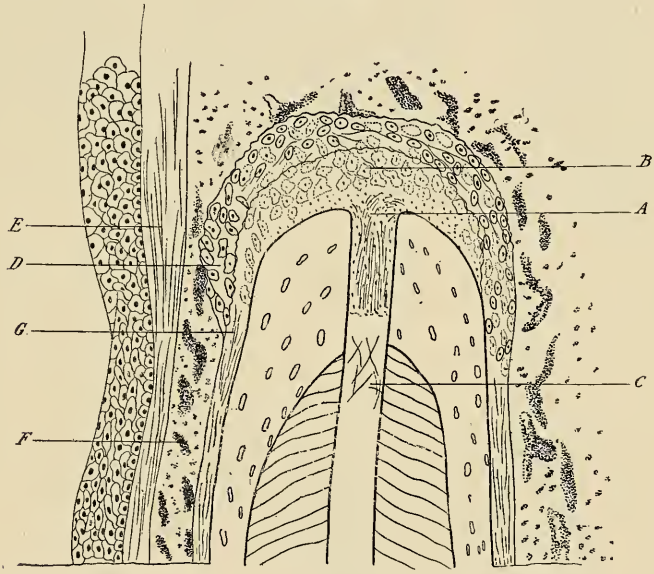

Showing the morbid anatomy of septic apical pericementitis (acute): *A*, pus; *B*, area of dying leukocytes; *C*, septic matter in root canal; *D*, inflammation of process (osteomyelitis; area of lesser inflammation); *E*, swollen periosteum and gum, hyperemic; *F*, alveolar bone in a stage of hyperemia; *G*, pericementum at edge of necrosis.

As this condition of inflammation becomes established the pain due to pressure upon the sensory nerves becomes of a violent throbbing character, accompanied by a sense of fulness. The swelling of the tissue about the apex of the root, due to the excess of fluid, blood, leukocytes, and tissue cells, of necessity pushes the tooth from its socket, so that it feels and is longer than the other teeth. Moreover, as it is bitten upon the apical tissue is further irritated. The tooth is loosened and percussion induces pain and elicits the dull note which is diagnostic of the increase of bulk in the pericementum. The color of the gum over the root becomes deepened.

FIRST STAGE OF PUS FORMATION.—The central area of the apical tissue—*i. e.*, that next the apical foramen—is broken down into pus, some of which enters the root canal (Fig. 535, *A*). As the area of pus formation widens, all of the apical tissue is liquefied (Fig. 538, *a*).

From a clinical point of view the abscess is incipient when inflammation of the apical tissue next to the foramen is profound, and pus

Fig. 536

Method of accurately determining length of root.

Fig. 537

A cyst extending from left lower second bicuspid to the central of same side. The central has a root filling. In absence of other things this may be regarded as the origin of the cyst.

Fig. 538

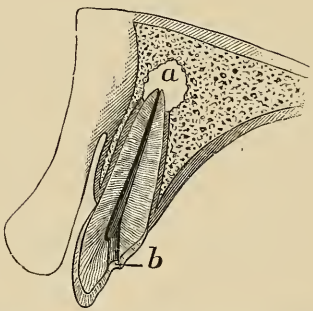

Acute abscess in second stage. Tooth opened at *b* for treatment, making an abscess, discharging *via* the canal. (Black.)

Fig. 539



Abscess on crowned root. (Skiagraph by Lodge.)

Fig. 540



Abscess on incomplete root. (Skiagraph by Lodge.)

formation has just begun (Fig. 535). The first stage continues while the pus is in the apical tissue.

Second Stage of Pus Formation.—The bone cells become involved in the process and are destroyed (osteitis). The throbbing pain, the extrusion, looseness, and dulness to percussion, and the inflammation and edema of the contiguous tissues are marked. The gum is widely inflamed, reddened, and swollen, but no demarcation of an abscess may be noted upon the gum at this stage. The membranes of the adjoining teeth become irritated and hyperemic, and they may exhibit tenderness upon percussion (Fig. 538).

Third Stage of Pus Formation.—The pus continues to form in all directions until the bone is perforated at some point—*i. e.*, usually through the labial alveolar plate — that being the thinnest and most readily perforated. The periosteum is now destroyed and the gum tissue directly involved as a boundary to the pus, which collecting beneath it, raises it into a distinctly demarked tumefaction (Fig. 541, *b*). The pain becomes less acute, owing to the binding resistance of the gum being less than that of the bone. At first the swelling is hard, and this represents a mass of gum tissue overlying pus; later, it softens at its highest point, pus appears as a yellow spot beneath the mucous membrane. The mucous membrane bursts and a discharge of pus follows. The inflammation and tenderness then largely subside, but some degree of looseness and protrusion remains.

Fig. 541

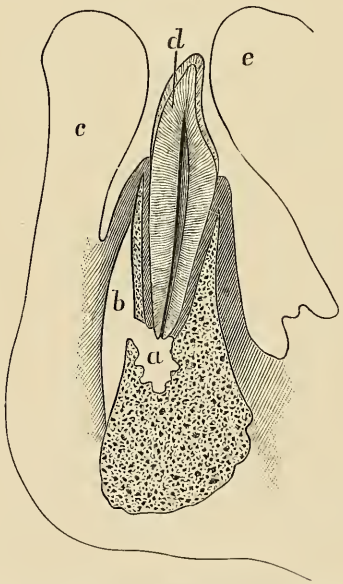

Acute alveolar abscess of a lower incisor in the third stage, with pus cavity between the bone and the periosteum: *a*, pus cavity in the bone; *b*, pus between the periosteum and bone; *c*, lip; *d*, tooth; *e*, tongue. (Black.)

During the latter part of the second and in the third stage of pus formation, instead of the swelling extending but little beyond the overlying gum, the tissues of the lips, cheeks, or neck may be very much swollen and with upper teeth the eye of the affected side injected. In some cases the outer skin may become reddened and

dusky, exhibiting the evidences of extension of the inflammatory process far from its original site.

The inflammatory process spreads out from the central focus of pus formation, there being around the pus a zone of active inflammation or stasis; about this one of a lesser degree of inflammation, also full of leukocytes; about this an area of arterial hyperemia or the first stage of inflammation, and around this normal tissue. These areas are not sharply defined, but merge into one another (Fig. 535, *A*, *D*, *E*, *F*; also p. 135 and Fig. 64).

In this way the contiguous area of the alveolar bone and the soft tissues of the face become involved in the process, being discolored and tumefied in proportion to the extent of the pus formation and the inflammatory reaction thereto.

While in the vast majority of cases the direction taken by the pus, and the point at which it finds exit, is the buccal or labial aspect, and immediately over the root apex of the affected tooth, or near it, these being the directions of least resistance, other anatomical conditions or histological peculiarities may make the direction of least resistance in some other path (Figs. 542 to 545).

Instead of the circumscribed suppuration described as the ordinary course of abscess formation about the apices of roots (septic apical pericementitis) which accompanies infection by the staphylococci, clinical evidences of infection by streptococci occasionally appear. The inflammatory process, instead of being circumscribed, is diffuse; the inflammation extends along the lines of the connective tissues and of the lymphatics; the connective tissues are swollen, the swelling extending to the tissues of the cheek, down the neck, and even to the shoulder—a phlegmonous inflammation. Instead of the comparatively free flow of pus which follows incision of the swelling in ordinary abscess, pus formation in streptococcus infection is seen, upon incision, to be limited and seropurulent. While in alveolar abscess of the ordinary types evidences of septic intoxication or poisoning are unusual, the lymphatics being blocked, as a rule, by the inflammatory exudates, septic intoxication and poisoning are the rule in the erysipelatous cases, those probably due to streptococcus infection; bacterial poisons being taken up by the lymphatics find their way into the circulation.

The symptoms of the absorption of bacterial products from the circumscribed abscesses are: Fever, often ushered in by a distinct chill. The pulse increases in volume and tension; it is full, hard, and frequent. The tongue is coated, the bowels constipated. The patient is also weakened and made irritable by pain and attendant loss of sleep and appetite.

In the streptococcal infection there is danger that these may change into the more profound symptoms of septicemia—*i. e.*, a soft, frequent pulse, repeated chills, diarrhea, clammy skin, general depression, and a disordered nervous system.

In multirooted teeth the inflammation and abscess frequently appear on only one root. If the case be seen early, before the active exudation period of the inflammation sets in, the symptoms may be clearly localized in one root, the tooth exhibiting tenderness upon pressure over the affected root, but not upon the opposite side.

After spontaneous discharge of the pus from an abscess, the condition remaining is that of an ulcerous surface (the abscess boundaries) which is being continuously infected from the putrescent pulp remnants. The conditions, it is seen, are not like those of ordinary abscess, where the infective material is largely discharged in the pus evacuation, and the cells bounding the abscess wall dispose of remaining bacteria, so that regeneration of tissue occurs. Spontaneous healing of an apical abscess is the exception; the embryonic tissue lining the abscess walls, being continuously infected, degenerates and dies as fast as it forms, leaving a condition known as chronic apical abscess, or chronic purulent, apical, septic pericementitis.

Clinical History.—The clinical history of acute alveolar abscess may be divided into three stages: (1) That of initial inflammation and pus formation; (2) the destruction of the alveolar process; (3) the passage of pus through the periosteum and mucous membrane. The second stage is usually the longest. The duration of the disease depends upon the readiness with which the tissues between the point of beginning pus formation and its exit yield. When the pulp chamber is open pus may find exit by this path, constituting the condition known as blind abscess—a misnomer, because a blind abscess is one without a point of discharge, without a fistula leading to it; in the cases discharging *via* the canal, the latter may be considered a fistula (Fig. 538).

Acute abscesses usually run a short course, the inflammatory symptoms being severe and the tissue destruction limited. Notably upon lower molars, and upon the lingual roots of upper molars, the density and thickness of bone overlying the roots may make paths of greatly increased resistance, so that the destruction of tissue proceeds along the line of the pericementum, the pus finding exit at the neck of the tooth. It is rare in cases of lower second molars, and still more rare upon the third molars, that pus finds exit over the apex of the root, the dense bone of the external oblique line offering the greatest resistance (Fig. 542). Over any teeth

the outer fibrous layers of the external periosteum may present unusual resistance to the perforative advance of pus, so that when the fibers of attachment of the periosteum have been softened by the inflammation, and pus gains entrance between bone and periosteum, it may travel or burrow along the course of this membrane (Fig. 543), depriving the bone of its main nutritive source, so that limited necrosis threatens. The roots of the central incisors may lie unusually close to the floor of the nose, and be overlaid externally by an unusually resistant layer of bone; in these cases the path of least resistance may be in the direction of the floor of the nose, the abscess opening at that point (Fig. 544), or the pus may perforate the lingual alveolar plate, and, raising the periosteum and mucous membrane, form a large swelling upon one side of the hard palate.

FIG. 542

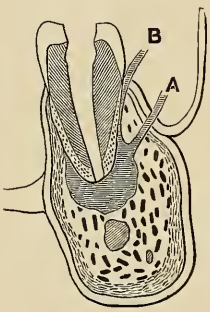

Abscess upon lower third molar, showing the usual paths of pus exit, *A* and *B*.

FIG. 543

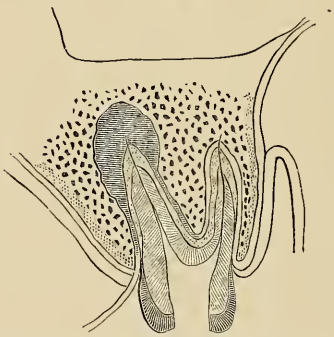

Abscess upon palatal root of an upper molar discharging at the neck of the tooth.

Vederspiel[1] instances a case in which an abscess starting upon an upper third molar finally infected the tonsil producing an abscess, also produced necrosis of a portion of the ramus of the inferior maxilla.

The root apices of the posterior upper teeth, particularly of the first and second molars, may, after the age of twenty-five or thirty, be encroached upon by the enlarging maxillary sinus, so that any or all of the roots of these teeth may be separated from the floor of the sinus by but a very thin lamina of bone or only by periosteum and mucosa; should abscess arise upon any of these roots, pus discharge into the antrum would necessarily follow. In these cases the acute symptoms may rapidly subside, but later symptoms of antral empyema may follow (Fig. 545).

[1] Dental Cosmos, December, 1912.

Resort to the use of poultices upon the face, for the relief of the pain of abscess formation, may induce such a softening of the tissue over which they are applied that the passage of pus is invited toward the exterior; the abscess may thus open upon the face or neck, producing permanent, disfiguring scars (Fig. 583).

Fig 544

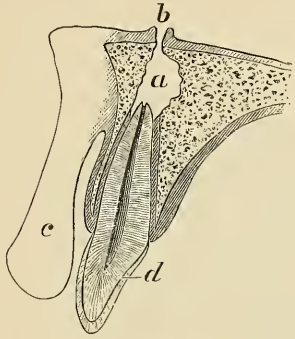

Alveolar abscess at the root of a superior incisor, discharging into the nose: *a*, large abscess cavity in the bone; *b*, mouth of fistula on the floor of nostril; *c*, lip; *d*, tooth. (Black.)

Fig. 545

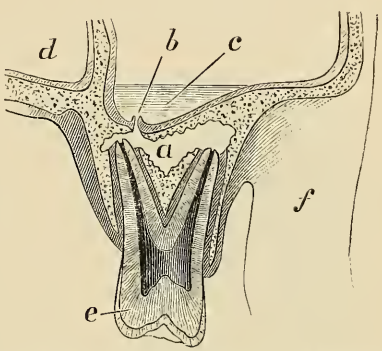

Alveolar abscess at the root of an upper molar discharging into the antrum of Highmore: *a*, abscess cavity in the bone; *b*, mouth of fistula on the floor of the antrum; *c*, pus in the antral cavity. (Black.)

In patients who are in a cachectic condition, who have an evil heredity, or whose tissue resistance is markedly lessened in consequence of tuberculosis, or more frequently of syphilis, septic pericementitis may run a riotous course; the bone suffers extensively by direct action; the periosteum is undermined, is stripped from the bone over large areas, and breaks down readily; so that while in the healthy person alveolar abscess formation may run a direct course and find prompt outlet, in the syphilitic patient extensive pus infiltration, with necrosis, may occur. In cachectic persons lymphatic involvement is common; waste products of bacterial origin find their way into the lymphatics, and set up secondary irritative processes in the nearest lymphatic glands—lymphadenitis.

In persons whose oral hygiene is neglected the third stage of alveolar abscess is frequently violent and the inflammatory process widespread.

Diagnosis.—In incipient apical pericementitis the symptoms may consist of reflex pains, but, as a rule, are distinctly localized in the teeth affected, which are tender to the touch. The discoloration of the tooth crown and other evidences of moist gangrene are usually present unless the tooth has been previously partially treated, when

the color may be good, but by transmitted light opacity is noted In a few cases the tooth has had almost a normal color even under the transmitted light. In the pronounced cases the symptoms are as described (see p. 570).

When a sinus is present a soft silver probe may often be passed toward the tooth affected.

A timid patient will often unintentionally confuse pericemental tenderness with the pain of sensitive dentin.

Fig. 546

Diagnosis of apical abscess by *x*-rays. (Price.[1])

Fig. 547



Skiagraph of perforation and apical abscess; wire thrust through same. (Lodge's method.)

In very doubtful cases, as when molars have deep amalgam fillings, or pins have been placed in root canals, or gold crowns cover the natural crowns, either the covering must be removed or a skiagraph be taken.

After high inflammation has existed for twenty-four hours, pus is generally present in the apical tissue.

Of two pulpless teeth surrounded by a zone of inflammation, the more tender and loosened is the one affected, though both may be acting at once. It is to be remembered that adjoining, otherwise normal, teeth may show some evidence of pericementitis, due to extension, so that differentiation is necessary. The various stages of inflammation and pus formation are judged by the appearance of the gum or by the *x*-rays (Fig. 546). The greater the swelling and injection of the gum, the more advanced is the pus formation.

The inflammatory action precedes the advance of pus, which furnishes a guide to the direction the pus is pursuing—viz., where the most intense coloration and the greatest swelling appears will be the point at which the abscess will point or discharge. A sudden subsidence of inflammation without an immediately discoverable

[1] Items of Interest, 1901.

point of pus exit should lead to the suspicion that the discharge has taken place in an unusual situation.

The direction pus may take is often determined by gravity, but the resistance of certain tissues may cause the pus to seek the easiest path. Thus, by discharging into the antrum it goes rather counter to gravity. In such cases as discharge into the antrum there is liable to be a collection of pus in that cavity which may cause destruction of the mucous membrane and bone. This condition is known as empyema of the antrum. The sudden subsidence of an acute abscess upon a tooth located beneath the antrum should create a suspicion of discharge into that sinus. If a fine probe can be passed an unusual length into a root canal it indicates this form of sinus involvement.

Fig. 548

Non-descended cuspid and lateral. These teeth were entirely enveloped in pus. The cuspid and lateral shadows overlie each other. Between these and the first bicuspid may be seen three tiny supernumeraries. (Lodge.)

An abscess originating about an impacted tooth, or one due to subperiosteal inflammation, must be differentiated[1] (Fig. 548). A pericemental abscess must also be considered. It is always more lateral and there is less facial involvement, also there is usually a pyorrhea pocket leading to it. An acute abscess of the pulp in its most pronounced stage may simulate incipient or even pronounced acute apical pericementitis. (See p. 449.) An abscess sometimes forms beneath the flap of gum overlying a third molar. This begins as an ulceration of the under side of the flap, but the pus burrows between the tooth and the gum, and when well confined may develop laterally, causing the formation and at least partial retention of a quantity of pus in the tissues of the cheek. This condition more nearly simulates the lateral abscess associated with a pyorrhea pocket, and as by extension it sometimes involves the tonsil, the case may be mistaken for an amygdalitis.

The last three conditions are usually associated with suspected teeth containing vital pulps, so that tests for pulp vitality are to be applied.

In certain cases of pulp gangrene part of the pulp only may be dead—*e. g.*, the lingual filament of the pulp of an upper molar; while the balance may be vital (the buccal filaments). This fact may con-

[1] Black: American System of Dentistry, vol. i.

fuse the response to tests and is to be borne in mind. A broken root covered more or less by gum or carious bone must be taken into account.

Prognosis.—In the majority of cases the prognosis of acute apical abscess, as to the future retention of the tooth, is favorable; and usually very favorable if the case receive intelligent therapeutic aid. The future of the tooth depends upon the thoroughness with which sources of infection may be destroyed and permanently removed, and the completeness with which regeneration of tissue can be induced.

Treatment.—In the initial inflammation and first stage of pus formation the treatment should be abortive, to afford relief from the pain. The cause of the inflammation should be removed, if possible, and the pus formed be removed or, at least, permitted to escape by way of the pulp canals. The promptness of relief from pain depends upon the thoroughness with which this is accomplished.

The pulp chamber should be opened to an extent which permits the free passage of broaches into the canal (Figs. 538 and 543).

If the cavity of decay be open, the pulpal wall is to be perforated. If a filling be present, it is in part or entirely removed. If the enamel be entirely sound, or if subsequent treatment require a new opening in line with the pulp canals, it is at least in part made.

These openings are usually begun with a small, spear-pointed drill (No. 100, S. S. W. Catalog) revolving in a perfectly true hand piece. To centre the drill, first spot the enamel with a dentate bur. The opening made is enlarged with successive sizes of sharp, round, dentate burs until of sufficient size.

According to the amount of tenderness, the tooth will require a counterpressure to that of the drill. If the entrance be made through the occlusal face of the tooth, or in a direction which would cause direct pressure on the apical pericementum, a ligature of linen thread with long ends may be placed around the tooth, and traction be made by drawing on the loose ends of the ligature.[1] Effective counterpressure against lateral entrance to the pulp chamber may be made by softening a small roll of modelling compound and moulding over the face of the affected tooth and several of those adjoining it, and hardening with cold water. This temporary splint is held in place by the index finger of the left hand. W. D. Tracy recommends for posterior teeth a double modeling compound splint, one lingual one buccal, to be held with the fingers, or two ligatures may be placed between the tongue before the compound is placed and the ends tied over the splints, binding them against the teeth. In case

[1] J. Foster Flagg: Lectures on Dental Therapeutics.

the inflammatory process is marked, or if the patient be in bed, it may be necessary to make a vent opening by the easiest path, especially when using a hand drill—*i. e.*, at the junction of enamel and cementum—directly into the chamber.

As soon as entrance to the pulp chamber is effected, the cavity is syringed with a strong antiseptic. Fine probes are passed and repassed into the opening to free the outlet, so that gases and pus may escape and fresh portions of the antiseptic be worked into the cavity. The escape of blood from the canal is a sign that all the pus is vented. The quickness with which relief is secured will depend upon the thoroughness with which the canals are entered and their putrid contents given vent. A tedious class of cases are those in which a canal of a molar is filled or partially filled. Unless entrance to and cleansing of the canal be accomplished, the inflammation will proceed until the pus finds external vent. An hour spent in gaining access to and cleansing such canals is well spent.

The patient may be directed to make suction with the tongue to create a vacuum tending to draw the pus, etc., into the canal. If a tight joint can be obtained with a special point an abscess syringe may have its plunger drawn back to create the vacuum. This measure is not necessary when prompt relief is obtained by venting.

The canals may be dried and an anodyne antiseptic, such as phenol camphor plus menthol, pumped into them. If, now, provision against mastication upon the elongated tooth be made by means of a guard, relief is tolerably certain.

Watkins[1] has used "blue light" applied from a 16-candle power blue-globed electric lamp through a funnel directly upon the part. He claims relief from the pain, enabling him to open the tooth previously too painful to be operated upon. He also claims that swelling is much reduced by it, in some cases in twenty minutes. The high frequency current is also useful in this connection.

Patients do not ordinarily tolerate the rubber dam in these cases, and as the tooth should be left open it need not be used.

A guard may be made from a strip of rubber dam two inches long and of a width corresponding to the distance from the buccal to the lingual gum margins and folded into a pad of the width of the occlusal face of the tooth to be covered. Floss silk is then sewed through this in such a manner as to cause it to tie the pad over the tooth, the silk itself encircling the neck of the tooth.[2] This should be attached to a nearby tooth, and will insure rest of the affected pericementum by preventing occlusion upon the crown (Fig. 549).

[1] Dental Cosmos, 1905.

[2] Flagg.

Cold antiphlogistics, such as lead water and laudanum or cataplasma kaolini, should be applied externally. No hot external applications should be used in abscess cases, as they may cause an external fistula to be formed.

The mouth is to be frequently washed with an antiseptic. In simple cases with prompt relief this is all that is necessary; in marked cases the reduction of the inflammatory engorgement should be attempted in addition.

Swedish leeches may be applied to the gum, or a cut or two made in the gum over the apex of the tooth will allow free bloodletting and drainage of the excess of blood in the pericementum. A hot pediluvium and a saline cathartic conjoined are useful as counterirritant derivatives, and the latter is also depletive, reducing the volume of the blood. The hot pediluvium with mustard added and diaphoresis conjoined are also useful. Ten grains of Dover's powder in divided doses in hot lemonade are given, in part, while the pediluvium is being administered, and the patient is later well covered up in bed.

Fig. 549



Rubber dam guard for use in pericementitis: *A*, roll of dam threaded; *B*, guard fitted over tooth; tooth eliminated to show the manner in which the silk encircles it.

Quinin in doses of gr. vj is given as a febrifuge and to limit exudation, and tincture of aconite, two drops at first, and one-half drop each half hour is given until the volume, tension, and frequency of the pulse are reduced.

If syphilis be a complication in these cases, potassium iodid, in doses of 10 grains each three hours, is useful as an antagonist of its influence and as a nervous sedative. Unless Dover's powder is used, morphin sulphate in blondes and morphin bimeconate in brunettes (especially those with blue eyes), or any persons with known idiosyncrasies to morphin, should be administered in $\frac{1}{8}$ grain doses, repeated each hour up to $\frac{3}{8}$ grain. When great suffering renders it necessary, a hypodermic may take its place. When used, a saline cathartic should be given the following morning. Trigemin is useful.

These several measures are to be regarded as the abortive treatment of alveolar abscess; they apply to all cases if seen early enough, and will in the majority of cases prevent the disease of the peri-

cementum passing the early inflammatory stages. In all cases the severity of the inflammatory process is lessened in proportion to the thoroughness with which the antiseptic measures are applied, provided that in the attempt at such application no septic matter be violently thrust through the apical foramen, especially of the one of a multirooted tooth which is not involved.

The Second Stage of Acute Apical Abscess.—In very mild stages the pus is in the bone and the infection considered more virulent, *i. e.*, the germs are specially active. The abortive treatment should first be tried, and if free venting of pus is obtained relief is usually given. If not given the case continues to the third stage. If bearable, or the surgical method be impracticable, a dental capsicum plaster may be applied to the gum or a roasted half-raisin may be applied. Either causes an inflammation of the gum, which advances the tissue that much nearer suppuration. Thus it prepares a readily invaded tissue and hastens pointing. The contrary effect has sometimes been produced, and is explained upon the ground that the increased amount of blood has increased the phagocytosis and destruction of bacteria or has stimulated a restoration of the circulation, possibly both. Trigemin is a useful adjunct when the pain is severe. For the purpose of hastening suppuration, calx sulphurata, $\frac{1}{2}$ grain each hour, is useful. It also sometimes hastens resolution. It is proper to denominate this the expectant treatment, and while, perhaps, unsurgical, at times permits no alternative except extraction.

When tolerable or imperative, the surgical method of venting the abscess through an opening in the gum is valuable. The apical region is located as nearly as possible by measuring the length of the tooth with a probe passed into the canal and over which a small piece of rubber dam is slipped as a guide. This is laid over the crown and gum and a tiny drop of carbolic acid is placed just above the point of the probe as a guide. A vertical cut is made in the gum down to the bone, and a broad spear drill is driven through it into the abscess tract. Whether this shall be done under ethyl chlorid refrigeration, local anesthesia, or short general anesthesia, the operator must determine.

A gradual perforation is useful in some cases. This method, designed by Black, consists in gradually escharing and scratching the gum tissue. Successive applications of just such carbolic acid as adheres to the point only of a sharply serrated plugger are made, followed by slight scratching only so that blood shall not be drawn. In this way the bone is ultimately reached.

A fresh drop of acid is applied, the periosteum scraped away slightly, and the drill then used.

A Rollins tubular knife (Fig. 550) has been used with success to remove a piece of gum, after which the drill or a fine trephine (Fig. 551) is used. Some acute pain may follow this operation, but usually lasts only a short time.

Fig. 550

Tubular knives.

Fig. 551

Walker-Younger trephines.

If antiseptics are used to syringe out the abscess cavity, it is better to use a mixture of six parts hamamelis (aqueous) and one part listerine as a partial sedative. The use of hydrogen dioxid is often very painful, owing to the rapid reaction with the blood present, and as it sometimes also drives the infective material into remote parts without disinfecting it, its use in this connection is not without danger, and should be avoided.

It has been a subject of controversy whether a tooth should be extracted while the abscess is in the second stage. It has been claimed that the continuation of pus formation after extraction renders the state of the patient worse than before extracted.

This occurrence is comparatively infrequently seen, and is, of course, due either to the retention of some pyogenic organisms beneath the clot which forms in the alveolus or the infection of the parts by extraneous organisms.

The retention of the tooth until a fistula forms would also confine the bacteria for the time.

Unquestionably metastatic infections have appeared as the result of persistent local infection following tooth extraction, the avenue being the lymphatics; therefore, in cases of extraction during the second stage of pus formation the alveolus should be forcibly syringed for ten minutes with the above listerine solution. If it be thought desirable to repeat the syringing, a tent of antiseptic gauze may be gently carried to the apex of the alveolus and left. This tent

may be removed to permit syringing, *and should never be left long at any one time, as septic inflammation of the alveolar walls may occur.* It also does not drain pus readily, so it might cause an abscess if left too long.

In cases of this kind oral sterilization and anti-infective systemic medication are of importance. As soon as improvement is noted the tent should be removed, the alveolus sterilized as before, and a new clot induced by a curetting of the walls. The case should now proceed as any ordinary extraction; if not, it should be treated as for dry socket (which see).

In a reply to a circular letter of questions regarding this point, Black, Kirk, Ottolengui, Hoffheinz, and Schamburg all favored extraction as a means of removal of the cause and as a less evil than allowing the tooth to remain enclosing the bacteria, which, if capable of producing septicemia, it would do if allowed to remain. They are therefore in agreement with the editor's position taken in the second edition of this work (1904). Brown argues the difficulty of decision in an individual case. All are practically opposed to the idea that pneumonia is more likely to result from postextraction sepsis than septicemia, Morris[1] having taken the position that pneumonia resulted from extractions in this condition. Each and all advised careful ante- and postextraction antisepsis.

The editor has had quite a number of cases of necrosis (necrotic dry socket) following extractions at the hands of specialists, and believes they and he should have been more watchful in these cases, and that in most cases a strong solution of potassium permanganate should be used as a wash before and after extraction, or tincture of iodin be locally applied, especially in cases requiring laceration of the gum. Antiseptic spraying of the alveolus, etc., is a reliable measure. In one case of extraction of a lower third molar operation under anesthesia for prevention of progressive necrosis became necessary. The making of a cautious diagnosis and awaiting the proper time, as recommended by Mitchell, is a physical impossibility unless one await the third stage or a fistula or general infection, as in this state the bacteria are considered virulent, especially while bone solution is in progress.

The Third Stage of Acute Apical Abscess.—In this stage the pus has found its way through or beneath the periosteum on the outside of the bone; therefore its germs are engaged in liquefying the gum tissue or in unusual location the mucosa or muscular tissue of the part. Except in these cases the gum is tumefied, a hard, circum-

[1] Mitchell: Dental Cosmos, 1907, p. 713.

scribed, inflamed nodule indicating pus near the bone, a soft, more generally diffused swelling indicating more superficially located pus, while a soft yellow or yellowish-pink tumefaction indicates pointing. In all these cases the indication is for a surgical opening of the gum rather than the opening of the tooth. The part should be gently disinfected with tincture of iodin on a ball of cotton, and a sharp bistoury should be boldly driven to the bone, with the cutting edge turned toward the occlusal. The lip or cheek is to be drawn well away to avoid injuring the coronoid, buccal, or facial artery. A cut about a half to three-quarters of an inch in length is rapidly made by sweeping the edge and point downward occlusally. Too deep lancing upon the hard palate may injure the posterior palatine artery.

As this is usually painful, it is better to refrigerate the gum with ethyl chlorid or operate under short general anesthesia, *e. g.*, nitrous oxid or the first impression of ether. Novocain is only useful in the case of deep-seated pus injected into the more healthy tissue. Next, the abscess tract is to be gently washed out with a diluted hamamelis solution, preferably warmed. Fairly hot water containing an antiseptic also gives relief.

If the abscess has been deep-seated it is well to introduce a fine tent of antiseptic gauze through the opening into the abscess tract to prevent the too rapid healing of the external orifice which is apt to occur, owing to the approximation of the lips of the wound produced by cheek pressure. This healing sometimes permits a second collection of pus. The tent should be removed not later than the next day, the abscess tract disinfected again, possibly with a mercuric chlorid solution, and the tent replaced. At this time the tooth should be opened and disinfected if not tolerable at the first sitting. When this is tolerable the crown may be tapped and formocresol sealed in the pulp chamber, just before the operation of lancing, in order to permit disinfection and thus limit pus formation and to save time. Tents in aveoli should never be left long at a time, as they become septic and may cause necrotic conditions of the alveolus.

The patient should always be cautioned to remove the tent if swelling return, as this indicates a stoppage of the vent, with collection of pus.

When diffuse cellulitis with marked febrile disturbance passing into the adynamic type is produced, one should fear the infection with Streptococcus pyogenes and treat not only locally, but use blood germicides against a possible septicemia. In these cases there is little pus formed compared with the area involved.

As a preventive of possible blood infection the following may be administered:

℞—Hydrargyri bichloridi . . . . . gr.j
Tincturæ ferri chloridi . . . . . f℥j—M.
Sig.—Twenty drops in water four times a day.

The editor employed this remedy with markedly beneficial effect, while suffering from a very severe abscess about the finger-nail, due to infection by the Streptococcus pyogenes and associated with lymphangitis extending as a bright red streak into the axilla.

If the adynamia and other symptoms be progressive, medical coöperation should be obtained to divide the responsibility and to afford every means possible toward the cure. The extraction of the tooth followed by sterilization and curettement of the part, and the use of streptococcus antitoxin or vaccine conjoined with the sustention of the vital powers by nutritious predigested food and alcohol is logical. In even ordinarily severe cases not of this variety and there will be some fever due to the toxin absorbed, and the pain loss of sleep and appetite will cause physical debility. (See p. 149.)

For this there is nothing better than the following, as tonic, antiseptic, and antipyretic:

℞—Saloli,
Quininæ sulphatis (vel hydrochloratis) . . . . āā gr. lx
M. et fiant capsulas no. xx.
Sig.—Take one four to six times daily, before meals when near them.

Or,

℞—Quininæ sulphatis . . . . . gr. xxx
Acetanilidi . . . . . gr. xxiv
Caffeinæ citratis . . . . . gr. iij
M. et fiant pil. no. xij.
Sig.—One every hour. (Endelmann.)

The facial swelling resolves with the cure of the abscess or its proper venting, but may be assisted by cold applications or cataplasma kaolini to the outside of the face and by gentle massage by the patient or nurse.

As a means of reducing swelling, vibratory massage is useful. A simple appliance for this purpose, devised by W. H. Mitchell,[1] consists of a cam-like piece of metal perforated at its smaller end for mounting upon a screw mandril; it is held in the dental hand piece strapped to the hand as shown. Its centrifugal force imparts a vibratory motion to the hand which can be utilized for massage with the finger tips, or by holding in the hand an instrument containing upon its end a soft rubber cup. The part to be massaged should be lubricated with vaselin (Figs. 552 and 553).

[1] Dental Brief, 1908; Academy of Stomatology.

The heat of a large electric lamp concentrated upon the face from a short distance and followed by massage is also useful in facial swellings due to cellulitis.

Fig. 552

W. H. Mitchell's vibrator strapped to hand.

Fig. 553

W. H. Mitchell's vibrator and rubber cap applicator.

Under no circumstances should hot poultices be applied to the outside of the face, as a discharge of pus in that direction will cause a disfiguring scar. If an abscess threaten to open externally, the abscess should be opened by an incision made from a point within the mouth, and, after sterilization of the tract, a drainage tent of antiseptic gauze should be introduced nearly to the bottom of the pus cavity. This should be removed daily, the abscess cavity sterilized, and the tent renewed. An antiphlogistic compress should be applied to the face. The principal object sought is the mechanical apposition of the walls of the abscess cavity at the dependent or external portion, in order that these shall unite by granulation and that the fistula shall in this manner become an ordinary one. The patient should lie in a position to counteract the natural effect of gravitation.

After lancing, the mouth should be kept well sterilized by frequent sprays or gargles of hydrogen dioxid, which may be diluted to one-third strength with water—*i. e.*, to a 1 per cent. solution.

If, in connection with the lower third molar, marked swelling be observed in the submaxillary triangle, free incision of the tissues of

the floor of the mouth should be made at the angle of junction with the bone. The cut should be made close to the bone and toward it, but not too deep, lest the mylohyoid artery or nerve be injured.

The deep lancing of an abscess upon the hard palate may cause a cut to be made in the posterior palatine artery. External to the jaws the facial and coronoid arteries are to be considered. Keeping close to the alveolar process while the cheek is pulled out renders the operation safe.

It is ever to be borne in mind that so long as the cause of infection remains pus formation continues, and so long as pus forms tissue destruction is in progress; furthermore, in proportion to the amount of tissue loss perfect recovery after alveolar abscess is delayed or imperfect.

While it is the clinical experience of nearly every operator that a tooth and adjacent structures may recover from inflammation which involves not only the first tooth attacked, but by an extension of the inflammatory process involves the general periosteum and neighboring teeth, provided the case receive prompt and decisive surgical treatment, yet the danger of necrosis and septicemia in prolonged cases is always imminent. When the general periosteum is involved, as shown by extensive boggy swelling in the mouth, if several free incisions carried to the bone do not afford prompt relief, the tooth which is the centre of infection should be promptly extracted. If, in the continued course of the pericementitis, chills, followed by fever, a coated tongue, and much physical depression occur, a general infection is to be feared, and no time should be lost in sterilizing the mouth, extracting the tooth, and subjecting the socket to free spraying with antiseptics. Systemic treatment is to be given (see p. 605).

In cachectic individuals acute abscesses may cause inflammation of the deeper tissues and of the periosteum as well, and extensive necrosis may occur. The after treatment of acute apical abscess which has been relieved by abortion is exactly that of moist gangrene or of chronic abscess without fistula (which see). In very mild cases the formaldehyd treatment may be instituted at once. In severe cases it is better to allow drainage for a day or two. When the relief has been afforded by lancing the treatment is as for chronic abscess with a fistula (see p. 618).

Acute septic apical pericementitis may occur on a temporary tooth, most frequently a temporary molar. The symptoms and pathology are the same, except that the looser character of the alveolar structure seems to frequently permit the abscess to assume the chronic form before the dentist is consulted. Children often hide these

conditions from their elders out of fear of the dentist. In strumous children the inflammation may be spreading and the lymphatic glands may be involved. There may also be some symptoms of septic intoxication evidenced by chills accompanied by fever, etc. These cases require an opening of the abscess, sterilization of the part, and attention to the systemic condition. If seen in the acute stage the treatment is the same as for the permanent teeth, unless the disease occur shortly before the date for eruption of the permanent successor, when the temporary tooth should be extracted, If treated, the canals should be filled with materials which can be resorbed by the tissues, such as paraffin or wax with aristol, paraform, or thymol (Fig. 587).

As soon as the pus escapes, the condition of chronic apical abscess is established.

CHAPTER XX.

CHRONIC SEPTIC, PURULENT, APICAL PERICEMENTITIS (CHRONIC APICAL ABSCESS)

By this title is meant a condition of apical pericementitis due to septic influences in which pus is continuously formed at the expense of the apical pericementum and contiguous tissues. It is the usual outcome of acute apical abscess, and is established as soon as the pus finds vent either through the gum as a natural or operative result, or through the root canal as the result of opening the canal.

These two avenues of pus escape give the two clinical conditions of (1) chronic apical abscess discharging *via* the root canal; (2) chronic apical abscess with fistula: (3) a third condition of latent chronic apical abscess (true blind abscess) with absorption of pus by the tissue may exist.

CHRONIC APICAL ABSCESS DISCHARGING VIA THE ROOT CANAL.

Pathology and Morbid Anatomy.—First Grade.—Upon abortion of an acute abscess in the first stage the pressure of pus upon the apical tissues is released, and, as a rule, the walls of the abscess cavity throw out granulations which fill it. This tissue tends to organize into more or less healthy tissue (cicatricial tissue). The bacteria are killed out except at that part represented by immediate contact with the root foramen; at this point the tissues are infected and some molecular loss of tissue as pus may occur. A limited loss of granulation tissue by pus formation is compensated for by the formation of new granulations. The conditions are almost analogous to those existing in moist gangrene of the pulp, and require analogous treatment.

Second Grade.—If the abortion of the abscess has only partly permitted the pus to drain, or the alveolar walls or crypts of the abscess wall remain infected, the pus will continue to form and escape in some degree *via* the canal. If the tooth now be extracted, a small abscess sac will be found upon the root end. If opened,

this will be seen to be a mass of fibrovascular tissue (inflamed pericemental apical tissue) having a central lumen connecting with the root canal (the abscess cavity).

Third Grade.—With partial vent to the pus formed, the abscess cavity of the second grade may enlarge, involve the bony walls of the alveolus, and the soft tissues then proliferate to such an extent that they finally organize into a large, fibrous, vascular sac attached to the tooth. This sac has the central pus cavity before described, which is connected with the pulp canal. It may be a half-inch or more in length (Fig. 554), and may be extracted with the tooth or may be left attached to the bone. It necessarily occupies in the latter a cavity of a size corresponding to its own bulk. As its inner walls are infected, extraction without its removal leaves an infected area, which must be disinfected or a secondary acute abscess may result. (See p. 603.) One case which had given only slight uneasiness owing to partial vent, was treated at two o'clock and the tooth extracted at midnight, had the appearance shown in Fig. 554.

Fig. 554

Chronic apical abscess third grade: *B*, abscess sac containing a central pus cavity; *D*, apex of root; *C*, canal containing pus.

Fourth Grade.—Instead of organizing, the fibrovascular tissue may be liquefied into pus. The root apex becomes denuded for a distance about the apical foramen. Pus collects about the apex of the root and rests upon the bone, owing to the influence of gravity. The bone is thus infected, inflamed, and further liquefied, while necessarily the abscess cavity enlarges. If a bistoury be thrust through the labial alveolar wall in such a case, as shown in Fig. 555, but slight resistance will need to be overcome. In the lower jaw the tendency is to burrow into the cancellated tissue of the bone away from the tooth, so that destruction of the pericementum may not be very extensive. In the upper jaw the tendency is to spread along the pericementum and into the cancellated bone, so that the cavities of chronic abscess upon the upper anterior teeth particularly may cause extensive excavation in the palatal process of the superior maxillary bone (Fig. 557). The pus may burrow in irregular and circuitous directions until it finds external vent.

In long-established cases deposits of pus calculi (serumal) may form upon the root end (Fig. 558). The cement corpuscles of the apical cementum may die and the root tissue itself become infected. In other cases resorption of the root end occurs. (See Resorption.)

Symptoms.—In all of these cases the formations are gradual, owing to the partial vent, and it may be that no pain beyond a slight

Fig. 555

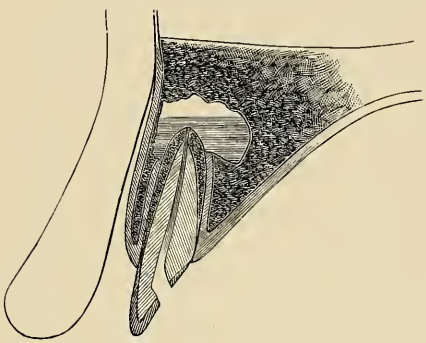

Chronic abscess on upper incisor, showing tendency of pus progressively to destroy pericementum, owing to the influence of gravity.

Fig. 556

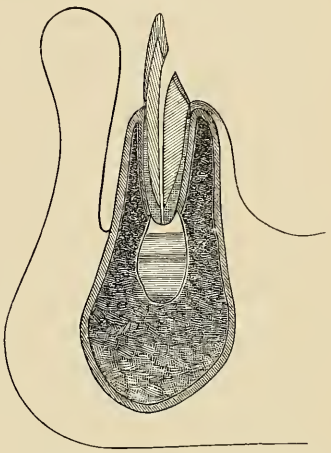

Chronic abscess upon lower tooth, showing tendency of pus to sink into the substance of the lower maxilla, owing to the influence of gravity.

gnawing or feeling of fulness or an occasional reflex pain may occur. If for any reason the vent become occluded, the pus formation becomes rapid and an acute abscess is set up, which may be painful

Fig 557.

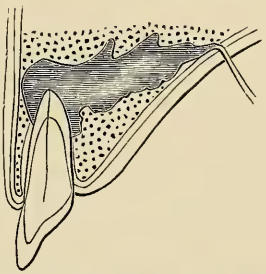

Chronic apical abscess discharging through the hard palate and threatening to discharge labially.

Fig. 558

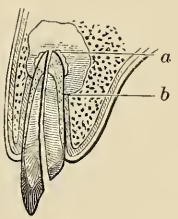

Chronic abscess, showing denudation of apex of root (*a* to *b*), with deposits of calculi (*a*) upon cementum.

or not, according to the amount of tension produced before discharge of the pus. Aside from this, the gum color at the apex is somewhat

deepened, the tooth is slightly loosened, and slightly tender to percussion. Signs of previous moist gangrene are in evidence.

Diagnosis.—The passage, without production of sensation, of an undue length of fine probe into a canal is evidence of destruction of apical tissue and a guide to its probable extent.

An extensively inflamed gum tissue over the apex indicates a probable approach of pus formation to gum tissue. The presence of pus in the canal or upon several dry cottons introduced for absorbent purposes is diagnostic. If pus be not seen, and the canal be thoroughly sterilized and dressed with an antiseptic, the supervention of an acute abscess affords evidence of the presence of an abscess sac or cavity. The *x*-rays afford a means of diagnosis (Fig. 571).

Prognosis.—The prognosis is favorable to a cure in nearly all of these cases, provided thorough canal asepsis and filling can be attained and the abscess cavity can be drained and disinfected. In cases resisting this treatment, a fistula must be established.

Treatment.—The first and second grades of chronic apical abscess discharging *via* the canal may be treated upon exactly the same principles which are involved in the treatment of moist gangrene of the pulp. The infection is considered as simply more deep seated, so that it is necessary to pass disinfectants into the abscess cavity with two objects in view: (1) To destroy the bacteria present; (2) to stimulate the tissues to granulative activity. The canal should be scraped and the foramen very slightly enlarged if necessary with a fine Donaldson cleanser, the canal having been flooded with 10 per cent. formalin or formocresol as an antiseptic.

If necessary the root canal may be otherwise enlarged. (See p. 545.)

A dressing of 10 per cent. formalin or phenol-camphor to which a little menthol and a drop of formaldehyd, 40 per cent., have been added, or formocresol, should be loosely placed in the canal and the tooth sealed for twenty-four hours, or, if the tooth has been very troublesome and is still tender, a soft temporary stopping may be used and the patient provided with instruments suited to the removal of the covering and the cotton. It is better that the tooth should be under the control of the patient. At the next sitting the cement stoppings are more tightly made. The Zieler-Hoffendahl method may be used to sterilize the root and abscess, then the dressing is sealed in for a few days and renewed as necessary, being made continuously tighter. (See p. 613.) When no pus can be found on the dressing or following it, or on an exploratory cotton twist, and there is no odor, the root may be filled; in case of any doubt in fine roots, with a removable material such as forma-percha on cotton or the paraform alum paste (p. 552), which may remain if no ill-results follow. A tem-

porary crown filling of gutta-percha should be used for a week or two. Each change of dressing should be preceded by sterilization of the cavity and bulb of the pulp chamber with a strong formalin solution to prevent reinfection of the apical tissue during the change, and it is well to use counterirritation directly after the root filling.

It is always well when using an occlusal opening to close it with amalgam or cement after the first tentative dressing, while compressible dressings are in place, as even one heavy bite upon the covering may force the medicament into the apical tissue and renew the irritation. Slightly countersinking the orifice of the tap will prevent an inward thrust of a rigid covering overlying cotton (Fig. 532).

Some operators prefer to leave a small vent in the temporary covering, used to act as a drain. This, however, is apt to prevent the concentration of the action of the medicament upon the apical tissue. If formaldehyd be irritant, perforating the temporary stopping with a pin will sometimes relieve the pressure.

If pus formation persist in any case with a large foramen the cotton may either be protruding from the root and keep up irritation or fall short of the root end and permit pus to enter the canal, and especially if no pain has been produced, good results sometimes follow a departure to the immediate method of root filling. The canal and pus cavity are resterilized for a half-hour using formocresol, deliquesced zinc chlorid, or carbolic acid on cotton against the apical tissue, and the canal apex is then filled with gutta-percha or oxychlorid of zinc. The tissues are expected to care for themselves. A persistent discharge of serum or of glairy lymph is indicative of inflamed aseptic but weeping tissue, and requires the same treatment. (See p. 579.)

In a relatively few cases teeth cannot be closed at all without a recurrence of trouble within a short period, which trouble is usually relieved by opening the tooth. The repetition of this is annoying, and in some cases is due to the strength of medicaments such as formaldehyd, which should be modified or abandoned for sedative antiseptics such as phenol-camphor or eugenol plus menthol. In some of the cases the gases may accumulate more rapidly than disinfection occurs. In other cases the irritability of the tissues seems to produce intolerance of any remedial measures. What is known as "systematic stopping and unstopping" seems sometimes to overcome the irritability and accustom the tissues to being covered. The system consists of stopping with eugenol and menthol or modified formocresol for about eight hours, or from morning to afternoon, then venting and redressing until the following morning, then for

twenty-four hours, then forty-eight, then seventy-two, etc., until the tooth stays stopped.

There have been a few patients who cannot seem to have teeth "treated," nearly all cases being practical failures even when aseptic. Some few may be kept in comfort for a while with permanent vents, but this is objectionable. The making of an artificial fistula should be attempted.

Cyst formation occurs owing to the projection of an aseptic root filling or to some not well understood cause; a cystic swelling may occur over the root of a tooth and have its origin in the pericementum The swelling is apt to be bluish about its margin, and has a clear, stretched look in the centre. It is probably due to a collection of fluid in some portion of the pericementum, or may have as its excitant a portion of calculus deposited aseptically in the pericementum. Indeed, apart from infection, it may be that cases of pericemental abscess, discharging merely glairy fluid, are cystic swellings. It may, however, be in relation with septic canal contents. (See p. 631.)

In such a case, if swelling increase or be persistent, an artificial fistula must be established (see p. 601) and the case treated as a chronic apical abscess with fistula.

In the third and fourth grades the prognosis for treatment by way of the canal is not, as a rule, good, but if desired may be attempted. If, however, an artificial fistula be established, the ease of treatment is greatly increased. The case is then treated as a chronic apical abscess with fistula.

In no case should hydrogen dioxid be forced in quantity into the pus occupying such an abscess cavity until the fistula has been made, and it is better even then that the bulk of it be washed out with warm water before applying the drug. A neglect of this precaution may bring about great pain, owing to the rapid reaction of the hydrogen dioxid with the pus and blood present. In some cases hydrogen dioxid has forced pus into remote locations without destroying it.

CHRONIC APICAL ABSCESS WITH FISTULA.

Morbid Anatomy and Pathology.—This form of chronic abscess occurs as the result of the discharge of an acute abscess through the gum or other part of the surface of the body, and whether the fistula has naturally occurred or been artificially established. (The interior of the mouth or other cavity exposed to contact with the air is considered external to the body proper.)

If the acute abscess has been severe or long continued, the tissue destruction may be great, but, as a rule, granulation promptly sets

in and the walls of the abscess cavity organize into cicatricial tissue. From the interior of this a canal (fistula or sinus) lined with cicatricial tissue leads to the surface, the pus being almost constantly formed at the expense of the granulation tissue, which is as constantly renewed.

The fistulous opening, as a rule, appears as a small teat of inflamed tissue located, in the majority of cases, upon the buccal surface of the gum, about a quarter of an inch below the apex of the root and slightly distal to it—a position probably determined by the density of the tissues surrounding the acute abscess. At times the only evidence of a fistula is a small spot of inflammation surrounding a minute opening, from which pus exudes. The fistula is sometimes located upon the lingual surface of the gum. It may perforate the bone of the hard palate and open through the mucous membrane of the roof of the mouth (Fig. 557). Instead of finding exit by a direct path through the buccal or lingual alveolar plate and gum, the pus may burrow along the length of the pericementum and discharge at the neck of the tooth, and simulate a pyorrhea pocket (Figs. 542 and 543). One-half or more of the lateral aspect of the pericementum may remain vital, although involved in a chronic inflammation, the remainder being destroyed. Not infrequently the pus burrows along the surface of the bone and discharges at a point over an edentulous portion of the jaw. This is

Fig. 559

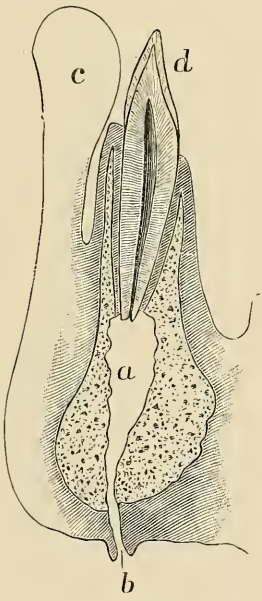

Chronic alveolar abscess of the root of a lower incisor, with abscess cavity passing through the body of the bone and discharging on the skin beneath the chin: *a*, very large abscess cavity; *b*, mouth of the fistula. (Black.)

Fig. 560



Chronic apical abscess on mesial root. Ultimate result of a pulp capping. Editor's practice. (Skiagraph by Hagopian.)

common to a lower bicuspid. It may burrow in the direction of the apices of other teeth, destroy their pulps and thus cause an abscess, having added causes for persistence.

When the apices of the roots of upper posterior teeth lie in very close proximity to the floor of the antrum, perforation of this floor may occur before tissue destruction has proceeded far enough in other directions to afford escape to the pus (Fig. 545). Extensive pus accumulations may occur in the antrum in consequence, and when the tissues in the antral floor are affected, other teeth may be involved. It may discharge into the cavity, in connection with acute abscesses; at such points the discharge may remain persistent. Sometimes the discharge occurs through the canal of the affected tooth; the canal then acts as a fistula (Fig. 538). Upon a lower tooth, particularly the incisors, the pus may burrow downward through the cancellated tissue of the bone and emerge at the base of the bone and open upon the face (Figs. 560 and 561).

Fig. 561

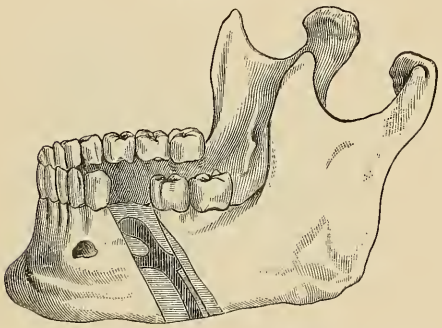

Fistula passing down through the body of the lower maxilla. (Black.)

Fig. 562

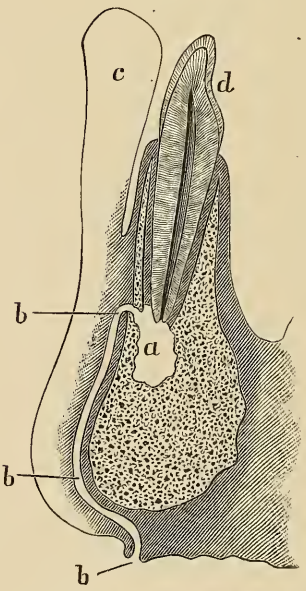

Chronic alveolar abscess at the root of a lower incisor, with a fistula discharging on the face under the chin: *a*, abscess cavity in the bone; *b*, *b*, *b*, fistula following in the periosteum down to the lower margin of the body of the bone and discharging on the skin. (Black.)

In other cases the pus may perforate the bone and find passage along the submuscular tissue, opening upon the face or neck (Fig. 562). The apices of the roots of teeth lying beneath the line of insertion of the mylohyoid muscle may cause an abscess to open in the neck cavity. Cryer records a case where an abscess opening upon the face immediately anterior to the line of the facial artery

was traced to the root of a lower molar; the direction of the sinus is shown in Fig. 563. In a case having a similar anatomical association the pus penetrated the bone lingually, was encapsuled beneath the internal pterygoid muscle, and appeared as a swelling at the inner aspect of the angle of the jaw. Another case dissected along the muscles of the neck and discharged at the clavicle. Occasionally the apices of the roots of lower molars are separated from the inferior dental canal by only a thin lamina of bone, so that discharge into this canal may occur with infiltration along the vessels and nerves in the canal (Fig. 254). While discharge into the nasal chamber is most frequently associated with abscess upon the central incisors, abscesses upon molars may discharge into the same cavity.

Cementum infection occurs as a sequence to death of the cement corpuscles from lack of nutrition. Pus calculi may also form on the roots in the long continued cases. The granulation tissue springing up about the parts has a resorbent action and the root ends are often resorbed, though this action is probably to an extent counteracted by the alkalinity of the pus. The formation of the latter may however, be in abeyance at times.

The extent of tissue destruction varies considerably, but is usually greatest in dependent parts, gravity influencing the burrowing of the pus.

Symptoms and Diagnosis.—A fistula is seen upon the gum, visible as either a small teat of flesh (perhaps pedunculated), discharging pus, or as a tiny orifice in the gum surrounded by inflamed tissue, and from which pus may be squeezed (Fig. 544). As a rule, a soft silver probe may be passed to the apex of a nearby root, whether possessing a crown or embedded in the bone. In case of an external opening upon the face a similar procedure shows the trouble to lie with some tooth root. The *x*-rays will sometimes be valuable in determining the exact location of the abscess cavity.

Upon the teeth themselves but four conditions may cause a fistulous opening: (1) Moist gangrene of the pulp or its equivalent apical infection; sometimes the sinus is at the oral end of a broken root; (2) septic perforations, apical or lateral; (3) a pericemental abscess (see Pericemental Abscess); or a secondary abscess associated with a pyorrhea pocket (see Pyorrhea Alveolaris); (4) lateral abscess about a third molar or impacted tooth.

Aside from these, the probe may lead to carious or necrosed bone, a cyst, or a subperiosteal abscess (maxillary periostitis).

In these cases the probe does not lead to a root. Carious bone will impart a honey-combed sensation to an excavator; necrosed bone will be exposed and firm, or the sequestrum will be in evidence

as a movable body. There may also be several fistulas and extensive inflammation of the tissue. A cyst will be a tumor with certain characteristics, and an impacted tooth will usually impart the feel of smooth enamel to the instrument, though the enamel may at times be rough at certain points. An embedded root will be movable,

Fig. 563

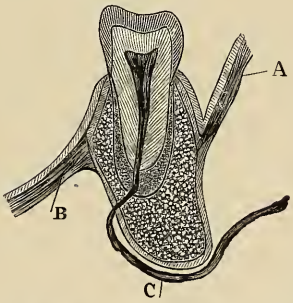

Abscess with tortuous sinus, opening upon the face: *A*, tissue of cheek; *B*, floor of mouth; *C*, abscess tract.

Fig. 564

Large abscess cavity in relation with a lateral incisor, complicated by an impacted supernumerary tooth beneath the nasal spine. (Philadelphia Dental College Museum.)

Fig. 565

Abscess and resorption at apex. (Skiagraph by Lodge)

and will present the dentin and its central opening, the pulp canal, as diagnostic features. Maxillary periostitis will, as a rule, have a history of traumatism, or the previous use of a probably infected hypodermic needle[1] associated with it. In all cases not clearly due to other than dental causes, evidence of the four dental conditions mentioned should be sought.

Treatment.—In cases arising from sources not dental, surgical interference for the removal of the cause is necessary. This may require a minor or major operation, according to the case.

In the purely dental cases the cause must also be removed. If due to pericemental abscess, this is to be treated. If due to a septic

[1] Boenning, Dental Cosmos, 1902

perforation not yielding to treatment by way of the root canal, the fistula may be enlarged, packed open with antiseptic cotton or gauze applied on successive days, and when the perforation is exposed it may be filled with amalgam. If properly done the fistula should heal. If this operation be impossible, the root should be amputated at a point between the perforation and the crown. If the perforation be in the middle or cervical third of the root, it may at times be treated from the root canal. A good method is to force root-filling material through the perforation and fistula and to smooth it off through the sinus. Stiff oxychlorid of zinc or oxyphosphate of copper are excellent. If incurable, the entire root must be amputated in case of a multirooted tooth. In case of a single-rooted tooth the tooth must be extracted, and if the conditions warrant the operation the root may be perfectly sterilized, properly filled, and then replanted after the associated abscess cavity has been surgically obliterated. (See p. 624.)

In the cases due to moist gangrene of the pulp the canals must be freely entered, the apical foramen opened with Donaldson or other cleansers, and the canals and abscess tract thoroughly sterilized.

The canals are flooded with a formaldehyd solution, mechanically enlarged, and if possible made continuous with the abscess cavity. It is then filled with hydrogen dioxid. With a Swiss broach upon which cotton is wound a plunging force is exerted upon the fluid in the canal. This tends to drive it into the abscess cavity and out of the fistula, flushing and sterilizing the abscess tract. This is then repeated. Antiseptic liquid soap may be used. If this simple procedure be not effective, a thread of cotton saturated with carbolic acid should be placed in the canal. Pressure is then exerted with gutta-percha, as in pressure anesthesia. A bit of cotton roll should be used to guard against burning the tissues. Phenolsulphonic acid may be forced through the apical foramen and fistula in some cases.[1] This dressing may be left until the next visit. A third method consists of filling the crown cavity with gutta-percha or vulcanite rubber, forcing the nozzle of an abscess syringe through the mass, and driving down the piston of the syringe. In all these procedures except the initial sterilization, the unaffected roots of multirooted teeth are to be avoided so far as possible, as undue pressure may excite an abscess The fistula will admit the nozzle of the syringe,

[1] Acid phenolsulphonic consists of 97 parts, by weight, of concentrated sulphuric acid and 93 parts, by weight, of phenol, kept at 100° C. for about twenty-four hours to produce a reaction, when sufficient distilled water is added to make the liquid assay about 80 per cent. of phenolsulphonic acid. (Buckley, Lilly.) Prinz, in Cosmos, April, 1912, gives some good reasons for its inferiority for any purpose to sulphuric acid.

Fig. 566



Minim syringe.

Fig. 567

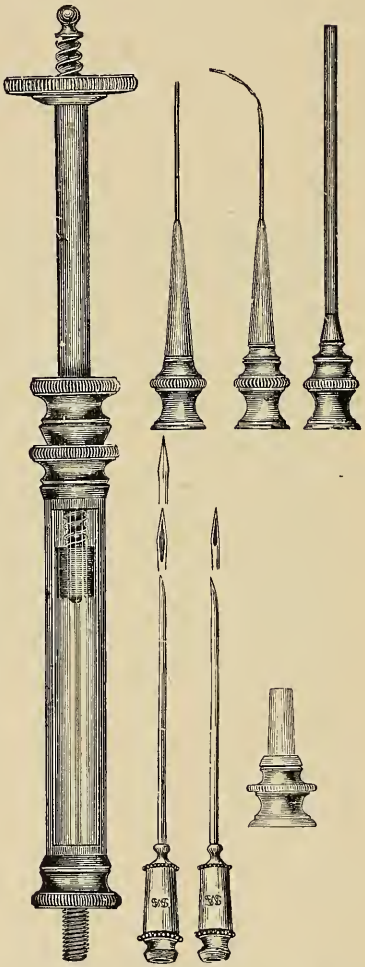

J. N. Farrar's alveolar abscess syringe.

Fig. 568

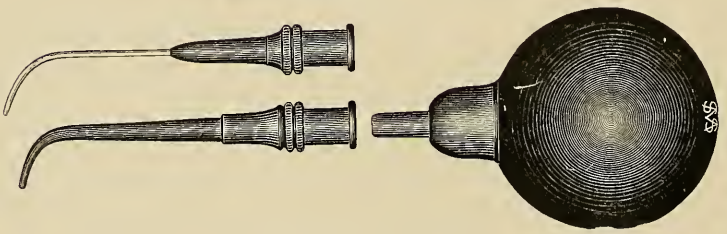

Bulb syringe.

which may be used to flush out the abscess tract with hydrogen dioxid.

The nozzle of a hypodermic needle may be fitted to the canal by packing wax, temporary stopping, or raw vulcanite about it; a piece of flexible tubing may be previously stretched over the free end and later the other end of the tubing stripped over the compressed-air syringe. Medicaments or air may thus be blown through the fistula. The method should be cautiously used in fistulous cases only, except for reasons well known by the operators employing them, as very painful distention of the cheek may occur. (See p. 576.)

The rubber cup shown in Fig. 569 may be used as a vacuum pump to draw the pus from the fistula or to draw medicaments through the canals.

All preliminary work having been done as well as possible, formocresol is to be pumped into the abscess tract and the canal temporarily stopped with the same antiseptic on cotton. With this treatment the discharge of pus should cease and be replaced by serum. It is good practice to resterilize the canal and fill it as soon as this result is noted, or, in emergency cases, the canal may be filled at the first sitting after prolonged germicidal work. The fistula then will probably heal uninterruptedly in the vast majority of cases. In a week or two the fistula should have healed if attached to treatable canals; for the difficult canals subjected to germicides only more time may be required, but healing usually eventually occurs owing to the removal of the cause.

If the abscess cavity does not heal one of several causes may be assigned: (1) The crypts in the walls of the abscess cavity may require further disinfection; (2) the cotton in the canal may have absorbed pus formed after an interval of antiseptic influence and may keep up the infection; (3) the root canal may not be explorable; (4) the root end may be encrusted with calculus, or the cementum be infected, or dead bone may be present.

For the first condition the canal and abscess tract may be treated with 10 per cent. zinc chlorid, or mercuric chlorid may be added to hydrogen dioxid (1 to 500 or 1 to 1000) and the abscess cavity syringed out at intervals. For the second condition a non-absorbent dressing should be used, such as forma-percha, or the root apex may be permanently filled with gutta-percha. In the fine, unexplorable canals 25 per cent. pyrozone may be used for twenty-four hours, as though bleaching the root, or Rhein's cataphoric method (see p. 556) may be employed. In some cases abscesses require some weeks to heal, but eventually do so, particularly if the abscess be syringed out with an antiseptic every third day *via* the fistula,

and the abscess tract filled with balsam of Peru or paraffin and aristol. Beck's bismuth paste may be injected for skiagraphy or to stimulate the fistula. Opening the fistula daily with a probe or needle aids healing from the bottom out.

Tissues about abscesses have an inherent tendency to repair; cases of long standing frequently healing promptly, sometimes, though not often, in twenty-four hours.[1]

In indolent chronic inflammation the use of a small gum dry cup with vacuum bulb attached may be used for five or ten minutes at a time several times a day, to draw fresh blood and effusions into the inflamed part. The opsonic index of the lymph drawn in is said to be raised to several times beyond that of the body lymph, thus rapidly increasing phagocytosis in the part. The rubber cup shown in Fig. 569 may be left imperforate and furnished the patient for this purpose.

FIG. 569

Rubber cup to be used as a vacuum cup.

FIG. 570

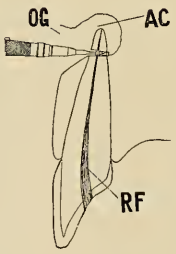

Amputation of root apex: *OG*, opening in the gum made by packing fistula; *AC*, abscess cavity; *RF*, root filling.

For the fourth class of cases the apical foramen should be sealed and the abscess tract syringed once a week with 25 per cent. sulphuric acid, the mouth and clothing being properly protected by using a pad of cottonoid over the fistula and needle to absorb the excess. This dissolves calculi and disinfects dead cementum. It also stimulates the soft parts to a granulative action. If necessary the patient should receive appropriate systemic treatment, especially if anemic. (See p. 637.) In this way some old and somewhat obstinate cases may be induced to heal. In some cases gravity so retains pus in abscess cavities that granulation is interfered with. The

[1] Darby, Proceedings of Academy of Stomatology, Philadelphia, 1899.

instruction of the patient in the syringing out of the tract with a mild antiseptic several times a day is of great value in that it removes pus which if retained would destroy granulations. Hydrogen dioxid should not be used except in small abscesses as it may cause the forcing of pus to distant areas. Many apparently desperate cases heal of their own accord after some months. Some success attends the packing of a root with a thick paste of iodoform in any oil after opening the root as far as possible. Cases in which a canal was not explorable for any considerable distance have healed after this treatment. The *x*-ray application, made for ten or twenty seconds, or skiagraphy seems to aid the healing of the fistula. The high frequency current also is a stimulant. If the abscess be incurable by the above method, or radical measures being considered better, the root

FIG. 571

A skiagraph of apical abscess cavity about two root apices; incurable by ordinary means.

FIG. 572

The same after root amputation.

FIG. 573

The same thirty days later, showing a certain amount of new bone formation. (Price.)

end may be amputated, after canal filling as far as possible with gutta-percha. The fistula is enlarged and packed open with antiseptic gauze or cotton, or sandarac varnish dipped into powdered orthoform applied until the root end is fairly in view. After sterilization of the abscess cavity and local anesthesia, a dentate fissure bur or a Schamburg surgical bur is laid upon one side of the root at the level of the healthy tissue, and carried laterally with a sawing motion until the root end is separated. It may readily be picked out. If the root can be correctly located without packing the fistula the part may be anesthetized and a portion of gum may be cut away with a tubular knife, or an incision may be made, after which a fissure or surgical bur may be used to cut away the root. Any necrosed bone may be removed at the same time. A skiagraph to act as a guide is necessary when the fistula is not packed open.

Necrosed root ends may occasionally be seen projecting through the gum and alveolar process which have been lost above them. They should be removed as above indicated. Sometimes salivary calculus deposits on them.

Antiseptic gauze or cotton saturated with balsam of Peru should be packed into the abscess cavity after operation to stimulate granulation. The quantity of gauze should be gradually lessened until the cavity is nearly healed. It should thereafter be kept sterilized by means of hydrogen dioxid until the cavity has healed. An alternative is to inject into the cavity Beck's bismuth paste:

℞—Bismuth subnitrate	30 parts
Vaselin	65 parts
Paraffin	5 parts
Wax	5 parts

Mix while boiling.

which excludes septic moisture, is antiseptic, and stimulates granulation. Stimulation by means of fused silver nitrate or sulphuric acid or scarification is at times necessary. Bone should gradually be deposited about the roots (Figs. 571, 572, and 573). Failure indicates some condition of sepsis; presumably the amputation has not included all septic root or the canal filling is defective.

A still more radical method of surgical treatment involves the extraction and replantation of the root, if worth while. The mouth is sterilized and the tooth extracted, care beng taken not to injure the enamel with the forceps. It is then placed in a 1 to 1000 solution of mercuric chlorid at 120° F., or phenol sodique, 20 per cent. The apex of the alveolus is in the meantime sterilized with hydrogen dioxid plus mercuric chlorid and thoroughly curetted. Bleeding is checked with the same solution or phenol sodique, 20 per cent., and a tampon of cotton saturated with the latter is packed into the alveolus. The replantation may be deferred for a few days if the parts are badly infected. In such case granulation is permitted.

Returning to the tooth, the apex is cut off slightly beyond the denuded area and smoothed; the pulp canal is well opened from the apex, all debris removed from it, and it is then well sterilized with sodium dioxid or 25 per cent. pyrozone. The canal is then dried and filled entirely with gutta-percha, or partly with gutta-percha and the operation completed with gold, which is nicely smoothed. The tooth should be handled in an aseptic napkin or one wet with the antiseptic, and when ready should be returned to the sterilizing solution. All being ready, the tampon or granulations are removed, the tooth washed in sterile water and replaced in its socket, and a previously prepared retaining appliance cemented to place. This

should remain for six weeks and be replaced should indications demand it. If the tooth be valueless for replantation purposes. the operation of transplantation may be done either immediately after extraction of the offending tooth or a few days later. The possibility of resorption of the root after plantations should have careful consideration, though it is not prohibitory.

The operation of transplantation may be done with a tooth recently extracted from another mouth or with a dried tooth, or, preferably, one kept in alcohol and glycerin, which many extracting specialists habitually retain to oblige applicants. If a suitable tooth be not obtainable, a root may have a crown mounted upon it in such manner as to have an open joint at a point to be placed beneath the gum line, and this joint should be filled with cohesive gold and polished. The tooth root is, of course, sterilized previous to and after the crown mounting, and its canal should have been thoroughly filled with gutta-percha. Any of these may become firm if thoroughly splinted for a proper length of time. The alveolus should be made to fit the root snugly by means of a bone reamer. The operation of implantation differs from this only in the fact that it is done where a tooth alveolus has been obliterated by combined absorption and bone formation, as after extraction (see p. 142). If the tooth be not lost by resorption, it is probable that some resorption occurs—toleration then ensues and bony deposition in the bays of resorption and about the root occurs. Possibly a true ankylosis (which see) may occur.

To select a proper tooth make a model and bite from an impression taken before extraction or immediately thereafter, cut off the offending tooth from the model, ream out a socket in the plaster; select tooth, and fit in place; attach with a little soft plaster, the model being thoroughly wet. Construct the retaining appliance, remove the tooth, sterilize, and fill the root; then put the tooth in the sterilizing agent until needed. Mendel-Joseph and Dassonville[1] have shown that in case of removal of a portion of the pericementum the lost portion may be regenerated.

Greenfield[2] has introduced an artificial root made cribriform of platinum soldered with pure gold. Special instruments of varied sizes are necessary to correspond with the sizes of the roots. Under due aseptic precaution the gum is cut with a tubular knife, and the socket drilled with a circular trephine, which preserves a core of bone, and the root covered with Beck's bismuth paste is inserted. Later a crown is mounted or a bridge attachment constructed.

[1] Dental Cosmos, 1906, p. 1059.

[2] Ibid., April, 1913.

The reader is referred to the article for details. The editor has had no experience with this method.

Fig. 574

Tubular knife for cutting gum.

Trephine with central starter later removed.

Fig. 575

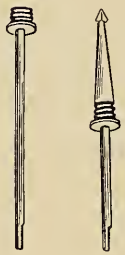

Trephine with central starter removed.

Fig. 576



Artificial socket drilled in bone, a core being left.

Fig. 577

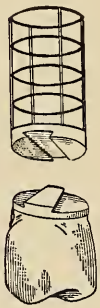

Artificial root and crown separated.

Fig. 578

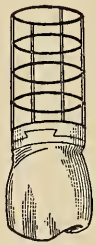

Artificial root with crown in place.

Fig. 579

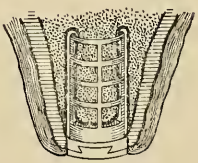

Artificial root in place.

Several cases of fistulous openings into the antrum have been noted by canal exploration in which no history of discomfort from antral empyema could be obtained. It was assumed that the root ends approximated the floor of the antrum, and that the abscesses were of simple chronic type. Such cases were treated upon the common principle of canal antisepsis, flushing the abscess tract with an antiseptic, and filling the canals. The antral condition was explained to the patients, who were warned of possibilities, but such as yet have not been reported.

A chronic abscess may discharge into the maxillary sinus for a long period before being discovered, unless the pus accumulation be extensive, when it escapes from the antrum into the cavity of the nose, discharging by one side. Smaller accumulations of pus find exit in the recumbent position, and attention is called to one antrum as the seat of affection by noting that in the morning pus appears at but one nostril. The discharges from purulent nasal catarrh appear upon both sides.

FIG. 580

Two artificial roots in drilled sockets. Greenfield. (See text.)

A more common history of antral empyema is the patient's complaint of dull, heavy pains and uneasiness over one side of the face, and an offensive odor, which may not be evident to the operator. High transillumination of the tissues about the mouth and through the cheek, by means of the electric mouth lamp of 20 volts capacity, the patient being in a dark room, may reveal an opacity on one or perhaps both sides, indicating the presence of fluid in the antrum. A clear pinkish transillumination is a sign of health. Tumors in the antrum entirely obstruct the light. Examination of the posterior teeth will show one of them to be pulpless, if the cause lies in apical abscess. If such a tooth be extracted, a profuse flow of pus may follow, and a probe may be passed through an alveolus directly into the antrum.

The diagnosis may be assisted by *x*-rays, both antra being radio-

graphed for comparison. Raper[1] states that the shadow does not actually demonstrate the presence of pus; but that something abnormal exists whether pus or a soft tumorous growth, the appearance being the same. It, however, locates the disease, whether in the

FIG. 581

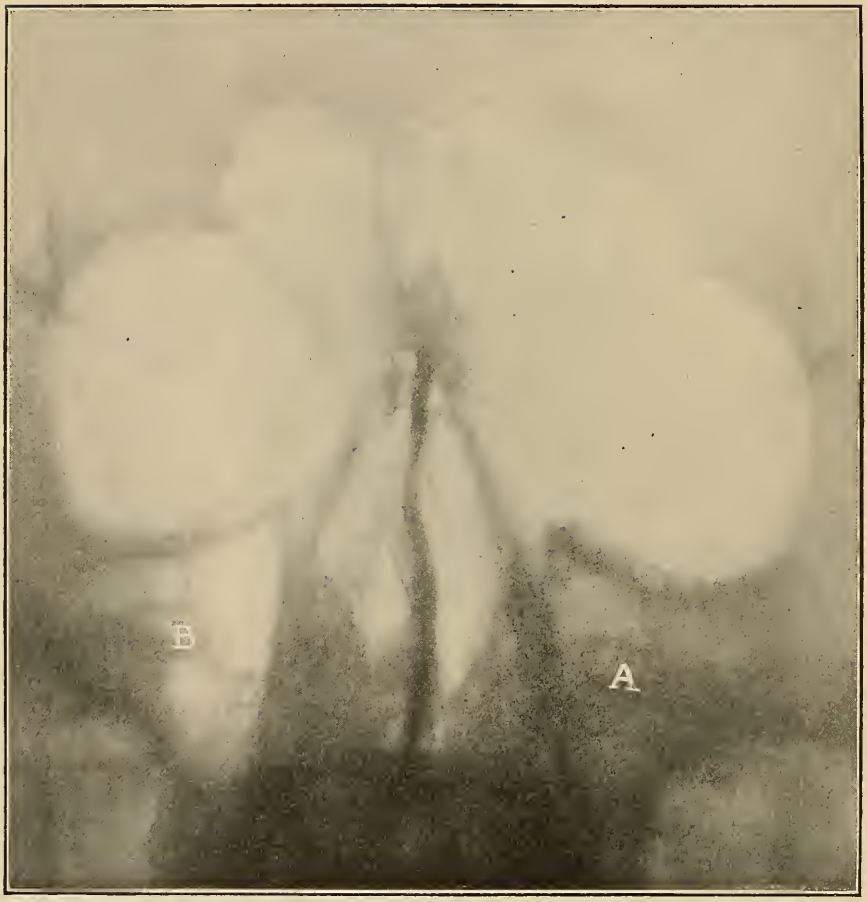

A, antrum with pus in it. *B*, healthy antrum. (Radiograph by Carmen of St. Louis.) Courtesy of Dr. Howard R. Roper.

antrum or other sinuses. The presence of opaque foreign bodies, as a piece of tooth root causing disease, is shown by skiagraphy.

Although extraction is the usual surgical relief, dental conservatism rebels against the immediate condemnation of the offending

[1] Items of Interest, July, 1912.

tooth. Efforts at curing the antral condition through the pulp canal are well-nigh hopeless—the antrum is entered at some other point. The tooth is treated as any infecting root; is sterilized and filled. The most certain spot of entry to the antrum is about one-quarter inch above the buccal roots of the upper first molar or between the roots of the first and second molar. The part, or the patient, is anesthetized, and the soft tissues incised or a section removed by means of a tubular knife; a drill or trephine at least one-eighth inch in diameter, driven rapidly, is passed upward, backward, and inward, piercing the thin shell of the antrum at this point. The opening is made of convenient size to admit of thorough exploration. The nozzle of an atomizer or syringe, filled with a mild antiseptic solution, is passed into the antrum and the cavity is freely sprayed. A probe or the finger is passed into the cavity and an exploration made to detect the presence of any dead bone or

Fig. 582

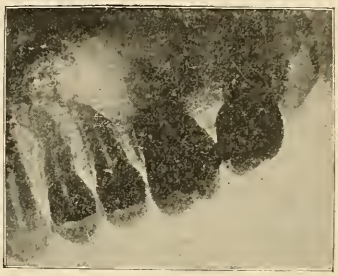

Emypema of antrum due to abscess upon root of bicuspid tooth. (Radiograph by Price.)

Fig. 583



Scar caused by alveolar abscess discharging on the face. (Black.)

Fig. 584

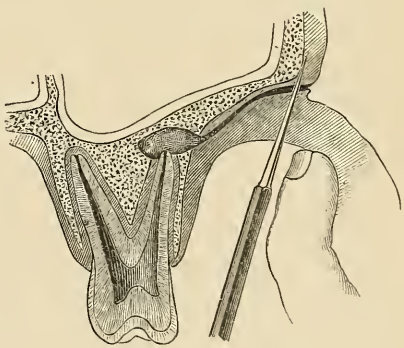

Operation for the remedy of scar on the face caused by alveolar abscess. (Black.)

bony septi, which, if found, must be removed, the cavity of entrance being enlarged to permit their removal. The antrum is then packed with gauze impregnated with iodoform, etc. After a few days the

cavity is sprayed about every other day with very dilute, warm Dobell's solution, Lugol's solution, or sterile ocean water. (For further information see works on Oral Surgery.) The opening either heals of itself or may be made to do so by the use of caustics or stitching the parts.

Unless necrosis of bone occur, cases of fistula opening upon the face or neck may be healed by the ordinary methods of canal treatment, carried out with extraordinary care to accomplish the irrigation of the fistula, or at least sterilize the apical tissue. The scar formation is less than when extraction is practised for the removal of the cause. If the fistula be indolent, the granulations may be stimulated by means of an injection of 10 per cent. silver nitrate solution. If the fistula obstinately refuse to heal, the tooth should be extracted and necrosed bone, if any be present, surgically removed, though amputation of the root apex may be tried.

Flagg[1] suggested, as a means of lessening scar formation, that a seton be passed through the external fistula into the mouth, and that it be gradually drawn into the mouth as the external fistula heals, after which the tooth is to be extracted if otherwise incurable.

In fistulæ discharging upon the face the formation of scar tissue may bind the tissue of the cheek tight to the bone. When this occurs beneath the tip of the chin, the scar, after healing, usually resembles a dimple, and calls for no interference. The scar and binding down along the border of the inferior maxilla, or beneath the malar bone in the upper maxilla, may produce deformity calling for remedy (Figs. 583 and 584). Black's operation is to be performed to lessen the deformity, for its complete correction is not practicable. A finger placed in the mouth draws the cheek away from the alveolar wall, when the exact position of the cord of attachment is discovered. A tenotome knife is passed into the tissues, dividing the band of attachment; a long pin is passed through the most depressed portion of the scar, its centre, the long ends of the pin resting upon the face; strips of adhesive plaster laid upon the skin under the head and point of the pin will prevent the latter sinking into the soft tissues. The pin is retained for several days, until the cut in the mouth heals. The principle involved is the supplying of a new section of scar tissue which, while it shrinks, makes the total length of the cord greater, hence less binding.

Systemic Complications.—The cachectic, debilitated, anemic, tuberculous, and syphilitic are liable to extensive pus formation, which enlarges the cavity unduly and may involve the roots of other

[1] Lectures on Dental Therapeutics.

teeth or even cause devitalization of their pulps, which aids in the continuance of the abscess by adding a fresh cause.

In such cases all the dead pulps should be removed after careful diagnosis, and the patient should be instructed in the use of a Sub. Q. syringe and a mild antiseptic, the object being to keep the dependent parts free of pus and allow granulations to form rather than be constantly broken down. In such cases hydrogen dioxid should be avoided as it may force undestroyed bacteria into remote parts.

In addition, such systemic medication or remedial measures as will raise the recuperative and resistant powers of the tissues should be employed.

If very persistent, a vaccine may be employed, after the method of Wright, to raise the opsonic index. (See p. 63.) The direct results of infection, toxemic and septicemic, have already been considered. Grieves contends that many root ends remain necrotic and develop blind abscesses and their sequelæ (which see).

Chronic Blind Apical Abscess.—A true blind abscess is one without a point of discharge. It is a result of septic contamination from root canals, a condition in which bacteria in unfilled root apices or in the interspaces between a root filling and the canal wall find their way into the fluid entering such a space and produce putrefaction—a condition practically analogous to moist gangrene of the pulp; or else bacteria in the blood arising from some other source, dental, tonsillar, or other focus, or entering to form a general blood infection, enter an apical region previously weakened as by pulp removal, apical irritation by root canal filling, a previous abscess, etc., and develops a chronic apical abscess.

An apical abscess is formed and the apical tissue acts as a fibrovascular envelope or sac. Under the pus pressure and the pumping force of masticatory movement, absorption of toxins and pus germs by way of the lymphatics occurs. The lymphatic glands may be involved; a systemic infection occurs.

Hartzell[1] states that Rosenow has shown that streptococci found in the mouth and tonsils can be made under suitable conditions to change into typical and encapsulated lanceolate pneumococci; or under other cultural conditions to produce organisms which locate in the joints, causing arthritis deformans; and under still different cultural conditions to produce Streptococcus viridans which is the common organism in heart-valve lesions, and under still other cultural conditions to become capable of causing ulcers of the stomach and bowels.

[1] Journal of the Allied Societies, June, 1914

In animals Rosenow has experimentally brought about heart lesions, from the bacteria in these heart lesions has caused ulcer of the stomach. From the bacteria there he has caused joint affections. From these he has produced typical pneumonia, and from the lung removed the original strain of organism which was also tested out along the series.

Hartzell has observed that when abscesses or pyorrhea pockets are freely communicating with air streptococci are most often non-hemolytic. In deep but active abscesses they are hemolytic. In long standing and blind abscesses they are non-hemolytic owing to encapsulation and the depressive activity of their own metabolic products.

Hartzell, in support of transmutation of bacteria, cites Larsen as causing the fusibacillus to develop a typical spirillum and again relapse into the fusiform bacillus. (This may account for Vincent's fusibacilli and spirilli found in conjunction in Vincent's angina.)

He quotes Schottmüller as isolating streptococcus mucosus from the lesions of parametritis, meningitis, and phlebitis and shows its biological characteristics as allied to those of pneumococcus. By experiments carefully conducted to exclude oral bacteria from septic root ends clipped into media, Hartzell developed streptococci which, entering the blood with their toxins, travel to distant points and produce systemic toxemia and local manifestations. It seems, therefore, reasonably clear that ordinarily harmless bacteria, as S. viridans and the fusibacillus, may transmute into virulent ones by a change in cultural conditions.

According to Grieves[1] the following distant manifestations may occur, as the result of combined ingestion and absorption of pyogenic cocci and the production of a septicemia and toxemia:

1. Upon the muscles, causing myositis.
2. Upon the joints, causing arthritis, synovitis, etc.
3. Upon the blood, causing septic and pernicious anemia and endocarditis or pleurisy.
4. Upon the glands, causing lymphadenitis.
5. Upon the nervous system, causing toxic neuritis and degeneration.
6. Upon the organs of excretion, causing skin rashes and nephritis.
7. Upon the gastro-intestinal tract, causing septic gastritis, enteritis, cholecystitis, appendicitis, colitis, etc.

In the kidney lesions, Hartzell notes albuminuria and casts in quantity, lessening as the local foci of pus formations are removed.[2]

[1] Dental Cosmos, May, 1914, p. 568.
[2] Journal of Allied Societies, June, 1914.

The symptom-complex[1] is mainly an anemic, pasty complexion, malaise, loss of appetite, debility, night sweats, loss of weight, low fever (100°), or subnormal temperature, which, together with the local inflammation (muscles, joints, etc.), should lead to dental examination by skiagraphy for obscure conditions as blind apical abscess or the investigation of septic conditions under crowns, bridges, etc. (as septic gingivitis, septic spaces under crown bands or in the cement, gangrenous tooth pulps, pyorrhea alveolaris, fistulæ leading to chronic abscess, tonsillar or sinus infection. In short, any source of sepsis, some of which may require the services of other specialists.

The abscesses are within the bone of the jaw while the dental symptoms may not be noticeable though the tooth may be slightly tender and there may be tenderness upon pressure over the apical region. There may be pain about the eyes or in the back of the head or neck. The postcervical glands may be enlarged. The fact that teeth have apparently been attended to is no warrant that septic conditions are not present, these conditions embracing any form of gingivitis or of pericemental infection, including pyorrhea. a blind abscess may at any time become acute, and finally establish a fistula, sometimes irregularly and without much pain.

BONE INFECTION ASSOCIATED WITH DENTAL LESIONS.

During the course of acute and chronic abscess the bone-marrow becomes inflamed by the pyogenic organisms and is broken down into pus. The condition may continue after extraction for apical abscess in the second stage, or if necrotic bone result in advanced pyorrhea. It may also occur from the bruising of the periosteal lining of the alveolus as the result of extraction of a hypercementosed root, or from a bruise induced by forcible use of forceps in the removal of deeply seated roots.

The walls of the alveolus become infected by pyogenic organisms, among which the Diplococcus pneumoniæ figures prominently.

The leaving of cotton tampons, placed as vehicles for pain-relieving agents, for an undue length of time also invites infection.

If during extraction the alveolar margins be lacerated, and especially if the bone be uncovered by clot, or the clot fail by solution, it also becomes infected and ulcerated, as shown by its suppurating and highly irritable surface; later the surface becomes insensitive,

[1] Dental Cosmos, May, 1914, p. 569.

indicating superficial necrosis, which may become progressively deeper. The clot seems to fail at times after extraction with anesthetics containing adrenalin or suprarenin. In some cases the socket may be free of blood for several minutes after extraction. Ragged gum margins may become gangrenous, although sometimes not. After extraction any loose margin of gum or rough edges of process should be trimmed up.

Symptoms.—The symptoms are those of local inflammation without necessarily much swelling of contiguous tissues, such as occurs in acute abscess. Some circumscribed swelling may occur, indicating an abscess in association with it, or a diffuse swelling, indicating inflammation of contiguous tissue. The orifice may appear as though normal, but close examination demonstrates a sinus leading to ulcerated or necrosed bone. If due to an acute abscess in the second stage, the symptoms of that condition may continue. As a rule, the patient presents within a week of the date of extraction, complaining of pain.

In the majority of cases the pain is of a deep, boring, continuous character. Reflex pains are also produced about the face. Much debility is caused by the wearing character of the pain, the loss of sleep and appetite, and probably also because of absorption of toxins. The gum margins are perhaps sloughing; the bone may be exposed and exquisitely painful to touch, or it may be necrotic and insensitive superficially. The case is one termed "dry socket."

Cases of general septicemic or pyemic infection from this source have been recorded.

Treatment.—The mouth and, in so far as possible, the inflamed part must be sterilized. Probably mercuric chlorid in hydrogen dioxid (1 to 1000) will answer best. If the solution be used hot, whether it be mercurialized or not, the pain is much relieved.

An injection of a 1 or 2 per cent. solution of cocain into the healthy tissue overlying the alveolus will assist in alleviating the acute pain and partly anesthetize the parts. All sloughing gum should be cut away. Exposed bone should be anesthetized by strong cocain solutions if painful to touch, or the patient should be anesthetized if necessary. Whether acutely inflamed or necrotic, the bone should be cut away with large sterile burs until healthy tissue is reached. After washing out the debris and further sterilization a clot is to be induced by curetting if necessary. The mouth is to be kept sterilized and, the patient is to be seen daily for a repetition of the curetting if the clot fail, or the alveolus may be gently packed with cotton saturated with balsam of Peru alone or with castor oil, equal parts, as a stimulant. In ordinary cases one or two local treatments

will be effective, but the tonic, antiseptic, systemic medication recommended under the heading of acute apical abscess is advised.

As a stimulant for granulating sockets, tincture of iodine diluted with equal parts of tincture of aconite or alcohol is valuable because of its irritant and disinfectant qualities. The socket is wiped with it daily.

If the infection be of aggravated character, precautions in the form of suitable systemic medication should be taken against a possible septicemia. (See p. 604.)

If the patient be not willing, or is unable, to bear this operation at the first visit because of the demoralization produced by the pain, an alternative proceeding may be adopted. A pellet of cotton wet with campho-phenique should be rolled in powdered orthoform and introduced into the socket after sterilization with iodine, or a stiff mass made from orthoform, zinc oxid, and vaselin may be packed into the alveolus as an antiseptic and anesthethic. (Jack.[1]) Trichloracetic acid in saturated solution, or silver nitrate, or aromatic sulphuric acid may be used as a special stimulant and the balsam packing renewed. The repetition of this after five to eight hours will afford marked relief. Later the radical operation may be performed if granulation does not set in. The introduction of cotton or gauze dressings into the alveoli for relief of pain immediately following extraction is to be done only with extreme care and for short periods, as such dressings are apt to be left in place by patients, and, becoming septic, act as causes of sepsis of the alveolar process. It is better to induce a clot if the removal of the cotton is not followed by hemorrhage. While alveoli will fill with granulations in the absence of a clot filling them, such a clot seems to be the best protection against sepsis and a depressed scar tissue. In some of these cases portions of bone may exfoliate. In one obstinate case the capsule of bone surrounding the apex of the alveolus came away.

EXTENSIVE NECROSIS ASSOCIATED WITH CHRONIC ALVEOLODENTAL ABSCESS.

The illustration (Fig. 585) is that of a case of necrosis with two external pus sinuses along the lower border of the mandible, associated with great pain on recumbency, rise and fall of body temperature, and occurrence of stupor and coma. The operation consisted of ex-

[1] International Dental Journal, 1905.

traction of the cuspid and first bicuspid, removal of the sequestrum, curettement of bone, and drainage.[1]

Fig. 585



The white line is artificial and shows the extent of the sequestrum (see text). (Skiagraph by Raper.)

Every chronic alveolodental abscess carries with it the danger of bone complication. It has been shown that in bone infection the organisms are highly virulent. Fortunately in most cases the involvement is slight and the parts care for themselves when the cause is removed. In more aggravated cases, either caries or necrosis of the bone may follow. Pus is formed at the expense of the parts, and sometimes infiltrates the surrounding soft and the hard parts, causing the loosening of teeth. This may occur even though the causal tooth be extracted. In caries the pus escapes by several fistulæ and examination leads to porous dead bone. In necrosis there is circumvallation of a portion or portions of bone, and finally one or more sequestra are loosened, and later, in part, liquefied. The remainder gradually works out of the fistula as one large or numerous small pieces. The patient may be much debilitated. In syphilitic or strumous cases an otherwise simple case may positively refuse to heal until the physical condition is improved by antisyphilitic

[1] Practice of Dr. Gilmer, description by Howard R. Raper, Items of Interest, July, 1912.

or tonic treatment. Surprising recoveries of extensively necrotic parts occur if the patient be brought into good physical condition, and the parts are antiseptically treated, the thorough loosening of the sequestra being awaited. By this means teeth have been retained in place and covered with new tissue, which operation would have exposed or removed. The determination of the point at which operative interference is desirable must depend upon the particular case and the amount of deformity likely to result from the operation. In some marked cases with toxemia, drainage must be obtained surgically, even if extreme operation be necessary.

Honl and Bukovsky are credited with the successful treatment of bad chronic suppurations by means of local applications of pyocyaneoprotein.

Jensesky[1] so treated a case of six months' standing, incurable by ordinary antiseptic and systemic treatment, and obtained remarkable results. Vaccine therapy is also useful.

Syphilitic intoxication or that of scarlet fever may cause a necrosis of alveolar bone, as may mercury. (See p. 231.) The extent to which the teeth or oral infection act as active exciting causes depends upon the condition present.

SEPTIC APICAL PERICEMENTITIS COMPLICATED BY PERFORATION.

In the treatment of root canals the required mechanical work sometimes results in (1) the passage of the drill through the apical foramen, enlarging it; (2) through the side of the root, causing a perforation.

In the first variety the complication chiefly concerns the root filling, which is to be conducted after sterilization upon the same plan as for filling an incomplete foramen. (See p. 555.)

If a lateral perforation be made near the root apex, it may be filled after sterilization with a cone similarly applied, but made bevelled at the end, or a bit of aseptic sponge may be introduced against the tissue for a base and be covered by oxychlorid of zinc. The packing of a fairly stiff mass of zinc oxychlorid into the root and through the perforation into the fistula has caused the healing of several obstinate cases continually weeping pus or serum. The moisture, if slight, rather aids the adaptation of the cement. The same treatment used with greater care is useful in chronic abscesses without fistula. It is well to fill only the apical portions of canals in

[1] Dental Cosmos, 1901.

either case, so that any removal for another trial may not be too difficult; the later filling of the coronal portion of the canal is very simple. The use of a stiff paste of zinc oxid and eugenol or even oxyphosphate of copper in the same manner is useful. If possible, it is well to irrigate the fistula with water to remove any excess, though if left it usually works out of the fistula, which later heals or not, as the case may be. If septic conditions persist, the root end must be amputated, or the tooth extracted, prepared, and replanted. If made in the middle third of the root, the canal must be sought for and treated as usual beyond the perforation, which is then separately treated with a gutta-percha cone, or a plaque of gutta-percha may be laid over the perforation and antiseptic cements or copper amalgam used to secure it in position. Extraction and replantation may be resorted to, but amputation does not serve so well, as the root leverage is lost and the tooth may loosen. In a

Fig. 586

Skiagraph of crowned curved root, with perforation and protruding root filling near apical foramen. With septic conditions, would require root amputation. (Price.[1])

Fig. 587

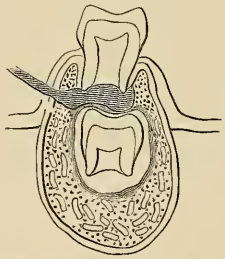

Showing the relations of an abscess upon a temporary tooth, with the crown of a developing permanent tooth underlying it.

favorable case, after canal exploration, a tapering probe may be passed into the canal and copper amalgam gently tamped about it and against the perforation; the probe is then withdrawn, leaving a central canal, which is later treated. Girdwood has reported good results from the use of copper amalgam, which, in this connection, the writer can confirm. In a few cases the fistula has been packed open and the perforation filled with amalgam through the sinus. The cases are mostly successful, but in one case healing did not occur until treatment after filling was suspended for several months.

Chronic Septic Pericementitis in the Temporary Teeth.—Any of the chronic septic conditions described may occur upon the temporary teeth. The presence of resorption and of the permanent crown

[1] Items of Interest, 1901.

usually confines the inflammation to a point lower in the alveolar process than in the case of permanent teeth. The loose character of the structure causes the ulceration to occupy a larger area, and the parts in chronic inflammation look more angry, but are fairly well tolerated. The treatment is practically the same for the curable cases; the others should be extracted. The root canals when treated should be filled with absorbable materials, such as paraffin or wax combined with aristol. Buckley recommends, as a canal filling in these cases, the use of a stiff mixture of calcium phosphate and formocresol (formalin, 1 part; cresol, 1 or 2 parts), to be packed into the pulp chamber and zinc phosphate quickly flowed over it; the cavity to be filled later.

Johnson[1] suggests that a eucalyptol solution of gutta-percha (see p. 551) be pumped into the canals and pressure exerted with temporary stopping until the solution appears at the fistula. The temporary stopping that does not interfere with filling integrity should be left.

Chronic Septic Apical Pericementitis (Non-purulent).—Continued apical inflammation of a low grade probably is a condition analogous to blind chronic apical abscess or the infection leading thereto.

Cause and Pathology.—The cause consists of unremoved gangrenous pulp tissue, septic serous collections in canal apices or about imperfect root fillings, or septic material in the root tubuli, all much the same in character. A very common cause is an otherwise good root filling which has failed to fill the apical portion of a curved fine or even well-opened root. While in skilful hands gutta-percha points and oxychlorid of zinc usually reach their apical destination, the editor has met unfilled apical canals after good operators as the most common of operative errors.

An imperfectly filled perforation may cause a similar condition, which, however, the *x*-rays should determine.

Albuminous fluid may enter the canal *via* the apical foramen, and, becoming infected, putrefaction ensues. The source of infection may possibly be *via* the blood, but leaking crown and root fillings more probably permit bacteria to enter from the mouth. The more or less constant result of filling roots with cotton permeated with evanescent materials only is evidence of this. The cotton absorbs fluid either from about leaky fillings, too often placed in contact with it, or else from the apical tissues; infection readily occurs and a highly odorous cotton is removed because of the apical irritation. When the cotton is well placed and confined under

[1] Dental Cosmos, 1899.

tight-sealing materials to the apical half of the root canal, this result is long delayed in many cases. Portions of gangrenous pulps

Fig. 588

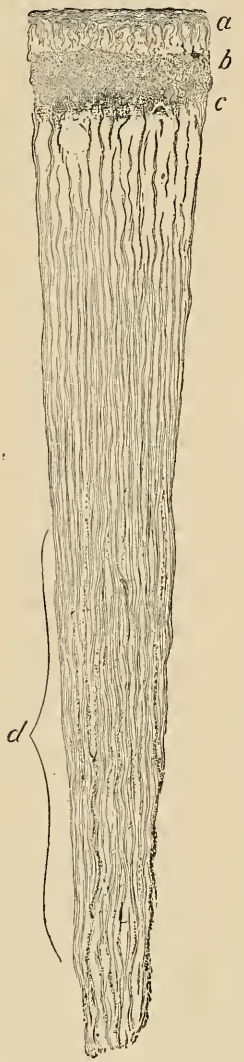

Sector of a cross-section from a diseased root: *a*, cementum; *b*, stratum granulosum; *c*, very narrow and finely branched tubules; *d*, penetration of bacteria into tubules. × 150. (Miller.)

Fig. 589

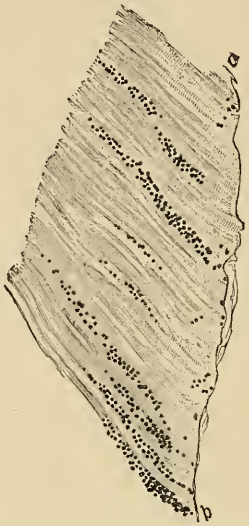

Dentin from the root of an abscessed tooth, showing the penetration of cocci to a depth of about $\frac{1}{10}$ mm. ($\frac{1}{250}$ in.); the side *a* to *b* bordered upon the canal. × 1000. (Miller.)

remaining in canals may likewise become infected. Extra and untreated canals are frequently causes.

Miller[1] has shown that root tubules are infected only for a short distance at their canal ends, so that infection from the pericementum *via* the cementum and dentinal tubules is highly improbable (Fig. 559). The putrefaction produces gases, and these exuding slowly produce the irritation. If pyogenic organisms be present, apical abscess may at any time supervene.

Mayrhofer[2] has shown that even formocresol fails to sterilize all

[1] Dental Cosmos, 1899.

[2] Items of Interest, March, 1910.

tubuli, so that bacteria, especially streptococci, grow back into the canal. If the canal filling be imperfect it is obvious that apical infection may arise.

Symptoms.—Subacute inflammation of apical tissue being present, the symptoms of this condition are tenderness upon decided pressure or upon percussion; the response may only be elicited by pressure or percussion in one direction. The tooth gives a dull note upon percussion, and is usually looser than its neighbors. The red line of the gum extends farther toward the gum margin than normal—quite to it in some cases. There is apt to be a response to heat.

The patient is apt to avoid the tooth in mastication. In some cases acute reflex pains in other teeth may precede an outbreak of acute purulent pericementitis, a frequent sequel to this condition. There are also evidences of previous devitalization of the pulp in opacity, lack of response to tests for vitality, etc. At times a history of previous canal treatment may be obtained or the evidences of an attempt at canal filling may be seen upon opening the tooth. The systemic symptoms if any are those mentioned under chronic apical abscess.

Diagnosis.—The condition requires careful differentiation from (1) non-septic apical pericementitis due to traumatism or malocclusion or to a perforation imperfectly filled; (2) pericemental abscess in the early stage; (3) abscess of the pulp in the later stages. In nearly all these cases the pulp may be vital. Being itself only subsequent to death of the pulp, tests for vitality are made. (See p. 563.) If pulp death be indicated by the tests, the pulp canal is explored, and, if found, treated and filled; a septic condition about or beyond the same is looked for.

There is great disadvantage in a large apical opening, particularly in the dressing and root-filling operation.

Treatment.—The condition being analogous to that of moist gangrene, or blind apical abscess, the treatment is the same. Before it can be applied the root canals should be opened, and to accomplish this all root fillings involved require removal. If an extra canal be found after apparently conscientious work has been done, this should receive attention before removing root fillings.

The bulk of gutta-percha root fillings are best drilled out with Downie broaches revolved in the engine hand-piece or by hand, eucalyptol being used to soften or dissolve the gutta-percha.

All cement fillings are removed by a drill so far as can be safely done, dryness being a great aid in locating the cement in the canal. When the danger of perforation arises, a stiff Swiss broach or a fine Downie broach may be rubbed down to a drill edge and used as a

tamp drill. Sulphuric acid in 50 per cent. solution or aqua ammonia aid by dissolving the cement.

The object sought for is an unfilled canal lumen, which, when found, is readily recognized by the ease of penetration with the broach and the absence of sensation until the apical tissue is reached. The fact that the sides of the root canal can be felt is assurance of safety against perforation which may occur in any case.

There can be no assurance of safety until the apical tissue can be explored, but perforation must be avoided. The fine Downie broach is useful in difficult cases, and, if necessary, a No. 1 Beutelrock drill may be used. When the apical foramen is open, or further work is impossible without the danger of perforation, the canal treatment is conducted upon the lines laid down for gangrenous pulp. (See p. 579.) A difficult class of cases sometimes presents in which the disease supervenes and where work which may be regarded as desperate has been done, or where pins have been inserted and are almost impossible of removal, as, for example, where a Logan crown, has been cemented to place. In such cases the idea of Watkins in applying blue light directly by means of a funnel may be of great value in reducing inflammation, and mild applications of the *x*-rays or the high-frequency violet ray may be useful, but sometimes the work must be carefully dismantled to permit retreatment. An *x*-ray should always be first made as a guide.

If the pericementitis have been of long standing, the thickening of the membrane will have caused protrusion of the tooth. The tooth should be ground off at its point of occlusion until it occludes with somewhat less force than its neighbors, the therapeutic principle in these cases being that of removing the source of irritation and procuring surgical rest. Indications of favorable results are found in the red gum line assuming its normal position, tenderness disappearing, and increased tightness of the tooth.

This affection is extremely common about the roots of pulpless teeth, and always signifies more or less enforced disuse of the teeth, and, if uncorrected, their ultimate loss.

This condition is sometimes associated with a chronic blind abscess. (See p. 631.) Upon treatment, acute apical abscess is apt to be lighted up; therefore the sterilization should be prolonged and thorough to avoid acute apical abscess. In one case of a cyst associated with a lower molar tooth which had a leaky gutta-percha crown and partial canal filling, extraction was advised for reasons other than canal treatment. The cyst then promptly developed as an acute abscess, which shifted its position toward the cheek and there discharged without production of scar.

Septic Pericementitis at Bifurcations of Multi-rooted Teeth.—Teeth weakened by caries may fracture after filling in such a manner that the line of fracture exposes the pericementum at the bifurcation. The crack admits septic saliva, and a filling or fillings usually sink gingivally, wedging apart the two sections and admitting more or less food matter. If the canals of the sections have been previously treated and filled, it is usual to find a more or less general pericementitis due to the wedging and septic irritation. It subsides upon sterilizing by means of a douche, while gentle broaching removes the accumulated debris. Formocresol, diluted with phenol camphor to a 5 or 10 per cent. formalin strength, is to be placed in the pulp cavity and covered with sandarached cotton, and a ligature of silk or wire is to be tied about the tooth to draw the parts together. A hollow metal crown is to be constructed and before placement a little oxyphosphate of copper or oxychlorid of zinc cement is to be worked into the joint, which is temporarily sprung open. The part may be joined by amalgam built into a dove-tail (Fig. 312), or a trephine may be driven into the face of the crown and a metal ring be cemented into it (Fig. 316).

If the canals be septic, an apical abscess may complicate the condition and require treatment while the fracture is being handled. In some cases a metal staple may be placed in the canals of the two sections and so arranged as to spring the parts together when forced to place. The joint should have one of the cements worked into it before this staple is cemented to place. About the staple quick-setting amalgam should be packed, a copper band having been previously adjusted to act as a matrix. Later, this band is to be removed and a porcelain-faced gold crown or a porcelain crown baked on a heavy wide platinum band and cap arranged to sustain it (Fig. 294).

The staple may be utilized as a portion of a crown base of the Richmond or other variety, the bifurcation and crown cementing being deferred until the final operation. Irritation may arise in some of these cases, which, however, need not prevent the trial of the method as a last resort.

The methods of tooth salvation here indicated are subject always to the general principle of extraction when advisable. In no case should teeth in inoperable condition be saved at the expense of the individual through constant pus formation.

CHAPTER XXI.

NON-SEPTIC PERICEMENTITIS.

Various grades of pericemental irritation, ranging from a mild arterial hyperemia to actual inflammation, may be produced by non-septic causes.

The most satisfactory evidence that inflammation may be so caused is furnished by Talbot's experiments with the mercurialization of dogs. Beginning with healthy pericementi, these were, after mercurialization of the animal, found to contain the round-celled infiltration characteristic of inflammation, and no bacteria could be found. Further evidence is given by the usual experimental study of inflammation with the mesentery of the frog. Simple irritation, even with antiseptic substances, produces the phenomena. Any of the causes which may produce inflammation may, if acting in more mild degree, produce arterial hyperemia. If the action of the cause be violent and then discontinued, as in the case of a blow, the inflammation resulting is acute, but may pass into a chronic form; but if the cause continue to act it produces a chronic inflammation.

For purposes of description, non-septic pericementitis may be divided, according to its character, into traumatic and symptomatic, and, according to its location, into apical and general.

TRAUMATIC PERICEMENTITIS.

By traumatic pericementitis is meant a profound irritation of the pericementum, the result of mechanical violence applied externally to the tooth, or of instrumentation or chemical irritation of the pericementum through the root canal.

Causes.—Violence Externally Applied.—Excessive force delivered directly upon the teeth, as in case of blows, falls, overmalleting in building fillings, the biting of nuts, thread, or other hard objects, or force indirectly delivered, as in case of blows received under the chin, bringing the teeth forcibly together, may all cause acute pericementitis.

An excessive amount of filling on the occlusal surface of a tooth, a maloccluding crown or overful fillings upon the proximal aspect,

maintaining a wedged condition, cause overocclusion upon the tooth and an irritation of its pericementum.

The overstraining of the pericementum of a tooth as the result of overuse, as in cases where only a few teeth remain for mastication, or where pyorrhea or calculus has caused resorption of the alveolar process and looseness of the teeth, or where artificial dentures are clasped to remaining teeth, or where bridges are supported upon insufficient piers, are frequent causes of non-septic pericementitis of a degenerative character. The presence of a rough flaring or a too deeply placed crown band beneath the gum margins, portions of cement used in cementation of crowns, or excess of filling material beneath the gum, are all causes of marginal gingivitis, with which pericementitis may be associated. With these marginal cases septic causes usually have to be considered as complications.

Too violent wedging is always followed by more or less pericementitis of the wedged teeth, and their neighbors, more marked when elastic-rubber wedges are used.

In correcting irregularities of the teeth, if they be moved too rapidly, are not firmly directed during the operation, or, subsequently, not firmly maintained in position, pericementitis of a high grade is frequently excited. (See Overuse and Malocclusion of Teeth.)

Violence Internally Applied.—If a wholly or partially vital pulp be torn from its apical connections, as in the use of pressure anesthesia, an apical traumatic pericementitis may be set up. This is usually transient. Secondary hemorrhage may occur and produce pericementitis.

Excessive laceration of the apical tissue by means of barbed instruments, the inclusion of air or medicament under a root dressing or filling, the same exercising pressure upon the apical tissues; the mechanical irritation of a projecting root filling, pivot wire, broach, or drill, are all sufficient causes.

The undue enlargement of the apex of the root canal or the passage of a reamer through the lateral aspect of a root may excite inflammation, and the perfect filling of the opening may be exceedingly difficult, so that if the tissues are not infected at the time, sepsis may later follow.

Chemical Irritation.—The application of arsenic to a perforation may excite inflammation and necrosis, which endangers the jaw. (See p. 528.) The use of arsenic as a pulp devitalizer may cause a hyperemia of the apical tissue, following the hyperemia of the pulp, and causing slight tooth extrusion, which is aggravated by the malocclusion. This is not dangerous. (See p. 521.)

The undue use of escharotics, such as carbolic acid, sodium dioxid,

zinc chlorid, sulphuric acid, or mercuric chlorid, in a pulp canal may excite an undesirable irritation. The limited irritation following their limited use is often more than offset by the advantages of the asepsis produced.

Prophylaxis.—Many of these causes are avoidable, and operators mindful of possible irritations should avoid the mechanical irritation of apical tissues, neutralize powerful acids or alkalies, use escharotics with caution, wedge teeth gradually, and after wedging either pack gutta-percha between the teeth to permit them to rest for a few days or fix them immovably with wooden wedges or steel separators during malleting.

During orthodontia teeth should be moved steadily, and after alignment is secured they should be firmly maintained in position until deposition of bone occurs.

Patients should be warned against the evil effects of thread biting and biting hard substances.

Pathology and Morbid Anatomy.—Chemical substances applied in excess cause a destruction of tissue dependent upon the quantity used. Inflammation tending to the resorption of the dead tissue occurs. The pericementitis presumably persists in some degree until the foreign (dead) material is removed by natural processes.

In the case of protruding foreign bodies, such as root fillings, broaches, etc., there is a tendency of the inflammation to become subacute or chronic. The foreign body may to an extent become encysted, particularly in the case of a gutta-percha root filling. In other cases the continued vascular disturbance, if of mild degree, produces hypercementosis; in more severe cases resorption of the root occurs.

Cases due to perforation of the root and wounding of the pericementum, after the acute symptoms have passed, commonly assume an irritative and chronic type, the soft tissues included in the perforation being in a state of chronic inflammation. Many of these cases become infected owing to the difficulty of completely sterilizing the apical portion of the canal which lies beyond them.

The pericementitis produced by pressure of included air, liquid, or plastic root filling upon the apical tissue is often severe. Upon removal of the root dressing or filling the engorgement is relieved by the gushing of blood through the root canal. The inflammation may, however, continue unless sedatives be applied to the apical tissue *via* the canal.

In cases due to traumatism, such as violent wedging, rapid movement in regulating, overmalleting, blows, biting of thread, ice, nuts, etc., the condition is surgically one of bruise.

The phenomena of active inflammation make their appearance to an extent governed by the degree of violence—exudation, swelling, redness, and pain; fibrinous and corpuscular exudations occur, and later a reorganization of tissue occurs, in some cases a degeneration, depending upon the completeness with which the indicated therapeusis is applied and upon the vitality of the pateint.

Traumatic pericementitis in high degree in the young may be recovered from; but in the middle aged and aged it may give rise to a series of degenerative changes which end only with the loss of the tooth.

In cases due to looseness of the teeth, of course, septic primary causes have to be considered, but the pericementitis may be quite as much mechanically as septically produced.

In all cases the extrusion caused by the inflammation adds another exciting cause of apical pericementitis—*i. e.*, malocclusion, which aggravates the condition.

Symptoms and Diagnosis.—The amount of pericemental inflammation present is evidenced by the soreness and extrusion of the tooth and the degree of redness in the overlying gum tissue.

A history of violence may be obtained when it has occurred. Malocclusion may be detected by occlusion marks upon fillings or by means of carbon paper. The untoward results of canal operations may be inferred from a personal knowledge of the case or, perhaps, from the history. It is at times difficult to exclude septic, nonpurulent, apical pericementitis as a cause, particularly if the case come from the hands of another practitioner. In doubtful cases the treatment for inferred traumatisms may be employed, and if followed by good results a *post hoc* diagnosis of traumatic pericementitis may be made. The *x*-rays afford a means of determining extruding root fillings, broaches, etc.

Treatment.—Foreign bodies protruding from the root apex must be removed if persistent symptoms demand it. This may require an artificial opening for its performance, or root amputation. Perforations should be carefully treated.

If evidence of pericementitis persist, the end of the root including the perforation should be amputated, or if the tooth persistently extrude, the tooth may be extracted, the perforation and canal filled with gold or gutta-percha, and the tooth replanted under antiseptic precautions.

In all cases due to violence the treatment is that adapted to injury; first, surgical rest of the pericementum. This may be accomplished in two ways: either by preventing the tooth striking its antagonists or holding it so rigidly that it cannot move if it does meet them.

As a preliminary measure the tooth is gently but firmly lashed to its neighbors by means of ligatures so that it is rigidly held. A swaged cap is either fitted to a neighboring tooth, or the antagonizing teeth are ground away until they fail to strike the injured tooth; the first method is to be preferred.

In cases involving several teeth, such as all of the incisors, two metallic plates are quickly swaged to cover posterior teeth and raise the bite, and they are cemented in position to relieve the irritated teeth from occlusion.

When the apical tissues have been irritated by way of the canal, sedatives, such as strong tincture of aconite or menthol in chloroform phenol-camphor, eugenol, or menthol-phenol[1] (menthol, 3 parts; carbolic acid, 1 part; melted together) or thymophen should be applied on cotton to the apical tissue by way of the root canal. All cases of traumatic pericementitis require the persistent use of counter-irritants, applied every other day to the overlying gum. (See p. 476.)

Systemic derivation is also useful in the acute cases. In even mild cases not due to violence the guarding of the extruded tooth against malocclusion is of advantage.

If the cause be some mechanical irritant at the gum margin, this should be removed and the case treated as above described. Recognizing the possible influence of septic causes, oral antiseptics are to be used.

SYMPTOMATIC NON-SEPTIC PERICEMENTITIS.

By symptomatic non-septic pericementitis is meant an aseptic pericementitis occurring as the result of systemic conditions, or of the action of drugs taken internally.

If mercury be administered to patients in large doses for long periods, or in one or more massive doses, or if the patient have an idiosyncrasy to the action of this agent, or be a worker in mercurials, an irritation of the salivary glands is excited, followed by looseness and soreness of the teeth and swelling of the gums; that is, a general pericementitis and maxillary periostitis arise. The patient has a metallic coppery taste, coated tongue, and fetid breath; the gums are puffy and bleed easily. In advanced cases the tongue and cheeks are swollen. Potassium iodid administered in this condition relieves the maxillary periostitis and pericementitis; but the same drug administered in health, or for conditions other than mercurial poisoning, also causes irritation of the pericementum. Pilocarpin

[1] Dr. Morgan Howe.

has a similar effect, though in much less degree. All of these drugs are partially eliminated by the glandular appendages of the mouth, and during elimination apparently act as local irritants. Lead poisoning may have a similar action. A blue line appearing on the gums is symptomatic. It occurs in painters and workers in lead. Lead has been found in the calculus on the teeth and even in the tooth substance.

Patients who have a gouty heredity, or who are the subjects of active gout, frequently exhibit a tenderness of the entire pericementum of one or more or sometimes all of the teeth. This pericemental disturbance may be the precursor of an acute outbreak of gout in the metatarsophalangeal joint.

Scurvy—a very rare systemic disease—is attended by rapid degeneration of the pericementum of the teeth and of the alveolar tissues.

Syphilis is also attended by pericemental irritation. This, of course, is of septic origin.

Talbot's experiments on dogs show conclusively that a true pericementitis may be induced owing to the chemotactic properties of the mercury alone. (See Interstitial Gingivitis.)

In auto-intoxication by intestinal toxins or by leukomains in diseases involving general malnutrition, the irritants are probably in part eliminated by the gums, which are in turn irritated. (See Pyorrhœa Alveolaris.)

It has been shown by Loup that mercurial stomatitis may be cured by mercury used as an oral antiseptic; therefore, the logical conclusion is that oral organisms play a part in the production of the local effects of mercury; probably the mercury produces a local predisposition. This is further confirmed by the fact that if the teeth are attended to and oral prophylaxis be practised before the administration of mercury to syphilitics, they tolerate greater amounts of the drug before salivation or stomatitis.

Treatment.—The drug should be discontinued, the disease, if present, should be antagonized, and the local complications, if any, should be appropriately treated, antisepsis being always advisable. If the pericementitis, gingivitis, and stomatitis be mercurial, the drug should be stopped and an antisialagogue used, such as atropin sulphate, $\frac{1}{100}$ gr. each four to six hours, until relieved.

Potassium chlorate as a mouth wash, or internally, is useful if the stomach is not irritable.

℞—Potassii chloratis . . . . . gr. xlviij
Tr. myrrhæ . . . . . f ʒss
Elixir calisayæ . . . . . q. s. ad f ʒiij—M.
Sig.—Teaspoonful every five hours, or use as a mouth wash. (Hare.)

Results of Chronic Non-septic Pericementitis.—If at any point of the irritated pericementum a constructive grade of irritation be maintained, the cemental tissue becomes hypertrophied (Fig. 590). If a more severe grade of irritation—*i. e.*, low-grade inflammation—be present for a long time, the cementum and even the dentin of the root may be resorbed. Both of these results may go on concurrently at different points, or resorption may be followed by deposition of cementum if the conditions change.

Chronic overuse or disuse of teeth results in degenerations of the pericementum. (See p. 661.)

HYPERCEMENTOSIS (DENTAL EXOSTOSIS, EXCEMENTOSIS, HYPERPLASIA OF THE CEMENTUM).

Definition.—By hypercementosis is meant a secondary deposit, or an increase of volume of the cementum of a tooth beyond the normal limit. It may be circumscribed or diffuse.

Causes.—A constructive degree of hyperemia or very mild inflammation is the proximate cause, which may be excited by numerous primary causes, such as a projecting root filling, a projecting edge of crown filling, deposist of salivary calculus, the overlapping of a cavity margin by the gum, malocclusion, non-occlusion, the biting of hard objects, such as nuts or thread, the overuse of certain teeth, the habitual tapping together of teeth, the habitual chewing of tooth-picks, the gradual pressure of gas from dead pulps. The pressure of a

Fig. 590

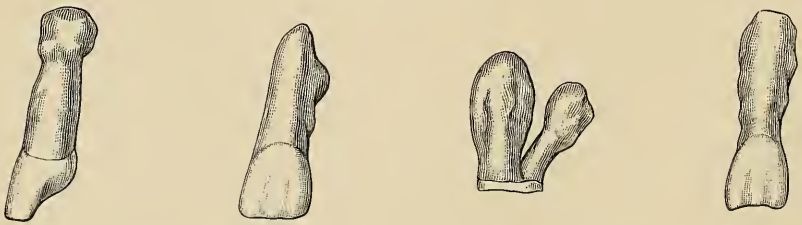

tooth root against another root during eruption is a sufficient cause. (See Fig. 173.) The overcrowding of teeth in an arch has also caused this condition, as has also the impaction of a tooth (Fig. 218). Chronic alveolar abscess or pyorrhea alveolaris may cause it by inducing about itself at a distance an area of hyperemia. (Aseptic Area.) It also seems at times to be induced after pulp devitalization from any cause. Hypercementosis is a possibility in any case of chronic pericemental irritation; it represents a degree of irritation

rather than any one specific cause. It has been discussed by some writers under the heading of Constructive or Condensing Pericementitis, and is fairly analogous to osteosclerosis. (See p. 144.)

Fig. 591

Hypercementosis. (Skiagraph by Lodge.)

Situation.—Hypercementosis may be diffused over almost an entire root or several roots, or be localized as a distinct nodule at some lateral aspect, or exist as a circumscribed enlargement about the apex of a root, or at the neck of a root. It is always located where the cause (hyperemia) has been produced (Fig. 590).

Fig. 592

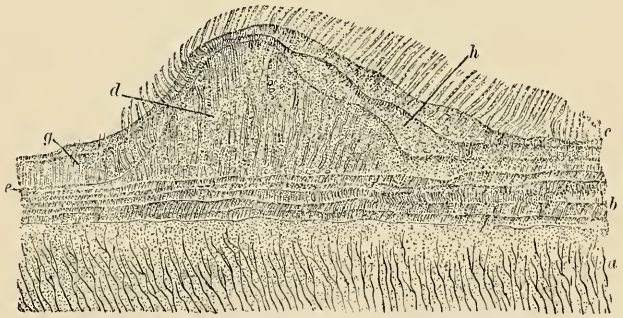

Hypertrophy of the cementum on the side of a root of a lower molar near the neck of the tooth of a man: *a*, dentin; *b*, cementum; *c*, fibers of peridental membrane; from *b* to *c* the cementum is normal and the incremental lines fairly regular, but at *d* one of the lamellæ is greatly thickened; at *e* this lamella is seen to be about equal in thickness with the others. The next two lamellæ are thin over the greatest prominence, but one is much thickened at *g*, and both at *h*. These latter seem to partially fill the valleys which were occasioned by the first irregular growth. From a lengthwise section. (Black.)

Flagg noted that 75 per cent. of cases of hypercementosis were found upon posterior teeth, and that the teeth were usually of the character termed dense—*i. e.*, the tissues of the individual were of recuperative type, tending to produce constructive changes.

Pathology and Morbid Anatomy.—For some time after eruption the cementum consists of but few lamellæ of deposit. It, however, reaches a maximum normal development at which it normally rests, as in the case of the physiological pulp cavity. As age progresses it is apt to be more thickly deposited at the expense of the pericementum, which becomes more attenuated. Whether this is due to irritants floating in the blood stream, or to the various local irritants above mentioned, or to perfectly normal development, is not clear except for certain definite cases.

Nodular and irregular forms arising from the general surface are clearly of abnormal type.

FIG. 593

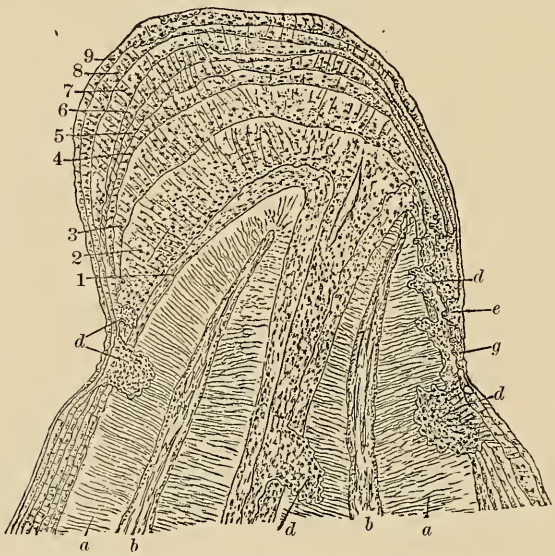

Apex of root of an upper bicuspid tooth with irregularly developed cementum: *a*, *a*, dentin; *b*, *b*, pulp canals. The lamellæ of cementum are marked 1, 2, 3, etc.; *d*, *d*, *d*, absorption areas that have been refilled with cementum. It will be seen that the apices of the roots were originally separate, but became fused with the deposit of the second lamella of cementum, and that in this regular growth began and was most pronounced. It has continued through the subsequent lamellæ but in less degree. It will also be noticed that the absorption areas, *d*, *d*, *d*, have proceeded from certain lamellæ. That between the roots has broken through the first lamella and penetrated the dentin, and has been filled with the deposit of a second lamella. Other of the absorptions have proceeded from lamellæ which can be readily made out. The small points, *e*, seem to have been filled with the deposit of the last layer of cementum, while others have one, two, or more layers covering them. (Black.)

Successive lamellæ are deposited; the pericementum recedes, causing resoprtion of the alveolar process. Union of the bone and cementum (ankylosis) very rarely occurs. A resorption of cementum and dentin may occur at some point owing to a different degree of

irritation, and in the area a new deposition of cementum may occur (Fig. 593, *d*). In some cases distinct areas of hypercementosis and root resorption are seen in close proximity. Chronic apical abscess may produce a denudation of the root end, and a short distance below an annular ridge of hypercementosis may occur. Areas of hypercementosis may be translucent or decidedly opaque, and sometimes the two are combined, a mottled appearance being produced.

If the growth proximate another root, the pericementum may resorb at the point of contact and a deposition of cementum occur which firmly unites the roots in a union called concrescence. (See p. 263.)

It has occurred that a root filling protruding through a perforation has caused a diffused exostosis of the alveolar process.[1] The hypertrophied process may be ivory-like in hardness.

Symptoms and Diagnosis.—Many cases exist without active local symptoms. In no case is the color of the gum altered unless other disease than hyperemia be acting as a cause. In some cases there are symptoms of hyperemia expressed as a disposition to bite hard upon the particular tooth, or to grind upon it. A paroxysm of gnawing pain lasting for some hours, and recurring at intervals, is also somewhat characteristic. Sympathetic hyperemia of the pulp with increased response to thermal changes may occur. (See p. 469.) The gum may have slightly receded.

Neuralgia, functional blindness, functional deafness, chorea, epileptiform fits, paralysis, cardiac neuralgia, insanity, and other related conditions have been cured by the extraction of hypercementosed teeth.[2]

The treatment of teeth presenting obstinate symptoms of pericementitis, apparently due to moist gangrene of the pulp, may at times be complicated by unsuspected hypercementosis.

In such cases, if pulp or pericemental complication cannot be determined, suspicion should point to hypercementosis and an *x*-ray examination be made, by which means the condition may be positively determined. As entire dentures have been extracted, tooth by tooth, in a vain endeavor to cure a neuralgia about the head, this means of diagnosis should not be overlooked.

Treatment.—The treatment for hypercementosis may first be a conservative one if only slight annoyance be produced by it.

Counterirritation—correction of malocclusion, etc.—may be employed. The symptoms may disappear. If they do not, or they

[1] Garretson's Oral Clinic, 1884.
[2] Brubaker. American System of Dentistry.

are severe when the patient applies, the tooth should be completely extracted. The operation of amputation of the root end might be safely tried for apical hypercementosis, but there are no records of its employment as a means of cure. The bulbous condition of the root end may cause extraction to be difficult, and fracture of the root end may occur. Flagg recommended that in such a case a fissure drill be passed about the circumference of the root end to remove the bony obstruction to its passage out of the alveolus, after which it may be lifted away with tweezers. In another method the root may be perforated by a drill and then divided into two sections by means of a dentate fissure bur, after which the halves may be pushed together with a small elevator. If not then removable the fissure bur can now easily enlarge the alveolar constriction. Cocain may be used as an obtundent. The use of alveolar forceps for the condition is little short of brutal, and only warranted by the impracticability of other means.

Extraction for hypercementosis may cause considerable bruising of the walls of the alveolus, followed by excruciating pain lasting often for days. The alveolus may refuse to granulate, and a septic condition result. The pain has at times been relieved by the injection of a 2 per cent. solution of cocain or novocain into the gum on either side of the alveolus, after which the surfaces of the alveolar walls should be sterilized and burred away until tissue capable of granulation is reached.

The alveolus should then be irrigated and a clot invited by causing a slight hemorrhage. (See p. 634.)

ANKYLOSIS (SYNOSTOSIS).

By this is meant the union of bone and cementum, a condition analogous to ankylosis of bone.

Hopewell-Smith[1] has described 5 cases, of which he offers the following explanation: (1) inflammation occurs and the membrane is changed into granulation tissue; (2) the cellular elements destroy portions of the bone and excavate the cementum; (3) the mass of granulation tissue is then ossified, joining the bone and cementum in a firm union.

E. C. Rice[2] has reported a case of a lady for whom an implantation of an upper bicuspid was done. In an effort made later to remove the tooth all attempts to loosen it in any degree with forceps failed.

In my own practice an implanted tooth is firmly immovable in

[1] Histology and Pathohistology of the Teeth.
[2] Private communication.

any degree, though several years in place. The union may not be a true ankylosis in these cases, though doubtless bone has entered areas of previous resorption. A remarkable case was shown the editor by Dr. J. Curry, of Philadelphia. Every pier tooth of four bridges was firmly ankylosed and immovable, yet large bays of resorption in each root necessitated extraction. This was not a plantation case.

Fig. 594

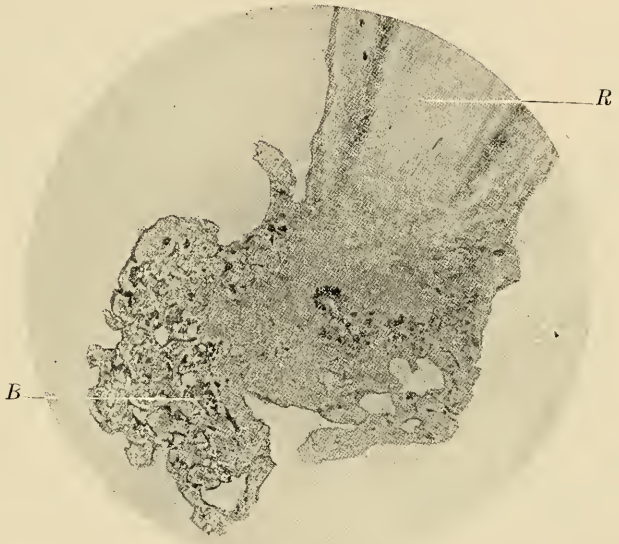

Vertical section of a human tooth ankylosed to the jaw: *R*, root; *B*, bone of jaw. The absolute continuity of the two hard tissues is strikingly shown. From the collection of the late Storer Bennett.[1] (Hopewell-Smith.)

RESORPTION OF THE ROOTS OF PERMANENT TEETH.

By resorption of the roots of permanent teeth is meant the gradual removal of the cementum and dentin of permanent roots by phagocytic cells existing in the adjacent soft tissue (osteoclasts). When occurring as the result of pressure by another tooth a tissue similar to an absorbent organ (See p. 218), as in resorption of deciduous teeth, is probably developed between them.

Causes.—The proximate cause is probably in all cases a degree of irritation greater than that required to produce hypercementosis. Probably a mild non-septic inflammation exists. Talbot's demonstrations of interstitial gingivitis, a term meant to include interstitial

[1] Transactions of the Odontological Society of Great Britain.

pericementitis, show that it is a frequent cause of both root and alveolar resorption. (See Deeply-seated Gingivitis.) In other words, it is due mainly to an aseptic pericementitis.

The disease has been discussed by other writers as "Rarefying Pericementitis," fairly analogous to osteoporosis. (See p. 144.)

Fig. 595

Fig. 596

Fig. 597



Fig. 595.—Apical abscess and resorption, produced by a protruding broach.
Fig. 596.—Deciduous cuspid crowned, mistaken for permanent cuspid which lay in jaw and caused resorption of root of permanent lateral. (Skiagraph by Price.)
Fig. 597.—Resorption at cervical third in two replanted teeth, one broken in consequence. Editor's practice. (Skiagraph by Hagopian.)

Fig. 598

Case of extensive resorption about upper central. (Skiagraph by Lodge.)

Fig. 599



Resorption of roots. (Skiagraph by Lodge.)

Of primary causes chronic apical abscess seems to be a frequent one. Although theoretically the alkaline pus formed should neutralize acid formation, the fact of resorption remains, and is probably explainable upon the ground that it is produced by the granulation tissue formed about the root apex during periods of lessened pus formation.

Protruding root fillings or broaches are common causes (Fig. 595). Plantations are frequently followed by it. A peculiar resorption

in the cervical third of two replanted incisors caused the fracture of one at the point of resorption and necessitated the removal of both teeth (Fig. 597). Plantations are usually followed by peculiar resorptions over even the entire root. Looseness of a tooth with the resultant excess of movement excites deeply-seated gingivitis and resorption of bone and often of roots. Partial luxation as the result of a blow or fall produces the same result, the pericementum becoming thickened, the tooth loosened and extruded, and malocclusion, which is also a cause, being induced.

A toothpick broken off in the gum tissue has produced resorption at the neck of the root.

Fig. 600

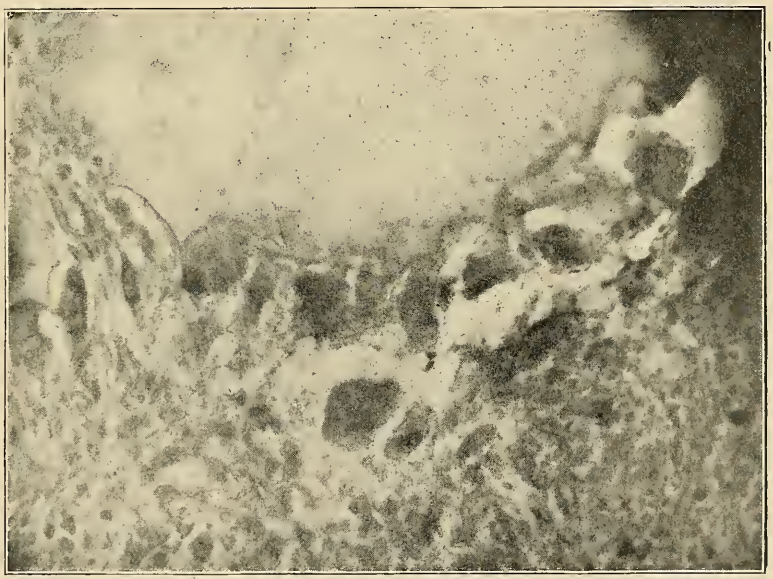

Inflamed pericementum, osteoclasts in Howship's lacunæ. (V. A. Latham)

The descent of a supernumerary or impacted tooth upon a permanent root has caused resorption, exposing the pulp of the resorbed root, and producing pulp reactions. This may be quite extensive before violent symptoms occur (Fig. 596). In one case both the buccal roots of an upper molar were removed by a supernumerary tooth, the crown of which fitted the resorbed root ends.

Resorptions also occur in orthodontia, as when a cuspid is delayed and presses upon a lateral root. The resorption may be more distant than the pressure point. In orthodontia this may be explained by the extension of the phagocytic area or the induction of such an

area about moving teeth; indeed, teeth cannot be moved without exciting a phagocytic action.

Dewey,[1] following Hertzler, claims that rickets causing imperfect calcification of teeth is liable to be a factor in untoward resorptions in orthodontia, while tuberculosis neither interferes with tooth, eruption nor calcification, but may interfere with proper physiological resorption because the phagocytes are elsewhere occupied and the absorbent organ is not fully developed.

Calculus beneath the gum margin has produced resorption through the production of gingivitis. In one case noted four lower incisors presented the characteristic bays at a point one-eighth inch below the gum line.

Some of the cases exhibit no tangible cause; the root resorbs apparently as the result of a peculiar reaction upon the part of the tissues of the individual, who may lose many teeth by this process—*i. e.*, a dyscrasia exists. The teeth may be non-carious and the pulps vital. In some of these cases neurasthenia or a uric acid diathesis seems to have some association with the condition (Fig. 601).

Pathology and Morbid Anatomy.—Both resorption of cementum and its redeposition occur in deciduous teeth as physiological processes; at some aspect of the cementum the tissue becomes hollowed out, and later filled in by new cementum. Resorption of tissue throughout the body is accomplished by means of multinucleated cells (giant cells, osteoclasts). At some part to be physiologically resorbed these cells make their appearance in contact with the tissue to be removed, and it gradually disappears, the layer of multinucleated cells constantly occupying the excavated territory known as Howship's lacunæ (Figs. 73 and 600).

If a foreign (aseptic) body be introduced into living tissues, it becomes surrounded by these cells, which in some cases effect its removal; in others, failing to remove the foreign body, connective tissue forms about it and encysts it; encystment may occur after partial removal by giant cells.

The resorption of a root may be of any extent, from a slight spicular roughness of the apex of the root to almost complete removal of the root.

Perforation of the root from side to side may occur, of course, involving the pulp canal, and, if the pulp be alive, obscure reactions upon its part may occur (Fig. 601).

An area of marked resorption may occur at a point just beneath the gum margin and upon any aspect of the tooth. In this situation

[1] Items of Interest, May, 1914, p. 358.

it may simulate a cavity of decay beneath the gum. It occurs upon either vital or devitalized teeth, and may expose the pulp of the root-canal filling. The gum tissue is usually found within the cavity.

It is probable that in plantations the root acts as an aseptic foreign body; mild inflammation occurs, subsides, and giant multinucleated cells attack the tooth root and endeavor to remove it by solution; this they accomplish, in part, in spots; then a tolerance is established and connective tissue organizes about the roots; later, more complete regeneration is represented in the formation of bone; condition of a bony fixation is established, evidenced by the clear ringing note elicited upon tapping the planted tooth.

Fig. 601

Idiopathic resorption of permanent root. The bay upon the side exposed the pulp and perforated the root as shown. Crater-like resorption about apical foramen. Pulp first devitalized on account of persistent pain and the tooth later extracted.

With reference to resorption after plantations, Miller[1] records the following results of his observations. The fixation of reimplanted or transplanted teeth may be accomplished in three ways:

1. By simple encapsulation of the root.

2. By the bundles of connective tissue which fill up irregular absorption spaces, especially where the pericementum has not been present at that portion when the implantation was made (a pseudo-attachment).

3. By direct union of the surrounding tissues with the living pericementum. He inclines to think this the only permanent attachment.

He states that for the most part osteoclasts were few and that resorption was carried on by small round cells.

The inflammatory reaction and resorption is least when replantation is practised, but may at times be pronounced in even those cases. If the socket of a tooth extracted for resorption be examined, a mass of soft tissue will be found occupying the locations corresponding to the areas of resorption (Fig. 602). No acid reaction can be detected with litmus paper, but, nevertheless, it is probable that the cells producing resorption excrete an acid capable of dissolving the tissue.

There is some evidence of this in cases of enamel resorption occurring upon the crowns of impacted teeth which have never been in relation with the oral fluids, and about which there is no evidence of

[1] Independent Practitioner, 1887

caries in the areas of dentin resorption also present. In the fortunate specimens of these cases a superficial decalcification of the enamel surface may be seen which can only occur as the result of acid action. (See p. 312.)

FIG. 602



Resorption of distal root of a first molar. (Skiagraph by Custer.)

FIG. 603

Diagram of a case of root resorption after secondary dentin had formed: *SD*, secondary dentin; *AR*, area undergoing resorption; peculiar central spire of secondary dentin which has resisted the resorbent action. Specimen in possession of Dr. A. P. Fellows.

Symptoms and Diagnosis.—The tooth may present symptoms of non-septic pericementitis, and may be loosened in advanced cases. In the early stages no looseness may be observed until a strain suddenly applied causes a luxation; thereafter the tooth progressively loosens.

The condition may be discovered by accident; evidences of mild pericementitis appear, and the pulp canal is opened to search for a cause. The pulp may be found alive; if alive, and it is killed, or if it is found dead, broaches pass suddenly into the mass of soft tissue underlying the root. The progressive loosening of the tooth, with its peculiar movement, is about the only constant symptom of the condition.

In cases of live pulp this organ may be hyperemic, so that increased response to heat or cold is felt; this, taken in connection with the tenderness upon percussion which can usually be elicited, and with the peculiar loosening of the tooth, is a diagnostic guide.

Flagg[1] stated that reflex neuralgias occur in this condition, but that the most constant indication noted by him was a sense of discomfort about the jaws, vaguely associated with some one tooth. The patient is convinced that if the tooth were removed relief would follow. In the absence of the loosening, which may not occur until the root is nearly gone, the resorption is most commonly discovered by entering the pulp canal and finding its length much shortened. In some cases the resorption may be found near the gum margin and simulating a cavity of decay, from which it may readily be diagnos-

[1] Lecture on Dental Therapeutics.

ticated by its appearance when exposed by packing the gum away. Such cases appear to accompany a marginal gum resorption.

The *x*-rays should exhibit the condition with sufficient clearness to furnish an absolute diagnosis.

Treatment.—If a diagnosis can be made, the tooth should be extracted except in the cases near the gum margin alone, which may be filled with plastic fillings. Even then the condition may progress.

DEGENERATION OF THE PERICEMENTUM.

Strictly speaking, the overuse, abuse, and disuse of the teeth are causes which produce a general hyperemia or inflammation of the pericementum (non-septic pericementitis). If continued, the inflammation extends into the gum tissue and a deep-seated gingivitis is produced. The results of the causes are, therefore, classifiable under either non-septic pericementitis or deeply-seated gingivitis. Either of these conditions renders the tissues involved liable to the degenerations and resorptions which accompany continued inflammation, or acts as a predisposing cause to local infection by oral organisms, beginning its action at the gum margin, and which sooner or later produces a purulent, or apparently non-purulent, liquefaction of the gingival portion of the pericementum (pyorrhea alveolaris).

In view of applied therapeutics it is well to consider these causes separately.

OVERUSE OF TEETH.

By overuse of a tooth is meant such a variety of occlusion that the tooth receives a greater stress than its neighbors, or than it is designed to bear. The stress may be received in the normal direction, but be excessive in amount. The most prominent cause of this condition is the loss of one or more other teeth, permitting undue stress to fall upon the neighboring teeth, or, in some cases, on far-distant teeth. Too prominent artificial crowns, particularly those of the all-gold type, cause a general increase of stress upon the pericementum. Enormously overful contour fillings may establish a similar condition. When but few isolated teeth remain in one denture and have antagonists, the teeth are certain to be overworked. Isolated and other teeth to which are attached clasps of artificial dentures or too large pieces of bridge-work, are in the majority of cases being constantly overstrained.

Pathology.—Like any other functional part which is overworked, the pericementum is first stimulated, causing the vessels to dilate. Soon evidences of overwork appear, and the condition passes into

one of interstitial pericementitis; the tooth projects, and is loosened; the overlying gum deepens in color, and evidences of venous engorgement are common (interstitial gingivitis). The result of the condition is a softening and degeneration of the substance of the pericementum; the alveolar wall is involved in the degeneration, and it melts down—is resorbed to a greater or less extent. Cases have been seen at this point with the gum margins as perfect as in any normal tooth though a symmetrical resorption of margins may

Fig. 604

Illustrating use of overarch bar. See text. Gorman.[1]

be present. In one marked case in which incisors met with a slight lingual occlusion upon the lowers, forcing them labially, the teeth were as loose as in the average pyorrhea case, but the gum margins showed absolutely no pocket. At any stage of the disturbance marginal infection may occur, and the degeneration and destruction of the pericementum be hastened by suppuration or other secondary degenerations establishing pyorrhea alveolaris.

The symptoms, diagnosis, and clinical history are given in the above description. The prognosis is the inevitable loss of the tooth

[1] Items of Interest, October, 1913.

if the causes be not removed, in which event the prognosis is governed by the extent to which the degeneration has proceeded. (See Interstitial Gingivitis.) These cases are often seen at a time when it is difficult to say which came first, the pyorrhea or the overwork, but the conditions of evident overstrain, as when posterior occulsion is largely lost, and the usually prompt response to surgical rest lead to inference that overwork started the predisposition to pyorrhea. Nevertheless in pyorrhea when the marginal inflammation has caused bone resorption to the point of tooth loosening the mechanical strain of occlusion is a cause of further overstrain and looseness.

FIG. 605

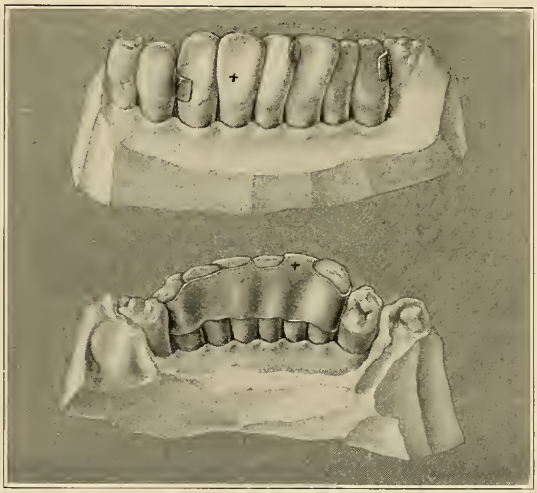

A case of pyorrhea alveolaris and overwork. Five natural and one artificial tooth mutually supported by holding against plate brace. Note restraint of right cuspid and central by clasp, artificial tooth bevels and T button and restraint of left teeth by clasp and button. This principle may be employed in ordinary plate work. Adaptation made by burnishing thin pure metal to teeth model, and stiffening with solder.

The teeth, if in overocclusion, should be dressed off until properly occluded. Prosthetic appliances should not be so attached by clasps as to unduly move the clasp teeth, especially buccolingually. The U-clasp is worthy of consideration in this regard. The appliance should support the teeth laterally, if possible, and occasionally the enclosure of the teeth by the plate clasps, with the hooks facing each other or a buccal embracing wire stay, is required, as, for example, where four lower bicuspids only are retained for support to the plate, yet where they also require support (Fig. 617). Where incisors are loose yet teeth must be inserted on plates, the judicious shaping of the natural and artificial teeth so as to afford a restraint

of the natural ones against the plate festoon is useful (Fig. 605). In some cases the festoon causes gingivitis and tends to cause loosening. This may be due to an improper looseness of the clasps permitting a rise and fall of the plate, or the inner edge of the festoon requires trimming. (A lower bar plate in which no contact except at clasp teeth is allowed because the bar lies beneath the tongue level and, of course, away from the teeth is an example of the principle involved in avoiding this class of injury). No attempt is made, however, to cause the artificial teeth to strike before the natural teeth, in the hope of giving surgical rest to these organs. Such attempts always result in failure, as they cause injuries to the tissues upon which the plate and teeth rest, which are more severe than the pericemental disturbance.

Properly adjusted bridge-work frequently does good service in these cases, provided the overoccluding tooth or teeth be first dressed down short of occlusion and are given a period of rest until the pericementum recovers. The bridge, if carefully planned, may be made to direct and control the stress received by the injured teeth. Joining the various bridges is useful. In this connection what is termed the "overarch bar" is a valuable device. The wire crossing the palate from one bridge to another on the opposite side automatically throws some of the stress received by the diseased teeth upon teeth upon the other side of the arch, which naturally are forced in an opposite direction during mastication or at least lend their support. (Fig. 604 illustrates this.)

The use of the Gilmore attachment is useful, the wire supporting the plate connects several teeth roots and gives them mutual support.

Improperly occluding artificial crowns should have this fault corrected by removing the excess of material or by setting properly made crowns. All crowns should have full mesial and distal contact, as spaces permit a wedging of teeth and injury of the interdental gum septum, as well as allow movement to occur.

Overfull fillings should be reduced to correct proportions and shape.

Surgical rest is the only hope of saving the tooth.

MALOCCLUSION OF THE TEETH.

Each tooth of a denture is not only designed to receive a definite amount of force, but to receive it in a particular direction or directions; any excess of this force, or alteration of its direction, is followed by abnormal stimulation of the pericementum and by its overstraining. The effects following a general increase of stress have been

considered under the previous heading. By malocclusion is here meant the constant reception of stress by the pericementum in directions to which it is quite unaccustomed, or which are not in accordance with the anatomical design of the tooth. It is a peculiar form of overuse.

Causes.—Original malpositions of the teeth may cause their faulty occlusion. The most prolific source of the condition is, however, altered occlusion due to those changes of position of the teeth which follow upon the loss of adjoining teeth.

Artificial crowns, which do not occlude in correspondence with the other teeth are a common cause. Improperly formed fillings are another cause.

The shifting of positions of the teeth, in consequence of pathological changes occurring in or about the pericementum, causes the crowns of teeth to occlude improperly.

Pathology.—The conditions established are those of overuse in a direction other than direct. A typical example of this condition is that of a lower second molar which has gradually tilted forward in consequence of the loss of the first molar; or a central incisor which has altered its position in consequence of secondary formations in or about the pericementum, a common precursor of phagedenic pericementitis. Some portion of the tooth, an edge, which before did not occlude with an antagonizing tooth, is brought into occlusion; if the occlusion be not unduly forcible, no immediate degenerative changes are evident. If the occlusion be excessive, the pericementum is not uniformly affected, but the greatest stress is brought to bear upon some lateral aspect of the structure. It responds in the degree of the overwork, and inflammation and degenerative changes occur, which, if the active causes be not removed, gradually spread to other portions of the pericementum, and the phenomena noted in connection with overuse occur, but are not so general in distribution. The tooth becomes more movable in one or more directions—*i. e.*, is loosened; it may develop some degree of tenderness upon percussion, and the gum color toward the affected side deepens, although it may remain normal in other parts. As in the previous cases, infection may—indeed, is likely to—occur. In some cases the pericementum may degenerate and be destroyed about one root of a multirooted tooth, and remain about the other. It is to be remembered that a less degree of irritation may produce hypercementosis.

Pyorrhea alveolaris in any form is a localized suppurative pericemental inflammation, which causes inflammation of the pericementum in general. Swelling occurs and the tooth is pushed up

into malocclusion. Other teeth are sometimes urged out of occlusion by these. Such teeth may sometimes be dressed off one thirty-second of an inch before the overocclusion is relieved. A direct result of the strain and compression brought to bear upon apical tissue is the production of non-septic pulpitis with reflex pain and response to heat and cold (see Fig. 413).

Diagnosis and Treatment.—In all malposed teeth a careful examination should be made of their mode of occlusion. If the tooth exhibit tenderness and looseness, malocclusion is almost a certainty; it only remains to determine its direction.

The spots of faulty occlusion may be determined by placing a strip of carbon paper (articulating paper) over the tips of the antagonizing teeth and having the patient bite; the spots of contact should then be ground away until the tooth is slightly short of direct occlusion. Fresh strips of paper are used, and the jaws moved laterally, as in mastication, to note other points of contact; these should also be ground away.

It suffices in some acute cases to place a rubber dam or metal cap guard upon a nearby tooth for a day or two to prevent occlusion upon the sore tooth, which regains its normal position in the alveolus as the inflammation subsides. The grinding and guarding may be combined, judgment being required.

Prognosis.—If the condition be not corrected every time occasion requires, the degeneration progresses until the tooth is lost.

If marginal infection has occurred, purulent or non-purulent marginal pericemental liquefaction (pyorrhea alveolaris) may have to be considered.

DISUSE OF TEETH.

Definition.—By disuse of teeth is meant a degree of usage less than the amount which the forms and structure of the teeth and contiguous parts fit them for. The disuse may be absolute or relative; teeth may not occlude at all, owing to the loss of antagonists or to extremely irregular positions.

Partial Disuse.—Causes and Pathology.—If soft food be used instead of that requiring vigorous mastication, or if one tooth of a side be diseased so that that side of the mouth is unused in mastication, or if one of the antagonists of a tooth be lost, the pericementi of the teeth involved do not receive their proper amount of exercise, and a degree of atony ensues.

This partial disuse has a more distinct relation to the health of the gum margin, which does not receive a normal amount of friction

from mastication, and if this be not offset, in part, by prophylaxis, marginal gingivitis ensues.

Infection and the formation of calculus increase the irritation to a marginal gum inflammation, which is liable to run into a pyorrhea alveolaris. This is the real significance of disuse as a cause.

Diagnosis and Prognosis.—A diagnosis of disuse (relative) is usually made out by inquiring as to the food habit of individuals. It is excessively common in civilized communities, particularly among the well-to-do, and is of almost constant occurrence in gourmands.

Treatment.—Patients should have pointed out to them the results of insufficient mastication, together with the evils of faulty oral hygiene. Every effort should be made, by the use of constant prophylactic measures, to forestall the occurrence of pyorrhea alveolaris. This and similar conditions are particularly to be feared in the degenerative periods of early and late middle age. It is between the ages of thirty and fifty years that ill-consequences are most to be feared from acquired debility of the pericementum.

Absolute Disuse.—Teeth which perform no work directly in mastication, or indirectly by serving as abutments for a bridge-piece, may be said to be in a condition of absolute disuse.

Results.—A tooth or root whose pericementum receives no stimulus becomes relatively a foreign body to the organism. It is a useless part, and the body attempts to cast it out. Perhaps these phrases are insufficiently exact; however, a disused tooth is lost through a series of pathological changes. It is probable that the impact of blood pressure raises the tooth an infinitesimal distance, and being without antagonism it does not wholly recover its normal position. The aggregate of these infinitesimal differentials being expressed in protrusions, probably lack of accustomed pressure allows a slight overfulness of blood with further increased blood pressure (see p. 123). Devitalization of the pulp sometimes lessens this.

This is a fairly rapid process, and occurs often after the trimming of teeth for bridge-work so as to interfere with the planned occlusion, unless the bridge be rapidly made. If unopposed, it extends progressively, the neck being usually exposed, though sometimes the alveolar process becomes developed and lies on a lower level as though it had followed the tooth down. Usually the bifurcation of a molar becomes exposed, calculi form, and the extrusion becomes hastened by marginal gingivitis. The tooth may be firm even though half its root length be exposed, though often it becomes looser than normal. Sometimes it strikes other teeth with a glancing motion. If the teeth in Fig. 606 were closer this would occur, and such a process (malocclusion) hastens the loosening. The opposite

gum may be injured by such a tooth. Another effect is the wedging of food between the teeth owing to a favoring entrance, the laterally unsupported tooth wedging apart and then closing upon the food. This injures the gum septum. (See Gingivitis.)

Finally the loosening or the annoyance compels the removal of the tooth.

The danger of marginal infection is always great in these cases. Some degree of infection, no doubt, exists in all of them, which serves to explain the increased rapidity of the degenerations.

FIG. 606

Absolute disuse and elongation of an upper and a lower molar; partial disuse of bicuspid; small abscess cavity in the bone about a root. (Philadelphia Dental College Museum.)

Prognosis.—If teeth can be directly or indirectly brought into use, so that their pericementi receive exercise, the cases may recover, provided the atrophic changes are not very pronounced; in which event the atrophy proceeds, although more slowly. Teeth crowned or made abutments for bridges, after degenerative changes have become established—*i. e.*, when the normal pericementum has been replaced by a thickened mass of partially organized connective tissue —usually become progressively looser; the alveolar atrophy proceeds until all attachment is lost.

If this principle be utilized early, the teeth may be saved. The results are better if the teeth or roots be utilized before the age of thirty than at later ages.

Treatment.—The treatment consists in bringing the teeth into use, if the degeneration has not proceeded too far. In crowning for a bridge pier it is customary to shorten the crown to the general occlusal

level, though even if a little longer and not in direct occlusion the tooth is brought into a sort of mastication which is useful if it does not introduce an element of malocclusion, *i. e.*, if the distal or repelling strain upon its mesial slope is compensated for by the mesial strain upon a pier or piers more mesial to it, or upon a pontic tooth, for example, upon the cuspid of Fig. 606, or pontic bicuspid occluding with the mesial slope of the lower first molar. In such a case as this grinding both the upper and lower molar occlusally and the introduction of an upper bridge is indicated. Later, extraction is inevitable. The operation, when determined upon, should not be delayed, for not only are bacterial growths invited about the loosened tooth, but the soft tissues are frequently increased in volume, and if extraction be delayed until complete local atrophy of the alveolar walls has taken place, a soft and spongy mass remains, which interferes with the comfortable wearing of prosthetic appliances in the future.

FIBROID DEGENERATION OF THE PERICEMENTUM.

Fibroid degeneration of the pericementum is a senile atrophic change occurring in teeth, the pericementi of which have run a healthy life course, but finally have become subject to senile marantic constitutional changes of not clear nature. The condition thus first defined by Hopewell-Smith[1] is further described as found in that class of teeth of the aged which have resorbed alveolar margins and exposed cementum, but not necessarily subject to pyorrhea alveolaris, though traumatic pericementitis may be present. In some cases the teeth may be firm.

Pathohistology.—The chief characteristics are an increase in size of the fibers of the pericementum, the loss of their nuclei, their generally structureless character, and their arrangement in prominent bundles about large spaces (areolæ). (See Fig. 607.)

The fibers are firmly implanted in both bone and cementum. The cementum does not become hyperplastic (hypercementosed), but the bone becomes osteoporous and the Haversian canals contain a shrunken fibroid tissue resembling that in the pericementum (Fig. 608).

The gum tissue in the vicinity also undergoes retrogressive changes in sympathy, becomes less vascular and more fibroid.

The condition may persist without inflammatory or suppurative changes, though it may act as a cause of obscure neuralgia or as a predisposing cause to pyorrhea alveolaris.

[1] Dental Cosmos, 1904.

Fig. 607

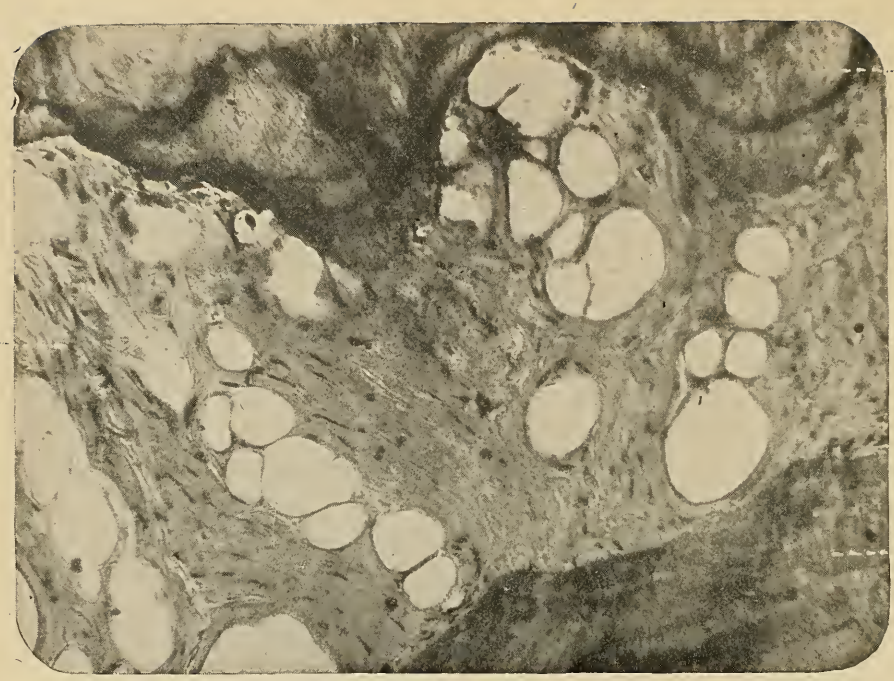

Fibroid degeneration of the pericementum: *C*, cementum; *A*, alveolus; *F*, fibers with decrepit nuclei. Transverse section. (Hopewell-Smith.)

Fig. 608

Fibroid degeneration of the pericementum: *C*, cementum; *M*, degenerated pericementum; *A*, alveolus; *H*, enlarged (osteoporous) Haversian canals. Transverse section. (Hopewell-Smith.)

Hopewell-Smith points out that the areolar spaces may admit microörganisms to deep parts, thus predisposing to antral disease or, possibly, osteomyelitis.

ACCIDENTS TO TEETH.

Apart from fracture of the teeth by accident, several interesting accidental conditions involving therapeutics require consideration.

Teeth Driven into Alveolar Process.—Blows, falls, etc., have occasionally caused teeth to be driven forcibly into the jaw. The condition may be complicated by fracture, in which case the judgment of the operator must be exercised. If the tooth be not fractured it may be drawn down with forceps and ligated in place until firm. The use of zinc phosphate upon the ligatures, if possible to use it, renders them more rigid. Splints may be used. If evidence of pulp death be noted by subsequent test, or apical pericemental inflammation, the pulp should be removed.

Luxation or Partial Dislocation by Accident.—Teeth may be partially knocked out and driven either lingually or buccally. The pulp connections will be ruptured, as a rule, but after asepsis of the parts by means of antiseptic sprays the teeth may be pressed into place, and if ligated or splinted may again become firm by deposition of bone about them. The pulps nearly always give evidence of death so that they should be later replaced by canal fillings.

Mendel Joseph and Dassonville[1] record experiments on dogs showing a vital attachment of the pulp of an immediately replanted tooth. They used strictly aseptic precautions.

Occasionally evidences of reattachment of pulp have been recorded[2] even after total displacement. If the accident result in elongation of the tooth with production of a chronically spongy pericementum, the operation of replantation should be performed.

Total Dislocation of Teeth by Accident.—If the accident result in total displacement from the mouth, the tooth or teeth may be prepared as for replantation (see p. 624), and under aseptic precautions replanted in their alveoli. If held by ligatures or splints they will usually become firm. If the teeth are kept moist a short delay if necessary does not prevent success, though clot and granulations must be swept out.

Attachment of Teeth.—Two or more teeth may be attached by the intervening alveolar process, fracture of which may cause both teeth to be removed in extraction. In a few cases of loose deciduous teeth

[1] L'Odontologie. See Dental Cosmos, 1906, p. 1060.
[2] Kirk and W. Trueman.

the gum has been sufficient attachment to cause the removal of two teeth at once.

In some cases the tough, fibrous nature of the pericementum causes the alveolar bone fractured by the leverage upon it to remain attached to the tooth, and Fig. 210 illustrates teeth attached by union of pericementum only.

Fracture of the Alveolar Process.—Slight fractures of the alveolar plate are of little consequence, as a rule. In some cases one plate may be fractured, and unless removed with the tooth, may usually be pressed back into place. Reunion may be looked for if asepsis be maintained. Fractures of the alveolar process from blows, kicks, etc., upon the jaw may become septic and sequestra may form, necessitating removal of both bone and teeth. Such fractures should have immediate attention. Fractures of the maxillæ should, of course, be immediately reduced.

Hemorrhage following Extraction.—Even in the absence of hemophilia postextraction hemorrhage may be somewhat severe, and is well controlled by a little tannic acid or powdered alum and thymol upon a pellet of cotton, or nosophen gauze wet with phenolsodique.

If necessary a linen compress should be placed over it and a Barton or Garretson bandage applied. The internal use of calcium chlorid or other hemostatic is indicated if the bleeding be continued. (See p. 120.)

Lacerations.—The tongue, floor of the mouth, etc., may be lacerated by the careless use of forceps, and the lacerated parts should be irrigated with antiseptics and the mouth kept under astringent antiseptics while the parts are healing. Lacerated gum margins should be trimmed up to prevent sloughing.

Postextraction Alveolitis.—This has been already discussed. (See p. 633.)

For ordinary transient pain, phenolcamphor with or without menthol added or equal parts of phenolsodique and laudanum are useful. Hot salt water held in the mouth is analgesic, styptic and stimulant.

SECTION VI.

PERICEMENTAL DISEASES BEGINNING AT THE GUM MARGIN.

CHAPTER XXII.

GINGIVITIS.

The diseases which begin at the gum margin are all inflammatory, and are due to mechanical, chemical, and infective local irritants, and probably may be due to overexcitation of the gum tissues by leukomains or other toxic products which are formed intrinsically within the body in malnutritional processes, also to overexcitation by certain drugs, both of which the gum is endeavoring to eliminate. The inflammation resulting is termed gingivitis. Many mechanical or septic causes which produce pericementitis, such as overuse or apical abscess, finally induce an inflammation in the alveolar bone (osteitis), and later an inflammation of the gingival tissue. In reverse order, inflammations beginning in the gum, reach the bone, and later the pericementum. It is plain then that pericementitis and gingivitis are often associated, and at the gum margin are almost inseparable.

If at any stage of a gingivitis, whether of mechanical or chemical primary causation, infection enter the inflammation becomes septic, and if pyogenic bacteria are the infective agents, pus is formed. At this juncture there is a pus flow from beneath the gum margin, usually from a pocket extending into the substance of the pericementum or the location previously occupied by it in the alveolus, and from this fact it is called pyorrhea alveolaris, though a variety of pyorrhea is apparently non-purulent. Some writers treat of all cases of gingivitis as cases of pyorrhea, advanced or incipient, and in view of the fact that a simple gingivitis may become a pyorrhea there is some justification from a preventive standpoint; nevertheless, there are so many phases of gingivitis that for purposes of discussion and applied therapeutics it is advisable to specify the various forms that may exist.

If confined to the gum margin it is properly designated marginal gingivitis; if the inflammatory elements (leukocytes and exudates) have infiltrated the deeper connective tissues it may be called deeply seated gingivitis or interstitial gingivitis. If a pus flow from the alveolus accompany the deeply seated gingivitis the condition of pyorrhea alveolaris is established.

With any of these conditions an hypertrophy or an atrophy may be associated, which, on the one hand, may result in hypercementosis or exostosis or thickening of gum, or, on the other, in resorption of gum or bone.

MARGINAL GINGIVITIS.

Definition.—By marginal gingivitis is meant an inflammation confined to the margins of the gums about the necks of the teeth.

Causes.—The causes of marginal gingivitis are local and general, which may be subdivided into predisposing and exciting. Both local and general causes may be in action at the same time.

Local Causes.—Marginal gingivitis may be excited by the presence of food masses or unremoved collections about the necks of teeth, their fermentation liberating chemical products more or less irritating. Miller[1] has shown that the materies alba about the necks of teeth may have either an alkaline or acid reaction, and the gums be inflamed.

The lack of contact or too light contact of approximal surfaces, whether due to faulty operations or induced by the wedging action of tooth-picks or floss silk, causing a general non-septic pericementitis and bone resorption (looseness of teeth) are contributory to the wedging of food.

Bacterial plaques not unlike those producing dental caries have been shown by Miller[2] to be formed upon many surfaces of the teeth even when no ill results are notable. In practice staining the teeth with tincture of iodin will readily demonstrate the presence of such bacterial films. Under favoring circumstances these no doubt produce marginal gum irritation, a fact proved by the relief of such a condition by prophylaxis—*i. e.*, the removal of the plaques.

Talbot[3] has demonstrated that a deep pocket may normally exist at the gum margin favoring the retention of food and other debris.

Mechanical causes produce direct irritation; these are deposits of salivary calculus resting upon the gum or beneath the gum margin; fillings projecting beyond cavity margin; edges of poorly fitted crown band and the putrefaction of food, etc., collected in the places from

[1] Dental Cosmos, 1894.
[2] Ibid, 1902.
[3] Intestitial Gingivitis.

which cement has washed out; gum overlying cavity margins; bruising of the gum margin by food crowded between teeth and removed by toothpicks; the fermentation of such crowded food (see p. 683); the mechanical action of toothpicks or floss silk improperly crowded upon the gum margin; projecting edges of artificial crowns or bits of cement used in their cementation; toothbrush bristles; fragments of toothpicks, bones, or oyster-shells, etc.; rings of rubber or of torn rubber dam or ligatures left in position; rubber or tape wedges forced into the gum; the crowding back of a gum by ligation which produces ischemia for hours; improper contact of the edges of prosthetic plates or appliances about the necks of teeth; injuries inflicted by rubber dam clamps, wedges, ligatures, etc.; the eruption of teeth through the gums.

An interesting case of recurrent epileptic attacks was proved due to a toothbrush bristle forced into the gum.[1]

The action of any of these causes may be complicated through the infection of the mechanically irritated part by oral bacteria. An excellent example occurred in the editor's practice. A perfect gum margin was irritated by the margins of a gutta-percha cap used as a remedy for hyperemia of the pulp. Pyogenic organisms produced a marginal suppuration which subsided upon removal of the cap.

All forms of marginal gingivitis are to be considered as incipient inflammations which, let alone, may lead to deep-seated inflammation and tissue destructions collectively called pyorrhea alveolaris.

Excessive smoking and the use of alcoholic liquors produce local irritative effects, resulting in catarrhal stomatitis and gingivitis.

Lack of exercise or brushing of the gums produces an atonic condition of the gum margin, predisposing to gingivitis of infective character. Too persistent brushing with stiff brushes may be equally injurious by causing marginal irritation.

A variety of ulcerative marginal gingivitis exists which tends to rapidly penetrate the pericemental tissue and may cause pyorrhea. The gum margin has a pasty, sloughing appearance, and the gum about several teeth may be involved. Vaughn[2] describes it as covered by a grayish necrotic covering which when rubbed off leaves a sensitive bleeding surface, the deposit being accumulated rapidly in an hour or two. He found the bacillus fusiformis and spirillum which work in symbiosis in Vincent's angina. In the severe cases he describes fever, dysphegia, headache, malaise, nausea, marked salivation, loss of appetite, increased cardiac and respiratory action,

[1] Dental Cosmos, 1910, p. 594.

[2] Ibid., 1912, p. 651.

and glandular enlargement as associate phenomena. The breath is offensive and characteristic. Syphilitic chancre may begin at the gum margin, and there is no reason why aphthæ should not be so located though usually elsewhere.

A form of phagedenic pericementitis causing very rapid destruction of the pericementum and loss of the teeth without loss of alveolar wall has occasionally been noted. In one notable case two upper incisors came away three weeks after an ulceration appeared about their gum margins. The patient wore the teeth for several weeks *in situ*, and could remove and reinsert them at will. The alveolar walls were bare, but intact. There was but little pain. The sockets healed after removal of the teeth and the freshening of the bone. The clinical features of this case were entirely distinct from those of the phagedenic condition recognized as phagedenic pericementitis, and were more probably caused by the Vincent bacteria (Fig. 611).

Cook has shown that stimulant and astringent washes, if used to excess, have a degenerative influence upon the gum margin. (See p. 84.) A too powerful formaldehyd wash has the same effect.

The production of deeply seated gingivitis by causes of systemic or drug origin involves a marginal gingivitis, but marginal gingivitis is not always produced by local causes of interstitial gingivitis; at least, not at first (see p. 648).

Systemic Causes.—These are the same as for Deeply Seated Gingivitis, which see.

Pathology.—The pathology of marginal gingivitis is that of an inflammation located in a peculiar situation—*i. e.*, in the marginal gum tissue—and tending to spread into the deeper interstitial tissues. (See Pathology of Deeply Seated Gingivitis.) As shown above when pyogenic bacteria enter, a pus flow or pyorrhea is established.

Symptoms.—The symptoms of marginal gingivitis depend upon the cause and degree of inflammatory action. When mechanical causes are acting the gum presents an inflamed appearance; it is swollen, of a bright red or purplish color, very sensitive to touch, and bleeds readily.

If a calculus rest against the gum, the latter may present a raw, chronically inflamed surface in contact with it. A ragged, red, split margin of gum is often associated with calculus upon the labial surfaces of lower incisors, cuspids, and bicuspids, and upper cuspids and bicuspids. At times the lingual surfaces of the lower incisors present such an appearance. If subgingival calculus be present, the gum margin, if markedly affected, appears loosened, and is of a flabby appearance and purplish in color. In some cases the gum margin appears thickened or hypertrophied.

A bloodshot appearance—*i. e.*, enlargement of terminal vessels—is often seen in gingivitis.

In cases due to unhygienic conditions—*i. e.*, food collections or vitiated secretions about the necks of teeth—a raw, red, outer surface of the gum margin is noted, particularly in young persons.

In stomatitis ulcerosa a yellow, pasty ulceration of the gum margins may occur. It is rodent in character, very painful, and may cause rapid loss of the pericementum and of the tooth. (See Vincent's Angina and p. 681.) In gingivitis due to oral infection by the coccus of gonorrhea an intense gingival inflammation with looseness of the teeth, pyorrhea alveolaris, and profuse salivation, may occur.[1]

Talbot[2] describes a greenish-gray glazed surface of ulcerated raw gum in two cases of profuse interstitial gingivitis due to the gonococcus.

Stein is inclined to doubt the etiology.[3]

The calssification of the gingivitis depends upon the cause and progress of the disease.

Prognosis.—If the case has run an acute course and is due to the action of mechanical causes plus infection, recovery is usually prompt upon the removal of the cause and sterilization of the injured part. In the chronic cases due to the more slowly acting mechanical and infective causes combined—*e. g.*, salivary calculus plus infection —much deeply seated gingivitis may have occurred accompanied by pericemental and alveolar resorption. This usually constitutes a permanent loss. If the gum margin is in a state of atony or inflammation as the result of collections of bacteria, etc., upon the cervices of the teeth, their condition may be improved by frequent prophylaxis.

Treatment.—The treatment of the condition consists in removing the source of irritation and restoring the normal circulation in the parts. If the source of the disorder be in some underlying constitutional condition, the symptoms may be ameliorated, although not entirely cured, by the correction of the general disorder.

Cases due to mechanical irritation are commonly confined to one or several teeth, rarely to an entire denture, except cases continued in consequence of deposits of scaly calculi beneath the gum margin or under plates. Foreign bodies, such as bristles and fragments of bone, should be removed. Projecting fillings or overhanging crown margins should be made flush with the general tooth surface. Sali-

[1] Vines. British Journal of Dental Sciences, 1903, and Dental Cosmos, 1903.

[2] Dental Cosmos, 1905.

[3] Bacteriology in its Relationship to the Oral and Nasal Cavities. Items of Interest, 1914.

vary calculi should be removed. When food crowds upon gum margins between teeth, lateral or mesiodistal contacts should be established either by contouring filling, introducing a bridge which establishes such proximal contact, or in some cases by wedging at some convenient point so as to crowd several teeth together, then introducing a contour filling or inlay. The contact should exist just a little to the gingival of the marginal ridges and not be too broad and should be well rounded.

In another phase of this condition in the writer's own mouth the extraction of a lower third molar allowed the distal cusp of the lower second molar to wedge between the upper second and third molars, so that the third molar was pushed distally and shredded food packed in simultaneously causing extreme and annoying gingivitis. In such a case if grinding the cusps of the antagonizing molars does not relieve, only extraction or firm attachment of the third and second molar will give relief (Fig. 609). In a few similar cases where fillings were present the fillings have been overcontoured and an iridio-platinum wire imbedded in a groove in one filling and the other pointed end allowed to rest in a slight groove in the adjoining filling. In this it plays freely but prevents the crowding of food, though food may float in laterally without direct injury.

Fig. 609

Marginal gingivitis located in septal tissue between upper second and third molar (see text). Also shows anterior drifting of second molar, due to extraction of first molar early in life.

This condition frequently results when a bridge has been inserted from a second molar forward. The third molar moves away. If any looseness of teeth exist it may be better to include the third molar as an abutment.

A further possibility lies in the use of a crown on the third molar with a hook or mortised piece attached, which hook or mortise plays in a suitable pocket in the crown attached to the bridge, or the pin

referred to may play in a groove. Some cases of bridge work are constructed with hook attachment, said hook playing in a specially made inlay in a tooth not otherwise included in the bridge (Fig. 610).

Fig. 610

Pin embedded in filling in third molar and extending into a groove in filling in second molar. Extension plays back and forth but protects gum.

Any associate pyorrhea due to this cause is usually rapidly cured by this establishment of contact.

Following this, perfect cleansing of all teeth is indicated, this to be maintained by monthly prophylaxis, at least until the case is cured and then continued periodically for prevention.

Antiseptic mouth washes should be employed frequently, no matter what the cause. If the gum tissue be soft and spongy, showing signs of venous hyperemia, antiseptic astringent mouth washes should be freely used:

℞—Zinc. chlorid. . . . . gr. x
Aquæ menth. pip. . . . . f℥j—M.
Increase as desired.

The above preparation, used in spray from an atomizer, or, if diluted, as a wash several times a day, is an excellent local application, meeting both indications. Prescriptions containing eucalyptus and benzoic acid are excellent:

℞—Acid. benzoic . . . . . 3 parts
Tinct. eucalyptus . . . . . 15 parts
Ol. menth. pip. . . . . 1 part
Alcohol . . . . . 100 parts
Saccharin . . . . . 2 parts—M.
(Miller.)

The above formula diluted one-half is agreeable and efficient.

An alkaline 1 per cent. salicylic acid wash is useful, not only for the gingivitis, but any attendant fetor of breath:

℞—Sodii boratis . . . . . ℥iss
Acidi salicylici . . . . . gr. xv
Aquæ menthæ pip. . . . . f℥iij—M.

The following is astringent and antiseptic:

℞—Boroglycerini,
Tinct. krameriæ,
Tinct. calendulæ,
Alcoholis . . . . . āā f℥j—M.
Sig.—One or two teaspoonfuls to a small glass of water.

Truman advises the use of hydronaphthol in an astringent vehicle as an effective germicide for use by a patient:

℞—Hydronaphthol . . . . . gr. x
Glycerol . . . . . f℥j
Alcohol . . . . . f℥j
Aquæ destil. . . . . f℥j—M.
Sig.—Use as a wash several times a day. (Pierce.)

Talbot recommends for gingivitis the following:

℞—Zinc iodid . . . . . 15 grams
Iodin . . . . . 25 grams
Glycerin . . . . . 50 grams
Water . . . . . 10 grams—M.
Sig.—Apply to gum on cotton wound on an applicator and dry after each painting. (Talbot.[1])

The following is a 5 per cent. formaldehyd solution which, diluted, can be used as a mouth wash, having astringent and antiseptic qualities. It is also useful in various strengths as a germicide for root canals. A formula for quantity is given, which may be reduced in prescriptions:

No. 1

℞—Thymol . . . . . ℥iss
Menthol . . . . . ℥ss
Oil of eucalyptus,
Oil of gaultheria,
Oil of cassia,
Oil of cloves . . . . . āā f℥iss
Alcohol . . . . . f℥ij—M.

No. 2

Formaldehyd, 40 per cent. sol. . . . . Oj
Boric acid,
Sodium biborate . . . . . āā ℥iij
Water . . . . . Oij—M.

No. 3

Water to . . . . . gal. j

Make up No. 1 first and shake well. Place No. 2 in a gallon demijohn and shake well; add No. 1 and shake again; add No. 3 and shake well. For dispensing this may be filtered; for ordinary use this is not necessary. For mouth use one-half teaspoonful is to be diluted in two ounces of water, making a 1 to 600 formaldehyd solution.

[1] Dental Cosmos, 1905, p. 1312.

Equal parts of Listerine and ordinary distillate of hamamelis is a useful combination. Glycothymolin is a very popular proprietary mouth wash. Lavoris and Vernas lotions are agreeable zinc chloride washes when used as directed. Phenol-sodique, 1 to 7 of water is quite useful.

For mercurial gingivitis and stomatitis the following has been rationally recommended:[1]

℞—Tinct. myrrhæ . . . . . f ℥iij
Potassii chloratis . . . . . ℥ss
Sodii chloridi . . . . . ℥ij
Aquæ dis. . . . . q. s. ad f ℥viij—M.
Sig.—Use as mouth wash. Repeat every two hours.

Fig. 611

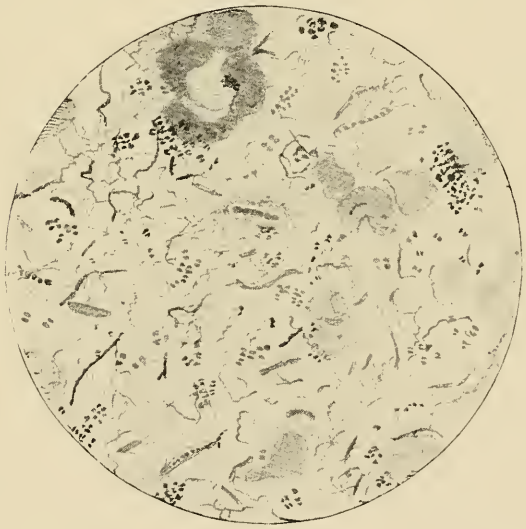

Showing Vincent's bacteria. (Lederer.)

All mouth washes require an application of about two minutes' duration at least twice a day after cleansing the teeth in order to produce the best effects. As this is somewhat fatiguing to the oral muscles, several applications may be made, one after the other, until the total is attained (Fig. 611).

In the ulceration gingivitis due to Vincent's bacteria the editor has found the following useful as a germicidal wash:

℞—Hydrargyri bichloridi . . . . . gr. j
Aquæ hydrogenii dioxidi . . . . . f ℥iv—M.
Sig.—Use several times a day.

[1] Medical Press, via Dental Cosmos.

Vaughn[1] recommends silver nitrate 15 to 30 grains, water f℥j, Lugol's solution, chromic acid 10 per cent., zinc chlorid 2 per cent., and argyrol full strength. Lederer uses salvarsan (see p. 787). Curettement is sometimes necessary. Kirk[2] recommends in addition local application of tincture of iodin and irrigations of hot water. The glandular enlargements require a cold compress or the ice bag.

For the restoration of gum tissue between molars and bicuspids L. Ashley Faught[3] has recommended applications of 10 per cent. trichloracetic acid on an orange-wood stick every day or two until the case is cured.

DEEPLY SEATED GINGIVITIS[4] (INTERSTITIAL GINGIVITIS, TALBOT).

Definition.—This may be defined as an inflammation characterized by the presence in the deep connective-tissue elements of the pericementum and gum tissue of an excessive number of leukocytes, attracted thither by a general or local irritation of the tissue mentioned.

Local Causes.—Any of the local causes producing marginal gingivitis, if acting deeply, may produce a deeply seated gingivitis. In addition to these, the eruption of teeth, the wedging of them, or their movement in orthodontia, the overuse, malocclusion, or disuse, in short, any of the causes of pericementitis, septic or nonseptic, if producing inflammation extending beyond the confines of the pericementum, are causes of deeply seated gingivitis. Pyorrhea alveolaris is a suppurative deeply seated gingivitis and pericementitis combined. Ulceration and necrosis following extraction cause gingivitis (see p. 633).

If at any time pyogenic infection occur at the gum margin, the purulent phenomenon of pyorrhea alveolaris is produced. It is to be understood that deeply seated gingivitis presents many of the features of pyorrhea alveolaris and that the latter is a gingivitis. The conditions are, however, pathologically separable.

The following is a good example: A lady presented an upper first molar which had had a pyorrhea which had been cured by treatment of gum margins and the mesiobuccal root amputated. There was no longer any appreciable pus pocket, but the tooth

[1] Dental Cosmos, 1912, p. 655.

[2] American Text Book of Op. Dent., p. 300.

[3] Dental Cosmos, 1905.

[4] The writer has introduced the term to replace interstitial gingivitis, not to multiply terms, but because it indicates fairly the anatomical situation. Strictly speaking, all inflammations are interstitial.

overoccluded one-sixteenth inch and had tipped forward. It was not supported mesially or distally by adjoining teeth. It was loosened. The overocclusion was removed by grinding, the tooth was wedged against its mesial neighbor, and a distal amalgam filling contoured out to its distal neighbor, thus affording support in the direction of its movement in mastication. It became much firmer. The writer considers this case as presented for diagnosis one of deeply seated gingivitis due to malocclusion and non-support, and not a case of pyorrhea. In like manner each case should be considered on its own symptoms.

When food enters the interproximal space it crushes the gum septum and later depresses it. The inflammation causes its absorption as well as that of the bone septum, so as to leave the buccal and lingual portion higher. This may also be inflamed and further depressed. The pericementi of both teeth suffer necrosis to the gum level. The pocket generally finally suppurates and a lateral abscess may result from this cause.

While this may be classified with pyorrhea alveolaris it seems to the writer rather a distinct form of deeply seated gingivitis, at least until the pus flow is established. The writer has seen another form of this condition in which caries at the linguocervical aspect of two molars permitted food to pack laterally (not from the occlusal) under tongue pressure. The decay proceeded up the sides of the lingual and buccal root adjoining, and a large pocket formed, the gum being stripped away. The wedging out of the gum, touching with silver nitrate after cavity preparation, filling with amalgam, and polishing reduced the pocket to a simple one. The gum grew in as far as it could, and the part remains relatively healthy, without pyorrhetic symptoms, but food collects and the condition may become worse again. In another part of the same mouth pus was found exuding from beneath the ulcerated flap of gum overlying a lower third molar. Otherwise the patient's teeth exhibited no pyorrhea. Such cases might be considered pyorrhetic if pyorrhea is to include all pus flows from the alveolus, but then we must consider apical abscess such. The writer believes it better to differentiate the conditions.

Systemic Causes.—Systemic causes act to produce a deeply seated gingivitis. Drug or metal poisoning, or auto-intoxication, whether gastro-intestinal or by leukomains, and acute infectious diseases, are systemic causes.

A case of spontaneous loss of all but one of the upper teeth, with subsequent complete alveolar atrophy as the result of the trophic disturbance from peripheral neuritis in a tabetic woman, has been

reported by Gaucher and Dobrovici, the diagnosis being confirmed by trophic disturbance in the foot followed by plantar perforation.

It seems quite certain that in conditions of general faulty metabolism substances are generated in the system or are retained by reason of faulty elimination, and which, floating about in the blood stream, act as irritants to the pericementi and gum margins about the teeth.

Moreover, the pericemental glands seem to be eliminating organs which may become overstimulated and thus diseased.

In all general nutritional disorders parts peripheral to the circulation are most affected, become debilitated, and tend to a degenerative metamorphosis of cells.

Rhein found, after repeated examinations of hospital patients, that "marginal gingivitis was an accompaniment of typhoid fever, tuberculosis, malarial disorders, acute rheumatism, pleurisy, pericarditis, and syphilis, among the acute diseases. Of chronic nutritional diseases, it was commonly observed in cases of gout, diabetes, chronic rheumatism, several forms of nephritis, scurvy, chlorosis, anemia, leukemia, and pregnancy. Also in disorders of the central nervous system and following the administration of mercury, lead, and iodin."

Rhein states that the gingivitis produced by each of these diseases has distinctive features which may even serve as diagnostic signs of the nature of the general malady.

Talbot's experiments in the mercurialization of dogs (see p. 644) demonstrate that efforts upon the part of the pericementum to eliminate the bichlorid of mercury result in a non-septic pericementitis, exhibiting in its morbid anatomy the characteristic round-celled infiltration of inflammation.

Black[1] has shown that a gingivitis produced by the systemic administration of potassium iodid may be proved to be caused by its elimination by the pericemental glands by test of the gingival secretion for the iodin reaction.

It is quite reasonable to suppose that irritative substances originating in the body and floating in the blood stream may act in like manner. This has been termed auto-intoxication.

Irritation resulting from the administration of mercury, lead, and iodin, or from toxic substances absorbed from the intestines, is, of course, extrinsic intoxication, but acts in the same manner.

It has been claimed by Hunter, Herschell, Goadby, W. B. Keyes, D. D. Smith, and others, that the toxins formed by oral fermentations and the septic infection of the stomach, intestines, etc., arising

[1] American System of Dentistry.

from the mouth are competent to excite a train of systemic disturbances ending in a general malnutrition.

Certain accomplished cures of such states by constant oral prophylaxis lend plausibility if not certain proof to this argument. Still, the malnutrition, whatever its cause, oral or otherwise, may become a predisposition by lessening the resistance of the soft parts about the teeth to local irritants or add the irritation due to auto-intoxication.

Talbot claims that interstitial gingivitis is largely due to auto-intoxication due to intestinal fermentation with production of by-products, notably indol, which, when absorbed, may or may not be eliminated through the eliminating organs—liver, kidneys, skin, and lungs—and that if these be insufficient to the task, retention occurs and even further disease of the organs themselves, especially the kidneys. Constipation aggravates the condition, if not producing it, by retention of fecal matter with which the poisons should be eliminated. The overstrain of the kidney in the endeavor to take up the work of the liver (when that is diseased) in elimination, produces renal inflammation and impairment of eliminative function.

The blood is surcharged with accumulated poisons, the heart and arteries degenerate, and cardiac hypertrophy and arteriosclerosis are produced. Blood pressure is increased and end artery and nerve degeneration occur, in the brain, eye, alveolar process, pulp, etc., being noticeable first in the gums. He draws attention to the transitory nature of the alveolar process and the inability of the arteries to expand, as in soft tissues, and that poisonous products settle in the end arteries, and points out that gingivitis is a natural result of these conditions. The demonstration of infarction in the pulp due to systemic conditions, even in the young, has been made by Hopewell-Smith, and also indicates end-artery strain.

Talbot regards indican, the absorbed product of indol in the intestine due to putrefaction and which is found in the urine, as the excitant of gingivitis in intestinal fermentation (auto-intoxication) and the general acidosis, as indicated either by an excess of acidity, in the urine or a deficiency therein, as excitant in various conditions of malnutrition.

The excess of acidity above 40° in the urine indicates excessively imperfect oxidation, while defective acidity (below 30°) indicates insufficiency of renal elimination. In both cases systemic acidosis is the condition. (See p. 103, etc.)

Diagnosis of Systemic Causes.—The diagnosis of systemic cause by malnutritional conditions involves almost the entire range of

medical diagnosis, a subject obviously beyond the scope of this work. If local causes do not explain the oral pathological condition it is well to refer the patient to a competent medical diagnostician for examination and treatment. Urinalysis or salivary analysis may, however, be made by either the dentist or a specialist in that work, and together with symptoms some information may be gained. Talbot directs that twenty-four-hour urine should be obatined and the following points looked for.[1]

Amount.—This should be about forty ounces.

Specific Gravity.—If high, it indicates an increased proportion of solids per ounce.

Degree of Acidity.—If above 40° it indicates acidosis by imperfect oxidation; if below 30° it indicates renal insufficiency and retention in blood of acid products.

Indican.—If present, it always indicates intestinal fermentation.

Albumin.—Not of certain origin.

Hyalin Casts.—If bloody, they indicate renal inflammation.

Compound Hyalin and Coarsely Granular Casts and Waxy and Amyloid Casts.—Indicate changes in structure of kidney.

Symptoms.—Headache, loss of appetite, loss of memory, irritability, biliousness, fatigue, muscle soreness, hypochondriasis, insomnia, vertigo, muddy complexion, tinnitus aurium, general nervousness, cold extremities, impotence, leg cramps, twitching of muscles, neurasthenia, pruritus, acne, urticaria, arteriosclerosis, gout, rheumatism, Bright's disease, diabetes, uric acid diathesis, nervous disorders, asthma, anemia, lethargy, stupor, insanity, etc., are symptoms which, in part, may develop from the auto-intoxication by the toxins and acidosis. (See General Malnutrition.)

Unnatural odor of the breath, armpits, and thighs indicate an effort of the lungs and skin at elimination.[2]

Lead poisoning occurs in those using white lead, as painters. The occupation together with paralysis of the extensors as in wrist or foot-drop, tremors, and peripheral anaesthesia from toxic peripheral neuritis and the blue lead line upon the gum are diagnostic points with which mercurial symptoms of like character may be confused through urinalysis for lead; the history and occupation clear it up.

In mercurial poisoning the occupation, history of drug administration, salivation, enlarged tongue, general pericementitis or gingivitis, urinalysis for mercury, will clear the diagnosis as against that of lead poisoning.

[1] Interstitial Gingivitis due to Auto-intoxication, Journal American Medical Association and Dental Digest, 1906.

[2] Talbot.

Pathology and Morbid Anatomy.—The local or systemic causes produce direct inflammation; the bloodvessels become overful, and waste products collected in the end arteries produce local degeneration, diapedesis of leukocytes into the interstitial submucous gum tissue occurs, and the spaces are filled with inflammatory exudate. The papillæ become enlarged and the epithelial layer undergoes an increase in formation of cells (hyperplasia). The gum in consequence of these changes becomes swollen, its color deepened, and it bleeds readily.

FIG. 612 FIG. 613 FIG. 614



Resorption of alveolar process due to interstitial gingivitis, caused by marginal irritation from excessive filling material. (Radiographs by Price.)

If the process be advanced the alveolar process is involved.

After a time the effects of continued low-grade inflammation are expressed in resorption of bone or cementum, or both, or hypertrophy of bone or cementum, or both, as the two processes may be in evidence at the same time.

Talbot describes several forms of bone resorption occurring in interstitial gingivitis:

(*a*) Lacunar resorption carried on by the osteoclasts normally lying upon the surface of the bone. Under irritation they increase in number and excavate irregular bays in the bone (Howship's lacunæ). These are then deepened and widened, destroying areas of bone. (See p. 146.)

(*b*) Perforating canal resorption beginning in the small canals normally perforating the trabeculæ of bone in various directions and transmitting the bloodvessels from one medullary space or Haversian canal to another (Volkmann's canals). The osteoclasts widen these, necessarily reducing the substance of the trabeculæ (Fig. 71).

(*c*) Halisteresis ossium, beginning with a decalcification of masses of the bone, the organic matrix being for a time undisturbed, but is later removed. This is a local expression of what may occur in other bones of the body in the condition known as osteomalacia (Fig. 74).

According to Talbot, premature resorption of the alveolar margins,

either local or general, is due to this process, called by him alveolar osteomalacia, and occurs in pregnancy or senility, as a rule.

He states that the decalcified bone may be recalcified after confinement in pregnancy, but is never restored in senility.

A lesser degree of irritation may set the osteoblasts at work and cause the building up of the alveolar process, either as a restoration of resorbed bone or as an hypertrophy of either the alveolar process or the cementum of the root (hypercementosis).

Endarteritis obliterans is a thickening of the intima of an artery or capillary, due to chronic irritation, and causing a lessening of the lumen of the vessel, even to the point of obliteration of the capillaries.

The blood flow is impeded and nutrition of cells impaired. Any cause of deeply seated inflammation may produce it. In all cases of chronic deeply seated gingivitis the bloodvessels are so diseased (Figs. 615 and 616).

FIG. 615

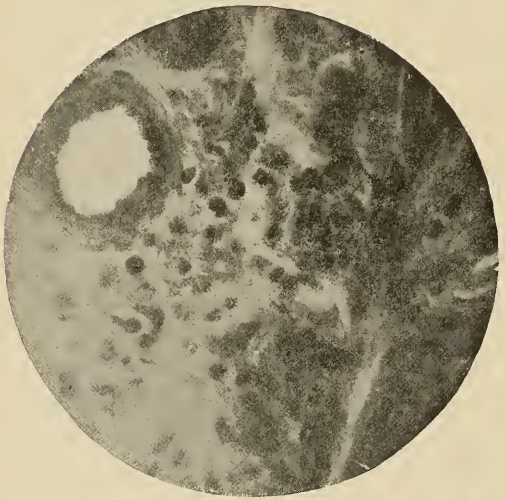

FIG. 616

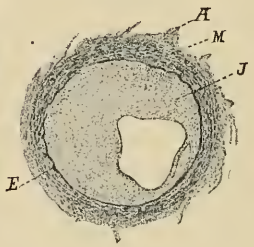

FIG. 615.—Longitudinal section of gingival border, showing round-cell inflammation, due to mercury, and extending to the inner coat of the bloodvessel, and also plasma mast cells. From a dog. (Talbot.)

FIG. 616.—Endarteritis obliterans: *A*, adventitia; *E*, elastic tissue between middle coat and intima; *M*, muscular coat; *J*, thickened intima. (Talbot, after Kaufmann.)

Local Treatment.—The treatment must be directed to the removal of the underlying cause. All local causes must be removed and the teeth put into physiological use as far as possible. This includes the removal of causes of malocclusion or overuse; of the crowding of food between teeth, the removal of local mechanical irritants and infective agents. The local treatment in general is that employed

for marginal gingivitis or for pyorrhea alveolaris. (See p. 677; also Pyorrhea Alveolaris.)

Systemic Treatment.—This, of course, depends upon the systemic condition and its causes, but if due to torpid biliary function or defective elimination with consequent retention of body products, the restoration of the eliminative function should be aimed at. In intestinal auto-intoxication impacted fecal matter should be removed by repeated injections, if necessary, of warm water, and the bowels be kept clear by flushing with soap and water once or twice a week. The massage of the abdomen restores the tonicity of the bowels. The bile function should be restored, and the bile be increased in flow by calomel and soda, $\frac{1}{12}$ to $\frac{1}{6}$ gr., every hour until 1 grain is taken; to be followed by a saline laxative (as Seidlitz powder); or podophyllin, $\frac{1}{12}$ to $\frac{1}{6}$ gr., up to $\frac{1}{2}$ gr., may be given instead of calomel.

Talbot[1] also uses:

℞—Aloin . . . . . $\frac{1}{4}$ gr.
Strychnin sulphate . . . . . $\frac{1}{60}$ gr.
Extract of belladonna . . . . . $\frac{1}{8}$ gr.
Pulv. ipecac . . . . . $\frac{1}{16}$ gr.—M.

Take at bedtime and follow with a saline cathartic next morning. If the stools remain unhealthy, administer each two to four hours 2 to 5 grs. of compound lime, soda and zinc carbolate until the stools are healthy.

To continue the stimulation of the liver administer bilin $\frac{1}{12}$ to $\frac{1}{4}$ gr. four or five times a day.

The urine should be examined for evidence of established disease, and if this be found the patient referred to a general practitioner. (See General Malnutrition.) If found only symptomatic of hepatic or renal insufficiency and nutritional disorder, the amount of urine should be increased to 40 ounces by the drinking of 3 pints of water (including table beverages) per day, which will aid bowel and renal elimination and flush tissues of accumulations, including retained acids. If the urine be abnormally acid (above 40°) administer 3-gr. tablet of lithia, sodium bicarbonate, or sodium chlorid in a glass of water four times a day. Hot or Turkish baths keep the skin free for eliminative function. Well-apportioned rest and exercise and moderate eating of proper nutritious food are indicated. (See pp. 97 and 105.) When organic disease is present the treatment should be relegated to the medical practitioner.

[1] Therapeutics and Treatment of Intestitial Gingivitis, Dental Digest, 1906.

MARGINAL ATROPHY OF THE GUMS.

In advanced age there exists often a tendency of the gums to shrink evenly away from the enamel, exposing the cementum. Hopewell-Smith describes this as accompanied by fibroid degeneration of the pericementum (which see), and regards the latter as a purely senile change.

It may be noted upon the buccal side only of a denture, and be due to vigorous brushing.

It is also seen localized at cervices next to a space from which a tooth has been extracted. In one case the editor saw a slightly hypertrophied gum distinctly overlapping a cavity margin drawn back one-eighth inch within a month as the result of extraction of the adjoining root.

FIG. 617

Recession of gum in senility; beginning decalcification of cementum; alveolar resorption after extraction. (Philadelphia Dental College Museum.)

Apart from senile changes, and possibly even including them, these effects seem to be the result of an overstimulation of the gums resulting in atrophy. It may be that collections upon the teeth are in some degree responsible. The gums have, for the most part, a healthy look, but are in a condition predisposed to pyorrhea alveolaris.

Treatment.—If localized and the restoration of the gum be desirable, Harlan's method may be tried.[1] (1) Cleanse the exposed

[1] Dental Cosmos, 1906, p. 927, and 1907, p. 598.

tooth surface and slightly roughen it near the gum margin. (2) Dissect away the gum from the root to about one-quarter inch in depth, wiping the blood away carefully with mouth open until hemorrhage ceases spontaneously, or check with adrenalin solution. (3) Make three incisions into and through the gum tissue. (4) When bleeding has almost ceased fill the cuts with dried zinc iodid, allowing the blood to liquefy it so that it may be carried around the gum margin. This creates a profound irritation, which should not be disturbed. (5) The patient should use a mild antacid antiseptic wash, as of sodium bicarbonate or milk of magnesia. (6) Repeat three or four times at intervals of three or four weeks, with cuts in a new location. (7) Use silk or pure silver ligatures around the teeth under the gum for further irritation. (8) To allay overirritation paint with 1 part adrenalin and 3 parts compound tincture of iodin once in three days.

Harlan states that a long time may be required in some cases. It should not be attempted over a gold filling, but an unglazed porcelain may be covered, though no attachment will exist. The principle involved is that of coaxing the gum into adherence with the roughened root, and the filling in of the cut with scar tissue.

As a wash use:

℞—Hydronaphthol . . . . . gr. xx
Oil eucalyptus . . . . . ♏x
Oil cassia . . . . . ♏x
Alcohol . . . . . ƒ℥iij
Distilled water . . . . . ƒ℥xiij—M.
Sig.—Use freely five or six times daily, diluted, if necessary, with more water.

The gums should not be brushed for several days after operating. Avoid insoluble dentifrices. If this treatment be considered inadvisable the appearance in a given case may be improved by the use of a pink porcelain inlay.

For general recession due to osteomalacia the general acidosis may be treated.

CHAPTER XXIII.

SALIVARY AND SERUMAL CALCULUS.

Calculi are more or less hard concretions found in varying situations and composed of inorganic and organic matter combined in an unknown manner.

As related to the teeth, calculi arise from the following recognized sources:

1. Obviously from the saliva, and deposited in situations which clearly indicate its source, salivary calculus (or ptyalogenic calculus —Peirce).

2. From the serum of the blood deposited at some point along the side of the root between the gum margin and the apex of the root, and called serumal calculus (Black), or sanguinary calculus (Ingersoll). Of this there are several varieties:

(*a*) That associated with a probable fermentation and an altered secretion from the gum margin, and known as subgingival calculus.

(*b*) That occurring in situations in which a chronic pus flow is found, whether apical or subgingival, and which may be called pyogenic calculus.

(*c*) That found upon the roots of teeth at a point to which saliva has no access and over which pus does not flow, and which is therefore deposited by the lymph derived from the blood, and to which the appellation hematogenic calculus (Peirce) is applicable.

In this class Kirk found two varieties resulting from pericemental inflammation: (1) Subpericemental deposits, and (2) intrapericemental deposits.[1]

These several names will be adhered to in further descriptions as having definite significance.

SALIVARY CALCULUS.

Definition.—Salivary or ptyalogenic calculi are hard formations composed of salts of the saliva which have been deposited or precipitated and combined in an unknown manner with organic substances, probably mucin or globulin.

[1] Dental Cosmos, 1905.

Occurrence.—They are found upon the surfaces of the teeth, notably in situations opposite the mouths of the salivary glands, in the ducts of the muciparous salivary glands (sublingual and submaxillary), and upon artificial dentures. A photograph of a plate containing an enormous mass of calculus, the result of seven years' accumulation, is shown in Fig. 618. The teeth are occasionally buried in it. The editor extracted three lower incisors which had been wired together, and were absolutely covered from the neck to the apex by calculus.

Varieties.—Clinically two distinct varieties of salivary calculus are recognizable: (1) The soft, friable, whitish yellow deposits found chiefly upon the buccal surfaces of the upper molars and upon the lingual surfaces of the lower anterior teeth; (2) dark-colored and hard deposits found more frequently in the latter situation, less frequently in the former.

Fig. 618

Salivary calculus attached to a lower partial plate worn seven years without removal. Shows form of sublingual space. Practice of Dr. Ford, Toulouse, France. (Specimen in possession of Philadelphia Academy of Stomatology.)

Origin of Salivary Calculus.—The origin of salivary calculus may be studied from several standpoints: (1) The formation of calculi in other parts of the body; (2) an analysis of saliva and salivary calculi; (3) extra-oral experiments upon saliva with a view to the formation of salivary calculus extra-orally; (4) the changes observed clinically in salivary calculus during its deposition.

Ziegler[1] states that all free concretions have an organic basis or nucleus (inspissated feces, vegetable material, epithelial scales, mucus, etc.).

As to cholesterin gallstones, he states that if the cholesterin be dissolved out by ether, a yellowish organic matrix remains which retains the form of the stone and presents upon examination radiating spaces formerly occupied by the crystals. He describes the formation of the gallstone as an infiltration or incrustation of degenerated organic matter (epithelial scales, etc.) with cholesterin, bile pigment, etc., to which, after a nucleus is formed, other portions are added in like manner.

[1] General Pathology.

Of urinary calculi he states that Ebstein has shown an organic substance albuminous in nature to be left after dissolving out the various salts.

In stratified calculi this stroma also shows stratification. Such a stroma may be seen after decalcification of a bit of salivary calculus.

Analysis of salivary calculus shows it to be composed of about 22 per cent. of water and organic matter as the portion removable by burning the calculus, and about 78 per cent. inorganic matter as the portion removable by decalcification with acids.

Following are the analyses of salivary calculus by Stevenson and Schehevetskey, respectively:[1]

	Soft tartar on molars.	Hard tartar on lower incisors.
Water and organic matter	21.48	17.51
Magnesium phosphate	1.31	1.31
Calcium phosphate with a little carbonate and trace of fluorid	77.21	81.18
	100.00	100.00

Water and organic matter	22.07
Magnesium phosphate	1.07
Calcium phosphate	67.18
Calcium carbonate	8.13
Calcium fluorid	1.55
	100.00

These observers are practically agreed upon the substances present in calculus as mainly calcium phosphate with some calcium carbonate, calcium fluorid, and magnesium phosphate combined with organic matter.

Talbot furnishes the following analysis of serumal calculus by J. H. Salisbury:[2]

Water and organic matter	32.24
Magnesium phosphate	0.98
Calcium phosphate	63.08
Calcium carbonate	3.70
	100.00

To these Kirk[3] adds ammoniomagnesium phosphate as a product of putrefaction.

According to Mitscherlich,[4] parotid saliva contains globulin, but no mucin, and contains calcium carbonate; calcium phosphate being present in but minute amount. The submaxillary saliva contains a large amount of mucin, which gives to mixed saliva its viscid nature.

[1] Talbot. Interstitial Gingivitis. [2] Ibid.
[3] Dental Cosmos, 1905, p. 752.
[4] Halliburton. Physiological and Pathological Chemistry.

Analyses of submaxillary saliva and mixed saliva by Bidder and Schmidt gave the following results:

SUBMAXILLARY SALIVA.

Water		991.45
Organic matter		2.89
Inorganic matter	Calcium chlorid, Sodium chlorid	4.50
	Calcium carbonate, Calcium phosphate, Magnesium phosphate	1.16
		1000.00

MIXED SALIVA.

Water		995.16
Organic matter	Epithelium	1.62
	Soluble organic matter	1.34
Inorganic matter	Potassium sulphocyanid	0.06
	Sodium, calcium, and magnesium phosphate	0.98
	Sodium and potassium chlorid	0.84
		1000.00

That an error of experiment or estimation exists in these analyses is shown by the fact that calcium carbonate is not mentioned as existing in mixed saliva, while it exists in submaxillary saliva; this is a physical impossibility.

It is presumptive, however, that calcium carbonate has not been specially estimated.

If a bit of calculus be dried and then burned at a red heat, the organic matter present will burn out, the calculus retaining its form. If a similar bit be subjected to dilute acid (1 per cent. nitric) the inorganic matter will be removed, the calculus will float to the top of the liquid, and, after a time, remain as a light stroma of nearly the original form of the piece.

If a bit of calculus be transversely ground, it is seen under a low-power lens to present a laminated appearance—*i. e.*, it has been deposited in layers representing periods of activity. The under surface of the calculus shows a concentric formation. Beneath the mass a nidus of darker calculus may be found, and if section of extensive calculi be made the greenish deposits may be seen scattered through the mass. Black has noted the presence of urates in nearly all specimens examined by the murexid test. Foreign bodies are sometimes entangled in the mass. Peirce recorded a case in which a small clasp plate was securely fastened to the teeth, and the patient denied possession of such a substitute.

In some cases extensive salivary deposits are found associated with highly offensive odors—*i. e.*, putrefaction of the organic matter

occurs as a part of the process—indeed, bacteria are constantly associated with the mass and may furnish their quota of the organic matter. Extraneous matters, such as tobacco smoke or other pigments, cause discoloration of the mass. With data relative to the physical and chemical analysis of calculi, the mode of calculus formation may be studied. It will be noted that the necessary elements of calculus formation are supplied by the saliva and food debris—*i. e.*, an organic basis is furnished in which calcium salts may be entangled, precipitated, or chemically combined.

If a test-tube be filled with saliva and allowed to remain at rest for several days, a flocculent, light yellow precipitate will be noted at the bottom of the tube. If the supernatant fluid be drawn off with a pipette and the precipitate be allowed to dry, it will be found possessed of the chief characteristics of calculus—hardness, friability, a light yellow color, tenacity of adherence to objects with which it is in contact, and capability of analysis into organic matter and inorganic salts.

FIG. 619

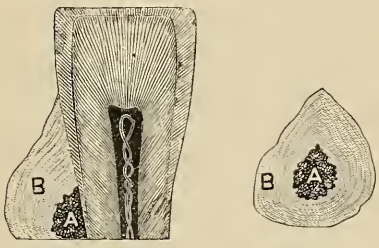

A, nidus; *B*, calculus.

The blood contains about 0.8 per cent. of inorganic salts, including those found in salivary calculi, and a certain percentage of them is also found in the blood corpuscles. They probably, therefore, exist in body cells in some proportion.

The salts are also taken into the body in the form of food. Their appearance in the various excretions and secretions of the body is to be regarded as in all probability an effort upon the part of the system to eliminate a superabundance of inorganic material from the body.

The ingestion of quantities of animal or vegetable food rich in phosphates, or the excessive liberation of the phosphoric acid in malnutrition, may produce an excessive elimination of these in the excretions and cause a tendency to the production of calculi about the body. This condition, known as phosphaturia, is observed in certain nervous diseases, rachitis, osteomalacia, leukemia, gout, and rheumatism,[1] in which the phosphaturia is symptomatic of an excessive katabolism; also in intestinal disturbance resulting in imperfect assimilation of food. (See p. 111.)

Whether taken in as food or liberated during metabolism it is probable, as pointed out by Talbot, that if one excretory organ fail

[1] Thompson. Practical Medicine.

to perform its office in full degree another must take up its work. For this reason, in any bodily condition affecting elimination a superabundance of inorganic salts may appear in the blood and hence in the saliva, and, probably, in even the secretions from the gingival margins.

That the deposit of calculus may have some dependence upon the superabundance of calcium salts in the saliva is evidenced by the fact that in young children but little calculus is deposited upon the teeth, though the oral fermentation is not lacking. The salts are needed in bone formation.

The Organic Factor of Calculus Formation.—Black[1] has argued from experiment that the organic basis is probably a colloidal agglutinating substance precipitated from saliva in the form of small oval or cylindrical globules, made up of a mulberry mass of fine globules. This substance he has called "agglutinin." This lodges upon solid objects and the minute particles of inorganic salts are precipitated into this.

This substance is coagulated (white) at 200° F., but as freshly deposited is transparent, and has a soft, greasy, sticky feel. Microorganisms multiply in it after a time, but at first it is free from them. Black has shown that this deposit precedes the infiltration by the salts.

Black regards this substance as some product of faulty metabolism, and as the determining factor in calculus formation rather than the presence of more or less calcium salts, and believes this to account for fluctuation in deposit. He found that the use once of Epsom salt as a cathartic would stop the accumulation of calculus for from a few days to several weeks, according to the condition of the patient. He regards the condition as not due to constipation, but rather due to the formation of a larger quantity of chyle than can be readily assimilated. In his own case he was able to limit calculus formation by reducing the intake of food and thorough mastication, and to bring it on at will by partaking heartily of rich foods.[2] The subject requires further investigation.

Exposure of the roots of teeth, especially the lower anterior ones, favors the deposition of calculus, owing to the difficulty of brushing the surfaces.

[1] Items of Interest, June, 1911.

[2] It is known that about one-third of calcium and other salts are eliminated in the intestinal secretion. It is therefore not certain from Black's experiments with Epsom salt whether the salts necessary for calculus formation are not so eliminated because of the stimulation of secretion from the surface of the swept and stimulated intestine. The fact that the quality of the chyle remained the same during the several weeks of lessened calculus formation seems rather to prove that retention of some organic or inorganic factor is of more importance than the quantity of chyle formed. Again, a lessened ration may reduce the quantity of the factors.

That rest or relative quiescence of the saliva is favorable for the formation of calculus is shown by the fact that it occurs at points which are ordinarily not subjected to agitation—*i. e.*, buccal surfaces of upper molars, lingual and labial surfaces of lower incisors.

Adhesive precipitations of newly formed and very soft calculus form in these latter situations in the course of twenty-four hours. If not removed by brushing they harden and thicken. An unused side of a denture often accumulates calculus in greater degree than the side used for mastication. This does not occur, however, if the brush be used properly and equally vigorously upon both sides.

FIG. 620

Unclean necks of teeth, salivary calculus, and green stain. (Philadelphia Dental College Museum.)

FIG. 621

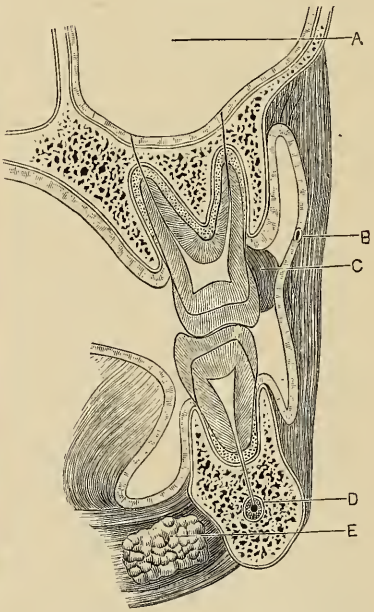

A, maxillary sinus; *B*, duct of Steno; *C*, parotid calculus; *E*, submaxillary gland.

Burchard pointed out that irritations of various natures about the teeth and gums may by reflex action cause secretions of fluid, abnormal in quantity and quality, from both the salivary glands and the buccal parietes (glands and gum margins). It is more probable, however, that the systemic condition and uncleanliness, together with tooth form, is largely responsible. The editor has a patient who is abstemious, eats moderately, exercises indefatigably in the open air, and drinks water freely. During the golf season, when perspiration is free, he has somewhat less calculus, but always

has some at uncleansed spots. This appears within two weeks of prophylaxis.

An increase of oral fermentation is commonly associated with an excess of calculus formation, but conditions of oral fermentation may be seen in which but little deposit occurs. The mouths of many children are examples of this.

FIG. 622

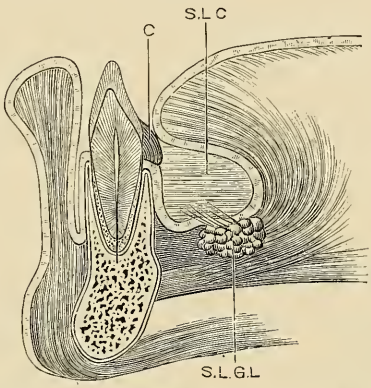

C, calculus; *S.L.C.*, sublingual cavity; *S.L.GL.*, sublingual gland.

FIG. 623

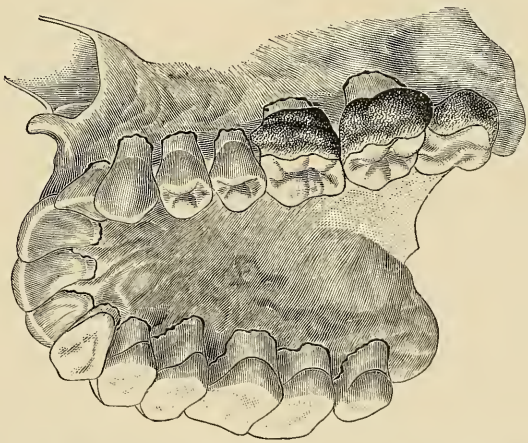

Right side, abrasion from overuse; left side, deposits due to stagnation.

Calculi harden with age. It is commonly noted that soft calculus may be readily removed with a brush. Calculus deposited upon lower teeth within a week or two after a thorough cleansing may be scraped away as a cheesy mass; after a much longer time it comes

away as a hard scale. In very old deposits it may be exceedingly hard and quite firmly attached to the teeth.

These clinical observations confirm the deduction that an infiltration of calcium salts occurs in the organic stroma of the calculus, analogous to that occurring in dead or degenerative tissue throughout the body (calcareous infiltration or degeneration). It is probable that a firmer chemical combination of the organic and inorganic elements of the calculus occurs as time passes, density being thereby increased. The organic basis is evidently a precipitation of a colloidal material, probably mucinous in character, upon the teeth, and into this the salts are precipitated.

In the analyses furnished by Stevenson (p. 694) it will be seen that hardness is, in part at least, due to an increased proportion of inorganic elements.

FIG. 624

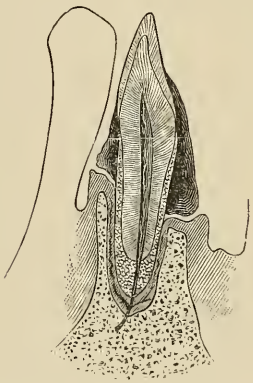

Section of a lower incisor, with a large deposit of salivary calculus impinging upon and causing inflammation of the gum. (Black.)

FIG. 625

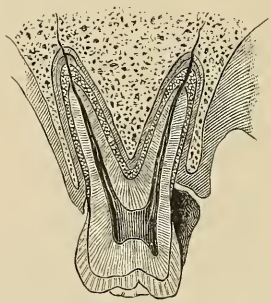

Section of an upper molar with deposit of calculus on its buccal surface, causing inflammation and absorption of the gum and lower border of the peridental membrane and alveolar wall. (Black.)

Theoretically, subgingival calculi, pyogenic calculi, and hematogenic calculi formed within the unbroken pericementum may derive their organic material from the secretions or necrotic tissue of the part, and their inorganic material (largely phosphate of calcium, carbonate of calcium, and sodium biurate) from the serum of the blood (serumal calculus). In the case of simple subgingival calculus the saliva may play a part by furnishing the necessary calcium salts, as claimed by Peirce, but this does not seem to be absolutely proved, nor would it seem to be necessary; indeed, in certain cases of pyorrhea pockets located about lower incisors in which salivary

calculus might readily be deposited, and from which both salivary and serumal calculus has been thoroughly removed, the serumal calculus has again collected in quantity, while the salivary calculus has not been redeposited.

Pathological Effects of Salivary Calculus.—In contact with the mucous membrane a salivary calculus excites first marginal gingivitis, and later deeply seated gingivitis and its effects. There is sometimes in this stage the wavy, gnawing, uneasy sensation, associated with mild inflammation, and the pulp being supplied with excess blood, becomes hyperemic and the teeth respond more readily to thermal stimuli. (See p. 470.) The gum margin is inflamed, and occasionally pyogenic organisms cause pus formation. The gum margin recedes and coincidently a resorption of the alveolar process is produced. More calculus is deposited and the process proceeds until much of the alveolar support is lost. Microörganisms no doubt aid in the process.

Fig. 626

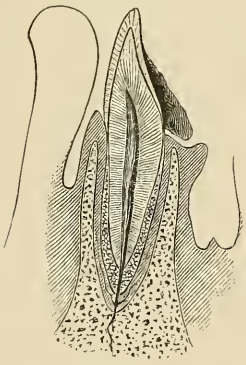

Section illustration of a heavy deposit of salivary calculus on a lower incisor, with partial destruction of the alveolus of the tooth. (Black.)

Fig. 627

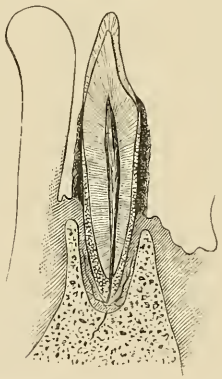

Sectional illustration of lower incisor, with deposit of salivary calculus less heavy than that shown in Fig. 626, but with greater destruction of the alveolus. (Black.)

The tooth is thus progressively loosened, first by inflammation, later by loss of alveolar process, moves about, and a resultant mechanical interstitial inflammation of the remaining pericementum occurs; as a result the membrane is thickened and the alveolar process partially resorbed (Fig. 624). As soon as the aveolar loss is considerable, infection usually occurs and suppuration may be grafted upon the results of mechanical irritation. Increased looseness occurs until the tooth drops out, unless mechanically held in place.

The entire process may occupy but a few years; in other cases the atrophy of the alveolar walls is very slow. I have recently seen

Fig. 628

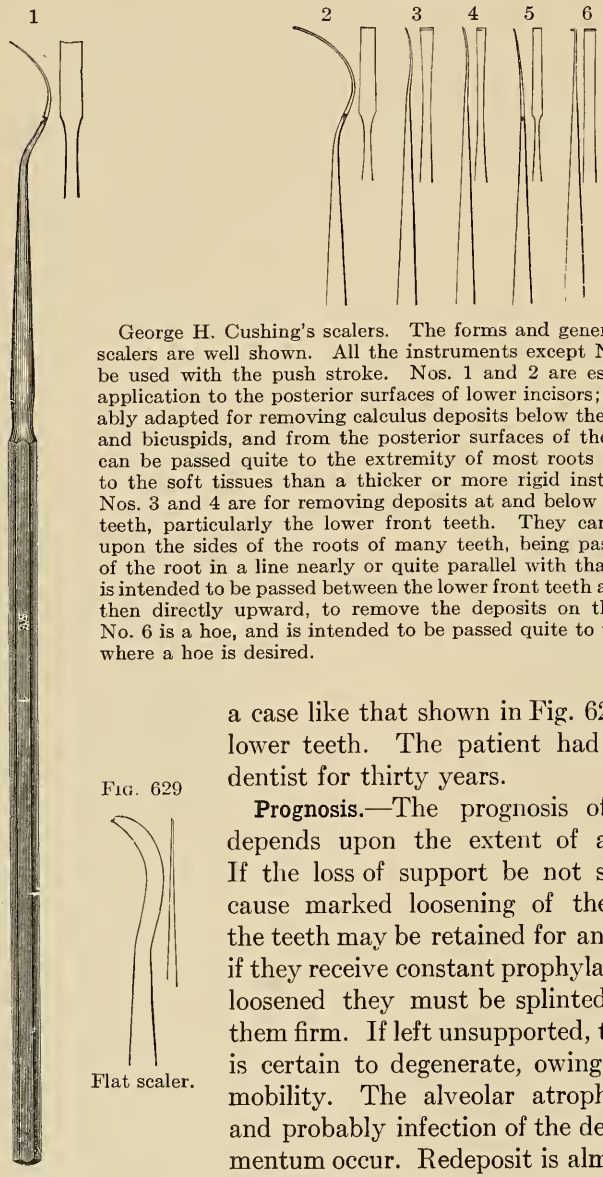

George H. Cushing's scalers. The forms and general character of these scalers are well shown. All the instruments except No. 6 are intended to be used with the push stroke. Nos. 1 and 2 are especially intended for application to the posterior surfaces of lower incisors; they are also admirably adapted for removing calculus deposits below the gum between molars and bicuspids, and from the posterior surfaces of the last molars. No. 2 can be passed quite to the extremity of most roots with less disturbance to the soft tissues than a thicker or more rigid instrument would cause. Nos. 3 and 4 are for removing deposits at and below the gum between the teeth, particularly the lower front teeth. They can also be easily used upon the sides of the roots of many teeth, being passed toward the apex of the root in a line nearly or quite parallel with that of the axes. No. 5 is intended to be passed between the lower front teeth at or near the gum and then directly upward, to remove the deposits on the proximal surfaces. No. 6 is a hoe, and is intended to be passed quite to the apex of the roots, where a hoe is desired.

a case like that shown in Fig. 626 on about eight lower teeth. The patient had not consulted a dentist for thirty years.

Fig. 629

Flat scaler.

Prognosis.—The prognosis of this condition depends upon the extent of alveolar atrophy. If the loss of support be not so extensive as to cause marked loosening of the tooth or teeth, the teeth may be retained for an indefinite period if they receive constant prophylaxis. If markedly loosened they must be splinted so as to render them firm. If left unsupported, the pericementum is certain to degenerate, owing to the increased mobility. The alveolar atrophy will continue, and probably infection of the degenerated pericementum occur. Redeposit is almost certain unless all morbid conditions are removed and extraordinary precautions be taken as regards cleanliness, which precautions are difficult to carry out without the aid of a dentist.

Fig. 630

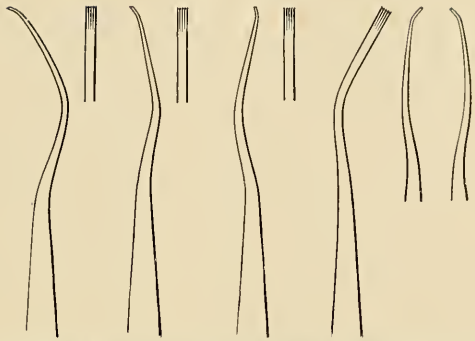

E. C. Kirk's scalers with dentate ends, designed to cut into calculus as well as maintain the course of the scaler upon the root side.

Fig. 631

Fig. 632

No. 3 Scaler.

Fig. 633

No. 11 Darby-Perry scaler.

Fig. 634

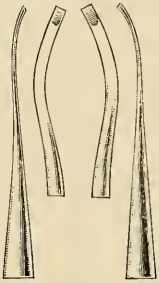

Pyorrhea scalers Nos. 5 and 6, revised set. S. S. White Dental Mfg. Co.'s Catalogue. Intended for use between teeth as well as for pyorrhea.

Fig. 635

No. 9 Darby-Perry scaler.

Fig. 636

No. 35 Darby-Perry excavator.

Fig. 637

Burton Lee Thorp's scalers.

Treatment.—The treatment may be divided under three heads: removal of deposits, correction of the effects of their presence, and prevention of their recurrence. The sole means of removing salivary calculi should be instrumental.

It is frequently recommended that mineral or some of the organic acids be used to soften the deposits or facilitate their removal. Anyone having seen a case in which a solution of sulphuric acid has been used for this purpose needs no further warning against the application. Acid solutions will certainly soften the deposits,

FIG. 638

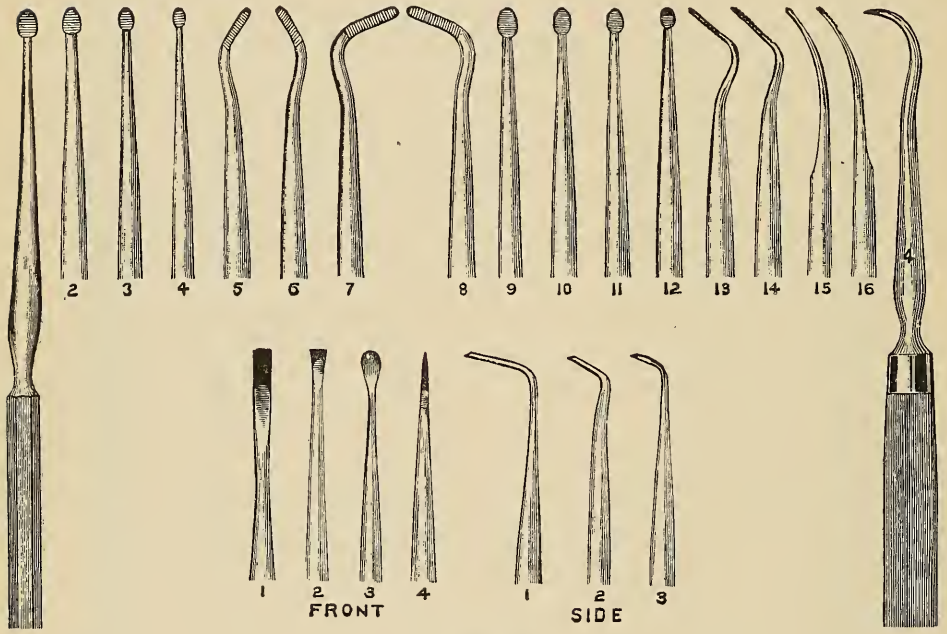

Smith scalers.

but at the same time inevitably cause a roughening of the enamel of the teeth by a solution of the calcium salts. To be sure, the acid does affect the calculus more than it affects the enamel, but the roughened surfaces of the latter not only invite widespread deposits of fermentable material, but render certain the more extensive accumulations of calculi in the future.[1] After oral sterilization

[1] Recently a proprietary preparation was offered me for removal of stains with assurance by the maker that no injurious acid was present. I highly polished the labial of an extracted tooth and applied it for one minute. The enamel was dulled and roughened. The preparation was acid to litmus. Such preparations, if needed in extreme cases, should be used with great care.

the gross deposits may be removed by means of large, sickle-shaped scalers, nearly all used with a draw cut. The instruments should have sharp edges and be introduced beneath the deposits, so that the gum be not unnecessarily wounded. The scaling should be continued until every surface which can be cleaned by these instruments is perfectly smooth.

For the approximal surfaces of the lower anterior teeth the flat-bladed instruments should be used with the push cut, or that in Fig. 651 with the draw cut. Younger's pyorrhea scalers are very useful (Fig. 649). Thorpe's scalers are useful (Fig. 637.)

For the removal of associated subgingival calculus not too deeply placed beneath the gum a No. 35 Darby-Perry excavator is of almost universal utility. It is used with the draw cut for the most part. A pair of them may be employed and made safe-sided by rounding one edge if desired, to avoid injury of the gum margin. The back of the instrument may be sharpened to an edge for a push cut. Smith's file scalers (Fig. 638) are useful for rubbing off calculus that can not be scaled off as a flake. All of the calculi visible, and all

FIG. 639

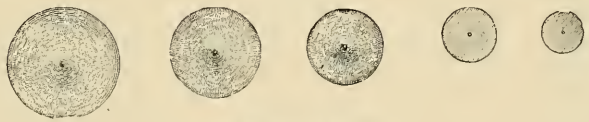

Moose-hide wheels.

that can be detected by their roughness, are thoroughly detached and scraped away with instruments. The surfaces of the teeth are next cleansed with pumice made into a paste with glycerin to prevent spattering, and with a few drops of hydrogen dioxid for antisepsis; flavoring matter or cologne may be added. The paste is applied to the surfaces of the teeth with rubber cups, or Abbott's or Robinson's brush wheels, which are used to cleanse the labial, buccal, and such lingual faces of the teeth as they will reach (Figs. 640 to 644). The gum should not be injured. When using brush wheels it is well to apply the brush to a point away from the gum and spread the bristles sgainst the tooth as it is carried toward the gum. The second brush in Fig. 640 is the best for the labial surface and lingual of bicuspids and molars, and the third one for the lingual of lower incisors. The lingual surfaces of upper and lower incisors are cleansed with moose-hide wheels and wheel brushes; a finishing bur[1] is useful in the removal of thinly distributed hard

[1] Guilford Lectures.

calculi on lingual and occlusal surfaces, especially in the mouths of smokers.

The approximal surfaces of the teeth are cleansed with fine linen tape or flat floss silk charged with the pumice paste. More inaccessible parts require the use of an orange-wood point mounted in a Jack porte-polisher (Fig. 645). It is advisable to repeat the polishing with precipitated chalk and the same carriers. When prophylaxis is frequent chalk is a sufficient abrasive except perhaps with the wood point.

FIG. 640

Abbott brush wheels.

FIG. 641

FIG. 642

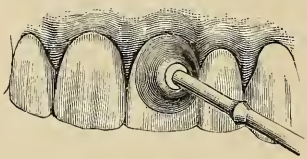

After cleansing, the associated gingivitis should be reduced and the parts kept sterilized while healing by means of an antiseptic astringent mouth wash. (See Gingivitis.)

If desired, the operation may be divided, the gross deposits and subgingival calculus being removed at the first sitting. After a few days' use of the mouth wash the stains and bacterial plaques upon the teeth and any overlooked deposits may be removed. Tincture of iodin painted over the teeth brings the deeper stains of the collection into prominence, as does also a solution of potassium permanganate.

Register states that a forcible spray of 1 per cent. hydrogen dioxid used after the application of tincture of iodin will soften the stains and render them more readily removable. The iodin is also rather germicidal.

Prophylaxis.—The smoother the surfaces of the teeth are made, the longer the redeposition of calculi will be delayed. Black sug-

FIG. 643

FIG. 644

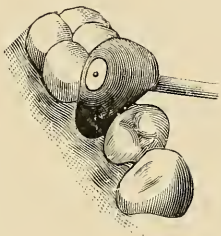

FIG. 645

Jack porte-polisher.

gests the use of the ordinary chip syringe and plain water, a forcible stream being accurately used to wash away the agglutinin. As a means of calculus prevention it should be valuable.

It is a wise measure to cleanse the teeth before any long series of operations is undertaken, and as a prophylactic measure in the combat with caries and pyorrhea alveolaris the operation should be frequently performed. Indeed, the teeth should be cleansed frequently, so that it may not be necessary to remove actual salivary calculus, except in those cases in which it collects with abnormal rapidity. A stick in a metal handle for self-prophylaxis is useful if the patient will use it. (See p. 442.)

In cases of very rapid recurrence of salivary deposits, evidence of an associated systemic condition should be sought. In this direction sialosemeiology and urinalysis may develop data worthy of attention. The systemic condition, if recognizable, should receive appropriate treatment. If not recognizable, the method suggested by Black of reducing the quantity of food and

the thorough mastication of such as is taken, may be conjoined with the occasional use of Epsom salt, if further needed as suggested. (See p. 697.)

SUBGINGIVAL CALCULUS.

By subgingival calculus is meant that form of deposit which occurs beneath the free gum margin and between it and the tooth. The deposits consist of small scales or granules, usually quite smooth and much darker (olive green) than salivary calculi (Fig. 646).

FIG. 646

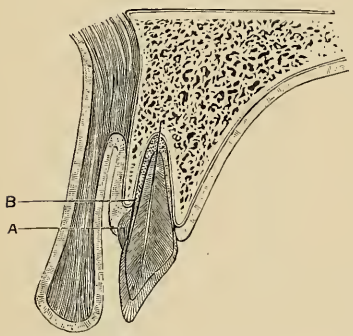

A, subgingival calculus; *B*, receding pericementum. (Black.)

FIG. 647

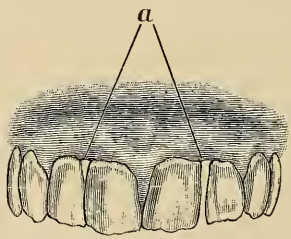

Resorption of the septum of bone and recession of the gum between the central and lateral incisors, caused by deposits of serumal calculus under the gingivæ. (Black.)

Composition.—They consist mainly of calcium phosphate combined with undetermined organic substances. (See pp. 694 and 697.)

FIG. 648

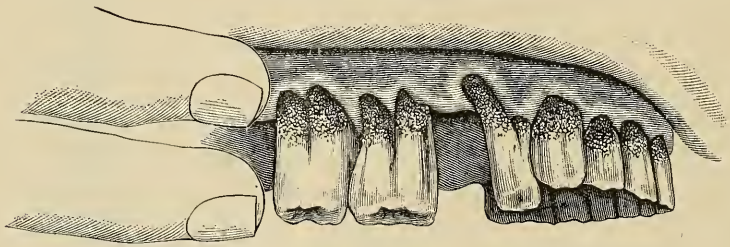

The alveoli irreparably destroyed by calcic inflammation. (Black.)

Cause and Pathology.—It is probable that some degree of marginal gum irritation first occurs, though many cases of an apparently healthy gum with a scale of calculus beneath it are seen. Whether the irritation arises through fermentations about the unclean necks

of the teeth or as the result of an effort upon the part of the gum margin to eliminate waste products from the system is not absolutely certain.

The theory most tenable is that uncleanliness exists; fermentation of the mixed marginal collection and altered gum secretion containing a precipitable organic material, occurs, the gum secretion containing also calcium salts; these are precipitated, forming a calculus. Fig. 297 shows a calculus on an unerupted tooth root, showing that the blood contains the elements necessary for its formation under localized irritation.

Talbot has shown that a natural pocket may exist at some aspect of the gingival space which is capable of harboring collections of foreign material. The normal gum margin closely approximates the tooth and has an apparent protective influence over the portion it covers. For some reason, such as a lack of normal friction or the presence of microbic plaques just above it, the gum may lose its normal tone and the calculus deposition be favored. Its secretion is also probably altered in quality.

Effects and Symptoms.—The direct effects are exerted upon the gum margin. The mechanical irritation may cause the gum and alveolar process to undergo resorption, the calculus being exposed.

At times this resorption is accompanied by evident marginal inflammation, at others the gum margin has a normal color, but the resorbing portion is sharply defined by a fine line (or crease) from the normal gum tissue, especially at the interdental septum. In a more advanced stage this demarked portion appears sunken or atrophied, and may have a sort of semihyalin redness characteristic of the inflammation. At times the gum margin appears everted (Fig. 647 *a*). If the deposit occur on only one side of a root the gum resorption may be confined to that side.

The lingual root of an upper molar is often exposed for a considerable portion of its length by successive deposits of calculi. The same is true in other situations, notably upon the labial surface of a lower incisor. This might be called a form of marginal phagedenic gingivitis.

If the deposit be generally distributed about the neck of the tooth the resorption is more equalized.

In some cases the bifurcation of roots may be exposed and calculi deposit in that situation.

In some cases the gum margin becomes simply atonic or passively congested and is pushed away from the teeth by large masses of the calculus, which undergo lateral accretion. It appears as a flabby, thickened, loosened gum margin, which readily draws about the

necks of the teeth if the calculus be removed. I have noted this in cases of suboxidation with bluish lips, and in renal insufficiency.

FIG. 649

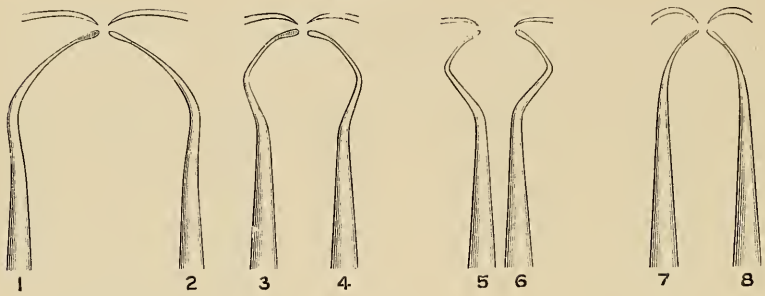

FIG. 650

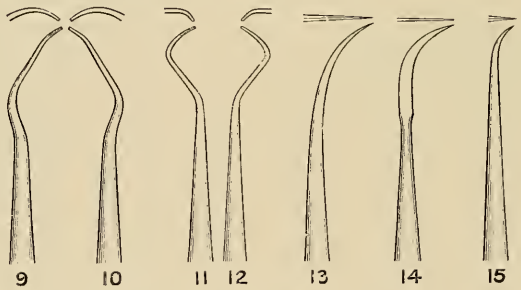

Younger's new set of pyorrhea instruments. (Revised by Dr. Robert Good.)

FIG. 651

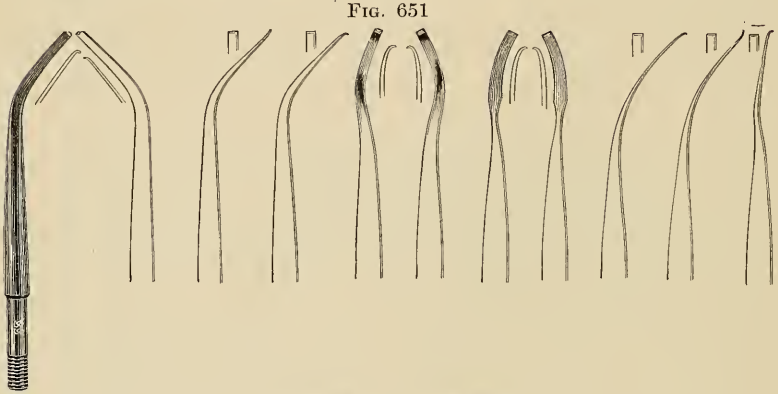

Tompkins' pyorrhea scalers.

Finally, pyogenic infection may occur about the calculus and the symptoms of pyorrhea alveolaris be implanted. When this is established, calculi may be deposited farther up the side of the root. This

pathology often precedes the condition of pyorrhea alveolaris which may supervene if pyogenic organisms enter the area.

Treatment.—The calculus should be removed by means of delicate scalers used with either the push or draw cut, as most convenient, after which astringent antiseptic mouth washes should be prescribed. The subsequent frequency of removal of causes by oral prophylaxis is of great importance. Figs. 649, 650, and 651 show convenient forms also useful for the deeper pyorrhea pockets. In most cases healing is spontaneous even without medication, but often the washes are of advantage. If pyorrhea be present on any tooth it is to be considered separately.

PYOGENIC CALCULUS.

Pyogenic calculus is that form of serumal calculus which is deposited at parts of the tooth root over which pus more or less continually flows. Talbot has shown that pus is rich in calcium phosphate.

In chronic apical abscess the root end may become encrusted with it, and in those cases in which apical abscess discharges along the pericemental tract it is common to find over the area fine granular deposits which vary in color from a light yellow to a reddish brown.

The same is true of active pyorrhea pockets.

This calculus prevents the healthy apposition of the gum tissue to the roots, probably because of its irritant and infective nature (Figs. 558 and 652).

Treatment.—All such calculi should be removed by whatever means possible, which may necessitate scraping the root end or its side, or even the amputation of the apical end of the root. In some cases 25 per cent. sulphuric acid or Tartasol may dissolve it. (See pp. 622 and 738.)

HEMATOGENIC CALCULUS (Syn. SANGUINARY CALCULUS).

This form of serumal calculus occurs in the so-called gouty pericementitis, a form of pericemental abscess.

It may occur in the abscence of apical abscess or a primary pyorrhea alveolaris, and, therefore, at points not acted upon by saliva or pus; hence it must be deposited by the blood through the lymph.

Miller[1] has offered satisfactory evidence of this in a description of a case of impacted cuspid well embedded in the bone, and not in any way exposed to either saliva or pus influence except that at a

[1] Dental Cosmos, August, 1901.

point over the cusp the gum underwent suppuration for a short time. The crown had undergone resorption, showing local irritation, and an olive-green calculus had formed upon the middle third of the root. Cases of pericemental abscess have been noted opening upon the gum face and presenting dark green calculi upon the root in that situation (Fig. 297). (See Pericemental Abscess.)

Peirce found in such deposits a proportion of sodium urate as shown by the murexid test and the cases associated with goutiness of the patient.

While such deposits may not cause immediate irritation, they may in time excite inflammation and necrosis of tissue, resulting in a discharge of glairy material representative of the condition. This form of dental disease will be further discussed.

CHAPTER XXIV.

PYORRHEA ALVEOLARIS.

General Considerations.—The term pyorrhea alveolaris means a flow of pus from a pus pocket located between the root of the tooth and the alveolar wall at the lateral aspect of the root. Apical and lateral abscess from gangrenous pulp or perforation are excluded. The alveolar wall may be more or less intact and either be exposed and necrotic or, as more generally the case, be still covered with its internal periosteum, which is the remains of the pericementum. In some cases the bone has disappeared and the gum tissue forms the outer covering. Pyorrhea alveolaris always involves the consideration of marginal and deeply seated gingivitis, but these need not necessarily be pyorrhea. It is therefore somewhat difficult to differentiate from gingivitis proper, as any form of gingivitis may later assume the characteristics of pyorrhea owing to infection.

In a general way pyorrhea alveolaris may be diagnosticated when there is a progressive gum pocket formed at the expense of the lateral portion of the pericementum, and the tooth becomes progressively loosened. Usually calculi and a pus flow are found, but in some cases neither are much in evidence.

The disease ceases spontaneously with the loss of the teeth, though the alveolar process is further resorbed as after any extraction.

Causes.—It seems that anything which may induce a gingivitis may initiate the process when infection is added of a character that will destroy the pericementum and produce the pocket at its expense. Therefore the causes of gingivitis or even of non-septic pericementitis are the primary causes of pyorrhea alveolaris (see pp. 665, 674, and 682, etc.).

The gingivitis itself is the proximate predisposing cause and the specific infection is the proximate exciting cause. It is obvious that these are difficult of exact differentiation, *i. e.*, it is difficult to say when gingivitis ceases to be such and becomes a pyorrhea, but when the pocket is established the case may practically be called a pyorrhea, and is treated as such. From a prophylactic standpoint it is wise to remove all causes of gingivitis as it is apt to lead to a pyorrhea.

The causes of marginal gingivitis are mostly obvious and have been discussed. (See p. 674.) The causes of deeply seated gingivitis apart from pyorrhea are more obscure, but, as stated in the dis-

cussion (p. 682), are either the more deeply acting causes of marginal gingivitis or are due to local or systemic causes which produce a more or less profound pericementitis or gingivitis apart from the alveolar pockets, and which have a tendency to cause inflammatory degeneration of the soft tissues and to produce a resorption of the bony tissue, thus predisposing the soft tissues to the local action of bacteria, or, in other words, lessening their resistance to bacteria.

Aside from inflammatory conditions actually produced by systemic conditions, the pericementum may be influenced by a lack of proper nutrition, as in anemia or neurasthenia or some form of systemic drain, as peripheral nutrition is evidently lessened in such states, and tissues seem more subject to infection. The opsonic index is probably lowered. (See p. 62.)

Investigations as to cause have proved uncertain in so far as the determination of a specific bacterium is concerned.

Galippe and Malassez, Miller, Black, Talbot, Goadby, Younger, Cook, and others have all failed to definitely isolate such a specific bacterium. The closest approach to a demonstration yet made was the determination by Kirk of the presence of a pure culture of the Diplococcus pneumoniæ in a few cases of freshly opened pericemental abscesses (which see).

The investigations of Goadby, however, do not confirm this as a cause of pyorrhea alveolaris in general, but rather point to the probability that the cause may be found among other oral bacteria, possibly thread forms or some of the blastomycetes. Talbot believes the ordinary pyogenic cocci to be the cause of the pus production.

Recently, M. T. Barrett,[1] working with Allen J. Smith, M.D., has found in the pus of 46 straight cases of pyorrhea actively motile endamœbæ (probably Prowazek's endamœba buccalis (Barrett)). Of ten apparently healthy mouths used as controls close examination revealed three with pockets with endamœbæ in the contents and seven without pockets or endamœbæ. The local treatment with an amœbacide (emetin hydrochlorid, ½ to 1 per cent., in normal saline solution was effective on several successive days. He refers to a flagellate protozoön and a ciliated one as found occasionally. Whether this is the exciting cause of pyorrhea, Barrett has not yet definitely claimed. Chiavaro[2] also found the endamœba buccalis, but regards it as non-pathogenic.

Curtis[3] believes obstinate cases of the disease to be either caused by or aggravated by tertiary syphilis. He bases his belief upon observations of fresh blood which, he states, upon the authority of Dr. Robert L. Watkins (New York City), contains syphilitic spores.

[1] Dental Cosmos, August, 1914.
[2] Ibid., September, 1914.
[3] Ibid., 1901.

"Egg-skin" eschar is the oral pathognomonic sign.

According to Curtis, the local infection in nearly all cases is of so mixed a type as to render it at present uncertain whether the liquefaction of the peridental membrane, etc., is due directly to the pyogenic organisms present in the pus formed or to other oral bacteria of uncultivable type which may initiate the process, after which pyogenic organisms may enter and form pus. The fact that pyorrhea alveolaris is seldom found fully established before thirty years of age, but is common after that period, and that it occasionally occurs in youth or even in childhood associated with some pronounced systemic state or disease, strongly indicates a systemic factor in the more pronounced forms of the disease.

The type of teeth affected is usually that of the narrow-necked variety in which the angle formed by the gum and tooth is less accessible to the brush and friction of mastication. This leads both to formations of calculus and to the retention of infective material.

In brief, it may be stated that the infectious nature of pyorrhea alveolaris is becoming more established though not yet fully scientifically proved, and that the causes probably require a local predisposition for their action, though it may be that continued infection is a sufficient cause. This local predisposition may be the outcome of local sources of irritation and degeneration alone or be produced by waste products floating in the blood stream, etc., or by a lack of nutrition due to general causes. Clinically in support of a local origin it may be observed that oral conditions leading up to pyorrhea are seen existing for years previous to a fully established and active condition. The presence of such a state therefore must not lead one hastily to assume that it is of necessity a disease of systemic origin, and at present the systemic sequels of pyorrhea seem of more importance than its possible systemic origin. In observing mouths at all times one should look ahead from all forms of gingivitis or causes liable to produce it to a possible future pyorrhea and take measures to prevent it. (See pp. 665, 674, and 682.)

Clinically, fully established cases of pyorrhea alveolaris may be divided into three classes: (1) Cases associated with a primary gingivitis and with the formation of hard, scaly, dark, annular calculi beneath the gum margin (subgingival calculus), the pockets not usually extending far beyond the deposits; (2) cases beginning with a marginal gingivitis and apparently not dependent upon the association with calculus, though frequently complicated by it; (3) cases having an apparent origin at some point between the gingival margin and the apical tissue, the gingival margin at first being apparently intact.

It is probable that the infecting agents in these types differ in their nature, or that in the event that they may be proved to have a similar origin the tissues react differently to them, either partially resisting them, forming calculus as a result of the irritation, or rapidly giving way to them, permitting a deep action.

In the abscence of known causes the conditions may be divided according to their clinical expressions.

In the consideration a pus flow due to apical abscess, lateral abscess upon a perforation, or that due to obvious salivary calculus (for these, see under proper headings), also simple gingivitis or deeply seated gingivitis, not resulting in the clinical feature of pyorrhea as defined, are excluded.

PYORRHEA AVEOLARIS BEGINNING AS A MARGINAL GINGIVITIS AND ASSOCIATED WITH SUBGINGIVAL CALCULUS.

Causes.—The causes of this condition are those predisposing and exciting causes of marginal gingivitis which have been described. (See p. 674.) Several local factors have to be considered in this connection: (1) The marginal infection; (2) the irritative effects of any calculus that may be formed; (3) the deep infection by pyogenic organisms; (4) the modification of the progress of the disease by the attendant loosening of the teeth and death of the pulp.

Clinical History, Pathology, and Symptoms.—There is usually an unclean condition of the teeth; infection exists either in tenacious films of bacteria attached to the necks of the teeth and requiring reasonably close observation for their detection, or in masses of detritus readily noticeable. Subgingival calculus is, as a rule, obviously present (Fig. 657).

The gum margin may be atrophied or be inflamed; or it may have a fairly normal appearance. When the gum margin is pressed upon, pus may be squeezed out in variable quantity.

It is assumed that the local infection brings about the deposit of mucous exudates rich in calcium salts at a point beneath the gum margin, and that formation of subgingival calculus occurs, followed by pyogenic infection and pus formation.

The gum may now be resorbed either with apparently normal bulk or the margin may be everted and thickened into a cord-like margin which is either of normal color or inflamed; the shrinkage of the gum causes the exposure of the calculus (Fig. 646). In this manner the bifurcations of the roots may be uncovered and calculi be deposited in that situation. The resorption may only be confined to one side of a root and be the result of several successive

depositions which may remain when the gum recedes, or which may be removed and again be deposited. In this way the side of the root may be exposed nearly to, and in some cases quite to, the apex.

FIG. 652

Serumal calculus, showing stalactite-like formations. (Talbot.)

The destruction of the tissues may assume several forms. In certain mouths, especially in neurasthenic and anemic patients, a viscous material may accumulate upon the necks of teeth or exposed

FIG. 653

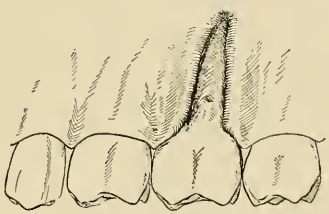

Destruction of pericementum, bone, and gum over buccal root of a molar.

roots; and the pericementum, bone, and gum may rapidly inflame and disappear, leaving the roots exposed to collect more of the material, while pus may not be much in evidence.

The resorption may occur as shown in Fig. 654, or the gum may be split and the destruction follow the length of the root on one side only until even the apex is reached (Fig. 653).

The tooth may be loose or firmly attached by the remainder of the pericementum. This is especially true of those teeth having very narrow necks, in which the roots describe a prominent curve just above the cervix.

FIG. 654

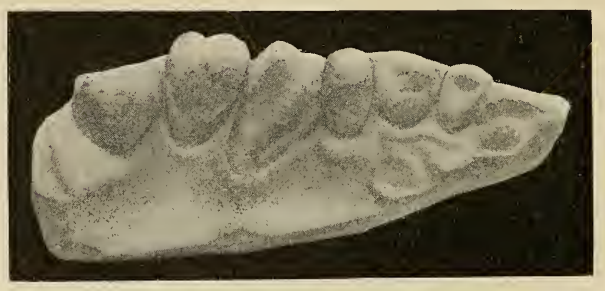

Resorption of gum over palatal root of an upper molar, associated with but trifling deposit of calculus, but the root is covered with a viscid deposit. Aged thirty-two years. Patient neurasthenic and of tuberculous diathesis. Condition in 1904. Tooth lost in 1907. In 1912 several other teeth were lost. In 1914 several more have gone.

Fig. 654 is a model of the lingual side of the right upper teeth undergoing the former process. The left upper posterior teeth and the lower incisors have also been lingually affected. There is but little calculus, but the viscous material is quite abundant, black stain is present, and dental caries is rife. The patient has been anemic and neurasthenic for years, and one lower molar has been removed for resorption of the apices of the roots associated with looseness. Many teeth have been lost. The patient is unable to perform an exact dental toilet and does not employ the dentist as she should.

In such cases the pus pocket may not be deep and the pus formed may readily be washed away. Such cases present some resemblance to simple gingivitis and might be so classed if there were no pus flow. Instead of this the pericementum may be progressively destroyed by suppuration and the gum margin remain practically intact. In these cases the pus flow is more abundant, a deep pocket is formed, extending a third or even two-thirds or more of the length of the root (Fig. 655). It is common to find beads of calculus deposited along the side of the root and presumably of serumal origin. (See p. 708.) The cementum being deprived of nutrition, its minute nutritional openings or openings containing fibers harbor bacteria.

These inflammatory disturbances necessarily involve deeply seated gingivitis or infiltration of leukocytes into the interstitial

connective tissue of the gum. As pointed out by Talbot, resorption of various kinds and at times constructive changes accompany such an inflammation. (See Deeply Seated Gingivitis.) Endarteritis is also noted. These results are noted in connection with this variety of pyorrhea alveolaris. In the early stages of the disease the probe usually fails to discover uncovered alveolar bone, although it may do so. If not uncovered its loss is due to resorption; if, however, necrotic and bare alveolar bone be found, it is undergoing a molecular necrosis under the influence of the pyogenic organisms.

Fig. 655

Pyorrhea pockets. Mesial root of molar largely denuded. Treated by amputation. (Price.)

Fig. 656

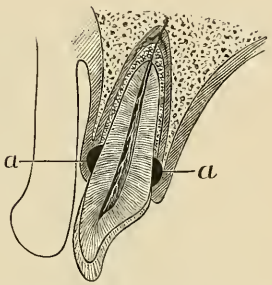

Section of an upper incisor, showing at *a*, *a*, a deposit of serumal calculus within the free margin of the gum. (Black.)

In some cases the pericementum may be destroyed at the cervical third of the root, the aveolar process may be resorbed on its inner surface, and an accompanying constructive irritation may cause the deposition of bone upon the outer aspect of the alveolar process; the gum margin is also thickened by cell proliferation. The condition imparts the appearance of hypertrophy of the gum and gum margin (Fig. 657). The inflammation of the pericementum may become general and the attendant swelling forces the tooth into malocclusion with its antagonist. The mechanical factor is now introduced and the extrusion increases gradually or even rapidly. Sometimes such teeth can be ground one-eighth inch before removing the excess occlusion. Such constant pounding is deadly.

When about one-half or more of the root has been stripped of pericementum and deprived of alveolar support, looseness and extrusion of the tooth become marked.

The advance of the disease now becomes more rapid; the undue mobility and malocclusion of the tooth excite an inflammatory reaction beyond the directly infected part; so that soreness and looseness are further increased. Extraction at the later stages reveals a thickened apical pericementum as the sole attachment to

the bone. After the looseness of the tooth becomes marked, the pulp of the tooth undergoes hyperemic changes, reacts to thermal stimuli, and is often killed by strangulation of its vacuolar supply. Pulp nodules often are formed before its death. Reflex symptoms may occur at this stage when the pus pocket approaches the apex. (See Pulpitis.) Infection of the dead or practically dead pulp readily occurs *via* the pocket (see Fig. 653), and septic apical pericementitis arises. The symptoms of the latter condition are modified, according to the facility with which the pus finds vent along the pyorrhea pocket. In some cases pericemental abscess becomes associated. The disease proceeds until the affected tooth or teeth are cast out, the alveolar walls having been largely absorbed, and

Fig. 657

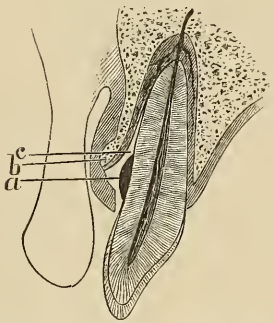

Section of an upper incisor, showing destruction of the peridental membrane and eversion of the alveolar wall, with thickening of its border: *a*, serumal calculus; *b*, thickened border of the alveolar wall; *c*, pus cavity. (Black.)

Fig. 658

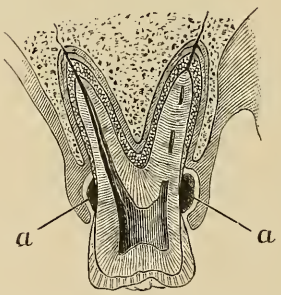

Section of an upper molar with its alveolus, etc., showing deposit of serumal calculus under the gingival borders: *a*, *a*, serumal calculus. (Black.)

the pericementum largely destroyed. The remainder of it is usually swollen. The disease ceases with the loss of the affected teeth, leaving a flattened or absent alveolar ridge covered by a mass of more or less spongy gum tissue.

The duration of this disease may be months or years, and a number of teeth may be affected at once. A general subcatarrhal condition of the mouth usually attends the disease. The presence of pus often imparts to the breath a peculiar, sweetishly fetid odor which may, however, be masked by an odor of putrefaction (pigstye or sewer-gas odor).

It is often the case that the shifting of pyorrhetic teeth permits the other teeth to move into a position in which they malocclude. This brings in a mechanical cause of interstitial gingivitis, which,

with the existing infection, brings other teeth into the pyorrhetic state.

Associated Abscess.—In a number of cases of deep pyorrhea pockets an infection of the aveolar structure, or, at least, of the tissue remaining over the deepest portion of the pocket, may occur, and an abscess form which discharges by a fistula through the labial or lingual aspect of the gum. It is to be regarded as an abscess secondary to a primary pyorrhea alveolaris. The passage of a silver probe through the two sinuses at once will reveal this (Fig. 660). In a

FIG. 659

Inflammation of pericementum, endarteritis obliterans. Talbot's case. (Latham.)

tooth treated for apical abscess such a pyorrhea pocket existed, and doubt arose as to the cause. The fact that it was near the gum margin and the probe could not be passed into a sinus leading to a root-end was considered evidence of abscess secondary to pyorrhea. Evacuation and antisepsis were sufficient to effect a cure.

In one case of pyorrhea alevolaris of the variety under consideration the pocket existed upon the mesobuccal aspect of a right lower third molar. The second and first molars were absent. The pus dissected away the periosteum of the bone and formed a large abscess

over the entire area of bone between the third molar and second bicuspid. After evacuation of the abscess, the probe was passed through it to the pyorrhea pocket (Fig. 661). Another expression occasionally occurs. The infection travels via the natural channels in the pericementum from the pyorrhea pocket to a deeper point in the pericementum (for example, to a point one-quarter inch or more below) producing what is called a pericemental abscess. The tissue between may seem unbroken and the fistula may seem like that associated with chronic apical abscess. Fig. 662 will illustrate the manner in which this may occur. In a case of a pyorrhea pocket on a lower lateral, transillumination showed a bright red spot at a point a quarter-inch below the pocket, and to the side of the root. The pain was intense, and only relieved by opening at this point with a lancet. In another case a fistula appeared on the buccal

Fig. 660

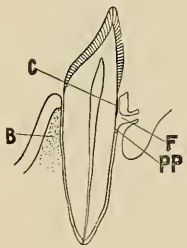

Gingival abscess secondary to pyorrhea alveolaris: *C*, calculus in pyorrhea pocket; *F*, fistula leading to pocket *PP*; *B*, bone on lingual side.

Fig. 661

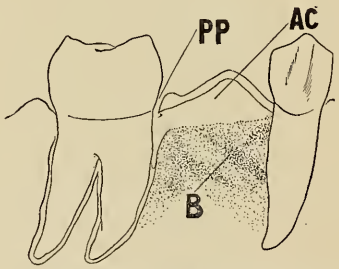

Diagram of abscess secondary to pyorrhea alveolaris (see text); *PP*, pyorrhea pocket; *AC*, cavity of secondary abscess; *B*, bone.

gum about one-third inch above the margin and between the buccal roots of an upper molar. The crown was tapped by a student for dead pulp, but exposure of the pulp demonstrated its vitality. Exploration showed a distolingual pyorrhea pocket leading into the bifurcation between the distobuccal and lingual roots. From thence the pericemental abscess discharged buccally between the buccal roots.

While dental caries may occur with pyorrhea alveolaris, it is usual to find the teeth of the most highly organized structure. The pulp tissue is usually increased in density, and there is a tendency to the constructive changes, secondary dentin, nodules, etc., and the inevitable degenerative changes following these diseases.

It has been contended that these pulps are responsible in a measure for the pyorrhetic condition, and it is possible that they may, by reflex action, influence the tissue nutrition of the pericementum and

gum margin, though the contrary process is more than probable, as pyorrhea frequently causes a pulp hyperemia which subsides with the cure of the pocket. If the pulps be degenerated, which is likely in very loose teeth or deep pockets, their removal aids the cure of the disease by diverting the blood they receive into the pericemental bloodvessels. This probably counterbalances the effects of the endarteritis obliterans. (See Deeply Seated Gingivitis.)

Fig. 662

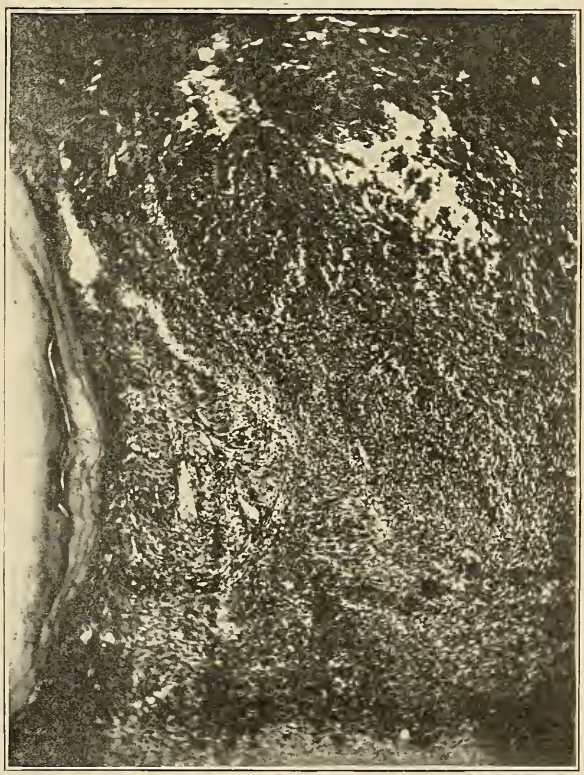

Pericemental abscess associated with a pyorrhea pocket. (V. A. Latham.)

It is also true that calculus does not seem to form as readily upon a devitalized tooth as upon one containing a vital pulp; it does form at times, however.

Diagnosis.—The diagnosis is easily made when the disease is established by observance of the phenomena just described. In difficult cases with pocket approaching the apex or bifurcation, a

skiagraph may be necessary for accurate determination of the extent of the disease (Fig. 655).

Prophylaxis.—As outlined above, the prevention of pyorrhea alveolaris of the first class involves the removal of the local and, if possible, the systemic causes of the gingivitis, if any exists, and the systematic cleansing of the teeth at short intervals. The daily use of the tooth-brush and antiseptic powders and washes by the patient is also important.

D. D. Smith advises, for this class of cases, a thorough cleansing once a month, or at first even oftener. The cleansing is to be done with an orange-wood point, grasped in a Jack porte-polisher and charged with pumice paste, best made with hydrogen dioxid. The local sources of gum infection are thus continually removed and the gums stimulated by the mechanical irritation with the wood point. Bridges require careful cleansing. (See pp. 441 and 737 for further ideas of prophylaxis.)

Treatment.—The treatment of well-established pyorrhea alveolaris of the first class is to be considered under three headings: (1) The removal of pus, calculus, and bacterial films; (2) the prevention of extreme mobility; (3) the medicinal treatment and the prophylaxis, or prevention of a relapse into the diseased condition.

The Removal of the Causes.—Calculus being an obvious irritant, it should be removed from crowns and all parts of the roots. To prevent infection of surrounding tissues and to remove the pus present the pockets are to be flushed out with hydrogen dioxid, which may be done by means of a syringe with fine nozzle after spraying out the superficial parts by means of an atomizer operated by compressed air. The forcible spray lifts away the gum margin and cleanses mechanically as well as chemically though not the depths of the pockets. The mouth is reasonably sterilized at the same time. If large quantities of supragingival calculus exist, it is well to next remove the gross deposits and permit the patient to use an astringent, antiseptic mouth wash for a few days, or the operation may be proceeded with.

Following this, cotton containing 10 per cent. trichloracetic acid may be packed into the gum pockets in order to superficially constringe the gum tissue, lessen the hemorrhage, and render more facile the removal of the subgingival calculi. The latter is accomplished with scalers of any suitable form, working either with a push or pull cut as best suits the case.

Fig. 663 illustrates the method of guarding against unnecessarily wounding the soft tissues. If the calculi be extraordinarily inaccessible the pockets may be enlarged by packing for ten or fifteen min-

utes with cotton tampons saturated with the 10 per cent. trichloracetic acid, which also softens the calculi, or salicylized cotton may be left in the pocket for a day. (Black.) In some cases novocain injections or applications of powdered cocain carried into the pocket on the working instruments must be made to prevent excessive pain. After removal of the bulk of calculus with scalers any fine granules

FIG. 663

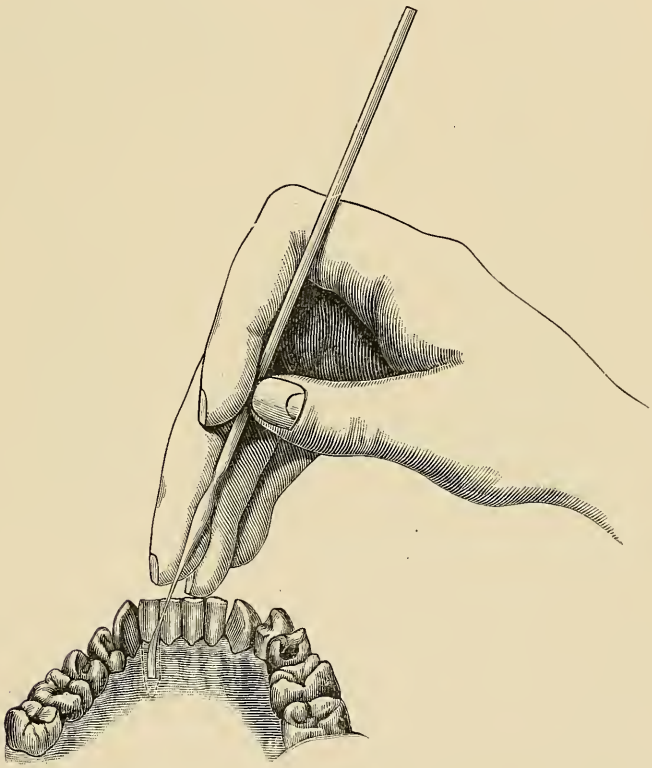

Showing the manner of holding an instrument for detaching calcareous deposits when using the pushing motion. The third finger rests on the edges of the teeth, allowing freedom of the hand to make rapid and effectual movements in dislodging the calculi.

or gummy collections should be well rubbed off with Rhein's approximal trimmers, or Smith's pyorrhea instruments. After this medicinal applications are made (see later). The scaling of each tooth is to be completed at one sitting, though more than one may generally be done, as repeated scalings interfere with the regenerative process, and the pocket is most accessible at that time. Hartzell claims that

if the cemental surface be scraped away to the depth of the attachment of the peridental fibers a source of infection lying in these minute openings will be removed, and the surface will be left smooth.[1] The lacunæ of the cementum should not be invaded.

Fig. 664

Scalers (three times natural size).

Fig. 665

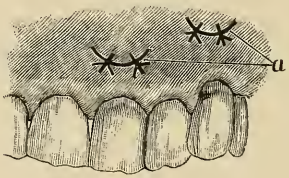

Illustration of the position and form of incision through the gum for exposing the root of the tooth and injured alveolar process: *a*, incision. (Black.)

The gum margins are not to be unnecessarily wounded, but very redundant granulations may be cut away. In case the pockets are so deep or have such form that the aveolar margins cannot be well trimmed without overstretching or injuring the gingival edges, Black advises that gum flaps be raised, exposing the alveolar margins (Fig. 665). A semicircular incision is made and turned back, and bleeding checked. By means of sharp chisels the alveolar borders are freely scraped, the pockets are flushed with hydrogen dioxid, and the flap secured by a couple of stitches. Local anesthesia should precede this operation. The same writer advises, in cases where eversion of the alveolar margin has occurred, that the process be exposed by cuts and broken down by three cuts made with a sharp chisel and mallet; the loosened segment of bone to be pressed firmly against the root. It is desired next that the entire pocket will fill with granulation tissue, and organization of the granulations take place, furnishing reattachment. That this occurs in some cases is undoubted. A reproduction of alveolar margins also occurs in some cases. The hope of good results lies in keeping the parts aseptic after all foreign deposits and dead material have been removed.

In cases of excessive loss of the pericementum of one root it is well to devitalize the pulp, as, in all probability, that organ will have been overstimulated and will be in a degenerative condition, and sometimes is actually infected. An abnormal response to thermal

[1] Dental Cosmos, 1908.

changes (ordinary cold) may occur (hyperemia or inflammation), or the pulp may fail to respond to extraordinary cold (ethyl chlorid), indicating degeneration. If the condition be marked and persistent after pocket treatment the pulp should be removed and it is well to resort to its removal at once when the pocket approaches the apex of the root, as the pulp is apt to be hopelessly affected. It has been claimed by Rhein, Smith, and others that the nutrition received by it will be diverted into the pericementum, to the benefit of the latter. Clinical experience seems to confirm this statement. The method also permits the use of pins placed in the root canal as part of an appliance fixing the teeth in position. An exposed pocket in the bifurcation may be treated by scraping and flowing oxyphosphate of copper cement into it (Figs. 666 and 667). In case of hopeless involvement of one root of a multirooted tooth the root

FIG. 666

Pyorrhea pocket in bifurcation.

FIG. 667

The same treated by scraping and filling with gutta-percha or oxyphosphate of copper. (Radiographs by Price.)

may be amputated if the remaining roots will endure the strain put upon them. Indeed, the other roots are apt to be firmer if the adjoining inflammation is thus removed. The canals of the roots must have been previously carefully filled.

Rhein[1] calls attention to the fact that collections are apt to occur about the surface left by the amputation, and that postextraction resorption of the alveolar process occurs. To obviate this he suggests the use of a porcelain root to replace the lost root, and about which the tissues contract firmly and remain in a healthy condition. This operation Rhein terms "heteroplasty following the amputation of natural roots."

Briefly outlined the process is as follows:

1. Prepare and fill the root canals as far as the pulp chamber; fill this with temporary stopping.

[1] Dental Cosmos, September, 1900, and September, 1902

2. Amputate the necrosed root by means of a fissure drill, and remove.

3. Coat the root with a film of paraffin to allow for shrinkage of the porcelain.

4. Take an impression of one-half of the root (longitudinally) by embedding in plaster; make articulating grooves and pour plaster for an impression of the other half; separate and remove the root from the plaster.

5. Burnish matrix platinum into each half of the impression, stiffen with porcelain, and reburnish. Complete one side with porcelain as in inlay work; in the other fuse a platinum box formed over a square platinum pin (this pin should be left in the box until the packing of the porcelain about the box is complete).

6. Flatten the proximating sides of the halves; paint with thin, fresh body; press together and fuse.

7. Strip off all platinum and dress off all protruding points, coat the entire porcelain with a thin film of body, place in furnace in an upright position, and heat almost but not quite to a glaze.

FIG. 668

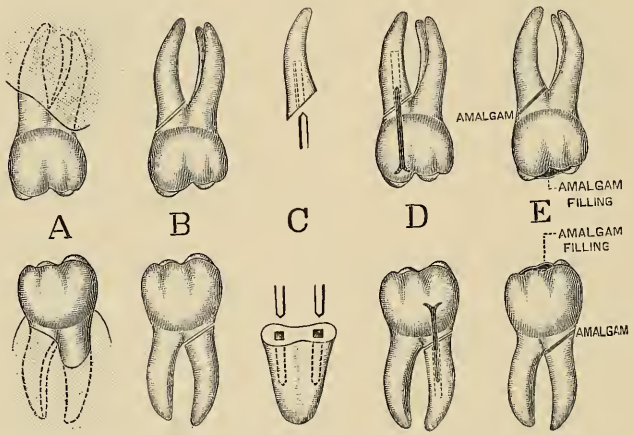

Heteroplasty following the amputation of natural roots. (Rhein.)

8. Wash out socket of natural root with antiseptics and remove temporary stopping from the crown cavity; try porcelain root in place, and if right dry everything; fill the box with cement, return the root to place, and pass the pin through crown cavity and into the root box. Adjust root, leaving a slight space for an amalgam joint.

9. Pack the crown cavity and the joint with amalgam, and at a later sitting finish the same (Fig. 668).

THE PREVENTION OF EXCESSIVE MOTION.—The excessive movement of loosened teeth but increases the deeply seated gingivitis in the remaining tissues. These demand rest. Any excessive occlusion due to the swelling of pericemental tissue may be compensated for by grinding the occluding surfaces. Such excessive occlusion and motion are readily detected during the act of occluding the teeth or by means of carbon paper. The fixation of teeth is a matter of mechanics, and the device used depends upon the case. Slightly loosened teeth may be temporarily splinted with ligatures of wire or floss silk. To prevent the slipping of these toward the gum margin it has been suggested[1] that small buttons of Harvard or other adhesive zinc phosphate should be placed upon the labial faces while under the rubber dam (Fig. 669). The floss silk may be saturated with a solution of chemically pure celluloid in acetone

FIG. 669

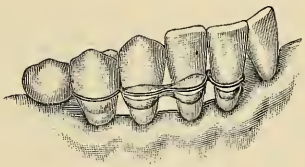

FIG. 670

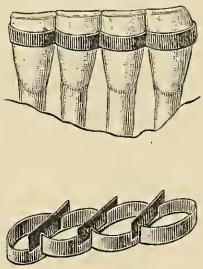

Temporary splint of silk floss or silver wire 30-gauge (one turn only shown). Buttons of zinc phosphate. (Rhein.)

(155 to 500 gr.[2]) to render it impermeable and more lasting. The preparation after application is allowed to dry under the dam to a coagulum and then dismissed for twenty-four hours, when it may be polished. It lasts for several months. The wire should ordinarily be of brass, as it is less likely to permit caries, and may be applied as a single strand being woven in figure-of-eight fashion, or a single loop may be made about all the teeth to be included and smaller loops about the wire at the interspaces, and these twisted tight to effect a tightness of the first wire. The fault in ligatures is that some mobility is always present. They may slip toward the gum, in which case a loop or two may be carried over the occluso-interproximal embrasure. For certain cases Dr. Hugh Mitchell has suggested a bar of iridioplatinum wire adapted to the lingual surface of the teeth to be splinted, and soldered to simple gold bands to be attached

[1] Reitz.

[2] Kowarska's paste.

with cement to two of the teeth adjoining the loose teeth. The other teeth are braced to the splint with fine wire, gold or platinum being preferred for anterior teeth.

Fig. 671

Diagram showing labial view of Mitchell's splint, with two bands and wiring.

Fig. 672

Diagram showing view of Mitchell's splint with two bands and bar.

Such a splint may be quickly made and is very effective, all slipping of ligatures being prevented; moreover, the wire may be kept away

Fig. 673

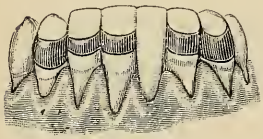

Five rings and included artificial tooth. (Evans.)

Fig. 674

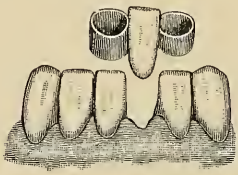

Two rings and included artificial tooth. (Evans.)

Fig. 675

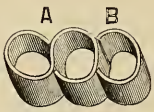

Method of making rings as in Fig. 538.

from the necks of the teeth and the gums. (Figs. 671 and 672.) After a reasonable period of immobility the attachment secured

Fig. 676

Labial view of a splint (see text).

Fig. 677

Lingual view of splint shown in Fig. 676.

Fig. 678

Occlusal view of the splint.

by treatment may be tested. Very loose teeth which have lost much of their supporting alveolar process must be secured by permanent splints. The simplest of these is a series of rings soldered

together, or its equivalent, shown in Fig. 670. The teeth are firmly ligated at their necks with floss silk. A wire measure is taken of the entire circumference of the teeth to be included, allowance being duly made for burnishing. A piece of thin platinum or 22 k. gold, No. 34 gauge and one-eighth inch wide, is cut to measure and a lap joint made and soldered. The ring is placed upon the teeth and moulded to their surfaces and to their interspaces. The thinnest separating saw is used to cut almost through the splint on both sides at one interspace. In this groove a straight piece of the plate is placed and the whole withdrawn from the teeth and the joints soldered. The process is repeated at another interspace and so on until the piece is complete. If the teeth are very tender, a plaster impression of the tips of the teeth may be taken and the work done on a fusible metal model. If space be necessary, the teeth may be slightly disked upon their proximal sides. If such spacing be not desirable, the necessary room can usually be obtained at the median interspace, but one platinum septum is placed and the piece is to be somewhat stiffened with solder at the indentations representing the interspaces. To render the appliance less conspicuous the entire lingual side may be stiffened with solder and solder be placed liberally at the junction of band and septum on the labial side. Nearly all the labial portions of the bands except the end ones may be cut away, leaving T-buttons at the labial portions of the septa (Figs. 676 and 678). The teeth may loosen in this more readily than in that shown in Fig. 670.

Another valuable device consists in grinding steps into the lingual surface of an incisor or cuspid. Soft thin metal is adapted. Three pins, No. 20 guage, are placed, two incisal straddling the pulp and one at the cervical step. The whole is stiffened with solder. Adjoining teeth may be united by union of these plates or they may be used as anterior abutments of bridges.

Fig. 679

It may also be used on centrals and cuspids. For example, in a case of loss of an upper cuspid and lateral the two centrals were fitted with the tripod step plates in Fig. 679 and the first bicuspid with a Carmichael, the pontic teeth then attached. No pulps were devitalized. In bicuspids the Carmichael attachment forms a very strong abutment.

Evans' method is readily comprehended by reference to Figs. 673, 674, and 675.

These splints are to be cemented with adhesive zinc phosphate so manipulated as to set quickly. Ames' cements are excellent.

The foregoing splints are too conspicuous for use in some cases

A simple device introduced by Dr. L. C. Bryan[1] consists of a pure gold band about one-eighth inch wide, nicely bevelled at its edges, and adapted about the *necks* of the lower incisor teeth to be splinted in somewhat the same manner that the splint illustrated in Fig. 670 is adapted. Particular attention is paid to the interspaces in the endeavor to bring the labial and lingual sections together as nearly as possible at that point. When ready the piece is sprung off, the rubber dam is applied, zinc phosphate is placed within the band and upon the necks of the teeth at all points, and the band is put in place and burnished. Before the cement has set gold wire is to be passed around the interdental portions, tightly twisted, and the twisted end cut off nearly to the band, and the remainder bent back into the indentation in the band. Dr. Bryan recommended gold clamps in the place of wire, but these are difficult of adaptation.

Such a piece is to be placed only on those lower incisors about which salivary calculus promptly collects, and should be avoided in the mouths of patients who will not present frequently for prophylactic service. Confined to such cases they do good service, and the cement does not readily wash away; indeed, a slight coating of calculus seems to protect the surface of it from solution. If the calculus be kept from the gum this remnant does no harm.

Several devices have been offered which require the devitalization of the pulps and filling of the root canals of the several teeth to be splinted.

D. D. Smith[2] suggests reduction of the lingual surfaces of the teeth and the fitting to them of thin metal backings, which, after adaptation to the teeth, are perforated and pins are thrust through for the root canals. After soldering each pin to its plate, readapting the latter and stiffening with solder, an impression is taken and the plates are united. The whole piece is cemented to place with oxyphosphate. A modification for vital teeth would be to drill three safe pits for pins for each plate instead of the one central pin for the canal, or to drill one hole through the incisal portion above the pulp for each plate. With this device one or more artificial teeth may be included to replace lost teeth (Figs. 680 to 684). The incisal edges, if broad, could have individual inlays cast on two safely placed pins (Fig. 277) and these soldered together.

Ames[3] suggests that in certain cases of lower incisors the teeth be devitalized and amputation be performed at the neck of each. Each root is then trimmed and fitted with a gold Richmond cap without pin (Fig. 683).

[1] International Dental Journal, 1899.
[2] Dental Digest, 1902.
[3] Dental Cosmos, 1903.

Fig. 680

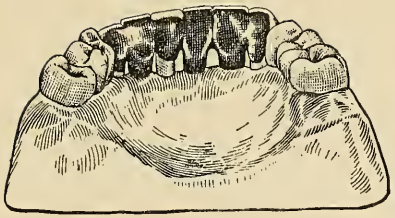

Splint for securing previously treated lower anterior teeth. (Ames, after Smith.)

Fig. 681

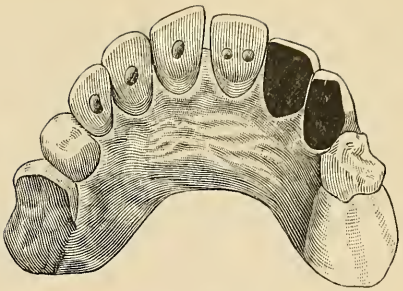

Upper teeth prepared for splint. (Ames.)

Fig. 682

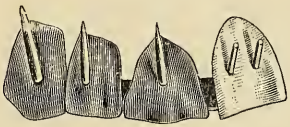

Splint for use in the case shown in Fig. 681.

Fig. 683

Root with cap fitted. (Ames.)

Fig. 684

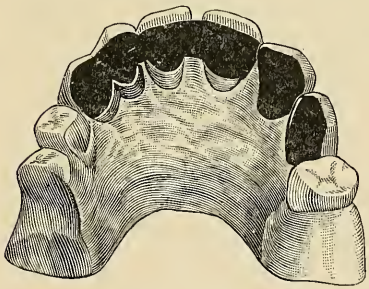

Same as Fig. 681. Splint in position.

Fig. 685

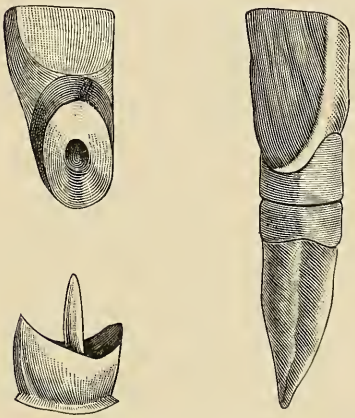

Tooth with Richmond cap. (Ames.)

Fig. 686

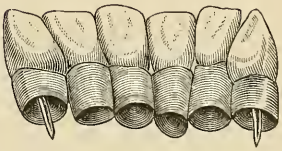

Splint for lower incisors. (See text.) (Ames.)

Each natural crown is slightly trimmed and fitted with a gold Richmond cap with a pin (Fig. 685). These two caps are united with wax, carried to the mouth, and adjusted in position. Each is then carefully removed, the natural crown laid aside (in water), and the gold sections invested and soldered together. The individual parts are readjusted in the mouth, an impression taken, an invest-

Fig. 687

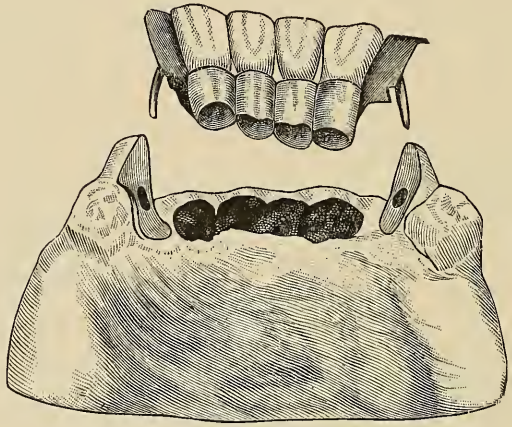

Splint for lower incisors. (See text.) (Ames.)

Fig. 688

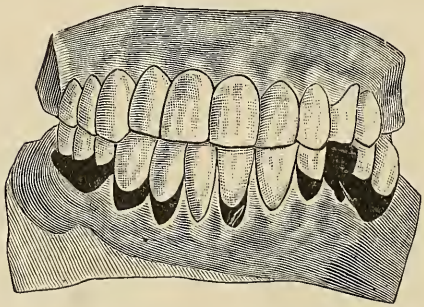

Splint and double saddle bridge combined. Front view. (Ames.)

ment made, and all soldered together. The natural crowns are then fastened in their prepared sockets with cement, and the piece is cemented to place. Pins may be placed in the roots if desired (Fig. 686).

If desired the piece may be further attached to the adjoining teeth by means of the lingual plate and pin (Fig. 687). The Ames

device would be useful in cases in which approximal cervical caries exists.

It may be stated that three or four teeth fairly loose individually, when united together may, as a whole, be quite firm.

Ames claims that the extension bridge shown in Figs. 688, 689, and 690 lasted for years and was in as good condition then as at the beginning. Fig. 688 gives the anterior view, Fig. 689 that of the right side, and Fig. 690 that of the left side.

Fig. 689

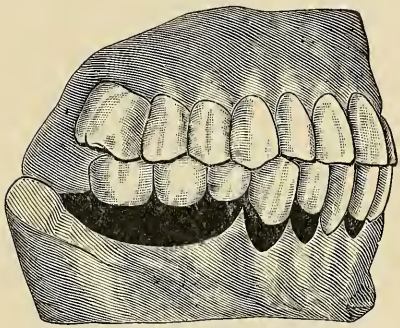

Right side of extension bridge shown in Fig. 688.

Fig. 690

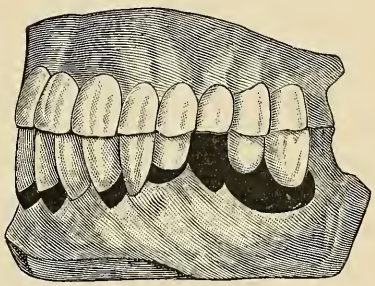

Left side of extension bridge shown in Fig. 688.

Rhein offers the following: After pulp removal and root filling a transverse groove is cut in the lingual side of the central or loose teeth and a half-groove upon the mesiolingual aspect of the pier teeth. A staple is formed of triangular iridioplatinum wire to fit into the root canals of the pier teeth. To this is soldered a pin for each of the central teeth. The face of the wire should approximately fit the bottom of the groove (Fig. 691). Rhein suggests the following method of attachment: (1) Fill the root with a paper point, place cement over that, and fill the cervical margin of the cavity and its floor with gold; (2) drill through the gold to the paper point, remove it, and refit the retaining appliance; when ready set with zinc phosphate, avoiding excess; (3) when this is set cut away to the gold and complete the gold fillings.

A less elegant but still practical method would be to cover the pins with a good, color-keeping amalgam pressed into the excess of cement before it has set. The margins are then to be freed of cement and the operation completed with amalgam, which later should be polished. In undecayed teeth this has no advantage over the method shown in Fig. 680; nor in decayed teeth over that in Fig. 685.

Smith's, Rhein's, and Ames' devices permit the use of an artificial tooth if necessary. The same may be said for the device which consists of a series of gold rings (Evans').

For the molars and bicuspids Rhein's device is transferred to the occlusal surface (Fig. 692).

Short metal caps made for the incisal tips of lower incisor teeth adjoining a space will successfully hold a bridge tooth. The device is, however, rather conspicuous. Well anchored gold inlays joined by solder or cast together, or a staple in two or more roots of different teeth about which staple fillings are later built may be useful. Carmichael attachments will serve for some teeth.

For the molar and bicuspid teeth it seems good practice to adapt short crowns to the teeth trimmed only to the fullest point of contour, and unite these with solder. Occasionally the bands may be slit occlusally and adapted closely without covering the cusps. A sort of bridge is thus made which causes the teeth to be firm even if all are originally loose (Fig. 693). It is mainly this factor which renders bridge-work useful in pyorrhea alveolaris upon isolated teeth. If the necks of such teeth are hypersensitive, silver nitrate may be used. This device is especially useful when teeth are inclined. As an example, an upper third and second molar were fitted with short crowns, a first bicuspid with a Carmichael and a pontic bicuspid used. The united held the three loose teeth very firmly.

The use of united barrel crowns reaching the gum margins is at times useful, but the configuration of exposed roots may render this impossible in some cases.

By the use of pure gold crowns, which may be stiffened occlusally with solder to gain strength, better adaptation at cervical portions may be obtained by hand burnishing after cementation of the piece.

All appliances cemented to the teeth and having a free margin are subject in some degree to a solution of the cement. These cases should be seen frequently in any event for prophylactic purposes, when the condition of the appliance may be noted.

Extraction and bridge-work may be at once resorted to in some of the aggravated cases, though if the appliance be mechanically constructed teeth which may be extracted with the fingers may be firmly held in splints for years. While this is a fact, good judgment may demand the early removal of such teeth before an appliance is constructed.

E. Ewing Roach[1] has suggested that in case of loose incisors drill holes may be made from mesial to distal or the reverse, and a plati-

[1] Dental Cosmos, 1908, p. 65.

num wire, 18 or 20 gauge, be cemented through the several teeth. The cases must, of course, be selected.

If desired the bridge may be made so as to mount the natural teeth after their extraction, by constructing sockets of gold for the recep-

Fig. 691

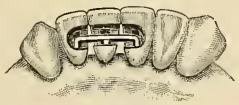

Permanent splint for cases of pyorrhea alveolaris in upper or lower incisors. (Rhein.)

Fig. 692

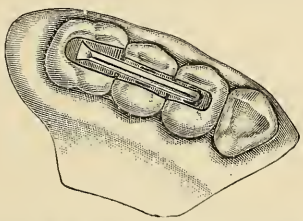

Permanent splint for cases of pyorrhea alveolaris on molars and bicuspids.

Fig. 693

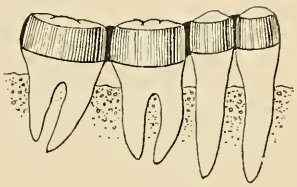

tion of the necks of the teeth somewhat after the manner employed in the Ames method. The sockets are then soldered to each other and to the bridge piers, after which the teeth are attached.

These sockets are to be made deep at first, and it is well to attach the teeth with gutta-percha in order that the row of sockets or a new row may be lowered to fit the gum if desirable. This will require the raising of the teeth to the occlusal level. Occasionally the use of the overarch bar is demanded to prevent the overuse of the teeth acting as piers for bridge-work. The lateral support of teeth by plates is occasionally of use in pyorrhea, but the question requires careful consideration. (See p. 664.) The prevention of mobility in advanced cases may be at times an impossibility. In such cases extraction, and the use of artificial teeth, is probably better judgment than the retention of the teeth until extracted one by one. In all cases the element of overuse must be considered and anything possible done to prevent it. (Read carefully page 661.) Also anything that may induce gingivitis as a riding plate festoon must, if possible, be avoided.

The Medicinal Treatment and Prophylaxis.—Simple cases often heal spontaneously after thorough work and antisepsis. If aseptic a clot drawn after the irrigation of the pocket with hydrogen dioxid is often useful. Some operators depend upon blood flow. In order to control the patient and watch the case, any pocket existing after a week should be washed out with hydrogen dioxid and then filled with balsam of Peru which can be kept ready at hand in a Safety Sub. Q syringe. This substance is a mild antiseptic stimulant of a

viscidity sufficient to fill the pockets even though wet, if the needle is inserted to the bottom. Thereafter it should be used twice a week.

If the case refuse to heal there may be calculus overlooked upon the roots. An acid is used to soften this if not removable by instruments. Head recommends the use in the pockets on each fourth day of ammonium bifluorid[1] as a solvent of calculus and tissue stimulant. It does not dissolve enamel or cementum. The tissues are to be protected against burns from any overflow, which must be removed. It produces no harm within two minutes. It is to be injected with a rubber syringe with a platinum point (Dunn syringe).

Lactic acid full strength (Younger), trichloracetic acid, 25 per cent. strength (Kirk); sulphuric acid, 25 per cent. strength (Truman) are all solvent for tartar, and stimulant germicides if infection continues the ulceration.

As an astringent antiseptic zinc chlorid deliquesced, or sulphocarbolate of zinc in 10 per cent. solution, or zinc iodid in 10 per cent. solution, or copper sulphate, 10 per cent., are all useful.

As an astringent lotion, zinc chlorid, gr. x to each fluidounce of aquæ rosæ, aquæ gaultheriæ, aquæ menthi piperitæ, etc., may be applied by the patient daily on a cotton swab made by rolling cotton on the end of a tooth pick. It may be diluted to an agreeable astringence for a mouth wash (or two-minute bath), or tincture of iodin may be applied every other day, or iodoglycerol (see p. 680) may be painted upon the gums.

Gentle massage of the gums by means of the finger-tips stimulates the tissues and squeezes out secretions. If common table salt be used in conjunction the stimulant antiseptic effect is obtained. Powdered sulphur is recommended by Gordon White instead.

The use of a strong stream of water from a syringe is recommended by Black to wash away the agglutinin collected.

Dr. A. B. Harrower has suggested the following formula for a powder which has in his own and my hands given good results as an astringent antiseptic:

℞—Magnesium carbonate	lb. j
Cream of tartar	lb. iss
Red cinchona bark	℥ij
Calcined alum	℥j
Oil peppermint	f℥v
Oil cinnamon	f℥iij
Oil rose geranium	f℥j

All ingredients to be finely powdered. The oils are to be added to the magnesium before thorough mixing of the powders. The whole is to be sifted through silk.

Saccharin may be added to the above as a sweetening agent. The powder when wet is almost neutral, and should do no harm in its limited use as a therapeutic agent.

[1] "Tartar Solvent," or "Tartasol," is made by neutralizing hydrofluoric acid with ammonium carbonate, filtering, evaporating to half the bulk, adding again an equal bulk of hydrofluoric acid, and again evaporating to one-half bulk (at 90° to 105° F.). (Items of Interest, 1909, p. 175.)

Black has recommended the use of the 1–2–3 mixture, or phenol-camphor, to be put into the pockets every three days, and a few drops to be used on the tooth brush.

℞—Oil of cinnamon . . . . . 1 part
Carbolic acid . . . . . 2 parts
Oil of gaultheria . . . . . 3 parts

℞—Gum camphor,
Crystal carbolic acid . . . . . āā q.s.
Mix in a mortar to an oily fluid.

Barrett injects as an amebacide a one-half of 1 per cent. solution of emetin hydrochlorid in normal saline solution into the tissue at the bottom of a pocket and fills the pocket with the solution, repeating this on several consecutive days (see p. 714).

Regeneration in the pockets should not be disturbed, so that unless the pus flow be active one should wait until sufficient time has been afforded (about a week or ten days) for granulations to form. If pus be then detected the pocket should be again treated thoroughly. Good results are obtained from the use of an astringent antiseptic wash used in forcible spray from an atomizer or introduced by means of a syringe. This should be done daily by the patient. Stagnant fluids in the pockets are washed out and replaced by the antiseptic, thus inhibiting the bacterial growth in the pockets and the mouth.

The teeth should be cleansed after meals to prevent media for infection lodging about the interstices, after which the antiseptic spray will aid in inhibiting bacteria. If the case still refuse to heal Beck's bismuth paste may be used.

℞—Bismuth subnitrate . . . . . 30 parts
White wax . . . . . 5 parts
Paraffin . . . . . 5 parts
Vaselin . . . . . 60 parts
Mix while boiling.

It is injected from a syringe kept for the purpose.

Good results from the application of the *x*-rays and high-frequency currents have been claimed by Parker,[1] Price, Guy, Satterlee, Tousey, and others

Raper claims that the otherwise incurable cases are not benefited.

The local treatment outlined must first be given and the *x*-rays and high-frequency currents used as an adjunct.

Tousey recommends an *x*-ray tube made of lead glass except for a single window of ordinary glass, through which the rays pass in one direction only, and thus both patient and operator are protected from the unintentional action of the rays.

[1] Dental Cosmos, December, 1903.

Applications of a minute or two have beneficial effect. The high-frequency currents are applied by small vacuum tubes or electrodes directly to the gums. They contain and emit violet and ultra-violet rays, which not only stimulate the part through the electricity, but also produce ozone upon the gum surface and carry it in and also produce ozone in the tissue by electrolysis.

The use of vaccines seems indicated in the more serious cases not yielding to local treatment, the predominant bacteria being employed in the autogenous vaccines. In past treatments these vaccines have only aided in resistance to the pyogenic infections, and some report good results from their use. A. H. Merritt[1] claims that after exhaustive trial he has found them of no greater use than local treatment. As yet no one knows the exact cause of pyorrhea, so it can not be said that the treatment has proceeded upon scientific lines.

McGehee[2] claims about 50 per cent. of cases improved markedly through the use of the Van Cott stock vaccines, of which each bulb contains in 1.0 c.c.: Streptococcus, 50,000,000; bacilli coli communis, 100,000,000; pneumococcus, 100,000,000; staphylococcus (combined aureus, albus, and citreus), 500,000,000, killed and in sterile solution.

He claimed his best results were obtained by beginning with one-fourth of the bulb content, 0.25 c.c., injecting at four-day intervals, later increasing to 0.50 c.c., and up to six, seven, or eight injections all told. An effort has been made to utilize the opsonic index in the diagnosis of pyorrhea alveolaris and its treatment by means of vaccines prepared from the variety of germ found to be the probable infection. It may be stated that the effort is to raise the opsonic index, or, in other words, the property of the blood serum which assists or promotes phagocytosis, so that the infection may be killed out. That is, the resistive force of the patient to the particular infection is raised. (See p. 63.)

Good results have been obtained in some cases by extraction and replantation, after root preparation and sterilization of the tooth and alveolus. The alveolus may have to be deepened.

If the interstitial gingivitis underlying the case be of systemic origin—*i. e.*, due to auto-intoxication from any disease, the alimentary canal, the pyorrhea itself, or to drug action—these should have attention. The systemic disease should, if possible, be cured by correct medical attention. Pyorrhea patients are of the hyperacid type (Michaels), and treatment should be directed toward elimina-

[1] Remarks before Pennsylvania State Dental Society, 1914. See Dental Cosmos for 1914.

[2] Dental Cosmos, September, 1912.

tion of waste products and the reduction of hyperacidity by the use of alkaline remedies. The bowels should be kept active and the skin pores open. Brisk exercise in the open air, if not specifically contra-indicated by organic disease, is valuable in both directions. Warm baths followed by cold douches and vigorous rubbing stimulate the skin. Turkish baths followed by massage directed to stimulation of the eliminating organs are valuable unless contra-indicated. Free drinking of pure water is necessary to the successful elimination of the waste products of the body. The water entering the blood increases the blood pressure and flushes the tissues and the kidneys, dissolving waste products. Water should be freely taken between or before meals in order that digestion be not interfered with, and if medicated with salts of lithium the alkalinizing effect and solvent action of lithium upon urates are obtained. Patients exhibiting an aversion to water drinking are more apt to take it when medicated than as a physiological necessity. (See also pp. 105 and 689.)

The prophylaxis of pyorrhea alveolaris is all important, especially in the cases in which chronic disease or malnutrition may not be readily overcome owing to confirmed habit of life or advanced stage of disease. The local conditions existing even after a cure of pyorrhea are such as to invite reinfection, and the establishment of microbic plaques, which frequent cleansing of the teeth will remove. The system of monthly or, if necessary, more frequent prophylaxis advocated by D. D. Smith should be practised. Its good results are particularly manifest in this class of cases. Also the use of the prophylactic stick by the patient twice a week and the careful and proper use of floss is very beneficial. The patient performs these manipulations with difficulty, and is apt to backslide. (See p. 442.)

Recurrence of the condition is probable if the oral prophylaxis or systemic treatment be neglected. The simpler cases yield quite readily; the advanced ones, in which much of the alveolar process is lost, and especially when the gums are flabby and admit food to the pockets, tax the patience of operator and patient alike, and are apt to end, sooner or later, in loss of the teeth affected.

This fact, however, should not prevent the retention of these teeth by every means at command during the period for which they may be made useful. If, however, any tooth prove an incurable source of pus formation, or from the first be likely so to do, it should be removed, otherwise the remaining teeth, and possibly the patient's blood, are continuously infected. The mouth will often be markedly benefited at the start if a few bad teeth are removed, and bridge work be inserted, to supply their places, thus removing the individual strain and splinting the remaining teeth.

SYSTEMIC EFFECTS OF PYORRHEA ALVEOLARIS.

It has been abundantly shown by Hunter and others that the pus of pyorrhea and other intense oral sepsis is a source of systemic infection, producing effects ranging from gastritis to actual septic infection. The importance of this fact is not to be lost sight of, and patients are to be informed of the dangers of constant pus formation, as well as of the presence of other forms of sepsis about the mouth and teeth.

R. D. Watkins, M.D., has examined the blood of pyorrhetic patients, and has found a mild condition of septic blood similar to but less than found in puerperal fever and advanced carcinoma and in other infective conditions.[1]

Goadby[2] reports the cure of a case of profound muscular weakness, mental depression, and insomnia after unavailing general medical treatment for neurasthenia, as following the extraction of teeth affected by pyorrhea. Vanel[3] cites a case of chronic septicemia with symptoms of pallor and asthenia, and ecchymotic patches (see p. 119) on the legs, associated with pus formation about the roots of teeth. The symptoms disappeared in a few weeks after the oral treatment.

Hunter and Leith[4] have described cases of subacute and chronic catarrh of the stomach and phlegmonous gastritis due to the ordinary pyogenic cocci, such as are found in the mouth, and which the gastric juice of the stomach of the particular individual at least was not competent to kill. Considering the fact that an oral subacute catarrhal condition is established in pyorrhea, the local transfer of the infection is not surprising. Park[5] believes many cases of appendicitis to be due to oral infection.

Kirk adds to this list pernicious anemia, bronchopneumonia, malignant endocarditis, pyemic lymphadenitis, etc., as possibilities of secondary infection or extension by natural contiguous channels.

Hartzell[6] claims that three deaths from septic endocarditis were traceable to violent pyorrhea.

Skinner instances a case of intestinal infection, accompanied by nervousness and weakness, with confinement to bed for three months, as rapidly and steadily improving after the treatment of a pyorrhea with profuse suppuration. Rheumatism and even arthritis defor-

[1] Items of Interest, 1904. [2] International Dental Journal, July, 1902.
[3] Dental Cosmos, 1908, p. 192.
[4] Transactions Odontological Society of Great Britain, International Dental Journal, 1899.
[5] Surgery by American Authors. [6] Dental Cosmos, 1908, p. 240.

mans have been claimed as associated with pyorrhea, the infection being absorbed by the lymphatics associated with the teeth. The bacteriology of this relation is now being investigated. The organism most often offending is the Streptococcus viridans, which may be isolated from the blood of the patients suffering from a general infection due to a local focus of infection, whether this be in the appendix, tonsil, or a dental abscess or pyorrhea pocket. It grows upon blood agar with a green color in its colonies. If the same bacterins can be isolated from the blood and the focus and the condition clear up upon removal of the latter, the relation is absolute. (See p. 631 and Index under Bacteria.)

PYORRHEA ALVEOLARIS NOT DEPENDENT UPON CALCULUS FORMATION.

A form of pyorrhea occurs in which calculus does not seem to be the exciting or contributory cause. It seems rather to be due to infection localized in soft bacterial collections in localities protected from ordinary friction.

Sometimes no perceptible calculus can be found upon the roots, but a soft gummy collection may be noted. The forms of the necks of the teeth readily permit bacterial collections and the infection causes a bright red marginal gingivitis. A pocket forms and the infection becomes deep. The gum tissue is sometimes destroyed between two teeth. There is often evidence of infection of other gum margins with the bright red color. In another form the gum margins are separated from the teeth. Pockets are formed which collect food. There is not much pus apparent, but there is a pig-stye odor of putrefaction. The marginal bone is lost. In another form a deep pocket forms and necrotic bone may be found.

The advance of the disease is sometimes rapid and sometimes not. Sometimes a lateral abscess is associated with it. The diagnosis is that of pyorrhea alveolaris of aggravated type, and probably special infection, and its progress, symptoms, and treatment are practically the same as in the first class.

The advance of the case may be very slow and limited to the teeth originally involved. The following is an example:

Miss H., aged twenty-five years, presented with well-established pockets, extending one-half inch toward the apex, upon the mesial aspect of the root of the right upper central incisor and distal and distobuccal aspect of the right upper lateral incisor. There was a history of traumatism due to violent and persistent wedging with rubber at about the age of sixteen. The case was then of several

years' standing, and the two teeth elongated about one-eighth inch beyond their fellows (Fig. 694). There was no subgingival calculus. The pockets were treated with some benefit, and the teeth shortened for the cosmetic effect, but the patient left the city suddenly before

FIG. 694

Pyorrhea alveolaris without calculus. Pockets as shown. Teeth were one-sixteenth inch longer, but have been shortened. Practically no calculus and but slight flow of thick, creamy pus. Gum prominent over affected teeth. Condition in 1904.

recovery, and was not seen again for three years. At this second visit it was found that the pockets were nearly the same as at first, and no other teeth had become involved. Nor had the teeth further elongated.

During the four years from 1904 to 1908, elongation and grinding reduced nearly all the crown of the lateral, which had one-quarter inch of its root cervix exposed. Coincidently with the exfoliation the pockets disappeared as though by a drawing up of the bottom. The two teeth were finally lost. The consideration of this form of pyorrhea should be that it is specially virulent.

CHAPTER XXV.

PERICEMENTAL ABSCESS.

In comparatively rare cases there begins in the lateral aspect of a pericementum a swelling which finally discharges its contents either at the gum margin or directly through the gum tissue.

The pulp of the tooth may be perfectly vital and the attachment at the gum margin at first at least practically unbroken. A deposit of calculus may or may not be formed in the area, and the discharge may consist of a glairy fluid or of purulent matter. Cases of this disease have been noted and described by Darby (1874), W. E. Walker (1895), Talbot[1] (1896), D. D. Smith (1897), and Kirk (1898). Black claims that he has never found such a condition without local injury.

Forms of Pericemental Abscess.—There are four forms of pericemental abscess as described and seen:

1. An ordinary pyorrhea begins at the gum margin and extends into the alveolus at the expense of the pericementum. The bacteria find their way to the bottom of the pocket or into the tissue at its side. They develop in the said location and the pus burrows into the lateral gingival tissue, causes swelling and pointing, and discharges at the lateral gingival aspect or analogous situation. (See p. 721.) This is not always opposite the gum orifice of the pocket. (See Figs. 660 and 661.) In one case a fistula was found at the buccal aspect of the gum opposite a point midway between the buccal roots of an upper molar at the middle third of the roots. The pulp was exposed and vital, having been drilled to on the supposition of its death. A gum pocket was found at the distolingual aspect of the lingual root and the pus had burrowed into the bifurcation between the lingual and distobuccal root, and discharged as stated, remaining as a chronic abscess. There is a simple acute condition of this kind of origin seen occasionally. A swelling of the gum margin occurs and pointing occurs, lancing usually demonstrates pus present and effects a cure. The infection has entered the gingival space, travelled into the tissue and developed what may be termed a true marginal gingival abscess.

[1] International Dental Journal, 1896.

2. There is a pyorrhetic condition at the gum margin; later an abscess develops on the lateral aspect at a point a little higher up toward the apex, usually at the gingival third. There may be no detectable connection between the two, but probably a deeper infection has occurred, the avenue being along the connective tissue spaces, the bloodvessels or the glands of Black. In one case of this sort the fistula was formed over the highest point of the middle third of the root of a cuspid retained for plate work. The gum margin was flabby, but not markedly pyorrhetic. There was firm tissue at the bottom of the space on all sides. The pulp was vital. Examination showed a small calculus on the root surface below the fistula. The abscess tract was limited. Sometimes it is of greater extent. Fig. 662 will illustrate how this occurs.

3. An acute swelling occurs over a root, the gum margin is unbroken, a discharge of glairy or purulent material occurs, and a calculus or none may be found. In this connection Fig. 297 shows that a calculus may exist as a primary cause of the pericemental abscess. As calculi of gouty (sodium bi-urate) or other origin occur in other parts of the body and in the pulp, there is no valid reason why one should not occur in the pericementum or upon the root under it if some sluggish condition of the circulation renders the tissues into a degenerative state favoring it. (See p. 103.) The pericementum contains white fibrous tissue which is particularly prone to such deposits.

Whether such a deposit occurred primarily in the case of the cuspid described under Class 2 and infection followed, or whether the infection and pus came first and the calculus followed is not quite clear. In two distinct cases, with healthy gum margins, the editor has seen an acute circumscribed swelling which was not yet open as a fistula and which was perforated by an explorer, disclosing a loss of alveolar bone and a small cavity filled with clear liquid in the tissues. The explorer reached the root without obstruction, and no calculus was present. After discharge and curettement the cavities healed. These two swellings looked like blisters or simple cystic swellings near the gum margin. If they had discharged at the gum margin they might have produced a gum pocket simulating pyorrhea.

4. In some cases of apical abscess the infection may travel along the pericementum and develop a secondary abscess at some point in the pericementum (as, for example, the bifurcation), as a pericemental abscess. This form corresponds to the cases of Class 2, but is apt to be more acute. It is also quite rare. The pulp is, of course, dead, at least partially in such a case.

The subject of pericemental abscess is in some confusion because writers have described all these varying phases as pericemental abscess, which indeed they are, yet they require differentiation into:

1. Cases occurring as a sequel to a distinct pyorrhea alveolaris, Class 1.

2. Cases associated with marginal pyorrhea cases but distant to them, in all probability having a source of infection in the pyorrhea pockets, Class 2.

3. Cases beginning on their own account; the relation of the calculus if present as a cause or result being in doubt, Class 3 (Figs. 658 and 659).

4. Cases beginning in an apical abscess infection, travelling *via* the pericementum to another portion of the pericementum, Class 4.

Kirk's studies show that in a few cases of pericemental abscess the pneumococcus may be found in pure culture. This suggests a Class 2 case, as they are found complicated by other pyogenic bacteria in the ordinary pyorrheas. A metastatic blood infection might exist.

Garrod found crystals of urates in the serum of blisters in gouty patients. In gouty patients they are found in joints, and they constitute the common tophus. (See p. 103.) "Urates of sodium are also discharged through the skin in gouty abscesses, either in liquid or solid form, and with or without pus." (Musser.) Musser[1] states that a number of these abscesses may discharge without impairment of the general health or even with benefit to the system.

Calculi scraped from the roots in pericemental abscesses exhibit in a varying degree a response to the murexid test, the test for urates. (Peirce.) The reaction may be very faint in some cases, being overshadowed by the calcium phosphate which makes up the bulk of these masses; in others it is pronounced—*i. e.*, urates made up a portion of the deposits.

Black[2] by test found urates in nearly all concretions, salivary and serumal, about the teeth. While he claimed that this proved that urates have no causal relation to pyorrhea, the findings seem rather to point to frequent presence of urates in the salivary and serumal excretions, which may really be a cause of irritation even when no obvious symptoms of gout are present.

Miller's demonstration of a calculus upon an unerupted tooth is to be recalled. It seems fairly reasonable, therefore, to suppose that in rare cases such a calculus may be the result of either gout or a local degeneration and act as an exciting cause. (See p. 312.)

[1] Medical Diagnosis.

[2] Dental Review, 1894.

Morbid Anatomy.—Aside from the state of the teeth which show evidences of a tendency to secondary dentin and nodule formation, it has been noted that the abscess is intrapericemental, not subpericemental. Figs. 697 and 698 show the inflammatory swelling of the pericementum; the central abscess cavity, and the loss by resorption of the alveolar process may easily be calculated. The original chronic nature of the local irritation in this case is evidenced by the presence of hypercementosis.

Fig. 695

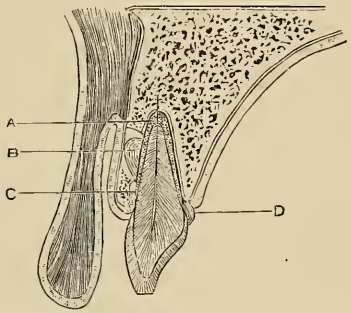

A and *C*, vital pericementum; *B*, gouty calculus; *D*, a subgingival calculus.

Fig. 696

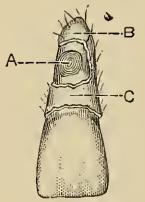

A, calculus in area of necrosis; *B*, and *C*, vital pericementum.

Fig. 697

Two views of an intrapericemental abscess. Pulp vital. (Kirk.)

Symptoms.—These have been largely foreshadowed in the discussion of the pathology. Upon some vital tooth there appears an uneasiness, at first not very painful, followed later by an inflamma-

Fig. 698

Transverse section through buccal roots and pericemental abscess shown in Fig. 697, showing intrapericemental abscess cavity with fistulous outlet and nearby areas of nodular hypercementosis. (Kirk.)

Fig. 699



Pericemental abscess. (Talbot.) (Photograph by Latham.)

tory swelling which may produce acute pain and then discharge a glairy fluid or purulent matter. There is an absence of the masked phlegmonous inflammatory involvement of contiguous tissues common in cases of acute apical abscess. The fistula may persist after the discharge and the case may first be seen in this condition. If it discharges at the gum margin it establishes an ordinary pyorrhea.

D. D. Smith calls attention to the absence of marked pain upon tapping and the production of a feeling of apprehension upon the part of the patient during the stages preceding the formation of the fistula. In other cases the shifting of the tooth from its position is the first noticeable symptom, followed later by the pain, and later still by the discovery of a pocket alongside the tooth.

Diagnosis.—In making the diagnosis the symptoms described are to be borne in mind, but the disease may be confounded with several diseases having somewhat similar symptoms. An acute apical abscess due to gangrenous pulp may be differentiated by obtaining evidences of pulp death, previous root-canal treatment, etc. There is also much greater pain upon percussion than in pericemental abscess. If slowly and painlessly formed it may be still more confusing, but the pulp is dead.

FIG. 700

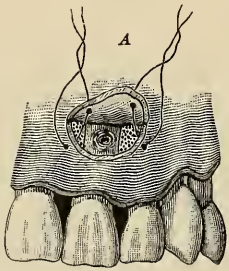

A, calculus.

If the apical abscess be in the third stage it may be differentiated, if any doubt exist, by incision and subsequent exploration.

An acute lateral abscess due to a root perforation is more difficult of differential diagnosis, but after incision evidences of perforation may be sought externally, or the root canal may be opened. In these acute conditions the *x*-rays may render valuable aid. The pulp being found alive by any reliable test is evidence that the case is either one of pericemental abscess or of acute traumatic pericementitis. In a few cases of partial gangrene of the pulp the pulp may test as vital, yet really the symptoms be due to apical abscess.

Acute traumatic pericementitis usually has a history of traumatism and presents more pain upon tapping. Any abscess is usually the result of infection due to rupture of the pericementum. The other forms of pericemental abscess must be differentiated (see p. 745).

Treatment.—If the pericemental abscess discharge by way of the gum margin, infection from the oral cavity occurs and the pocket originally formed becomes deeper. The case simulates then a pyorrhea alveolaris beginning at the gum margin. The treatment is then conducted accordingly. If the swelling occur upon the gum, at a point more or less midway upon the root, it should be opened under antiseptic precautions. An injection of cocain solution should be made, if necessary, and a semicircular flap raised. The diseased area should be explored for calculus and, whether found or not, the necrotic tissue should be curetted away. Next, the pocket should be syringed out with an antiseptic and filled with balsam of Peru or a clot induced. The flap is next laid into place. The mouth should be kept in an aseptic condition during the healing of the parts. It is well to have the patient keep the sinus open with a needle to ensure healing from the bottom rather than ballooning by pus, which may cause recurrences. The systemic considerations are the same as those described on pp. 714 and 740.

CHAPTER XXVI.

REFLEX NEUROSES.

Reflex neuroses consist of (1) pain produced in parts distant to the point at which irritation is produced, while pain may or may not be absent at that point (sensory reflexes), or (2) they may consist of muscular excitation in parts distant to the cause (motor reflexes), or (3) they may consist of nutritive disturbances in the distant part, probably a form of motor reflex in which the trophic nerves or the vasomotor nerves are reflexly irritated so as to produce trophic disturbances.

The source of irritation may be in the dentinal fibril, in the pulp, or in the pericementum, producing sensory or motor or trophic reflexes in other parts or the source of irritation may be in some other location than about the teeth and produce phenomena about the face or teeth.

Whether of dental origin or not a sensory reflex is called neuralgia, though the cause of a neuralgia may possibly be a direct irritation of a nerve trunk or terminal.

While all reflex dental disturbances are, as a rule, located in some part of the great nerve branch supplying the source of irritation, the irritation may be reflected to distant parts; first, of the same cranial nerve, and secondly, to other nerves. That is, pain having its origin in one of the upper teeth is most likely to be referred to a point or points in the distribution of the superior maxillary division of the fifth nerve. Disturbances in or about the lower teeth are usually referred to the distribution of the inferior maxillary division. In affections of either upper or lower teeth the pain may be referred to the ophthalmic division. In all of these cases, but most notably in connection with disturbances of the upper teeth, the usual symptom of trifacial neuralgia—tenderness of the supra-orbital and infra-orbital nerves at their points of emergence upon the face, the supra-orbital and infra-orbital foramina—is commonly present.

Cases are extremely rare where the reflex pain is referred to the opposite side; so unusual is this occurrence that its mention warrants suspicion that other sources of irritation exist upon the side referred to.

The extent of acuteness of reflex pain bears no direct relation to the apparent extent of the source of irritation.

As might be surmised from the function of the dental pulp, painful reflex dental disorders are more common in connection with diseases of the pulp than with those of the pericementum.

REFLEX NEURALGIA FROM EXPOSED DENTIN.

The exposure of the dentin to external sources of irritation is followed by reactions governed, first, by the degree of sensitivity inherent in the protoplasm of the tissue; and secondly, by the degree of hypersensitivity induced in it. Reflex disturbance due to these irritations is more common in the class of persons called "neuralgics," *i. e.*, in those whose nervous irritability is exalted, a condition which may remain even in nervous exhaustion (see p. 110). Like direct pulp pains, unless actual pressure be exerted upon the affected tissue, there is no localized pain. In the absence of deliberate irritation, the pain may be referred to any portion of the peripheral distribution of the fifth nerve upon the face, but if an acid liquid, such as lemon juice or vinegar, or sugars be taken into the mouth, pain is excited, which is referred indefinitely to the teeth of one side, frequently of one jaw. Reflex pains due to this cause often appear when there is but little loss of dentin.

When carious cavities have proceeded to any depth evidences of direct pulp disturbance are obtained through the increased response to thermal changes.

Reflex pains from exposed dentin appear most commonly in connection with exposures at the neck of the tooth and upon abraded areas. Obstinate and persistent neuralgia, positively referred to another nerve branch, may apparently owe its origin to so slight a cause as exposure at the neck of a tooth of a line of dentin (Fig. 702). The proof of the connection between the two is made clear by a disappearance of the neuralgia after the exposed dentin has been subjected to the action of powerful caustics (especially silver nitrate), destroying the dentinal filaments to some depth. The connection between the two may be revealed only by accident; the contact of a toothpick, a dental instrument, or the finger-nail may induce a paroxysm of pain. In one case, after removal of calculus, the necks of the lower incisors became a cause of severe neuralgia, compelling the use of silver nitrate.

While in some cases the dental origin of reflex pain may be made clear by the induction of a painful response in the area of reflection, by irritating a tooth pulp, this reaction is not constant. The causal

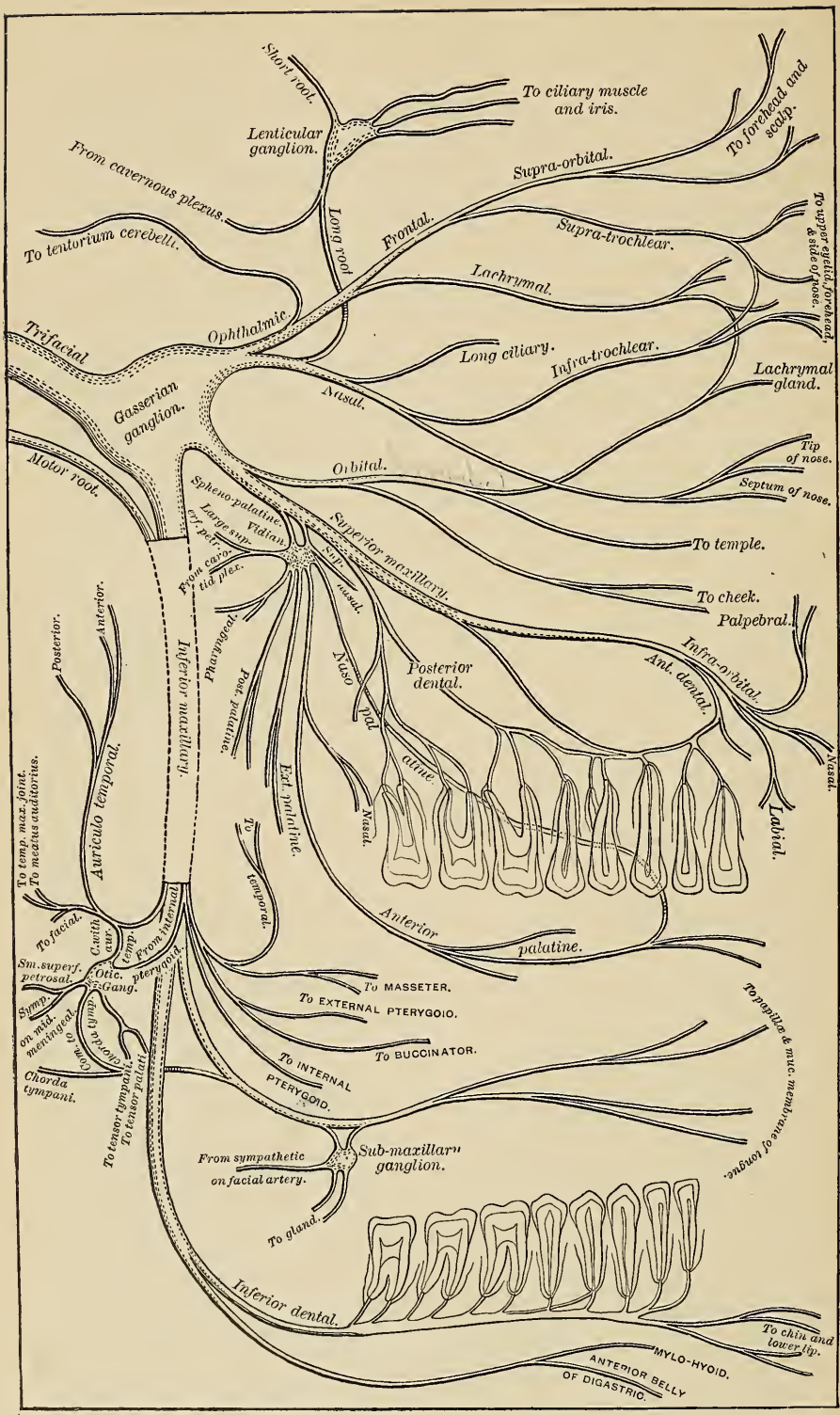

FIG. 701.—Plan of the fifth cranial nerve, showing the relationships of the dental nerves. (After Flowers.)

relation is only certain when the cure of localized dental disease is followed by a disappearance of the neuralgia without further treatment. This proof should be exacted in all cases.

Fig. 702

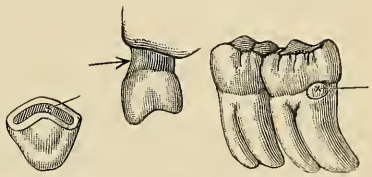

Sites of dentin exposure frequently associated with reflex pains.

The most common sources of neuralgic attacks about the face are diseases of the eyes and teeth. In general terms, diseases of the eye give rise to reflex pains referred to the distribution of the first branch of the fifth nerve; diseases of the teeth usually cause reflex pains in either the superior or inferior maxillary divisions, according as the upper or lower teeth are affected. In all painful affections of these nerves attention should at once be directed to the organs named.

REFLEX NEURALGIAS FROM PULP DISEASES.

The disturbances require classification according to the distance between their source and their manifestations.

In the Fifth Pair of Nerves.—Pain referred to a different spot or area than its origin is a characteristic of all pulp diseases. The extent of its reflection depends, first, upon the patient, as noted in connection with the reflex pains from exposed dentin; and secondly, upon the variety of pulp disease. In neuralgic patients any variety of pulp disease may cause comparatively distant pains. But, as Black has pointed out,[1] the general rule is, that the more chronic and profound degenerative diseases of the pulp are much more liable to give rise to distant reflex pains than are acute pulp diseases.

The pains of acute hyperemia and of acute inflammation of the pulp are usually referred to the region of the tooth affected, or to a corresponding nerve trunk. In conditions of venous hyperemia, nodular calcifications, chronic inflammation, and, later, pulp degenerations, the pains may be of such character that their dental origin is only determined after persistent search. Particularly is this true of the growth of pulp nodules. The source of the reflex pains is all the more obscure from the fact that in these chronic degenerations direct dental symptoms may be entirely absent, and are only elicited upon the most searching examination and exhaustive tests. In some cases of pulpitis even removal of the pulp by cocain has been fol-

[1] American System of Dentistry, vol. i.

lowed by a neuralgia due to irritation of the nerve trunk in the pulp stump at the apex, so proved by cure through strong sedatives applied *via* the canal. In one case the neuritis lasted several days.

There is no constancy in the location of the pain due to any of these causes; but tenderness of the eyeball upon pressure; iritis or conjunctivitis; persistent pain in the temporal and anterior auricular regions, particularly in connection with pulp diseases of the lower posterior teeth; in the ear itself, a common site of the reflex pain excited by chronic pulp inflammation and suppuration of that organ; behind the ear, back of the lower border of the mastoid processes, tender spots may develop; tenderness to pressure may appear at the supra-orbital and infra-orbital or mental foramen, and about the chin. In the same class of diseases the pains may frequently radiate as far as the shoulder. Many of these cases receive attention from the general practitioner, and the painful attacks recurring at irregular intervals are relieved by analgesic remedies—phenacetin, acetanilid, exalgin, etc.—and no attention paid to a probable dental source of the disorder. It should be a routine practice to examine the teeth in cases presenting pains of the type and in the situations described. Acute diseases of the pulp, including suppuration, notably abscess of the pulp, usually have attention directed to the teeth through pain induced by thermal changes, so that their diagnosis is quickly made. Not so, however, with the chronic degenerative changes, except possibly of pulp nodules; for if the pulp is in the late stages of degeneration, it may require repeated applications of cold and heat to elicit a response from teeth which do not respond by tenderness upon percussion.

Fig. 703

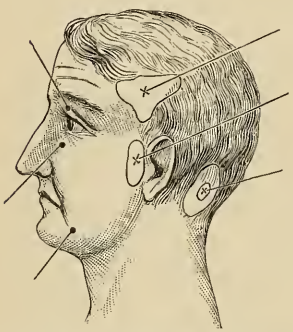

Spots of tenderness in reflex neuralgias of dental origin.

Failing to obtain evidence of pulp disorders, examination should be made for exposed and hypersensitive dentin. Then, examination of the pericemental reaction of each tooth should be made, and for any evidences about the teeth pointing to pericemental disturbance. (See later.)

Lauder Brunton[1] records that, in his own case, temporal neuralgia accompanied by tender eyeball was found due to exposed dentin upon the posterior cervical surface of a lower third molar (see Fig. 702). The same writer[2] announces that "so frequently are headaches

[1] St. Bartholomew's Hosp. Rep., vol. xix. Reprinted in his Disorders of Digestion.
[2] Ibid.

dependent upon decayed teeth, that in all cases of headache the first thing I do is to carefully examine the teeth;" as should everyone else. Upson cites by radiograph a case of severe headaches of years standing, cured by extraction of an impacted cuspid.[1] Brunton explains the painful reaction upon the accepted hypothesis of the pathology of megrim, that it is due to spasmodic contraction of the peripheral end of an artery, with dilatation of the proximal portion. "Irritation in the tooth is reflected to the cervical sympathetic ganglia and causes spasmodic contraction of the arteries through irregular stimulation of the vasomotor nerves."

An abnormal tooth located in the anterior floor of the nasal cavity was the cause of headache for years, so proved by cessation of headache after its surgical removal.

REFLEX PAINS FROM DISEASES OF THE PERICEMENTUM.

As a general rule, pericemental pains are located at the affected tooth; but in some of the disorders the teeth may not be tender upon percussion, and yet excite reflex pains in other parts, the proof of the connection being determined by a disappearance of the pain upon extraction of the tooth. The roots in such cases usually present either an hypertrophy of cementum or show that resorption of a portion—it may be a major portion—of the root has occurred.

In cases of hypercementosis it is assumed that the source of the irritation is pressure upon the nerves of the pericementum by the hypertrophic growth. Very widespread disorders may arise from this source.

Flagg[2] records many varieties of trifacial neuralgia; pains in remote parts of the body; grave functional disorders of the eye and ear; and motor disturbances—chorea, epilepsy, and paralysis—having a direct demonstrable connection with hypercementosis. Insanity has also been produced.

He mentions violent attacks of trifacial neuralgia as the most common reflex disturbance from this source; and next, long-continued pains in the ear or eye of the affected side. The existence of acute disease of these organs is usually diagnosticated by the general practitioner. He states that aural and ocular disturbances, both functional and painful, are of gradually increasing severity.

In examining for a dental source of such pains, exposed dentin, pulp diseases, and inflammatory affections of the pericementum should be first excluded. In examinations by percussion a different

[1] Raper, Items of Interest, August, 1912, p. 575.
[2] Dental Cosmos, 1878.

response may be obtained from some one tooth than from the others. Hypercementosis of a particular tooth may be suspected by finding the gum line slightly receded and the tooth attachment unusually firm; if, in addition, vague, heavy dental pains have persisted at intervals over a long period, the diagnosis is probable. It is only certain when tapping upon the tooth brings on a paroxysm of neuralgia, and a skiagraph actually exhibits the hypertrophic growth. The remedy is extraction. Any root fragment left unextracted may perpetuate the reflex disorder. The writer has recently treated a case of neuralgia due to a lingual root of a left upper first bicuspid which was retained in the gum after extraction. The gum had healed perfectly over it. It was only discovered by the use of the *x*-rays.

Painful affections referred to the neighboring region of the affected tooth, or diffused through the distribution of the corresponding nerve trunk, or to the eye or ear, may accompany the process of resorption of the roots of permanent teeth. Gillman[1] records a case where facial paralysis disappeared upon extraction of a tooth which had long been the seat of disturbance and which, upon extraction, revealed resorption of its root. In these obscure cases a skiagraph, if taken at once, will be a great aid in the exclusion or diagnosis of pericemental and root abnormalities.

All of the acute or chronic, septic or non-septic, inflammations of the pericementum may give rise to reflex pains. The most common causes of the reflex pains are found in that stage of pericemental irritation which antedates acute septic apical pericementitis. Unless an exacerbation of the reflex disorder, or symptoms referable to that region, be induced by pressure or percussion on the tooth, a causal relationship is only made out by either relieving an existing dental disorder (for example, finding and curing an incipient apical abscess due to moist gangrene), an *x*-ray skiagraph, or extracting the teeth.

Cases of ovarian and uterine neuralgia and sciatica and cases of obstinate pains in the knee, toes, and fingers have been traced to dental irritation of some one of the varieties named, the proof of association being disappearance of the pain with loss of the tooth, though this is now not always necessary for a cure.

IMPACTED TEETH AS A CAUSE OF NEURALGIA.

Neuralgia of varying degrees of severity is a common accompaniment of impacted teeth. It is most frequently noted in connection with eruption of the lower third molars, not only because this tooth

[1] Boston Medical and Surgical Journal, 1867.

is the one most frequently impacted, but because of the anatomical relations of its roots with the inferior dental nerve.

In the milder forms of impaction, those in which eruption, though delayed, is subsequently completed, the pains are commonly localized and associated with but occasional attacks of rigidity of the masseter muscles. If, however, the crown present horizontally or nearly so, and its progress is arrested by impaction against the posterior wall of the lower molar, or if its progress be arrested by permanent imprisonment of the advancing crown between the posterior surface of the second molar and the base of the coronoid process, not only may intense local pains be induced, but severe reflex disturbances of both a sensory and motor character may occur. In some of these cases root formation is completed, although the crown of the tooth does not advance, in which case compression of the inferior dental canal and its contents may occur and cause grave reflex disturbances. The local irritation about the root, due to root growth, may excite continued constructive action by the pericementum, and the hypertrophic growth in its turn may be the source of reflex neuralgias.

Complete imprisonment of the entire tooth has been found to be the exciting cause of facial neuralgias, for the cure of which extensive surgical operations have been performed.

Impacted cuspids and other teeth may excite no other symptoms than reflex neuralgia. The possible connection between an impacted tooth and neuralgia is made out after excluding other dental causes, when it may be observed that one or more of the permanent teeth are absent from the dental arch, at dates long after their normal time of eruption.

A condition equivalent to partial impaction, in which dental irritation may be the source of reflex neuralgia, is seen when the teeth are crowded into arches too small for their accommodation. During the period of eruption severe maxillary pains may recur at intervals. The diagnosis is by means of the *x*-rays. The production of insanity as a reflex condition has been discussed on pp. 294 and 762.

PHANTOM ODONTALGIA.

This is a form of neuralgia in which symptoms similar to toothache appear in the edentulous jaws or in locations from which teeth have been extracted. The name was applied by J. Foster Flagg. It seems to be due to the compression of nerve-endings by dense bone. It may, of course, be a reflex neurosis from some other focus of pulp or pericemental or nerve trunk irritation.

Any history obtainable of a previous local inflammation should be obtained, and if the pain is localized in any spot the bony tissue may be broken up by operation with a view to removal of such a cicatricial inclusion of nerve terminals. At least in troublesome cases such a simple operation is admissible. Cryer reports successful operations for removal of "bone whorls," the cause of neuralgia (see Fig. 704).

Fig. 704

The arrow points to a dark, three-sided shadow—a bone "whorl." The *X* on the shadow is caused by a scratch on the negative. (Radiograph by Pancoast. Courtesy of H. R. Raper.)

PARALYSIS OF THE SENSORY TRACTS.

The operation of extraction and occasionally disease of the pulp and pericementum have produced a temporary paralysis of a branch

of the fifth pair and loss of sensation in the lip or cheek may result. So far as observed the cases are of not more than a few months' duration and may be ameliorated by massage, either passive or vibratory or by faradization.

MOTOR DISTURBANCES FROM DENTAL DISEASES.

Motor disturbances due to dental irritation may occur as recurrent or persistent contraction or paralysis of muscles, together with more or less chorea; in rare instances epilepsy and hystero-epilepsy. Twitching of muscles of the affected side of the face, ranging from slight affection of the occipitofrontalis or orbicularis palpebrarum to recurring spasm of the elevators and depressors of the lower lip, are far from uncommon phenomena attendant upon pulp and pericemental diseases. In one case mentioned by Guilford[1] a pulp nodule was the cause of tic douloureux (painful muscluar contractions) of two years' standing. Varney Barnes cites a case of "blinking of the eyes," caused by an impacted tooth.[2] A case of recurrent epileptic attacks was proven due to a tooth brush bristle forced into the gum.[3] (See also p. 464.)

Contraction of the masseter muscle is a common accompaniment of retarded eruption of the lower third molar, which may be intensified until the condition is fitly termed trismus, in some cases of partial impaction of the teeth. Partial trismus has been found due to a general overcrowding of the dental arch.[4] Records of cases of torticollis, due to dental diseases, are also given by Brubaker.

Cases of facial paralysis, and cases of paralysis of one arm, of paraplegia and hemiplegia, and even of general paralysis, have been noted as disappearing after the extraction of diseased teeth. It is noteworthy that in these cases, as well as in several cases of tetanus recorded, the probability of an infection entered into the pathogenesis of the nervous diseases.

Stellwagen[5] records a case where symptoms of partial hemiplegia followed upon the operation of capping the pulps of two molar teeth; the symptoms disappeared promptly upon extraction of these teeth. A case of facial paralysis followed extraction of seven roots upon one side. It was successfully treated by eight applications of a weak galvanic current.[6] Facial paralysis has also followed the eruption of teeth, as of a second molar. Infantile paralysis has also been caused by dentition (see p. 203).

[1] Private communication. [2] Raper, Items of Interest, August, 1912, p. 575.
[3] Dental Cosmos, 1910, p. 594.
[4] Brubaker, American System of Dentistry.
Private communication. [6] Griefswald: Cosmos, 1906, p. 356.

Cases of insanity arising from dental diseases have been recorded; they were both maniacal and melancholic. In several of them a restoration to a normal mental state followed promptly upon removal of the offending teeth. In some of these cases a preëxisting maxillary neuralgia directed attention to the teeth as possible sources of the nervous diseases.

Dr. E. Ballard Lodge[1] reports a case from the practices of Drs. Upson and Stephan in which a lady had suffered from acute melancholia and insomnia. A skiagraph revealed an impacted upper third molar pressing against the distal side of the second molar. Extraction effected a cure. Upson[2] reports a number of like cases, as well as some due to pulp and pericemental disease. The local conditions were painless. (See p. 294.)

Cases of deafness have been recorded due to diseases of both pulp and pericementum, notably to hypercementosis. Deafness which has persisted for a long period has been markedly lessened by the extraction of teeth the seat of disease. Cases of suppurative otitis media have been regarded as having pathological association with septic diseases about the teeth, from the fact that the aural trouble subsided immediately after extraction of the diseased teeth.

Sensory disturbances of the eye, associated with dental diseases, have been alluded to; in addition to these, grave structural and functional diseases of the eye, traceable to dental causes, have been recorded, such as motor and trophic disorders.[3] Among the latter may be mentioned corneal inflammation and ulceration and phlyctenular conjunctivitis. These are probably due in part to reflex trophic disturbances.

Irregular paralyses of the third, fourth, and sixth nerves of the affected side have been noted.

Amblyopia and functional blindness without retinal conditions to account for it have been found to arise from notably advanced degenerative changes in the dental pulp, sight returning to the eye after loss of a diseased tooth. DeWitt[4] records a most instructive case where temporary blindness was associated with septic apical pericementitis, disappearing after evacuation of the abscess and reappearing when secondary inflammatory action arose in the pericementum. The ocular affection disappeared permanently and almost entirely with the loss of the tooth. The history of this case illustrates the important causal relationship of reflex disturbances

[1] Dental Summary, 1908. [2] Dental Cosmos, 1910, p. 526.

[3] See Brubaker, American System of Dentistry, vol. iii, for very full and detailed discussion of these subjects.

[4] Quoted by Brunton, Disorders of Digestion.

with late pulp degenerations; for the blindness arose two months after some teeth were filled, and existed for twelve years before the septic apical pericementitis appeared.

Trophic Disturbances following Dental Diseases.—Two cases of localized alopecia (loss of hair) have been reported,[1] obstinate during the dental disease and cured by the cure of a pulpitis in one case and extraction of a root for suppurative pericementitis in the other. Such cases show a vasomotor disturbance in the distant part.

DENTAL PAIN ARISING FROM OTHER THAN DENTAL SOURCES.

Conditions of pain the reverse of those discussed—*i. e.*, pain definitely or indefinitely located in teeth which exhibit no morbid conditions whatever—demand occasional attention at the hands of the dentist.

Chronic malarial poisoning, as stated in the beginning of this chapter, may give rise to periodical attacks of maxillary neuralgia. As in the gouty cases, the constitutional cause of the disturbance is made clear through the therapeusis most effective, viz., the periodical recurrence of the pain leads to the inference of a malarial origin, and to the administration of quinin. Anemia and other conditions in which there is accumulation of products of metabolism also cause it.

Syphilitic pains in the jaws have a pericemental character, and other evidences of syphilis are present which point to a diagnosis.

Pains in or about the teeth are occasional accompaniments of diseases of the brain or its vessels, and of pregnancy or diseases of the uterus, kidneys, and bladder.

Disease in any portion of the fifth cranial nerve may cause pain referred to the teeth, for example, inflammation of the nerve trunk, a tumor in the nerve, or a tumor pressing upon the nerve trunk, or a portion of fractured bone so pressing, or a cicatrix contracting upon a nerve.

Dental pain during pregnancy, without any direct evidence of dental disease, is relatively common.

Disorders of the lower bowels, causing constipation, may give rise to pain referred to one or more teeth, the pain ceasing promptly upon the administration of an active evacuant.

La grippe occasionally produces antral empyema or neuralgia about the dental region as one of its sequelæ.

Pain may appear in one or more teeth either with or without association with pain about the maxillæ or tenderness at the foramina

[1] Mounier: Le Laboratoire, 1907.

of emergence. If there be possible causes in defective teeth or teeth with fillings in which pulp irritation is a possibility, there may be difficulty of diagnosis. There may be a history of an attack of influenza or even of coryza, with the common variety of which dental pains are often associated. Abscess in the maxillary sinus or other sinuses may do the same.

It may occur after la grippe has seemed to have disappeared. The pain is at first generalized over the entire head, but gradually localized in one or several upper teeth, more frequently in the second molar, occasionally the bicuspids. It sometimes is so severe that the patient thinks an abscess is forming.

There is almost always pain in the molar region when pressure is made upon the inner alveolar portion of the hard palate, and sensitivity of the external alveolar region.

For the pseudoödontalgia Roy recommends a capsule containing the following:

℞—Antipyrin . . . . . gr. vij
Quinine hydrobromid . . . . . gr. iij
Sodium bicarbonate . . . . . gr. iij
Sig.—One dose. Increase and prescribe four times a day.

Locally he recommends:

℞—Mentholis . . . . . gr. x
Acidi borici . . . . . ʒiij
Vaselini . . . . . ʒj—M.
Sig.—A small portion to be applied within the nostrils on rising and retiring.

Treatment of Facial Neuralgia.—The cause should be sought for, and, if possible, removed: If due to disease of the teeth, these should be relieved; if due to eye disease, or other cause, this should receive attention. Should one not discover the cause, yet desire to afford a relief pending its discovery, the accepted remedies antipyrin, acetanilid, and phenacetin, combined with caffein or the bromids, are useful.

℞—Antipyrini (vel phenacetini vel acetanilidi) . . . . ʒj
Caffeinæ citratis . . . . . gr. x
Potassi bromidi . . . . . ʒiij—M.
Ft. in chart No. x.
Sig.—One every thirty minutes until relieved. (Hare.)

If the patient be constipated, the bowel should be freed of toxic substances by the use of castor oil, repeated as necessary. Castor oil in small doses is antineuralgic.

In obstinate neuralgia and other painful affections with unremovable cause, the application of the *x*-rays has been urged by Morton as highly efficacious in relieving pain, often for a considerable time.

The blue ray is also used. A remedy of exceedingly simple nature was introduced by Verge and Pitres in 1902. It consists of injecting into the mucous membrane or skin, about where the pain seems to originate, 1 c.c. of alcohol (85 per cent. plus 1 per cent. cocain is preferred by Lenson) at the temperature of 60° C. by means of a hypodermic syringe. Asepsis must be provided for.

A slight humming sensation and swelling of tissue occurs about the area of injection. The pain disappears for a long period after one or two injections a week apart.

Dr. H. I. Patrick[1] recommends the injection in trifacial neuralgia not dependent upon recognizable conditions as preferable in the middle aged and aged to the Gasserian operation, and sets forth the landmarks as well as the conditions for the operation.

The Gasserian ganglion has also been injected with alcohol with apparent satisfaction, and is less serious than radical operation.

A deep injection into the nerve trunks has high medical indorsement. A case in which the face became black on the side of injection was also followed by relief and subsidence of the congestion. The method has been objected to by some. It has been recorded that myosis, and prickly or tingling sensation or paralysis of the part or nearby muscles of temporary nature are by-effects. Injection of the nerve trunk with dilute osmic acid has been practised by surgeons.

Strychnin in fairly large doses has been employed under medical supervision. When the cause cannot be determined the nerve itself may be resected. These are mainly measures in the hands of surgeons.

[1] Journal of the American Medical Association, January 20, 1912.

CHAPTER XXVII.

INFECTIONS OF AND FROM THE MOUTH, AND STERILIZATION.

The conditions found in the human mouth, as pointed out in Chapter III, are of a character which afford lodgement to, and opportunities for multiplication of, many forms of bacteria, both saprophytic and parasitic. The oral conditions are, however, not entirely constant, so that at different periods they may favor the development of some special bacterial forms more than others. The nature of these variations has not been made out, although their effects are indubitable. Again, the oral bacterial inhabitants are not constant as to species, for while there are many forms which appear to be invariable occupants of the oral cavity, many pathogenic forms are but accidental residents. Becoming resident, they may or may not develop according as they find in the mouth a suitable soil. The nature of what constitutes a suitable or unsuitable soil has not been determined, although in some cases extra-oral culture experiments furnish some indications.

Bacterial growths, as causes of dental caries and diseases of the pulp and pericementum, have been discussed in connection with those several diseases. It was shown that the pyogenic cocci are almost constant inhabitants of the human mouth. There appeared also evidence that some important disorders of distant parts are directly traceable to septic processes about the teeth, and, in addition to these, suppurative diseases in other parts become curable after removal of a septic tooth, such conditions representing infection from a local dental infection, an important aspect of dental pathology.

Of the many oral bacterial forms, some are cultivable and some are not; hence the specific effects of some are discovered, others are doubtful.

With regard to local affections, other than those described in the body of this book, a bacterial causation has been made out in some, but in others it has not.

STOMATITIS.

Definition.—By stomatitis is meant an inflammation of the mucous membrane of the mouth. If secretion is markedly increased it may be termed catarrhal stomatitis.

Varieties.—It may be localized, as in marginal gingivitis, or be diffuse; and, again, be accompanied by localized tissue destructions—ulcerations; the character of the ulceration differs according to its probable causes.

Occurrence.—Most of these diseases belong to the period of childhood, although localized ulcerative stomatitis may appear in the adult.

Causes.—The causes of stomatitis are so many and varied as to suggest a classification under heads according to assignable causes. While it is true that bacterial infection has not been shown to be a direct cause of all of these conditions, some degree of causal relationship is probable in all of them. The disease may, however, be included under two heads according as they are or are not localized, and necrotic. The less localized cases appear as a diffuse catarrhal affection, affecting wide areas of the oral mucous membrane; the others appear as spots of localized tissue destruction attended by surrounding hyperemia.

- Catarrhal stomatitis
  - Local
    - Simple.
    - Infective
      - Fermentations.
      - Diphtheria.
      - Gonorrhea.
  - Symptomatic
    - Eruptive fevers.
    - Syphilis.
    - Tuberculosis.
    - Typhoid fever.
    - Drug action
      - Iodids.
      - Mercury.
      - Lead.
      - Pilocarpin, etc.
- Ulcerative stomatitis
  - Local
    - Aphthæ.
    - Thrush.
    - Noma and gangrenous stomatitis.
    - Herpes.
    - Syphilis (primary).
    - Gonorrhea.
    - Vincent's angina.
    - Stomatitis epizoötica.
    - Actinomycosis.
    - Lukwig's angina.
  - Symptomatic
    - Syphilis
      - Secondary.
      - Tertiary.
    - Scurvy.

Simple Local Catarrhal Stomatitis.—The general symptoms of catarrhal inflammation—heat and swelling, with deepened color of the mucous membrane, followed by increased secretion and exudation—attend several types of oral irritation, such as the irritation induced by erupting teeth, particularly of the deciduous teeth. Inflammation of any degree may follow the taking into the mouth of caustic chemical substances, such as caustic alkalies, mineral acids, carbolic acid, etc., which are occasionally taken by children.

Other irritant drugs and very hot fluids may produce similar results. General catarrhal stomatitis is a frequent affection of confirmed smokers, and of drinkers of distilled liquors.

The cure of these conditions consists in the removal or neutralization of the cause, and the use of local sedatives and antiseptics to allay irritation and prevent infection. The most effective method of treating the inflammatory condition is by antiseptic sprays, such as diluted Dobell's solution, followed by sprays of strong solutions of potassium chlorate. If much pain exist, phenol-sodique is an admirable sedative antiseptic, used in 10 to 20 per cent. solution, as a spray.

Infective Local Catarrhal Stomatitis.—This in some degree is a common, perhaps the necessary, antecedent condition to many of the ulcerative forms of stomatitis. It is probable that many of the cases of stomatitis found in infants, children, and adults are due to unusual fermentations occurring in the mouth. Children whose nursing bottles are not kept clean; those who at a later age suffer from neglect of the teeth and from the effects of improper food: adults in whose mouths dental disease is widespread, and whose oral hygiene is very faulty; all exhibit abnormal conditions of the oral mucous membrane—more or less swelling, softness, and deepened color of the mucous membrane, a coated tongue, and offensive breath, with an increase of oral secretions.

The complexus of oral symptoms is commonly, and also by the general practitioner, regarded as symptomatic of gastric, intestinal, and hepatic disorders, as doubtless it is, but the causal relationship is in many cases probably the reverse of that implied in such opinions, for it is probable that the disturbances of digestion are fermentative in character, and the organisms causing them find their way to the stomach from the mouth, which was first affected. The treatment of this condition consists in the correction of its causes, their non-repetition, and the continued use of oral antiseptics.

Symptomatic Catarrhal Stomatitis.—Stomatitis in its catarrhal form usually accompanies the early and later stages of the eruptive fevers, scarlet fever, smallpox, etc. In scarlet fever, smallpox, and measles evidences of direct infection of the mouth exist and the inflammatory reaction is pronounced.

Catarrhal stomatitis is one of the manifestations of secondary and tertiary syphilis, antedating the appearance of tissue necrosis (ulcerations).

More or less catarrhal stomatitis, confined, it may be, to the mucous membrane of the gums, is common in the mouths of phthisical patients; tubercular ulcers may arise or threaten. In some

cases the palate has been perforated. Curtis states that these are usually fatal.

The stomatitis of typhoid fever may be regarded as an almost essential feature of the disease.

The effects of drug elimination by the oral tissues have been already discussed (see p. 648 and 773).

Mercurials in excess produce gingivitis with puffy gums which bleed readily; there is coated tongue, fetid breath in marked cases, swollen tongue and cheeks, and exfoliation of the teeth. The history of administration of mercurials, and, possibly, of syphilis, as a reason for it affords a diagnosis. The mercury should be stopped; atropin sulphate, 5 minims of a 1-grain to 1-ounce solution in water, administered as an antisialagogue every four to six hours; a 5 per cent. potassium chlorate solution in hydrogen dioxid makes a useful mouth wash for reducing the local inflammation.

Ulcerative Stomatitis.—In all probability these ulcerations are always infective. Like catarrhal stomatitis the ulcerative disease may have only a local significance or be indicative of some general disease.

Ulcerative Stomatitis of Local Significance.—The more usual or infantile forms of these disorders are a sequel of catarrhal stomatitis, at least of an acquired debility of the oral tissues, and their primary cause is, therefore, the cause producing a condition of mucous membrane which permits the growth of infective organisms. One of these diseases, thrush, has already been described. The others, aphthæ, herpes labialis, and noma, are all probably due to the action of organisms.

Aphthæ.—This affection is common in its isolated form, as the canker sore. In the catarrhal stomatitis of children, during or after dentition, multiple sores frequently make their appearance. The condition can best be studied when it appears as an isolated sore in the mouth of the adult. The most common situation of the sore is at the junction of two mucous surfaces, such as that of the gum with the lip or cheek, or that of the floor of the mouth with the gum or tongue. Redness diffused over a limited area, followed by a nodular hardening, occurs, during which local pain is annoying; the centre of the hardened area breaks, the epithelium disappearing, forming a raw surface, which quickly acquires a rough, yellowish white coating which is easily removable. The sores are very painful.

The mouth is usually otherwise healthy, and there is an absence of associated throat and skin affections.

The notable fungus of the blastomycetes is the saccharomyces albicans; this organism, when classified by mycologists as a thread fungus, was known as the oidium albicans (Fig. 705). The growth

of this organism illustrates forcibly the influence of soil on the growth of fungi. It does not occur in the mouths of healthy, well-nourished, and clean children with good surroundings. It is a disease of childhood, particularly of nurslings, and its occurrence is almost always confined to bottle-fed babies whose feeding bottles are kept in an unclean condition. Debility of the oral tissues is established in consequence of the fermentations arising from the source just named, furnishing a favorable condition for the development of the saccharomyces (oidium) albicans. The condition produced is known as thrush. The infection may be carried from one child to another, and if the fungus be brought in contact with an abraded mucous surface of an adult it may develop.

The fungus burrows between the epithelial cells of the mucous membrane (Fig. 706), not beyond it. It first appears in small spots which coalesce, until large patches of a membranous-like growth

Fig. 705

Saccharomyces albicans, thrush fungus. (Miller.)

Fig. 706

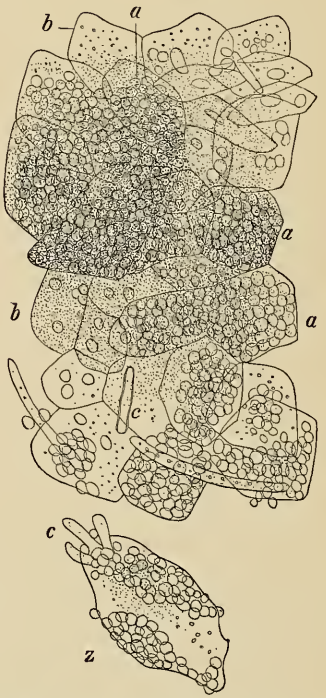

Pavement epithelium covered with spores of the oidium albicans. (Ch. Robin.)

cover extensive surfaces, spreading by continuity to all of the mucous surfaces associated with the mouth.

As bud fungi flourish only in media of acid reaction, the use of alkaline washes is indicated in the treatment of this condition. Wiping the patches with dilute phenol-sodique is efficacious. Small spots may be cauterized with silver nitrate or trichloracetic acid.

Hydrogen dioxid or 25 per cent. iodin in glycerin are also useful.

This condition follows so constantly upon the taking of very indigestible food, such as lobster, Welsh rarebit, etc., that acute indigestion must be regarded as having some causal relationship

with it. It is also of frequent occurrence in the mouths of dyspeptics; that form of gastric disturbance attended with a deficiency of hydrochloric acid in the gastric juice appears to have a constant association with it, though it is probably caused by the oidium albicans.

The appearance of ulcerative stomatitis in children, together with its treatment, was discussed in the chapter on Dentition.

The general treatment of these ulcerations appearing in the mouths of children is the administration of a laxative, and the subsequent administration of listerine, gtt. x, every two hours. Locally the mucous membrane is to be sprayed with hydrogen dioxid, followed by sprays of strong solutions of potassium chlorate.

Localized aphthous patches in the adult are promptly relieved by the administration of calomel, gr. ij, at night, followed in the morning by a mild saline. The local sore is dried and touched with pure carbolic acid. The administration of alkalies before meals, and hydrochloric acid after meals, usually remedies the gastric condition, unless it be of long standing. A variety of aphthous sore is called, from the anatomical situation of the ulcers, follicular stomatitis. Irritation and swelling of the mucous follicles in the palatal, buccal, and labial mucous membrane are accompanied by more or less localized inflammation; the follicles become ulcerous, the small ulcers having a uniform size. This condition quickly disappears under the treatment advised for ulcerative stomatitis. An indication of the bacterial origin of all of these disturbances is seen in the efficacy of antiseptics used in their treatment.

Rubber Sore Mouth.—A form of stomatitis is due to artificial dentures resting upon the mucous membrane, and either by pressure or light friction, or possibly by preventing radiation of heat, they cause desquamation of the epithelium. The part beneath the plate assumes a more or less reddened or ulcerated appearance. Vulcanite plates that are not smooth upon their surfaces of adaptation may produce this physical irritation, but oftentimes such surfaces may covered with infective mucous plaques, so that this may in some cases be an added cause.

Eilestein has shown that the use of vermillion colored vulcanite causes minute pores to appear in the vulcanite which harbors bacteria which may induce inflammation of the oral epithelium.[1] The use of carmine-colored vulcanite is suggested.

Treatment.—The treatment consists of rest and healing mouth washes. Antiseptics are usually included. (See Gingivitis.)

Stomatitis Aphthosa Epizoötica.[2]—This is the oral expression of foot-and-mouth disease occurring in cattle and rarely fatal, and

[1] L'Odontologie. See Dental Cosmos, February, 1911, p. 248.
[2] Lartschneider: Dental Cosmos, 1908, p. 880.

usually lasting about eight weeks. The germ is not fully determined as yet.

Equinia (Glanders).—An infectious disease of cattle which may be transferred to man, producing a purulent discharge from eyes, nose, and mouth.

Diagnosis.—The diagnosis rests upon the presence of the disease in nearby cattle and the prodromata and later presence of fever, pustules on the mucous membranes of the lips, tongue, and sometimes on the hard palate and throat, occasionally between fingers, around nails, or on nipples. These later burst, leaving ulcers with a grayish-yellow coating. The pustules dry up without scars in the second week.

Treatment.—The treatment rests upon antisepsis in so far as the local manifestations are concerned.

Diphtheria.—While the point of first attack of the diphtheria bacillus is most marked about the soft palate and tonsils, the false membrane forming there and spreading to the pharynx, more or less general inflammation of the oral mucous membrane also occurs.

NOMA, CANCRUM ORIS, GANGRENE OF THE MOUTH.

In ill-fed, ill-nourished, and ill-kept cachectic children, the debilitation of the oral tissues may exceed the grades given, and a disease, probably bacterial in origin, may arise which leads to widespread necrosis of the cheeks and maxillæ. The condition is called gangrene of the mouth, noma, or cancrum oris; the latter term has been applied to the less severe varieties.

This disease may make its appearance as an ulcer at the junction of cheek and gum; in other cases a severe stomatitis arises without a primary ulcer. A greater or less extent of the cheek acquires a board-like hardness, becoming livid; the overlying mucous membrane breaks, exhibiting a large slough. The necrosis extends toward cheek and jaw, destroying further tissue. The sloughs undergo putrefactive decomposition, emitting a stench. The destruction of tissue may be arrested, or may proceed, destroying in a few days the entire cheek and bony tissues. In the more severe cases the disease is almost invariably fatal, because the extent of the tissue destruction bears a constant relation to the underlying debility of the patient. It will be seen that the disease resembles malignant pustule or carbuncle in several of its features.

Schimmelbusch[1] found a bacillus (pure culture) upon the borders of the necrosis which may prove pathogenic of noma.

[1] Miller: Dental Cosmos, September, 1891.

Hillesen obtained a diplococcus which developed in pure culture, produced noma in an animal into which it was injected, and from the lesion a pure culture of it was obtained which in like manner was put through four animals.[1]

These cases are purely medical; so that their full discussion is not warranted in these pages. The principle of treatment is to improve the general condition of the child, destroy the probable infection in the borders of the still vital tissue by cauterization, and promote sloughing of the necrosed tissue by the use of antiseptic applications.

FIG. 707

Noma. (J. Lewis Smith.)

Dr. L. Fisher (New York) reported a case upon the inside of the cheek, cured by applications of ichthyol in lanolin four times a day over the entire area.[2]

The Eruptive Fevers.—Hyde and Montgomery describe the following oral symptoms associated with various diseases having eruptive dermatitis as phenomena:

Scarlatina.—The mucous surfaces of the mouth and fauces are engorged tumid, reddened, and often covered with deep reddened puncta. The tongue is coated with a white fur over the filiform papillæ. This is first partly lost, giving red puncta and a white background; when totally lost it gives "strawberry tongue."

[1] Dental Cosmos, 1908, p. 180.

[2] Ibid., 1902.

Variola.—The papules may appear over the entire alimentary canal. In the mouth they lose their epithelium, through heat, moisture, and friction. Reddened excoriated surfaces appear, over which the epidermis is reformed. Gangrenous complications are rare.

Hemorrhagic Variola (Effusions of Blood into Mucous Surfaces).—The mucocutaneous orifices are crust-covered and exude an extreme fetor. Blood may escape from the mouth.

Varicella.—The macular lesions may extend to the surfaces of the eyes, mouth, etc.

Rubeola.—Even three days before skin eruptions. "Koplik's spots," bluish white or bright red with central bluish-white punctum on mucous membrane. In period of affloresence a catarrhal or eruptive inflammation.

Syphilis.—Secondary eruptions, later forming mucous patches; characteristic crusts about nose and mouth.

Urticaria.—The eruption in well-marked cases may include the mucous membranes.

Angioneurotic Edema.—The rosy red to livid edematous plaques may appear upon the lips and pharynx, producing at times dyspnœa.

Erythema Scarlatiniforme.—The mucous membranes in mouth and fauces may be reddened or be denuded of epithelium, but the characteristic "strawberry tongue" of scarlatina is wanting.

Erythema Iris.—The papules may coalesce and be filled with blood or hematuria may result with severe involvement of mucous membranes of lips and mouth, ulceration rapidly ensuing.

Erythema Multiforme.—Like the iris variety the macules may appear in the mouth.

Dermatitis Herpetiformis.—When affected, mucous membrane of mouth sodden, macerated, pustules; and bullæ form and rupture, leaving raw erosions or sloughing patches of mucous membrane; extremely foul odor.

Herpes Simplex.—Herpes Zoster.—See this chapter.

Erysipelas.—May extend to mouth, causing a dry, tumid, glazed appearance.

Rhinoscleroma.—A rare disease; usually begins in nose; may extend to mouth, with ulcerative destruction, causing exfoliation of the teeth.

Pemphigus Foliaceus.—The mucous membrane of the mouth and throat may be denuded.

Pemphigus Vegetans.—White patches followed by excoriation with foul odor may occur.

Drugs Producing Stomatitis.—Many drugs taken internally may produce dermatitis or stomatitis as a temporary efflorescence, while with some, as mercury, the impression is more profound (see p. 648);

with others it is simply expression of idiosyncrasy, with which the oral tissues may or many not take part.

Iodin or bromin or their compounds; antipyrin and others of its class; arsenic, belladonna, aconite, carbolic, nitric, tannic, boric, and benzoic acids; sodium benzoate and sodium borate.

Chloral, digitalis, mercury, opium and its alkaloids, phosphorus, podophyllum, potassium chlorate, castor oil, cinchona and its alkaloid, quinine, salicylic acid and salicylates, strychnine, tar, turpentine, and others of less interest are mentioned. Silver nitrate may produce argyria of the skin and mucous membranes. As instanced by argyria, the drug finds its way to the superficial tissue in which it may produce irritation.

SYPHILITIC AFFECTIONS OF THE MOUTH.

The recognition of syphilitic lesions about the mouth is of vital importance to the dental operator, first, because by the recognition he may take steps to prevent the carriage of infection to innocent patients; and secondly, that he may avoid inoculation of himself by the poison.

In the minds of many, syphilis is associated with the lower class of persons, who are confirmed *débauchés*. While it is undoubtedly true that its prevalence is most marked in this class of persons, it appears, with horrible frequence, in persons who would be little suspected of having such infection. The operator is to be guided in his opinions and precautions in this matter, not by the social status of the patient, but by the nature of the morbid conditions existing.

The cause of syphilis is the traponema pallidum discovered by Schaudin and Hoffman, and present in its lesions, transmitted from one person to another directly or through the medium of an inanimate object which has been infected.

The diagnosis may be made by microscopic examination. The sore is washed and the serum later exuded used to make a smear on a glass slide. Stein states that the edge of the sore should be scraped with a sharp instrument after washing, and the serum collected from that source, otherwise the treponema may not be obtained.[1] This is first dried in the air, then stained with Hastings' stain. After a minute distilled water is added until a metallic film is formed. After five minutes more they are washed in running water and dried. The treponema pallidum stains a faint blue.[2] They may also be seen living by aid of the "dark-field illuminator."

[1] Dental Cosmos, July, 1913, p. 744.
[2] McKee: Dental Cosmos, 1909, p. 1437.

Syphilis is usually divided into three stages, primary, secondary, and tertiary; to these may be added a fourth stage, viz., in patients who have been discharged as cured mild manifestations of disorders, particularly of the skin and mucous membranes, make their appearance from time to time, and disappear promptly upon the administration of iodids. The semen of syphilitics in the secondary period is infectious to apes.

The first stage of syphilis—primary syphilis—consists in the formation of the primary sore or chancre, and the involvement of the nearest lymphatic glands. Secondary syphilis is attended by fever, eruptive inflammations of the skin, inflammation and superficial ulceration of mucous structures. In tertiary syphilis destructive inflammation of the skin, mucous membranes, and connective tissue occurs, together with the formation of specific tumors—gummata.

Some differences of opinion exist among syphilographers as to the relative infective power of the secretions from the several lesions of syphilis. All are agreed, however, that the secretions from the secondary lesions observed in and about the mouth are highly infective. It is the part of prudence to regard all syphilitic lesions as infective. All these stages of syphilis may be seen in the human mouth. It is to be remembered that if the mucous membrane of the mouth be infected from a mucous patch (a secondary lesion), the acquired disease will appear, not as a mucous patch, but as a chancre. It is from mucous patches that infection is most to be feared.

Primary Syphilis of the Mouth.—Causes.—The primary lesion of syphilis, chancre, when found in the mouth is a consequence of direct infection from a syphilitic. The infection occurs from contact of the mucous surface of the mouth with a syphilitic lesion upon another person. It has been transmitted by kissing, even with an innocent person as the intemediary; it may occur from using a glass or cup previously used by a syphilitic, by smoking cigars or cigarettes which have been made by syphilitic cigarmakers, who have applied the tongue to the tobacco in attaching the wrapper. Dental instruments may be the carriers. Any of the articles named, or the contact of any article which has been in contact with a syphilitic lesion, if brought in contact with an abraded mucous surface, may cause infection.[1]

The infection may be transferred from patient to operator if the fingers have any abraded surface, or if the surface is broken acci-

[1] Metchnikoff and Roux found that an ointment composed of 10 parts calomel and 20 parts lanolin, applied by inunction to an intentionally infected part, prevented the appearance of syphilitic infection if used within one hour after inoculation. Mercuric chlorid was of no avail. Dental Cosmos, 1907, p. 1007.

dentally by an instrument. Dentists have been inoculated upon the hand. During and since the time of Hunter the use of teeth from syphilitic patients in plantation operations has been a clearly recognized medium of communication. About 32 per cent. of all primary chancres appear within the dental field either upon the lips or within the mouth.

Appearance and Diagnosis.—"The primary lesion of syphilis never makes its appearance before ten days after infection; the maximum period is about ninety days; the average is twenty-one days."[1]

It usually appears as a single, elevated, hard papule. In cases of dental infection, most frequently about the lips, the papule loses its epithelial coating after some days. The induration surrounding the papular mass increases until the papule, which is now raw and in a process of ulceration, appears surrounded by a ring of cartilaginous hardness. This induration is the one distinguishing feature of the chancre, which is not painful. In about a week after the appearance of the primary sore, swelling of the submaxillary lymphatic glands is observed. In case the chancre appears upon the tongue, the subhyoid lymphatic glands are swollen.[2] Unless pyogenic infection has occurred, the lymphatic involvement is not inflammatory, there being no pain present. In from three to four weeks the sore disappears, leaving no signs of its site in some cases; in others, some induration may persist.

The diagnosis of this condition is the important consideration, so far as the dental practitioner is concerned, its treatment being the province of the medical practitioner.

The elevation of the sore, its *induration*, and, if obtainable, the time of inoculation, are diagnostic data. The sore is single, as a rule, and there is hard, nodular painless swelling of the neighboring lymphatics. A single ulcer of ulcerative stomatitis may in some degree simulate the appearance of a very small chancre. It may exhibit slight induration, but its irregular form, situation, painfulness, and the usual absence of lymphatic involvement, together with its prompt disappearance after sterilizing the mouth and cauterizing the ulcer, will differentiate the two sores. If the chancre be upon the tip or sides of the tongue, where it is subjected to irritation, it may become very large and bear a close resemblance to epithelioma of that organ. In epithelioma there are apt to be pains of a lancinating character, the induration follows ulceration, and the ulcer has hard edges and often a warty-like growth.

[1] Gross: System of Surgery.

[2] Park: Surgery

It is a wise precaution to view all sores about the mouth as possibly infectious. All errors of diagnosis in this direction will be more than compensated for by the assurance of non-transference of infection.

Secondary Syphilis of the Mouth.—The secondary manifestations of syphilis may be observed in and about the mouth, no matter what the location of the primary lesion may have been; they are the result of a general, not a local, infection. A skin eruption appears also.

Fig. 708

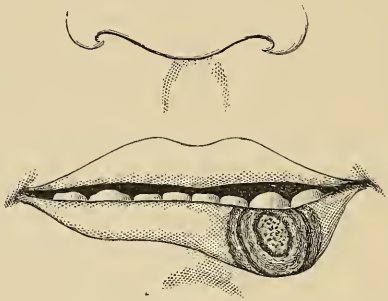

Chancre of the lip.

Secondary infections of the mucous tissues appear in from four to twelve weeks after the appearance of the primary lesion. Sore throat, due to inflammation of the mucous membrane of the pharynx and parts about, is almost constant; together with syphilitic hoarseness, due to the extension of the affection to the mucous membrane of the larynx.

The appearance of copper-colored areas upon some portion of the mucous membrane, on the tonsil, pharynx, soft palate, lips, or buccolabial surface, precedes the loss of epithelium over these surfaces, which soon occurs, forming the most virulently contagious lesion of syphilis, the mucous patch. The patches become covered with a grayish-white, opalescent, pasty covering, resembling the ulcerations of non-specific stomatitis. So close is the resemblance that a differentiation can only be made at times by additional evidences of secondary syphilis. Single patches may coalesce, forming large, irregular areas covered by a grayish-white pellicle. These patches are rarely painful. Ulcerations having ragged, irregular outlines may appear at the sites of the original patches or in other situations, and exhibit a tendency to spread. In healed cases the cicatrices present a whitish pellicle and contracted scar, indicative of old healed ulcers. In the skin little pits and linear scars are symptomatic.

The diagnosis of the condition is determined by the history and

by a discovery of other lesions of secondary syphilis, iritis, headache, neuralgia, paralysis of muscles of eye and face, chorea, brittle, cracking nails are often early symptoms;[1] also the lymphatic glands will be involved; skin eruptions, falling out of the hair (alopecia), and the areas of copper-colored eruption upon the mucous membrane of the pharynx and soft palate.

Hugenschmidt[2] has observed among syphilitics, who presented no local lesions, the frequent nocturnal occurrence of indefinitely located dental pains, spreading to the palatal region. In case of doubt, search for the treponema, or the Wassermann or luetic reaction may be employed.

Tertiary Syphilis of the Mouth.—The syphilides of the secondary stage arise in, and are confined to, the mucous and dermal structures; those of the tertiary stage arise in the deep connective tissues, and are frequently associated with periosteum.

Tertiary lesions, as seen by the dentist, are usually in the form of ulcers of, first, the soft or hard palate, and of the tongue or lips. In the earlier stages hard, nodular formations may be noted as antecedents to the ulcerations. Chronic periostitis of the palatal processes may occur, leading to the formation of localized thickenings. In other cases, in the soft palate, upon the tongue, or in the hard palate, localized swellings may occur, having a livid red appearance; the overlying mucous membrane breaks, establishing an ulcer, which may perforate the soft palate and destroy a portion of the palatal process, or form large ulcers on the tongue. The condition is one of gumma. These lesions appear in from two to five years after the secondary manifestations.

Tertiary Lesions.—The sight and hearing may be affected, the throat diseased, causing loss of voice, necrosis of the bones and tissues of the nose causing deformity. The brain or spinal cord affected may cause paralysis, locomotor ataxia, or loss of reason. These are usually the result of failure to follow treatment to a conclusion.

The tongue may have either a localized or widespread parchment like hyperplasia of the mucous membrane, and muscular tissue which may cause it be become indented by the teeth, to lose its papillæ, and become dry and red. Pedersen[3] calls attention to the fact that the indentations do not disappear when the tongue is stretched, while if due to ordinary debility they may do so.

Although there is much doubt as to the degree of infectiveness of these tertiary lesions, precautions as to sterilization should be taken as with the primary and secondary lesions. A defined, ragged ulcer

[1] E. Whitney: Dental Cosmos, 1911, p. 524.
[2] Dental Cosmos, 1892.
[3] Ibid., 1908, p. 332.

occupying the hard or soft palate, which has persisted for a long time, should always be viewed with suspicion, and a search be made for other evidences of syphilis.

These ulcerations appearing upon the side of the tongue may closely simulate epithelioma of that organ. The confusion is increased if, in consequence of the presence of jagged teeth, a continuous irritation is excited. Moreover, leukoplakia of the cheeks, a diagnostic sign of incipient epithelioma, frequently accompanies tertiary syphilis.

The existence of tertiary syphilis is of great clinical importance to the dentist in that a condition of lessened resistance of tissues is established, and disease processes which in the healthy person are comparatively circumscribed, in the syphilitic run a riotous course. A septic pericementitis by extension may involve a wide area of periosteum, leading to extensive maxillary necrosis.

Treatment.—The treatment of syphilis has been largely by the administration of mercury and potassium iodid for a long period until the treponemata shall have been killed out. If not so continued the tertiary lesions may reappear with serious results The. latest development in treatment is the use of Ehrlich's preparation of arsenic, dioxydiamedoarsenobenzol, "606," or "salvarsan," for which positive claims as a prompt cure are made.

TUBERCULOSIS OF THE MOUTH.

The bacillus of tuberculosis, under favorable conditions, develops in the tissues of the mouth, producing its characteristic lesions. Finding a suitable soil, such as is furnished by the heredity which predisposes to phthisis pulmonalis, the bacillus may find entrance to the deeper tissues from the mucous membrane of the mouth and excite tuberculosis in the deep structures, the bone, etc. A number of perforations of the hard palate have occurred. According to Curtis these are usually fatal. What part is played by local oral and dental lesions in tuberculosis of distant parts, by establishing pathways for the entrance of the bacilli into the circulation, is at present conjectural, but that such infections occur is very probable. Lupus, a skin tuberculosis, may extend to the mouth producing nodules.

ACTINOMYCOSIS.

The condition produced by the development of the ray-fungus, the actinomycosis, in the lower jaw and cervical regions of cattle and swine—lump-jaw—is not unknown in human beings. It may be

derived by chewing straw or grass in which the ray-fungus has produced "rust."

Miller[1] gives 203 cases reported in German medical literature between 1886 and 1891. In at least 120 of these cases the point of entrance of the fungus was found to be in the region of the mouth or throat. Actinomycosis threads have been repeatedly found in the saliva and in carious teeth, and notably in the tonsils. Whether the path of entrance to deeper structures is ever through carious teeth is undertermined, but certainly lesions or wounds about the mouth furnish an entrance. Padgett reports a case of alveolar ulceration following extraction, which proceeded to abscess upon the face. Bacteriological examination showed the ray-fungus.

The disease has yielded to the action of sulphate of copper, $\frac{1}{8}$ grain, plus iodid of potassium, 10 grains, internally four times a day, together with local irrigation of 0.1 per cent. solution of copper sulphate.[2]

GONORRHEA.

Cases of oral infection by the gonococcus of Neisser have been reported. The oral mucous membrane and the gums may undergo intense suppuration with its accompaniment. Fever and its accompaniments may be present. The eyes are very subject to secondary infection in an individual suffering from gonorrheal urethritis. The hands are a medium of transference. Babes may be directly infected by the mother during birth, and blindness often results. The law now requires the instillation of a mild solution of silver nitrate or other antiseptic as advocated by Crede. The diagnosis can be made by microscopic examination of the bacteria. Stein claims that endeavor to infect the nose with gonococci failed and questions oral infection by them. (See p. 677.) Lederer in a case of oral infection in a patient with urethral gonorrhea found it by microscopic examination to be a case of Vincent's angina, which see.

GENERAL SEPTIC DISEASES OF DENTAL ORIGIN.

The effect of the existence of dental diseases upon the body at large, particularly as regards secondary infection, is a matter increasing in importance as the possibilities of their connection are made out. At present the organisms of greatest demonstrable pathological interest are the pyogenic cocci. The almost constant presence

[1] Dental Cosmos, 1891.

[2] Brophy: Dental Cosmos, 1908, p. 78.

of these organisms in the mouth, carried thence into the pharynx, posterior nares, larynx, lungs, and stomach, furnishes the reason for the pyogenic and phlegmonous inflammations which occur in these organs. The diplococcus of pneumonia, a frequent organism, but waits a favorable opportunity to establish high inflammations and fibrinous exudations in the lungs, and possibly in other structures.

The most important clinical associations of dental with general infections are diseases of the pericementum. The pulps of teeth, having no lymphatics, do not appear to take up and transmit the products of the action of septic organisms; but while the evidences of such absorption, involvement of the neighboring lymphatics, are not present, it must be remembered that the veins may transmit the poison, and, in addition, may perhaps convey organisms from a diseased but still vital pulp to distant parts. When, however, the pulp is dead and the pericementum is invaded, there is no doubt of general infection from this local source. More or less septic intoxication is a common attendant upon severe septic apical pericementitis, and septicemia accompanied by inflammation of the neighboring lymphatic glands is of sufficient frequency to emphasize the need of the vigorous antiseptic treatment recommended in all of these cases.

Pyemia is far more uncommon.[1] Pyogenic organisms, gaining access to the blood current from the local source of infection, establish suppuration in distant parts; in other parts of the bone, or in other bones (osteomyelitis), in the lungs, meninges, and substance of the brain. One case[2] has been reported where abscess of a toe, ear, and forearm ceased, and recovery took place after treatment and filling of septic root canals. Several cases are tabulated by the same author in which extensive necrosis and death resulted from pyemic infection from septic pericementitis. Some of these cases recorded were associated with acute, some with chronic, septic pericementitis.

In addition to the usual pyogenic cocci, Miller has isolated several forms of cocci, bacilli, and spirilla, forming products which, if injected into the circulation of animals, cause death from septicemia in from hours to days. As many of these forms may be brought into relation with deep parts by the anatomical conditions created by pulp death, the possibilities of many types of infection *via* pulpless teeth are evident.

The possibilities of local as well as general infections through the conditions established in the several forms of pyorrhea alveolaris should not be forgotten. (See pp. 438, 603, 605, 631, 742, 787.)

[1] Miller: Dental Cosmos, 1891.

[2] Ibid.

The pockets formed by the soft tissues overhanging lower third molars whose eruption is impeded invite the passage of septic organisms to deep parts. Local pyogenic infections are common in these cases, and may extend into the pharynx and the submaxillary tissues, as in Ludwig's angina.

HERPES LABIALIS (HERPES SIMPLEX).

This consists of a vesicular eruption upon the lip, tongue, mouth, cheeks, or allæ of the nose. The vesicles are filled with a clear fluid which soon discharges. An excoriation is left often covered by a light crust, which is never followed by a scar. The condition may cause little pain or considerable burning and itching. It may accompany colds, fevers, exposure to heat, draughts, and gastric disorders. It follows either a direct irritation of the nerves, as after the use of rubber dam or other dental operations in susceptible persons, or may be of reflex origin; in either case localized peripheral neuritis being the initial lesion.[1] There is some reason to believe that infection plays a part in its production. As a preventive it is well to lubricate the lips with glycerin and rose water or with cold cream when much stretching or other irritation is necessary.

HERPES ZOSTER.

This is a probably infectious disease, almost invariably monolateral, associated with a neuritis usually of a spinal ganglion or with a peripheral neuritis, which produces, first, a hyperesthesia of the integument, macules, and later vesicular eruptions not usually beginning on a mucous surface. They appear in groups and may coalesce, forming patches. Desiccation forms a crust; pus may form.

The interest to dentists lies in the fact that in zoster of the head exfoliation of the teeth is said to be associated in rare cases.[2]

LEUKOPLAKIA BUCCALIS.[3]

Upon the inner surface of the cheeks or lips, and upon portions of the gum and the dorsum and edges of the tongue, may appear sharply outlined, dull, whitish, slate-colored or silver-whitish points, disks, streaks, bands, ribbons, or patches of irregular shape, either flattened or slightly elevated, above the general level of the mucous surface. They may crack or fissure, and inflammation of the derma and pain

[1] Hyde and Montgomery: Diseases of the Skin. [2] Ibid. [3] Ibid.

result. Ordinarily they are simply rough and without much discomfort. It occurs almost exclusively in males. They differ from the mucous patches of syphilis in that the latter are soft and tend to ulcerate, and, while they may accompany syphilis, may occur in its absence or of any history of it.

They simulate the keratosis of lichen planus, which should also appear as papules upon other parts of the body.

Apart from syphilis, it is due to irritation such as that from tobacco or rough teeth, and with syphilis, tobacco, and rough teeth may be additional excitants.

R. H. Ivy reports three cases with tendency to epitheliomatous degeneration, all without history of syphilis, and in two of which the Wassermann reaction was negative.[1]

The use of alcohol and spices are also a cause.

The pellicle is closely adherent, and consists of an hypertrophied and hyperkeratinized epithelium, with more or less inflammatory infiltration of the derma and with partial obliteration of the papillæ.

The chief danger in the disease is the tendency to epithelioma, some authors estimating 30 per cent., especially in the cases in which exfoliation and ulceration occur. Some fourteen years ago a male patient presented with a leukoplakia in which there was a constant desquamation as though very hot liquids had been used. Medical treatment was given, tobacco and liquor were largely avoided, but after about twelve years, epithelioma involving a jaw operation occurred.

The removal of the pellicles by suitable caustics, galvanocautery, or bur, and radiotherapy, the use of soothing mouth washes, together with a hygienic regimen, and the avoidance of irritants like tobacco, alcohol, spiced, hot, or iced foods, is the usual treatment to avoid epithelioma. The diagnosis lies clearly within the province of the dentist who may note it before the patient. The treatment is usually conducted by the physician, and is often unsatisfactory as to permanent cure. Cases with syphilitic history, of course, require antisyphilitic treatment.

Leukoplakia has been also called buccal psoriasis, but psoriasis does not affect mucous surfaces, hence it is a misnomer.

LICHEN PLANUS.

This condition, which may simulate leukoplakia,[2] is characterized by an eruption consisting of glistening flat-topped polygonal papules

[1] New York Medical Journal, October, 1912, p. 1187.
[2] Ibid., April 13, 1912.

with tendency to form irregularly arranged groups. On the mucous surface they appear as whitish macules, striæ, or flat papules on both sides of the tongue at the points in contact with the molar teeth.

They are the result of an arterial or venous hyperemia of the papillæ of the corium, a secondary thickening of the lower part of the rete, and a tertiary flattening of the papule by pressure.

A proliferation of cells in the granular layer and a deposit of keratohyalin in whitish spots occur. This causes a similarity to leukoplakia. It usually occurs in the nervously exhausted, though many patients may have a fair degree of body nutrition while yet nervously exhausted.

PHOSPHOR NECROSIS.

This disease is a more or less extensive necrosis of the maxillæ due to the entrance of phosphorus or its fumes into contact with the periosteum or pericementum of a tooth.

It was formerly frequent in match factories, when white phosphorus was used, though now less when the red is employed, but has occurred through the chewing of match heads, and a case has been reported in which a half grain taken in three days caused it.[1]

As it does not ordinarily occur in the mouths of those having sound teeth, it is generally regarded as of local origin, the phosphorus gaining entrance either through the pulp canal of a tooth, or, possibly, through some point of injury external to the tooth.

Abscesses containing offensive pus cause great swelling and excessive salivation, and may cause several fistulæ, while the swallowing of the discharge causes general toxic disturbance, and infection such as pneumonia or cerebrospinal meningitis may have rapid effect.

The periosteum remains unaffected as to its vitality, while the bone proper undergoes osteoporous necrosis, becoming like rotten sponge. As the sequestrum is separated, there is a tendency to formation of new bone by the periosteum. The necrosis of bone may be very extensive, involving in the lower jaw the entire horizontal portion, while the ramus may remain unaffected. In the lower jaw, after exfoliation, the bone may be almost entirely restored to an amount nearing fair comparison with the ordinary edentulous mouth, while in the upper jaw no repair occurs. This new bone may undergo atrophy if not put to work by artificial teeth.[2] As a prophylactic sodium bicarbonate solutions are recommended by Arnone.[3]

[1] Arnone: Dental Cosmos, 1910, p. 425.

[2] For consideration of treatment the reader is referred to Garretson's System of Oral Surgery, sixth edition, and other writings upon the subject.

[3] Dental Cosmos, 1909.

SCORBUTUS.

This is scurvy as described on pages 215, 649, 684, and below.

PURPURA HEMORRHAGICA.

This is the appearance of small purplish spots beneath the skin and mucous membrane, and is dependent upon infection and toxic conditions.

Brown,[1] following Schamberg, presents the following clear differential symptoms:

Scorbutus.	Purpura Hemorrhagica.
1. Occurs in those subjects due to lack of vegetable food and to bad hygiene.	1. No such etiological relationship.
2. Definite antecedent symptoms, weakness, impaired circulation, etc.	2. Antecedent signs slight or absent.
3. Onset slow.	3. Onset sudden.
4. Gums spongy, swollen, and bleeding; teeth loose.	4. Gums often bleeding, but not swollen.
5. Severe muscular pain.	5. Less marked.
6. Brawny infiltration of lower extremities.	6. Not present.
7. Hemorrhages from mucous membranes, not profuse, as a rule.	7. Hemorrhages from mucous membranes so severe as to sometimes prove fatal.

LEPROSY.

During the progress of leprosy, an infective disease, characteristic nodules and ulcers appear about the oral structures. As many parts of the head are affected in like manner, these are but symptoms of the progress of the effects of the Bacillus lepra.[2]

ANGINA.

Angina is usually defined as a sense of choking or suffocation, a symptom which accompanies inflammatory affections of the pharynx as well as the paroxysmal neuralgic affection of the heart known as angina pectoris.

Angina Simplex.—This is inflammation of the pharynx, with, of course, more or less swelling and infiltration of exudate. Swallowing may be difficult. Local depletion and sedative washes, with general derivation, are indicated. If chronic, stimulant washes are useful combined with general tonic treatment.

[1] Dental Cosmos, 1911, p. 296.
[2] For an exhaustive article see Oliver, Dental Cosmos, 1908.

Ludwig's Angina.—In 1836 Ludwig described a disease which is considered to be an infectious cellulitis in the submaxillary region, which may extend deeply into the tissues of the neck. The infection is thought to be due to the Streptococcus pyogenes or bacillus of malignant edema, though the Staphylococci and Diplococcus pneumoniæ are found, and probably enter the cellular tissue of the submaxillary region and neck through the oral or pharyngeal mucous membrane or a wound. An apical abscess, also, the repeated impaction of food into the peridental region, especially about a third molar, and its fermentation has caused a deep infection resulting in this disease. The patient has lassitude, chilliness, and fever.

A hard swelling appears beneath the mandible after several days, and extends toward the neck and under the tongue. There is muscular rigidity and the head is inclined in one direction. The skin is not much reddened.

Later edema is marked and may extend upward toward the parotid gland or the glottis. Breathing and swallowing are rendered difficult by oral and pharyngeal swellings. There are the usual oral symptoms of inflammation. Upon incision the connective tissues are found to be sloughing, grayish black in color, and may ooze pus.

The board-like hardness of the floor of the mouth and the marked dyspnea are constant features.

The spread of the infection being by continuity of cellular spaces, the glands are much enlarged.

A large abscess may form and discharge. Pneumonia, septicemia, and pyemia are complications to be feared as the result of spreading infection. Incisions for drainage and antisepsis are usually conjoined with systemic treatment, but as the case is often of dental origin the cause should be removed.

Vincent's Angina.—This is an edematous tonsillitis, which may affect also the mucous membrane of the mouth and pharynx, followed by the formation of a pseudomembrane as in diphtheria, later ulceration and hemorrhage may appear. There are the usual accompaniments of inflammation in this locality, together with fever and sometimes rigors. It usually lasts about two weeks. It also occurs about the gums without necessarily affecting the pharynx, and here may last much longer.

The differential diagnosis from diphtheria and syphilis is made by microscopic examination. Vincent's bacilli, spindle-shaped, pointed at extremities, and 6 to 10μ in length, are usually associated with a long thin spirillum. (See Fig. 611.)

They take several stains, but not the Gram. In diphtheria, Loeffler's bacilli, and in syphilis the treponema pallidum would be

found. Tuberculosis, gonorrhea, stomatitis, and pyorrhea must also be differentiated. (Lederer.)

In the treatment mercuric chlorid 1 to 10,000 in 4 per cent. boric acid solution, and especially salvarsan, 10 per cent. in sesame oil, suspended by the aid of Iodipin (Merck) is recommended for injection into the pockets or applied to the gum, are highly recommended by Lederer. The writer has cured a number of cases of this type by the use of mercuric chlorid, 1 grain in each four ounces of H_2O_2. A microscopic examination was not made.[1] Vaughan recommends silver nitrate, 4 to 8 per cent., Lugol's solution, chromic acid, 10 per cent., zinc chlorid, 2 per cent., and Argyrol full strength, also a light diet and cathartics.

DENTAL STERILIZATION.

It must ever be borne in mind that the dental operator constantly works in a field of infection, and unless extraordinary precautions be taken every instrument which touches this field—the fingers of the operator, his mirrors, glasses, napkins, rubber dam, rubber dam clamps—becomes immediately infected as soon as it is brought in contact with the mouth of the patient. The likelihood of infection varies with the patient and the particular instruments; mouth mirrors, rubber dam clamps, scalers, and all instruments used in the treatment of pulp canals are likely to become more promptly and extensively infected than other instruments. Again, the forms of the instruments determine whether or not increased opportunity is given for the retention of infective material. The fingers of the operator may be the medium through which infective material is transferred from one patient to another. Infection may be carried from superficial areas of the mucous membrane of the mouth, from the enamel and the saliva, into deeper structures, where conditions are favorable for the development of sepsis.

The scheme for dental sterilization, therefore, includes the sterilization of the operator, instruments, apparatus, appliances, etc., used in operations, and the sterilization of the field of operation prior to operating.

The Operator.—Extreme personal cleanliness upon the part of an operator is clearly the first step in asepsis. The best class of dentists are exceedingly neat as regards personal habits; daily bathing, care of the nails and of the skin, and immaculate linen form as much a part of the day's labor as dental operations *per se*. The virtues of soap

[1] For an exhaustive article see Vaughan, Dental Cosmos, June, 1912.

and water, wherever they may be applied, are regarded as a very important item in preventing infection.

Linen which has been boiled prior to wearing may be regarded as safely sterile; so that the matter of personal sterilization relates to the hands, particularly to the finger-nails. The space under the nails is a favorable habitat for many organisms, notably the pyogenic cocci, the staphylococcus pyogenes aureus being commonly present in this situation.

It has always been advised that the finger-nails be trimmed short, and be made smooth to avoid mechanical injury to the soft tissues of the patient. Since the advent of aseptic and antiseptic surgery these precautions have an additional significance; nails kept short and smooth may be more readily cleansed than if long and ill-kept. The nails should be cut so that they nowhere project beyond the tips of the fingers. Their mechanical cleansing should be done with smooth instruments, not sharp knife-blades; the latter produce rough surfaces, which furnish spaces for lodgement of bacteria. There is but one effective method of washing beneath the nails; it is that followed by the general surgeon. After dipping the soap in water as hot as can be borne by the hands, all of the finger-nails should be made to scrape the soap until the spaces under the nails are filled with soap. After this coarse hand-brushes are used to scour every part of the hands with soap and water as hot as can be borne. Special nail-brushes are next used to scrub beneath the nails, driving out piecemeal the soap masses there. The general surgeon continues the scrubbing until the nails are scrupulously clean. The soap usually used is Castile, or soap made from palm oil, etc., but antiseptic soaps, such as ethereal soaps, may be substituted with advantage. Tincture of green soap is effective (see below).

Sterilization of the cleansed hands is insured by immersing them for five minutes in antiseptic solutions, such as 50 per cent. alcohol. The hands should be sterilized after treating each patient; rubbing the hands with a paste of mustard, flour, and water for three minutes and washing off with sterilized water is effective. (Nancrede.) If the patient dismissed has possessed an unusually septic mouth, or has been a syphilitic, for example, the time for hand cleansing and sterilization is to be prolonged; if syphilitic, every instrument used is transferred to separate vessels containing antiseptic solutions or boiled, and the hands are viewed as highly infected; they are scrubbed with mercuric chlorid solutions to prevent personal infection or the carriage of infection. Chancres have from time to time appeared upon the fingers of dentists as well as physicians. In a known syphilitic case one might use the rubber gloves worn by surgeons, at any rate all abrasions should be covered with collodion.

Sterilization of Apparatus.—The scrupulous cleanliness of the operating chair, of which the head-rest should receive frequent changes of boiled linen coverings, the metallic parts should be rubbed, and general covering cleansed; the cleansing, polishing, and sterilizing of cuspidors; the changing of paper coverings upon instrument tables, etc., are part of the general scheme of sterilization. The floor of the operating room also requires attention; instead of being covered with carpet, it is preferable to have it made of parquetry material or cement, over which rugs are laid, which may be removed from the room for cleansing; the floor proper being scrubbed.

Napkins used about the mouth are certain to become infected, so that their boiling should be prolonged at least fifteen minutes. For many operations it is preferable to substitute strips of muslin for linen napkins, which after being used may be thrown away.

If a hydraulic saliva ejector be used, the glass mouth tubes should be changed for each person, a sterilized tube being substituted directly before its use is required. A number of these tubes should be in use, and may be sterilized after washing by placing them in a 50 per cent. solution of listerine or a formaldehyd solution for a few hours. Tumblers and mouth mirrors may be sterilized in like manner. The cloudiness of saliva tubes is produced by the formation of salivary calculus, and may be removed by the use of acidulated water.[1]

At the close of each day a large cup should be filled with an antiseptic solution, which is to be drawn through the tubing of the ejector to keep it in a reasonably aseptic condition.

'Rubber dam may be sterilized by boiling water, but it is more safe and cleanly to use a new piece for each patient. It should be washed and then dusted with borated talcum powder.

The water used for douching cavities should be boiled previous to placing in the warmer, and should have a little pleasant antiseptic added to it.

Nancrede[2] states that all pyogenic cocci, and even anthrax spores, are killed by boiling instruments for two minutes in a 1 per cent. solution of sodium carbonate, which also prevents rusting.

Mouth mirrors and other instruments which can be wet may be placed for one-half hour or longer in a covered jar containing 20 per cent. formaldehyd, to which borax has been added to saturation. Rusting is prevented by borax (Williams).

Broaches, trephines, and other small points requiring to be kept sterile may be placed in a bottle such as are sold containing gold cylinders, and kept wet with any essential oil or carbolic acid.

[1] Thornton: Dental Review, 1903. [2] Park's Surgery by American Authors.

G. Zederbaum[1] suggests sticking the shanks in the cork; when to be used the cork is to be transferred to another bottle of like size containing alcohol and shaken to remove the antiseptic. They may then be washed in sterilized water.

Extracting forceps require careful mechanical cleansing and prolonged boiling after each use, for perhaps more cases of infection, and of many kinds, have resulted from unclean forceps than from all other causes combined.

Instruments, such as hand-pieces, which cannot be conveniently wet may be wiped off with alcohol and then subjected for thirty minutes to formaldehyd gas, any closed vessel may have cotton rolls saturated with liquid formaldehyd placed therein. Enough gas is given off to disinfect. Lacking a special apparatus an aluminum omelet pan with the handle filed off makes a convenient and not unsightly sterilizer. If desired, all the instruments may be so sterilized. These methods involve the employment of several instruments of each kind, an economy of time in any event. The entire instrument case may be disinfected by placing a formalin tablet in each drawer (Miller).

Sterilizing the Field of Operation. A good method is to forcibly spray the mouth with a 1 to 3 per cent. solution of hydrogen dioxid, in order to force infective material from about the teeth. The other solutions, as a solution of potassium permanganate or mercuric cholorid or alcohol may then be used. This spraying or washing should be somewhat prolonged when the mucous membrane is likely to be injured, as in extractions which often result in infection from the patient's own secretions. Many operators keep a stock of inexpensive toothbrushes for such cases, which are thrown away after the patient has used them, who is directed to scrub the teeth well with the brush and the antiseptic solution.

For very thorough disinfection thoroughly cleanse the teeth and use the antiseptic between them upon floss silk. For surgical work or etherization very active work should be done. Wadsworth,[2] in an investigation of mouth washes and their action on pneumococci, found but little value in the ordinary wash or even solutions of formalin, lysol, or H_2O_2. He found that

℞—Alcohol . . . . . 30 parts
Water . . . . . 70 parts
Glycerin and salt, a small quantity added.

was very effective in destroying the bacteria.

[1] Dental Cosmos, 1907.

[2] Ibid.

In a series of tests upon the devitalizing power of germicides for streptococcus, gonococcus, pneumococcus, and Bacillus typhosus, Post and Nicoll[1] found tincture of "green soap" (a brownish liquid composed chiefly of alcohol and caustic potash), alcohol in solutions above 50 per cent., silver nitrate solution from 1 to 1000 to stronger, tincture of iodin, Senn's solution (iodin 1, potassium iodid 1, water 100 and even 400), phenol, 5 per cent., and chloroform were effective in one minute.

Potassium chlorate, mercuric chlorid, 1 to 500, failed in ten minutes. Boric acid failed in two hours. As some of these germicides are for the mouth and some for the hands the information is of great practical value. Perhaps the best method of sterilizing gums for injections or gum margins for work is to spray off any accumulation and apply tincture of iodin for a few minutes.

The routine practice of scaling and polishing the teeth and prescribing an antiseptic mouth wash prior to the commencement of a series of sittings is to be highly commended.

In scaling the writer uses antiseptic washes freely during the entire operation.

If ulcerations or inflammatory conditions exist, the sterilization is to be prolonged. If a suspicion of syphilis exist, not only should the mouth be freely washed with strong antiseptics, but special instruments should be used, preferably an old set, kept sterilized and used only in special cases.

A deep infection may usually be prevented during the treatment of pyorrhea alveolaris and pulp gangrene by attention to the sterilization of the infected tract before beginning work upon the parts or during its progress. These methods have been indicated in the discussion of these subjects.

[1] Spence: Dental Cosmos, 1911, p. 548.

INDEX.

A

Abnormal food supply, 28
nerve supply, 29
physical conditions, 29
waste removal, 29
Abrasion, 300
acids in, 306
in animals, 308
of calculus, 306
degrees of, 301
during sleep, 301, 311
effects of, 307
from clasp, 306
gritty powders as cause of, 305
labial and approximal, 303
lingual, 307
occlusal, 300
pulp hyperemia in, 477
relation to caries in, 303, 307
tooth-brush in, 306
treatment of, 309
Abscess, apical, acute, 586
causes of, 586
clinical history of, 593
diagnosis of, 595
extraction in, 603
guards in, 599
pathology of, 588
scar threatened in, 606
stages of pus formation in, 589
symptoms of, 588
systematic stopping in, 613
systemic complication in, 604, 607, 630, 643
treatment of, 598
varieties of, 592, 597
chronic, 609
blind, 631, 642
necrosis from, 635
scar from, 534
symptoms of, 617
in temporary teeth, 638
treatment of, 618
with fistula, 614
without fistula, 609
around third molar, 234
fistula in, 134, 614
perforation of bone in, 601, 614
pericemental, 745
Abscess, pointing in, 134, 604
of pulp, 497
pus in, 134
syringe, 619
Absence of teeth, 275
Absorbent organ, 217
Acacia, use of, 207
Accidents to teeth, 671
Acetanilid as cause of hemorrhage, 120
use of, 400, 491, 605
Acidity, hyper-, 98, 102, 307, 359, 415, 740, 741
Acidosis, acids in, 93
Aconite, tincture of, 124, 234, 476
Aconitin, use of, 234
Actinomycosis of mouth, 780
Aërogenic bacteria, 45
Adenoids in mouth breathing, 224, 228
Adrenalin, use of, 403, 517
Age as predisposition, 31
Agenesia of enamel, 260
Agglutination, 61
Air warm, use of, 401
Albumin, fermentation of, 47
Albuminuria, 112
Alcohol, injection of, 765
use of, 150, 401, 423, 789, 791, 992
Alexins, 54
Aloin compound, use of, 689
Alopecia, from dental disease, 763
Alteration, definition of, 21
Alum, use of, 483, 490, 491, 612
Alveolar process, fracture of, 672
Alveolitis, postextraction, 603, 633, 672
Amalgam, copper, use of, 430, 561
facing, 527
Amboceptors, 61
Ameba of dysentery, 38
properties of, 18
of pyorrhea, 714
Ameloblasts, 160
Ammonia, use of, 423, 642
Ammonol, use of, 400
Amputation of roots, 619, 623, 727
Amyl nitrite, use of, 519
Anemia, 114, 116
Anesthesia of apical tissue, 520
conductive, 407, 482, 520
diplœic, 408
general, use of, 398, 515
mucous, 407, 482

Anesthesia of nerve trunk, 407
by pressure. *See* Pressure.
of pulp, 404, 407, 515
reflex, 409
Angina, Ludwig's, 235, 787
simplex, 786
Vincent's, 675, 681, 787
Angle, classification of malocclusion by, 223
Ankylosis, dental, 654
Anomalies of teeth. *See* Malformations.
Antikamnia, use of, 400
Antipyrin, use of, 764
Antiseptic powders, antiseptic washes and, use of, 439, 679, 738, 791
Antitoxin, formation of, 57
streptococcus, use of, 150
Antrum, empyema of, 626
Aphthæ, 769
Aqua regia, use of, 536, 549
Aristol, use of, 429
Arsenic, accidents with, 528
action of, on gum tissue, 528
on pulp tissue, 521
variations in, 513
apical hyperemia from, 521
coverings for, 527
formulæ for, 525
iodide of, use of, 488
mummifying paste and, 530
necrosis from, 529
objections to, 524
pocket for, 528
pulp hyperemia from, 521
in pulp nodule, 464
resistance to, 464, 492, 524
second application of, 524, 528
suffusion from, 522, 524, 531
use of, 492, 525
danger of, 492, 528, 645
Arsenical fiber, 526
Asperin, use of, 491
Astringents, use of, 126, 679, 738
Atomizer, use of, 739
Atrophy, 79, 253
marginal, of gum, 690
Harlan's method in, 690
Atropin, use of, 381, 649
Attachment of teeth, 265, 266
Auto-intoxication, general malnutrition as cause of, 93
oral, effects of, 684

B

Bacteria, action of gastric juice upon, 54
aërogenic, 45
in blood, 44, 49
as cause of disease, 36
of inflammation, 131
chemical composition of, 39
chromogenic, 45
Bacteria, classification of, 41
conditions antagonizing, 53
of dental caries, 340, 342, 343, 362, 378, 633
destruction of, by tissue, 53
division of, in blood, 45
effect of blood reaction upon, 64
external antagonistic agencies, 65
facultative, 45
fermenting action of, 45
ferments of, 46, 47
forms of, 41
immunity to, 56, 57, 61
intoxication and general infection by, 44, 48, 49, 53, 55, 136, 146, 148, 234, 439, 603, 631, 742, 781
life of, conditions of, 40, 45
localization of, 44
media of, 40
motility of, 40
of mouth, 50
obligate, 45
parasitic, 44
pathogenic, 49, 51
penetration of root tubules by, 640
of secondary dentin by, 457, 498
photogenic, 45
plaques of, 348, 362
position in vegetable kingdom, 36
predisposition to, action of, 30, 31, 50
products of, 48
pyogenic, 132
resistance to, 53
saprophytic, 45
spore formation of, 43
spreading of, in tissue, 49
zoöglea of, 43
zymogenic, 45
Bacterial plaques in dental caries, 340, 362
Balsam of Peru, use of, 622, 624, 634, 738
Band, dental, 159
Bandage, use of, 126
Beck's bismuth paste, 622, 624, 625, 739
Benzoic acid, use of, 679
Benzoin, use of, 476, 482, 490
Bilein, use of, 689
Bismuth, subnitrate, use of, 207, 739
Black, glands of, 165, 193
Black's 1-2-3 mixture, use of, 739
operation for scar, 630
Blastomycosis, 39, 769
Bleaching agents, use of, 581
Blindness, dental, cause of, 762
Blisters, use of, 125
Blood, alterations in, 113
bacteria in, 44–49
coagulation of, 116
extravasation of, 119, 126, 480, 484, 507
pressure, 123

Blood, reaction of, as immunizing factor, 64
supply to teeth and jaws, 190
Bloodletting in inflammation, etc., 138, 236, 491
Blue light, use of, 400, 599, 642
Bodkin, wire, use of, 442
Bone, caries of, 89, 144, 617, 635
of face, embryology of, 153
infection of, from dental lesions, 633, 635
inflammation of, 142, 633
of jaw, crypts of, 166
development of, 165
necrosis of, 145
from alveolodental abscess, 633
from syphilis, 595, 780
perforation of, in abscess, 601, 614
regeneration of, 146
resorption of, 146, 687
in gingivitis, 690, 701
septa, 166
Borax. *See* Sodium biborate.
Boric acid, use of, 764
Boroglycerin, use of, 680
Brewer's yeast, use of, 137
Broaches, Downie, use of, 534
Swiss, 554
use of, 534, 554
Bromural, use of, 400
Brush, use of, 439
Bruxomania, 301

C

Caffein, use of, 605, 764
Calcareous infiltration, 87
Calcific degeneration of pulp, 466
Calcification of teeth, 161
tubular, 449
Calcium chloride, use of, 121
lactate, use of, 121
salts in blood, 696
in pus, 711
Calcoglobulin, 161, 164, 454, 462
Calcospherites, chemical composition of, 161
in dentin, 180
in enamel, 176
in pulp nodule, 460
Calculi, basis of, 88, 693
Calculus, analysis of, 694
hematogenic, 711
origin of, 693
pyogenic, 711
salivary, 692
analysis of, 694
foreign bodies in, 695
hardening of, 699
hematogenic, 711
mode of deposit of, 698
occurrence of, 693
organic factor of, 697
Calculus, salivary, origin of, 693
pathological effects of, 701
pyogenic, 711
removal of, 704
scalers for, 702, 703, 704
structure of, 695
treatment of, 704
varieties of, 692
sanguinary, 711
subgingival, 708
Calendula, use of, 680
Callahan method, 536
Calomel, use of, 321, 776
Campho-phenique. *See* Phenol camphor.
Canada balsam, use of, 423, 553
Canals, accidents in opening, 548
continuity of, lost, 432
fillings, removal of, 575, 641
imperfectly filled, results of, 641
root, enlargement of, 533
topography of, 541–543
Cancrum oris, 772
Cantharides, use of, 532
Cantilever wire spur, use of, 678
Capping for pulp, 427
Capsicum plaster, use of, 476
Carbohydrates in dental caries, 340, 344, 347
Carbolic acid, use of, 207, 235, 401, 411, 412, 414, 418, 475, 490, 496, 520, 531, 601, 739, 619
Carbon dioxid, defective elimination of, 96, 316
paper, use of, 666
Carcinoma, 78, 784
Caries of bone, 89, 144, 617, 635
dental, 337
acids in, 343
neutralization of, 376, 415, 443
age in, 357
alkalies in, 443
arrangement of teeth in, 351
bacteria of, 342, 344, 364, 369, 378
bacterial plaque in, 348, 362
bodily condition in, 358
calcareous waters in, 357
causes of, 340, 344, 347
bacterial, 340, 342, 344
exciting, 339
synopsis of, 340
predisposing, local, 349
systemic, 356
in cementum, 384
chemical reactions in, 344, 376
clinical history of, 385
deep-seated, 416, 418
defects of fillings in, 351, 379
dentin in, 371
decalcification of, 372
secondary, 382, 388
diagnosis of, 390
diet in, 346, 352, 361, 445

Caries, dental, eburnation in, 383
effect of malnutrition upon, 96
in enamel, 362, 340
experiments in, 341
ferments in, 341, 375, 377, 379
filth as a protection from, 349, 361
foodstuffs in, 346
glycogenic, 346, 355, 358, 360
heredity in, 356
history of, 337
clinical, 385
inception of, 340, 362, 385
location of, 362
lactates formed in, 343, 376
lactic acid in, 343
liquefaction foci in, 378
loss of crown by, 431
of root by, 431
of tissues in, 380
Miller's general experiments on, 341
morbid anatomy of, 362
mucin in, 355
of Nasmyth's membrane, 371
pathology of, 362
penetrating, 387
perforation by, 389, 428
periodicity in, 357
pigmentation in, 383
prenatal influence in, 356
prognosis of, 392
progress of, 386
saliva in, 354, 443
prophylaxis of, 437
pulp in, almost exposed, 421
exposed, 425
recurrence of, 436
relative liability of teeth to, 385
saliva in, 354, 443
school children and, 357, 358, 438
of secondary dentin, 382–388
self-healed, 371
simple, 416, 417
spreading, 387
stages of, 396
structure of teeth in, 352, 388
sulphocyanate in, 359, 360
superficial, 416
symptoms of, 390
of temporary teeth, 432
terminations of, 388
therapeutics of, 416
toxic effects of, 438
transparent zone in, 380, 387
tube casts in, 380
under fillings in, 379
Caroid, use of, 137
Caseation, 83
Castor oil, use of, 207, 634, 764
Catabolism, 23
Cataphoresis in hypersensitive dentin, 403, 419
Cataphoresis, use of, 520
Cataplasma kaolini, use of, 237, 600, 605
Cathartics, use of, 125, 600
Caush, tubes of, in enamel, 174
Caustics, use of, 137
Cautery, actual, use of, 311, 415
electric, use of, 311, 415
Cavitine, use of, 418, 419, 423
Cells, chemical changes in, 23, 24
composition of, 17
giant, 67, 218
hypertrophy of, 67
life conditions of, 25
movements of, 18
nucleus of, 18
properties of, 19
phagocytic, 19
receptors of, 24, 59
reproduction of, 20
stimulation of, effects of, 20, 21, 66
stimuli of, 20
Cellulitis, submaxillary, 787
Cement substance, 162, 163, 167
solution of, 363, 368
oxychlorid of zinc. *See* Zinc.
oxyphosphate of copper. *See* Copper.
oxysulphate of zinc. *See* Zinc.
silicate, use of, 322, 418
zinc phosphate. *See* Zinc.
Cementum in dental caries, 384, 417
formation of, 167
histology of, 167, 182
malformations of, microscopic, 250
nutritional relation to dentin, 183
relation of, to enamel, 174, 182
repair of, 324
Chalk mixture, use of, 207
use of, 414, 442
Chancre of hands, 789
of mouth, 777
Cheek, distention of, by air pressure, 576, 621
swelling of, 605
Chemotaxis, 55
Chewing gum, use of, 444
Chloroform, use of, 234, 418, 476, 482, 551
Chloro-percha, use of, 398, 414, 476, 482, 575
Chlorophyll, chemical action of, 39
Chlorosis, 115
Chorea from dental disease, 653
from dentition, 232
Chromogenic bacteria, 45
Cinchona, use of, 738
Cinnamon, oil of, use of, 739
Circulation, disturbances of, 113
local, 122
Cleansing of teeth, 439, 705
Cleft palate, embryology of, 156
Clot, absorption of, 142
healing under, 142

Clot, septic, 119, 151
Cloudy swelling, 83
Cloves, oil of, use of, 401, 414, 427, 475
Coagulants, use of, 121, 410, 526
Coagulation of blood, 116, 130, 132
necrosis, 90, 132
Cobalt, use of, 526
Cocain, systemic effects of, 519
use of, 403, 411, 475, 515, 634
Codein, use of, 491
Cold, use of, 124, 138, 204, 236
Colloid degeneration, 86, 511
Coloboma, 81
Colophony, use of, 414, 553
Color of teeth, 299, 329, 580
Complement, 61
Compress, use of, 120, 126, 606
Concrescence of teeth, 263
diagnosis of, 233
Conical teeth, 253
Constipation, dental pain from, 763
Copper amalgam, use of, 430, 438, 507
oxyphosphate of, use of, 415, 507
sulphate, use of, 738, 781
Cords, dental, 159, 170
Cotton root dressings, 554, 574, 621
salicylized, use of, 725
tampons, danger of, 604, 633
Counterirritants, use of, 145, 476
Counterpressure in opening tooth, 598
Credé's ointment, use of, 150
Creosote, use of, 552
Cresol, use of. *See* Formocresol.
Crowns, cantilever, use of, 430
loss of, by caries, 431
removable, 584
use of, 431
Crypts of teeth, relations of, 166, 170, 175
Cup gum, use of, 621
Cups, use of, 125
Curette, use of, 137
Cusps, supplemental, 270
Cycle, vicious, 30
Cysts, associated with apical conditions, 614, 642
causes of, 68
dentigerous, 69, 283
dermoid, 69
teeth in, 70
impacted teeth as cause of, 68, 283
varieties of, 68

D

Deafness, dental, cause of, 653, 762
Decalcification of dentin in dental caries, 372
of teeth, 66, 217
Degeneration, 81
calcific, of pulp, 466
cloudy, of pulp, 511
colloid, 86
Degeneration, colloid, of pulp, 511
fatty, 81
of pulp, 511
fibroid, 507, 669
of pericementum, 661, 669
of pulp, 507
hyalin, 85
in mouth, 85
of mucous membrane, 85
lardaceous, 86
mucoid, 85
of mucous membrane, 85
of nerve-end of pulp, 514
of pericementum, 661
Dehydrator, use of, 401
Dentifrice, use of, 443
Dentin, caries of, 371
decalcification in, 371, 422
secondary, 450
development of, 161
granular layer of, 181, 249
histology of, 176
hypersensitivity of, 181, 393
causes of, 393
diagnosis of, 390, 393
pathology of, 393
symptoms of, 396, 753
treatment of, 398
interglobular spaces in, 249
lines in, 176
of Schreger in, 176, 250
malformations of, microscopic, 247
nutritional relation of, to cementum, 183
to dentin, 183
recalcification of, 424
repair of, 324, 450
resistance to acid by, 660
resorption of, 487, 504
secondary, 182, 424, 450
bacterial penetration of, 457, 498
staining of, 334, 383
by putrefaction, 580
stains of, treatment of, 335, 580
tubes of, 176
tubular calcification of, 449
tumor of, 453
Dentinal fibrils, 162
papilla, 159
Dentition, cause of, 194
constitutional states modifying, 200, 214, 231
normal, 198
pathological, 198
as cause of epilepsy, 200
climate and weather in, 200
convulsions in, 203
diet in, 208
first, 198
headache in, 203
hemophilia in, 206
hemorrhage after, 205

Dentition, pathological, intestinal complications in, 201, 207
feeding after, 208
lancing in, 204
nervous disturbances in, 199, 202, 213
paralysis in, 203
pulmonary disturbances in, 204
saliva in, 198
shock after lancing in, 206
skin disorders in, 204, 206
strabismus in, 204
symptoms of, 200, 202
systemic conditions influencing, 200, 214, 231
treatment of, 204
periods of, 197
process of, 196
second, 215
disorders of, 230
irregularities of, 220
necrosis in, 231
pathological, 232
symptoms of, 196, 198
Depletion of gum, 491
of pulp, 491
Derivation, use of, 125, 213, 236
Dermoid cysts, 69
teeth in, 70
Development of face, 153
of teeth, 159
Devitalization of pulp, 521
Devitalizing fiber, use of, 516, 526
Diabetes mellitus, 101
Diagnosis, definition of, 26
forms of, 26
Diathesis, acquired, 94
gouty, 104
hemorrhagic, 119
hyperacid, 93
Dilaceration of teeth, 267
Discoloration of teeth, 329, 580
Disease, bacterial causes of, 36
basis of, 25
causes of, 28
exciting, 28
predisposing, 30
clinical history of, 26
existing, as a predisposition, 33
functional, 25
predisposition to, 30
previous, as a predisposition, 33
of teeth, 666
Dislocation of teeth, 671
Distomolar, 279
Dobell's solution, use of, 626
Donaldson cleaners, use of, 534
Dover's powders, use of, 600
Downie broaches, use of, 534
Drill, Gates-Glidden, use of, 537
spear, use of, 598
Dropsical infiltration, 86
Drugs, intoxication by, 100, 774
Dry cups, use of, 125, 621
socket, 634
Dryness, use of, 401
Dunn syringe, use of, 738
Dwarfism of teeth, 251
Dysentery, ameba of, 38

E

Ear, disease of, from dental cause, 653, 762
Eburnation in dental caries, 383
Ecchymosis, 119
Ehrlich's theory of immunity, 59
Electrical disinfection of root canal, 612
Electricity in pulp putrefaction, 577
as test, 564
Embalming paste, use of, 551
Emboli, septic, 119, 151
Embolism, 118
Embryology of face, 153
of teeth, 157
Emetin, use of, 739
Emphysema of cheek from air pressure, 576, 621
Empyema of antrum, 626
Enamel, agenesia of, 260
in dental caries, 340, 362
development of, 162
formation of, effect of exanthemata upon, 253
fracture of, 322
histology of, 172
hypoplasia of, 253
imbrications of, 245
lines of Schreger in, 174
malformation of, macroscopic, 251
microscopic, 239
nodule, 268
opaque spots in, 240
organ, development of, 159
organic matter in, 172, 242
parts of, 172
relation of, to cementum, 174
resorption of, 312
rod, 163
sensitivity of, 396
stains upon, 331
striæ of, 163, 244
stripes of Retzius in, 174, 244
of Schreger in, 174, 245
tubes of, 173
Caush's, 173
unusual location of, 268
Encystment of teeth, 283
Endarteritis obliterans, 77, 688
Energy, nerve, loss of, 110
sources of, 23, 99
Epilepsy from dental disease, 200, 653
pathological dentition as cause of, 200
Epizoötic stomatitis, 712
Equinia, 772

Ergot, use of, 121, 124
Erosion of teeth, 313
acids in, 314
extraneous, 317
effects of, 319
malnutrition upon, 96, 316
possible action of glycogen in, 84
treatment of, 321
Eruption of teeth, causes of. *See* Dentition.
Escharotics, effects of, 29, 645
Ether, use of, 398, 402, 519
Ethyl chlorid, use of, 402
Etiology, definition of, 26, 28
Eucalyptol, use of, 551, 575
Euca-percha, use of, 551, 639
Eugenol, use of, 423, 475, 476
Evans' root drier, use of, 531, 553
Exanthemata, 152
malformations caused by, 152, 253
necrosis caused by, 152, 214, 231
Excess of teeth, 278
Exostosis of alveolar process, 653
Extirpation of pulp, 532
Extravasation of blood. *See* Blood.
Eye, disease of, from dental cause, 653, 756, 758

F

Face, development of, 153
embryology of, 153
fistula on, treatment of, 606, 630
Farradism as test, 564
Fat, degeneration of, 81
infiltration of, 81
necrosis of, 91
Fermentation, bacteria as causes of, 45
definition of, 45
products of, 46
of proteid matter, 47
Ferments, organized, 46
unorganized, 46
varieties of, 47
Fever, 146
Fevers, eruption, 773
Fibrin, formation of, 116
Fibroma, 74
Fibrosis. *See* Degeneration.
Filling material, use of, 309, 321, 416, 426, 438
Fillings, combination of, 422
Fistulæ, 134
in antrum, 626
causes of, 617
on face, threatened, 606, 630
treatment of, 630
healing of, 622
making artificial, 601, 614
non-healing of, 621
packing, 623
premature closure of, 137, 604
Flagg's operation for scar, 628
Fletcher's carbolized resin, use of, 414, 429
Flexion of teeth, 267
Floss silk, use of, 391, 441
Follicle, dental, 167, 170
wall of, 161, 168
becomes pericementum, 168
Food, chemical changes in, 24
concentrated, use of, 150
supply, abnormal, 28, 94
Formaldehyd, action of, upon products of putrefaction, 572
uses of, 413, 477, 496, 501, 517, 544, 546, 680, 790
Formocresol, use of, 496, 546, 612, 639, 640
Formo-percha, use of, 551, 578, 612, 621
Fracture of alveolar process, 671
of teeth, 322, 571
repair of, 324, 451
reunited, 324
treatment of, 326
Fungi, animal, 36
as ferments, 45
vegetable, 36
Fungous gum, 429
Fusion of teeth, 261

G

Gall-stones, origin of, 81, 693
Galvanism, sterilization by, 612
as test, 564
Gangrene, 89, 91
circumscribed, 92
dry, 91
moist, 91
discoloration from, 580
of pulp, 562
dry, 562
moist, 565
partial, 570, 580
Gastric juice, action of, on bacteria, 49
Gaultheria, oil of, use of, 739
Gelatin, use and danger of, 120
Gemination of teeth, 266
Geranium-formol, use of, 572
Germicides, action of, 65, 791
Giantism of teeth, 251
Gingivitis, 673
antiseptic washes in, 679
astringent washes in, 679
deeply seated, 682
interstitial, 682
marginal, 674
resorption of bone in, 687, 701
systemic causes of, 683
Glanders, 772
Glands, pericemental, 165
Glycerin, use of, 237, 402
Glycogen in caries, 346, 355, 358, 359, 360
infiltration of, 84, 355

Glycogenic infiltration in dental caries, 355
Gonorrhea of mouth, 781
Gout, 103
chronic, 103
contrasted with rheumatism, 108
diet in, 105
oral effects of, 747
relation of, to teeth, 710
salts deposited in, 103
treatment of, 105
Goutiness, 104
treatment of, 105
Granulations in regeneration, 138, 146
Greenfield's artificial root, 625
Grippe. *See* La Grippe.
Guards, use of, 477, 599
Guillotine, gum, 235
Gum, depletion of, 491, 604
glycogenic infiltration of, 84
hyperplastic, 389, 429, 506
laceration of, 671
lancing of, 204, 235, 604
marginal atrophy of, 690
Harlan's method in, 690
tissue, action of arsenic on, 528
Gutta-percha, eucalyptol solution of, use of, 551, 639
use of, 418, 421, 423, 430, 433, 476, 507, 550, 638

H

Hair, teeth and, 70, 276
Halisteresis ossium, 146, 687
Hamamelis distillate, use of, 604
Hands, sterilization of, 790
Hare-lip, 157
Harlan's method in atrophy, 690
Headache in dentition, 203
from impaction, 294
from pulp diseases, 756
Healing by second intention, 140
under a clot or scab, 142
Heat, use of, 137, 606
Hematogenic calculus, 711
Hemoglobin, derivatives of, 89, 580
Hemophilia, 119
in dentition, 206
Hemorrhage, acetanilid as cause of, 120
after extraction, 672
pulp removal, 518
replantation for, 121
treatment of, 120
varieties of, 119
Hemorrhagic diathesis, 119
sex in, 120
Heredity as a predisposition, 33
Herpes labialis, 783
zoster, 783
Hertwig root, sheath of, 165
Heteroplasty following amputation of natural roots, 728
High-frequency current, 563, 623, 739
Histology, morbid, 25
Hoffendahl, electric method of, 577
Hot water, use of, 410
Howship's lacunæ, 146, 658
Hutchinson's teeth, 254
Hydrastis, use of, 121
Hydrogen dioxid, 206, 235, 496, 582, 623, 706, 770
dangers of, 614
Hydronaphthol, use of, 623, 691
Hygiene, definition of, 27
Hyoscyamin, use of, 400
Hyperacidity. *See* Acidity.
Hyperacidosis, 93
Hypercementosis, 650
reflex neuroses from, 653
Hyperemia, arterial, 122
collateral, 123
compensatory, 123
degrees of, 124
pathology of, 125
of pulp, 468
arterial, 468
devitalization in, 478
from arsenic, 521
from electric action, 479
from hypercementosis, 653
idiopathic, 471, 478
thermal toleration in, 474, 478
venous, 479
devitalization in, 524
from hanging, 482
reflex, 123
as a resistance to infection, 124
results of, 123
symptoms of, 124, 471, 482
treatment of, 124
venous, 125
suffusion from, 480
Hypernutrition, 66
Hyperplasia, 68, 503, 506
of gum, 389
of pulp, 389
Hypersensitivity of dentin, 393. *See* Dentin.
Hypertrophy of cells, 67
Hypnotism, use of, 400
Hyponutrition, 79
Hypophosphites, use of, 488
Hypoplasia, 79, 253
of enamel, 253
Hysteria, 233

I

Ichthyol, use of, 773
Immunity, 34, 56
acquired, 57
blood reaction in, 64
Ehrlich's theory of, 59
lost, 35, 56
natural, 56
Impaction of teeth, 283

Impaction of teeth, as cause of cysts, 69, 294
death of pulp from, 293
diagnosis of, 295
headache from, 294
neuralgia from, 292
resorption of roots from, 285, 295, 657
symptoms of, 292
treatment of, 296
Implantation, 625
Inanition, 99
Indican as an index for malnutrition, 100, 685
Indol, 100
Infants, feeding of, 208
Infarction, 119
of pulp, 507
Infection, classes of, 49
general septic, 149
of mouth, 766
predisposition to, 30, 31, 56
resistance of tissue to, 52
spreading of, 48
Infiltration, calcareous, 87
dropsical, 86
fatty, 81
glycogenic, 74, 355
pigmentary, 88
Inflammation, 127
bacteria in, 127, 131
bloodletting in, 138
of bone, 143
catarrhal, 130
causes of, 127
coagulation in, 129, 132
derivation in, 138
exudates of, 126
infective, 131
necrosis in, 132
pathology of, 127, 131
of pulp, 483
chronic, 501
resolution in, 132
simple, 127
stimulation in, 138
suppurative, 132
symptoms of, 131, 135
general, 131, 135, 136
treatment of, 137
Injury of teeth, 322
Inoculation by bacteria, 49
Insanity from dental disease, 294, 759
Insomnia from dental disease, 439, 762
Instruments, sterilization of, 790
Insulator, 311
Intermaxillary bone, failure of development of, 168
formation of, 153
Intestinal complications in pathological dentition, 201, 297
Intoxications, 100
acid, 102
bacterial, 101, 148
Intoxications, drug, 100
intestinal, 94, 686
intrinsic, 101, 102
septic, 148
Intubation of root, 584
Involucrum, 145
Iodin, dental, tincture of, 476
use of, 235, 412, 476, 507, 530, 549, 572, 579, 770, 792
Iodoform, use of, 549, 623
Iodoglycerol, use of, 738
Iron, chloride of, tincture of, use of, 353, 605
dialyzed, use of, 530
Ischemia, 122

J

Jaw, development of, 153
growth of, cause of, 172
Jodoformagen, use of, 423, 427
Joining of teeth, 421, 699
Jugulation of pulp, 481

K

Kalium natrium, use of, 536, 577
Karyokinesis, 20
Kerr broaches, uses of, 534
Kowarska's paste, 729
Krameria, use of, 680

L

Laceration of soft tissues, 672
Lactic acid, use of, 738
Lacunæ, Howship's, 146
La grippe, as cause of reflex pain, 763
Lanolin, use of, 149, 776
Laudanum, use of, 121, 672
Lead, oral effects of, 649
water, use of, 121
Leeches, use of, 600
Leprosy, 786
Leukemia, 115
Leukocytosis, 115
Leukoplakia buccalis, 783
Lichen planus, 784
Light, electric, use of, 391
Lime-water, use of, 446
Linings, use of, 419
Listerine, use of, 207, 770, 790
Lithemia, 106
Lithia salts, use of, 689, 741
Liver, functions of, 98
in general malnutrition, 95, 98
Ludwig's angina, 235, 787
Lupus of mouth, 780
Luxation of teeth, 639
Lymphangitis, 605

M

Magnesia, milk of, use of, 321, 415
sulphate of, use of, 125, 600, 697
Malaria, dental pain from, 763
Malformations, macroscopic, 251
microscopic, 239
of roots, 271, 545
of teeth, 239
Malnutrition, causes of, 23, 93
from gingivitis, 742
general, 93. *See* Bacteria intoxications.
auto-intoxication in, 93
diet in, 97, 105
Malocclusion of teeth, 664
causes of, 219
classification of, 223
Malpositions of teeth, 281
Massage, use of, 605, 738
vibratory, 605
Maxillæ, embryology of, 154
Maxillary rampart, 159
Mechanical injury of teeth, 322
union of teeth, 266
Meckel's cartilage, 158
Melancholia from dental disease, 762
Menthol, use of, 401, 482, 496, 540, 764
Menthol-phenol, use of, 475, 648
Mercury, bichlorid of, use of, 150, 235, 559, 605, 621, 624, 648, 649, 681, 789, 792
as cause of stomatitis, 648
oral effects of, 232, 648, 681
Talbot's experiments on dogs with, 644
Metabolism, diseases of, 24, 93
Metastasis, 56, 144
Methyl chlorid, use of, 402
Microörganisms, as disease causes, 36
Milk, modified, 208
Mitosis, 20
Morphin, use of, 138, 399, 491, 600
Motor reflexes from dental disease, 761
Mouth, actinomycosis of, 780
asepsis of, 788
bacteria of, 50
pathogenic, 51
breathing, 224
development of, 153
gangrene of, 772
gonorrhea of, 781
hyaline degeneration in, 85
infections of, 766
inflammation of. *See* Stomatitis.
lamp, electric, use of, 390, 626
sepsis from. *See* Bacteria intoxication.
soft tissues of, laceration of, 672
sterilization of, 788
syphilis of, 775
tuberculosis of, 780
washes, application of, 679, 788
Mucin, characteristics of, 85
Mucin in dental caries, 355
Mucoid degeneration, 85
of mucous membrane, 85
Mucous membrane, glycogen in, 84
hyaline degeneration of, 85
mucoid degeneration of, 85
overstimulation of, effects of, 84
Mummification of pulp, 556, 558
Mummifying paste, arsenic and, 530
Mustard, use of, 125, 789
Myers' syringe, use of, 406, 518
Myrrh, tincture of, use of, 649, 681

N

Nasmyth's membrane, 165, 172
in dental caries, 371
Necrobiosis, 89
Necrosis, 89
after extraction, 634
of alveolar bone, 608
of bone, 145
arsenical, 529
from alveolodental abscess, 635
from syphilis, 636, 775
coagulation, 90, 132
etiology of, 89
of fat, 91
from exanthemata, 231
from mercury, 232, 648
from typhoid fever, 221
liquefaction in, 91
phosphorus and, 785
varieties of, 89
Neoplasm of pulp, 511
Nerve energy, loss of, 110
fifth, 754
sensory, of face, 754
supply, abnormal, 29
trophic influence of, 29
vasomotor, 122, 29
Nervocidin, use of, 520
Nervous disturbances in dental disease, 203, 752
in dentition, 193, 204
Neuman, sheath of, 162, 176
Neuralgia, cause of, 270, 389
from hypercementosis, 653
from hypersensitive dentin, 753
from impacted teeth, 277
from pericemental disease, 757
from pulp disease, 755
from secondary dentin, 433
treatment of, 764
Neurasthenia, 110
Neuroma, 155
Neuroses, reflex, 752
Nitric acid, use of, 311
Nitrous oxid gas, use of, 398, 491
Nodule, cemental, 273
in pulp, 458
Noma, 235, 772

Non-conductors, uses of, 419
Novocain, use of, 407, 518
Number of teeth, variations in, 275
Nutrition, basis of, 22
deficiency of, 79
disturbances of, 24, 28, 30, 66, 93
excess of, 66

O

Obligate bacteria, 45
Odontalgia, phantom, 759
Odontoblasts, 160, 178
atrophy of, 453, 510
relation of, to sensory nerves, 181
Odontomata, 273
Oligocythemia, 107
Opium, use of, 121, 125, 207, 234, 602
Opsonic index, raising of, 622, 740
Opsonins, 62
Organic matter, decomposition of, 45, 47
fermentation of, 45
Organs, composition of, 22
Orthoform, use of, 413, 429
Osteitis, condensing, 144
rarefying, 144
Osteodentin, 456
Osteomalacia, 146, 446, 687
Osteomyelitis, 143
Osteoporosis, 144
Osteosclerosis, 144
Overarch bar, use of, 664
Overfeeding, 99
Overuse of teeth, 661, 664
Oxaluria, 110
Oxidation, deficiency of, 93
excessive, 93
Oxygen, nascent, use of, 582

P

Pain, dental, from other sources than dental, 763
postextraction, 603, 633, 672
Palate, cleft, cause of, 156
Papain, use of, 560
Papoid, use of, 137
Paraffin, use of, 552, 739
Paraform, use of, 612
Paraglossus, 311
Paralysis from dental disease, 760
in dentition, 203
Paramolar, 279
Parasitic bacteria, 44
Pathogenesis, definition of, 26
Pathogenic bacteria, 44, 49
Pathology, basis of, 17, 25
dental, definition of, 17
general, definition of, 17
Pediluvium, hot, use of, 118, 600
Peptones, 47, 126
Perforation by accident, 548
by caries, 389, 428
Perforation as cause of abscess of root, 619
filling of, 561
in septic cases, 637
Pericemental abscess, 745
Pericementitis, 585. *See* also Pyorrhea alveolaris.
acute, septic, apical, 581
extraction in, 602
beginning at gum margin, 674
chronic, septic, apical, 609
classification of, 585
gouty, 710
non-purulent, 639
non-septic, 644
chemical, 645
results of, 650
symptomatic, 648
phagedenic, 676
septic at bifurcations of roots, 643
symptomatology of, 585
traumatic, 644
Pericementum, blood supply to, 190
calcospherites in, 193
cellular element of, 186, 193
degeneration of, 661
fibroid, 669
development of, 168
diseases of, 586
fibrosis of, 669
function of, 184
glands of, 165, 193
histology of, 184
nerves of, 190
overuse of, 661
Periostitis, 143
maxillary, 617
proliferative, 143
suppurative, 143
Peru, balsam of. *See* Balsam.
Petechia, 119
Phagocytosis, 19, 55, 152, 622
Phantom odontalgia, 759
Phenacetin, use of, 400, 491
Phenobromate, use of, 400
Phenol camphor, use of, 414, 475, 540, 672, 689, 739, 771
sodique, use of, 444, 672, 724, 770
Phenolsulphonic acid, 619
Phosphaturia, 111
Phosphor necrosis, 785
Phosphorus, use of, 81, 785
Physical condition, abnormal, 29
Physiology, morbid, 25
Pigmentary infiltration, 88
Pigmentation in dental caries, 383
Pigments in tissue, 88
Pilocarpin, oral effects of, 648
Pins, removal of, 576
Piscidia erythrina, use of, 400
Plantation, mode of attachment in, 659
resorption after, 656
Plaques, microbic, 348, 362
Plaster of Paris, use of, 427

Plethora, 113
Podophyllin, use of, 689
Pointing, 134
Polycythemia, 113
Porte-polisher, use of, 442
Potassium bromid, use of, 402
carbonate, use of, 402
chlorate, use of, 206, 444, 649, 681, 792
hydrate, use of, 411
permanganate, use of,
sulphocyanate, use of, 415
Poultices, danger of, 606
uses of, 606
Powder, tooth, use of, 443
Precipitins, 62
Predisposition to disease, 30
general, 30
local, 33
Pregnancy, dental pain from, 763
Pressure anesthesia, 458, 465, 474, 482, 496, 516
hemorrhage after, 517
Process, alveolar, fracture of, 672
Prognosis, definition of, 26
Prophylaxis, 26, 437, 445
Proteid, composition of, 18
fermentation of, 47
use of, 23
Protoplasm, composition of, 18
properties of, 22
Protozoa as disease causes, 36
Pseudoödontalgia, 759, 764
Ptomains, 44, 47
Pulp, abscess of, 497
action of arsenic on, 521
anesthesia of, 405, 415
blood supply of, 178
capping of, 426
cavity, duplication of, 267
forms of, 186
constructive diseases of, 449
death of, from impaction, 294
symptoms of, 563
degeneration of, 507
calcific, 465
cloudy, 486
colloid, 514
fatty, 511
fibroid, 507
nerve, 514
depletion of, 482, 490
destructive diseases of, 468
devitalization of, 521
digestion of, 560
exposure of, symptoms of, 425
treatment of, 422, 426
extirpation of, 532
gangrene of, 562
partial, 570
histology of, 176
hyperemia of, 468
arterial, 468
devitalization in, 476
Pulp, hyperemia of, arterial, from electric action, 479
idiopathic, 471, 478
thermal toleration in, 478
from arsenic, 521
venous, 479
suffusion in, 480
hyperplasia of, 389, 503
infarction of, 507
inflammation of, 483. *See* Pulpitis.
chronic, 501
jugulation of, 481
knocking out, 531
mummification of, 556, 558
neoplasm of, 511
nerves of, 181
nodules, 458
arsenic and, 465
puncturing of, 482, 490, 531
putrefaction of, 565
reaction of, 447
removal of, 515
partial, 557
special methods of, 531
replantation of, vitality after, 456
sclerosis of, 501
sedation of, 475
suppuration of, 492
swelling of, 486
thermal tolerance of, 424
toughening of, 538
ulceration of, 493
vitality of, tests for, 563
Pulpitis, 483
acute, 484
chronic, 501
from pyorrhea, 666
hyperplastic, 503
resorption of dentin in, 487
Pumice, use of, 705
Purpura hemorrhagica, 786
Pus formation, stages of, in apical abscess, 589
varieties of, 135
Putrefaction, 47, 565
formalin in, 572
germs of, effects of electricity upon, 577
of pulp, 565
Pyemia, 151, 782
Pyocyaneo-protein, use of, 637
Pyogenic calculus, 711
Pyorrhea alveolaris, 713
abscess secondary to, 721, 745
beginning with a marginal gingivitis, 716
in bifurcations of roots, 727
breath in, 720
bridge and plates in, 662, 736
causes of, 713
clinical history of, 716
dental caries and, 687
diagnosis of, 716, 723
endarteritis in, 719

Pyorrhea alveolaris, gum incision in, 726
recession in, 716
heteroplasty of roots in, 728
interstitial gingivitis in, 683, 719
living pulps and, 727
looseness in, 719
malnutritional factor in, 740
not dependent upon calculus, 743
opsonic index in, 740
oral catarrh in, 720
pathology of, 716
prevention of motion in, 729
prophylaxis in, 737, 741
recurrence of, 741
replantation in, 740
root amputation in, 727
shifting of teeth in, 665, 720
splints for use in, 729
systemic effects of, 742
symptoms of, 716
treatment of, 724
medicinal in, 737
varieties of, 715
Pyrozone, use of, 531, 582, 624

Q

Quinin, use of, 150, 400, 491, 600, 605, 764

R

Rachitis, 110
Rampart, maxillary, 159
Recalcification of dentin, 423
Receptors of cells, 24, 59
Reflex action, 199, 201, 203, 761
disorders of dental origin, 752
of systemic origin, 763
neuroses, 752
pain, 464, 470, 471
pathology of, 752
Regeneration of tissue, 138, 146
Repair of dentin and cementum, 324, 455
Replantation, 624
for hemorrhage, 121
of pulp, vitality after, 456
secondary dentin after, 456
of teeth, 647
Resorcin, use of, 143
Resorption of bone, 146
varieties of, 146, 687
of enamel, 312
of permanent roots, 655
of pulp, 487, 504
of temporary roots, 216
perforation by, 219
Retention of teeth, 221
Retzius, stripes of, in enamel, 174, 244
Rhein, root methods of, 539, 540
Rheumatism, 107
chronic, 109
contrasted with gout, 108
muscular, 109
treatment of, 108
Ridge, dental, 159
Robinson's remedy, use of, 311, 411, 415, 418
Root, amputation of, 619, 623, 727
artificial, 625
bifurcation, formation of, 168
calcification of, 167, 171, 176
canal, accidents in opening, 548
anatomy of, 541, 543
cementum forming end of, 168
electrical disinfection of, 577
filling of, 550, 613
inaccessible foramina of, 544
loss of continuity of, 432
development of, 167, 220
drier, Evans', use of, 531, 552
filling, immediate, 539, 576
removal of, 549
fracture from putrefaction, 571
fusion and concrescence, 272
implantation of, 625
long and short, 270
loss of, by caries, 389, 432
malformations of, 271, 545
multiple, 271
perforation, 329
permanent, formation of, 220
resorption of, 295, 655
repair of, 324
replantation of, 647
resorption of, 216, 219
of permanent, 655
soap in, use of, 619, 789, 792
sterilization of, 571
systematic stopping, 613
temporary, resorption of, 216
transplantation of, 431, 625
Rose geranium, oil of, use of, 572
Rubber band, use of, 441
cup, use of, 621, 705
sore mouth and, 771

S

Saccharin, use of, 207
Salicylic acid, use of, 679
Saliva, analysis of, 695
in dental caries, 354, 443
in general malnutrition, 93, 314
increased flow of, 198
infective bacteria in, 50, 781
lack of, 354
relation of acid food to, 355
Salivary calculus, 692. *See* Calculus.
Salol, use of, 150, 207, 553, 605
Salter, lines of, in dentin, 176
Salvarsan, use of, 780

Sandarac, use of, 429
Sanguinary calculus, 711
Sapremia, 148
Saprophytic bacteria, 45
Sarcoma, 74
Scab, healing under, 142
Schizomycetes, 36, 41
Schreger, stripes of, in dentin, 176
in enamel, 174, 245
Sclerosis of pulp, 501
Scorbutus, 109, 215, 649, 786
infantile, 215
oral effects of, 649, 786
Scurvy. *See* Scorbutus.
Sedation, results of, 21
Sedatives, use of, 475, 482, 490, 501, 648
Sepsis dental, bacterial intoxication and, 439
general, of dental origin, 439, 631, 781
intoxication from, bacterial intoxication and, 148, 439
Septicemia, 149, 235, 782
from apical abscess, 604, 631
Sequestrum, 89, 92, 145, 785
Serres, glands of, 193
Serum therapy, 59, 122
Sex as predisposing cause of disease, 31
Sheaths of Neuman, 162, 176
Side chain theory, Ehrlich's, 24, 59
Silicate cements, use of, 322, 418, 424
Silver, Credé's ointment, use of, 150
soluble, use of, 150
nitrate, use of, 311, 412, 415, 433, 438, 477, 530, 624, 770
Sinus, 134
Size of teeth, variations in, 251
Skin eruptions, 152, 204, 632
Slough, 92
Soap, use of, 619, 789, 792
Sodium biborate, use of, 679, 790
bicarbonate, use of, 412, 423, 490, 689, 764, 785
bromid, use of, 213
carbonate, use of, 411
chlorid, use of, 412, 549, 681, 689, 738
dioxid, danger of, 577
use of, 336, 412, 549, 576, 582, 790
hydrate, use of, 411
potassium and, alloy of, use of, 536, 577
sulphate, use of, 121
Somnaform, use of, 399, 515
Sphacelus, 87
Sponge, use of, 637
Stains, black, 333
in dentin, 334
dyes and, 333
green, 331
metallic, 329
non-metallic, 331
red, 333
Stains, tobacco, 333
treatment of, 334
Starvation of tissue, 99
Stellate, reticulum, 160, 164
Steresol, use of, 297
Sterilization, dental, 788
Stimulation, effects of, 21, 66
Staples, use of, 328, 421, 643
Stomatitis, 766
aphthous, 769, 772
classification of varieties of, 767
in dentition, 204, 206
epizoötic, 772
follicular, 771
from drugs, 774
from eruptive fevers, 773
from glanders, 772
infective catarrhal, 767
mercurial, 768
beneficial effects of mercury in, 649, 681
simple catarrhal, 767
symptomatic catarrhal, 768
typhoid, 768
ulcerosa, 677
ulcerative, 769
Stopping, systematic, 613
Strabismus in dentition, 204
Stratum intermedium, 160, 165
Strontium lactate, use of, 121
Structure of teeth, 239, 352, 388
Strychnin, use of, 519, 765
Subgingival calculus, 708
Suffusion, 119, 580
from arsenic, 524, 531
from hanging, 482
from venous hyperemia, 480
Sugar in diabetes, 101, 360, 358
as source of energy, 24, 99
Sulphocyanate, use of, 360, 415
Sulphuric acid, use of, 531, 549, 622, 624, 738
Sulphurous acid, use of, 583
Supernumerary teeth, 280
Supplemental cusps, 270
Suppuration in inflammation, 132
of pulp, 492
Suprarenal extract, use of, 121
Susceptibility to disease, 30
Symbiosis, 49
Symptoms, definition of, 25
objective, 26
subjective, 26
Synostosis, dental, 654
Syphilis, dental pain from, 763
hereditary, 257
of mouth, 775
necrosis of bone from, 636, 775
oral effects of, 254
stigmata of, 257
Syphilitic teeth, 254
Systematic stopping of troublesome root, 613

T

Tannin, use of, 206, 402
Tartasol, use of, 738
Temperament, classes of, 32
Therapeutics, basis of, 21
  definition of, 17, 26
Thrombosis, 117, 481, 521
Thymol, use of, 420, 423, 427, 475, 483, 490, 496, 540
Thymophen, use of, 475
Tic douloureux, 464
Tissue, composition of, 23
  excessive destruction of, 99
  food supply to, 22
  regeneration of, 138
  resistance of, to bacteria, 53
  starvation of, 99
  waste, excessive, 99
Tomes, granular layer of, 249
Toxalbumins, 44, 48
Toxemia, 44, 48, 135, 136, 148
  in general malnutrition, 93
Toxins, 44, 48
  chemotactic properties of, 55
  as ferments, 44
  immunity to, 57
Toxoid, 60
Toxon, 61
Transparency of dental structures, 382, 449
Transparent zone, 380, 387
Transplantation, use of, 431, 625
Trephine, use of, 328, 643, 602
Treponema pallidum, 256
Trichloracetic acid, use of, 507, 738, 770
Trigemin, use of, 492, 600
Trioxymethylene, use of, 413
Trophic disturbance, 29
  from dental disease, 763
Tube casts in dental caries, 380
Tuberculosis of mouth, 780
Tubes of dentin, 176
  of enamel, 174
Tubular calcification, 449
Tumors, 72
Turkish baths, use of, 689, 741

U

Ulceration, 92, 136
  of pulp, 493
Uremia, 101
Urates in pericementum, 747
  in tissue, 97
Uric acid in gout, 103
Uterine disease, dental pain from, 763
Uvula, bifid, 158

V

Vaccine therapy, 62, 63, 150
Vapocain, use of, 402
Varnish, use of, 419, 421, 423, 476, 477
Vascular system, disturbances of, 113
Vaselin, use of, 739, 764
Vasomotor nerves, 122
Vegetable fungi, 36
Venous hyperemia, suffusion from, 455
Veratrin, use of, 225
Vibrator, use of, 605
Vincent's angina, 675, 681

W

Wall, follicular, 161
Waste, removal, abnormal, 28, 94
Water, boiling, as germicide, 790
  drinking of, 689, 741
  warm, use of, 418

X

X-rays, use of, 612, 623, 739

Z

Ziehler-Hoffendal, electric method of, 612
Zinc chlorid, use of, 410, 484, 517, 621, 679, 738
  iodide, use of, 738
  oxid and eugenol, use of, 423, 427, 476, 489, 638
    use of, 427
  oxychlorid of, use of, 411, 415, 423, 427, 551, 637
  oxyphosphate, use of, 232, 419 421, 423, 476
  oxysulphate, use of, 427
  sulphate, use of, 427
  sulphocarbolate, use of, 738
Zoöglea of bacteria, 43

COLUMBIA UNIVERSITY

This book is due on the date indicated below, or at the expiration of a definite period after the date of borrowing, as provided by the rules of the Library or by special arrangement with the Librarian in charge.

DATE BORROWED	DATE DUE	DATE BORROWED	DATE DUE
	OCT 8 '38		
	OCT 15 3[illegible]		
	OCT [illegible]		
	DEC 6 1949		
C28(638)M50			

COLUMBIA UNIVERSITY LIBRARIES (hsl,stx)
RK 301 B892 1915 C.1
A text-book of dental pathology and ther
2002340801

RK301 B892
1915
Burchard
Text-book of dental pathology and